

MR, CT and Conventional Radiography Practices



MR, CT and Conventional Radiography Practices

for Laboratory Medicine
and Diagnostic Imaging B.Sc. Students

The publication appeared following program:
TÁMOP-4.1.2.A/1-11/1-2011-0106

© Péter Bogner 2014
© Authors 2014
© Zsófia Kürtös 2014

Lectors:

Péter Bágyi
Erzsébet Grexa

Editor:

Péter Bogner

Authors:

Csaba Vandulek
Eszter Vinczen
Judit Rékási
Zsófia Kürtös
Orsolya Balogh
Zsuzsanna Szűle
Kornél Kelemen
Lászlóné Lukács
Tamás Simor
Szabolcs Halász

Translator:

Zsófia Kürtös

ISBN 978 963 226 487 5

Institutes taking part in constructing the electronical version of this book are:

Pécsi Tudomány Egyetem Egészségügyi Kar Kaposvári Képzési Központ Diagnosztikai Képző Tanszék
Kaposvári Egyetem Egészségügyi Centrum Onkoradiológiai Intézet
Pécsi Tudományegyetem Általános Orvostudományi Kar Humán Anatómiai Intézet

The CT and MR photos and pictures are shown with the permission of the Kaposvári Egyetem Egészségügyi Centrum Diagnosztikai Intézet as their own (all rights reserved) made by their associates.

Editor: Andrea Valovics

Cover designed by Mrs. Tamás Bede

Animations, videos: Csaba Vandulek, Kornél Kelemen, Zsuzsa Szűle

Technical editor: András Nász

Identification number: 3758



ÚJ SZÉCHENYI TERV

Medicina Könyvkiadó Zrt. ■ Budapest, 2014

Contents

I. MRI examinations step-by-step	7
1. MRI Safety.....	8
2. Basic terms and terminology.....	13
3. Patient preparation	18
4. Magnetic Resonance Imaging of the Brain.....	20
5. Magnetic Resonance Imaging of the Spine.....	33
6. Magnetic Resonance Imaging of the Upper Extremities.....	40
7. Magnetic Resonance Imaging of the Lower Extremities	51
8. Magnetic Resonance Imaging of the Neck.....	65
9. Magnetic Resonance Imaging of the Chest.....	69
10. Magnetic Resonance Imaging of the Abdomen.....	74
11. Magnetic Resonance Imaging of the Pelvis	80
12. MR Angiography.....	88
13. Magnetic Resonance Imaging of the Heart.....	92
14. Magnetic Resonance Imaging of the Breast.....	104
Quiz.....	108
Solutions.....	119

II. CT	120
1. Principles of CT Imaging, CT radiation dose optimization	121
2. CT image characteristics, postprocessing	125
3. Information on the handling of the injector.....	140
4. CT scan procedure, and the radiographer's tasks.....	142
5. CT imaging of the head.....	146
6. CT imaging of the musculoskeletal system and spine.....	157
7. CT imaging of the neck, mediastinum and chest wall.....	168
8. CT imaging of the lung	173
9. CT imaging of the vascular and lymphatic system.....	177
10. CT imaging of the liver and biliary tract.....	189
11. CT imaging of the pancreas, spleen and gastrointestinal tract.....	192
12. CT imaging of the abdomen, retroperitoneum and adrenal glands.....	202
13. CT imaging of the urinary tract.....	205
14. CT imaging of the male and female pelvis.....	208
15. CT imaging of the heart.....	211
16. Image quality, quality assurance	216
Quiz.....	218
Solutions.....	229

III. X-ray	230
1. Conventional radiology and the radiology workplace.....	231
2. X-ray photography.....	236
3. Introduction to radiographic imaging techniques.....	239
4. X-ray anatomy and imaging technique of the shoulder girdle and the humerus.....	246
5. X-ray anatomy and imaging technique of the upper limb.....	259
6. X-ray anatomy and imaging technique of the pelvis and lower limb.....	281
7. X-ray anatomy and imaging technique of the vertebral column and sacroiliac joint.....	317
8. X-ray anatomy and imaging technique of the bony chest and respiratory system.....	339
9. X-ray anatomy and imaging technique of the skull.....	354
10. X-ray anatomy and imaging technique of the facial bones.....	362
11. X-ray contrast agents.....	371
12. X-ray anatomy and non-contrast imaging of abdominal, and acute abdominal disorders.....	383
13. X-ray anatomy and imaging technique of the urinary system.....	388
14. X-ray anatomy and imaging technique of the gastrointestinal tract – part I.....	396
15. X-ray anatomy and imaging technique of the gastrointestinal tract – part II.....	403
16. X-ray anatomy, imaging technique and interventional procedures of the breast.....	408
17. Special x-ray examinations.....	414
18. X-ray imaging of polytrauma patients.....	417
Quiz.....	419
Solutions.....	436

I. MRI examinations step-by-step

I.1. Basic aspects of MRI

Introduction

Cross-sectional magnetic resonance imaging (MRI) has become a major diagnostic imaging modality in a few decades. Its key role is not only limited to the diagnosis of disease, but it also has an ever growing role in the therapy of diseases through interventional MRI procedures, as well as in medical research. Although MR imaging is a well-established imaging technique, it is important to note that it is still characterized by rapid and dynamic advancement that is closely related to the development of hardware, information technology and the changing expectations of medicine. From current research and development, interventional MRI should be highlighted as well as the development of ultra-high field equipment which have a constant magnetic field strength above 7 Tesla.

This dynamically developing imaging modality is associated with risk factors that underpin the importance of MRI accident prevention and safety skills and the need for regular training.

Safety aspects during the MRI examinations

According to international expert recommendations, each institution with an MRI equipment should work out their own MRI Safety Regulation that includes standards to ensure the safety of patients, employees and research subjects, and also the MRI diagnostic tests, interventional procedures, intraoperative studies and research that are performed in the examining room. Regular revision of these rules should be based upon the latest research findings and expert recommendations, and it should be followed by an upgrade of test equipment. Similar to the radiology department's practice where there is a designated radiation protection officer, it is recommended to have an MRI safety commissioner, who is responsible for enforcing local MRI accident prevention and safety regulations, organizing training within the MRI department, as well as for reviewing and updating these safety rules. In addition, it is recommended to document all equipment and examination related incidents appropriately, taking official regulations into account.

Fundamentally, all radiographers working in MRI are expected to not only have theoretical knowledge of safety aspects and regulations, but they are also expected to be able to apply them in their work for the safety of their patients and their own. In the following, working environment risk factors of MRI employees and related expectations will be reviewed.

Practical risk factors

Radiographers, working with MRI equipment, are exposed to different risks or harms while performing their duties. These risk factors may be categorized into two main groups: the direct effect of different magnetic field strengths, and the effects of cryogen liquids.

The effects of electromagnetic fields

During an MRI exam, the following three types of magnetic fields are expected in the scan room:

- Static magnetic field (B_0)
- Magnetic field of the alternating gradient (dB / dt)
- Radio frequency (RF) magnetic field (B_1)

Static magnetic field (B_0)

The most important accident prevention aspect of the constant magnetic field focuses on the following factors: biological effects of B_0 , ferromagnetic projectiles and implants.

Of the biological effects, the most significant risk factors are the induced currents which arise when a body is moving in the static magnetic field. The static field causes magnetic stray fields, which surround the MRI machine so that the distance from the isocenter determines the radiographer's involvement. For this reason, if a radiographer goes through this magnetic field, this may induce an electric current in the body. The speed at which the body moves (transit speed) may influence the degree of the induced current.

In practice, stray RF currents around the MRI device are infinitesimally small, thus they do not tend to be harmful to personnel. Discomfort could occur if some bodypart of the radiographer was within the MRI unit during the measurement, but this usually does not occur in clinical practice.

Other biological effects that may occur due to the static magnetic field are cardiovascular responses (elevation of blood pressure, changes in heart rate, and / or changes in the ECG curve). Based on the results of current research, these changes are within the physiological range, up to 8 Tesla magnetic field. Also, when working within 2 to 4 Tesla, radiographers may experience dizziness, nausea, a sudden flash of light or a metallic taste in the mouth. Based on current research these phenomena are transient, thus mainly those radiographers experience them who stay inside the MR room during the examination, for example during interventional and intraoperative MRI.

In contrast to biological effects, the attracting effect of the magnetic field may cause serious damage. In the static magnetic field, ferromagnetic materials have a significant chance to become

displaced or even to fly. The risk of injury to the patients and radiographers exists, especially when a subject moves as a projectile or if the radiographer gets stuck between the ferromagnetic object and the MR device. Because this may occur in the examination room, therefore it's prohibited to enter the study site with objects that contain ferromagnetic materials (eg.: wheelchair, oxygen tank, medical and non-medical equipment, etc.). The most dangerous area is the so-called control zone where the magnetic field is greater than 0.5 mT. It is forbidden to bring any non-MRI compatible devices into this area. It is practical to mark this boundary visibly on the floor of the examination room.

The constant magnetic field may interact with implants (pacemakers, aneurysm clips, neurostimulators, etc.) and monitoring instruments. Possible displacement of the implant can result in tissue damage within the body, or outside the body it can be dangerous. Other potential negative effects may be disruption or even destruction of the medical devices themselves.

Magnetic field of the alternating gradient (dB/dt)

Alternating gradient fields also require caution. In this case as well, stray fields are significantly smaller outside the MR unit than inside of it, but they may cause unwanted effects. This largely depends on the employed measuring technique, because the power and speed of the alternating gradient fields may vary accordingly. The main biological effects of the alternating gradient field are peripheral nerve stimulation, muscle stimulation, and acoustic noise. The electric circuits induced by alternating gradient fields may affect neurons and/or muscle fibers. In this case, the patient and the radiographer may have a feeling of discomfort, and in extreme cases, limb twitch or even ventricular fibrillation may occur.

The vibrating gradient coils cause substantial noise in the test room. The potential of this risk factor can be significantly affected by the mechanical structure of the MR equipment and the time spent in this environment. The noise level depends on the location of the radiographer within the examination room, and it can be as high as 80 dB for the majority of MRI equipments. Exposure to noise greater than 140 dB or prolonged and often repeated high levels of noise can permanently damage hearing

Radio frequency (RF) magnetic field (B_1)

During the examination, the most important adverse effects of the external magnetic field exciting the hydrogen protons are increase in body temperature, as well as burns. After the RF excitation, energy transfer occurs that results in a change in body tissue temperature. A 1° C increase in core temperature is admissible for a healthy person, but a higher body temperature fluctuation, especially in cardiovascular disease, can be harmful for the radiographer and the patient.

Contact burn injuries may occur during RF excitation, especially when the skin is in contact with metal objects, cables of body coils, ECG electrodes and the inner surface of the magnet. These accidents may be prevented by careful patient positioning.

In conjunction with the regulations of MR devices imposed by the medical devices directive (93/42/EEC), a factory-installed internal monitoring system ensures that the B_1 RF field does not cause greater than 1 °C warming, muscle contraction or any peripheral nerve stimulation. This monitoring is based on the Specific Absorption Rate (SAR) which limits the absorbed energy by the entire body between 1 Wkg⁻¹ – 4 Wkg⁻¹.

Cryogen fluids

During normal operating conditions, liquid cryogen gases that are used in the superconducting magnets do not pose a risk of injury, because the parts that are in contact with cryogenes can be found at the top of the magnet, and thus are out of reach for the radiographer. However, spontaneous or deliberate magnetic quenching should be treated as a source of increased risk for accident. Due to quenching, the static magnetic field's energy is converted into heat, which causes most of the liquid helium and sodium to condense. Ideally, this large amount of gas can leave the examination room through the dedicated exhaust pipes. In case of an MR magnet quench, the device's walls cool down substantially or they may even get icy, and a cloud-like formation may be observed in the examination room. The gaseous sodium and helium can get into the examination room if the conducting pipes are damaged or blocked.

In this case, the following adverse effects may occur:

- Asphyxia, since the gases displace oxygen from the test premises
- Frostbite and hypothermia
- Blast in the examination room due to overpressure

General guard

The most important precaution the radiographer can take is to be as far as possible from the MRI device. The greater the distance, the less she is exposed to electromagnetic fields. One meter around the opening of the MRI device is where the gradient of the static field is at its maximum, so the radiographer should move slowly within this area. Moreover, in general, it is advisable not to stay longer than required in the examination room, in order to minimize exposure to the electromagnetic fields, and all workers should be made aware of potential adverse effects.

The radiographer's exposure to the radio frequency and the alternating gradient fields may be reduced by her staying as far away from the MRI machine and by performing as few tasks in the middle of the magnetic field as possible. Thus, it is advisable to automate the injection of the contrast media, anesthetics and other medications during the study. In addition, efforts should be made to ensure that the various control units, anaesthesiology equipment and other instruments are located as far as possible from the MRI unit. The minimum distance largely depends on the strength of the radio frequency field and the alternating gradient field. Generally it can be stated that a minimum distance of one meter away from the device is necessary to prevent unwanted effects of the alternating gradient fields, although it is the safest and most appropriate to observe the 0.5mT border.

Summary

The radiographer plays a central role in the execution of the MRI exam therefore it is important for her to be aware of the regulations of MRI accident prevention and safety, to know these preventive measures and to know how to use them. New knowledge and the theoretical and practical aspects of the latest guidelines can be obtained through continuous professional education. Training for and simulating the commonly encountered accident situations with other employees, who may encounter the MRI equipment, are equally important.

I.2. Basic terms and terminology

Acquisition. Data acquisition takes place between two successive RF excitations during an MRI examination. RF excitation is followed by relaxation during which the precessing spins transmit their energy, that they acquired during excitation, in the form of RF waves. The RF waves are detected by coils, and then the encoded data are stored in the K-space.

Number of acquisitions (NA, NEX). It determines the number of acquisitions during data collection. It also determines how many times each line of the K-space will be read out.

Artefact. False features in the image produced by the imaging process.

B0. Conventional notation used to refer to the main or static magnetic field produced by the magnet.

B1. In the MRI system, it is the time-varying magnetic Bfield that is created by the RF excitation coils. During acquisition, it rotates (offsets) the patient's net magnetization vector (NMV).

Echo. The echo is the regrowth of the transverse magnetization component that follows after the cease of magnetization during dephasing.

Echo time (TE). It is the time between the 90 degree RF pulse and the received signal (echo) sampling.

Dephasing. Decreasing of the phase coherence of the signals in the transverse (XY) plane.

Excitation. Excitation of the hydrogen protons with RF pulses causes some of the protons to get to a higher energy state.

Fast spin echo (FSE). A commonly used sequence which consists of multiple 180° refocusing pulses to produce echoes with different phase encoding steps. In this method, several lines of the K-space is filled with one RF excitation pulse. The echo train determines how many data lines will be read out during an excitation.

Phase Encoding. Using different phases, the signals from the MR are decoded along one direction of the field.

These signals are created by a varying magnetic field gradient in a given slice that we previously chose by a slice selective gradient.

FID (Free Induction Decay). After the 90 degree RF pulse creates the transverse magnetization, a temporary MR signal is obtained, which will decrease in the direction of B_0 . This decreasing sinusoidal signal is the FID.

Flip angle (FA). This parameter indicates the angle by which the RF pulse offsets the magnetic vector from the Z axis (B_0) towards the X – Y direction.

Fourier transformation. It is a mathematical algorithm by which the computer is able to calculate the exact localization and intensity of the voxels.

FOV (Field of View). The size of the test region.

Frequency encoding. During data collection the gradient magnetic field creates a varying degree of precession along the gradient's direction. The frequency composition of the collected data corresponds to different spatial locations. This method gives us the other direction within the chosen slice besides the direction given by the slice selection gradient.

Gradient. The amount and direction of the rate of change in space of some quantity, such as magnetic field strength.

Gradient echo. A pulse sequence which, as opposed to the SE pulse sequence, rephases the spins in the XY plane after the RF pulse is applied by the gradient pulse.

Gradient magnetic field. It is the magnetic field created by the gradient coils, which changes the B_0 field in a given direction. Combining the selective excitation of several fields, the MR signals' location can be determined. These are the so-called slice encoding, frequency encoding and phase encoding gradients.

Gyromagnetic ratio. The property of a nucleus that determines its resonant frequency and it is related to its mass and charge. This is a constant for a given nucleus, and its unit is Hz/T. Using this ratio, the resonance frequency of the MR equipment can be determined (Larmor frequency).

Inversion Recovery (IR). A pulse sequence in which a 180 degree pulse precedes both the 90 degree excitation and the 180 degree refocusing pulses. Because of this, the net magnetization will be in an inverted position.

Inversion time. It is equal to the time interval between the 180° inversion pulse and the subsequent 90° pulse.

K-space. The K-space is the obtained data set (mathematical information) that results from data collection, and carries information about contrast (centrally), and resolution (peripheral). One line of the K-space corresponds to an echo which is collected during one phase encoding step. All the information about the images are included in the K-space. This mathematical information is transformed into an image using the Fourier transformation.

Larmor frequency. The precessional or resonant frequency (ω_0) of a nuclear spin when it is placed in an external magnetic field. It is related to the magnetic field (B_0).

Longitudinal magnetization. The net magnetization along the static magnetic field (M_z).

Magnetic induction. The physical quantity used to describe the strength of the magnetic field. Symbol: B, unit: T (tesla).

Magnetic resonance. It examines the changes in magnetism of the nuclei in a given tissue, caused by the effects of different electromagnetic fields.

Magnetization vector. The summation of all the (positive) individual magnetic moments in a sample. It is parallel to the external magnetic field (B_0).

Matrix. The number of pixels assigned to each imaging direction. At a fix FOV, if the matrix increases, the voxel size decreases. A higher image matrix leads to better spatial resolution but poorer SNR. For a larger image matrix, a longer acquisition time is needed, because then there will be more lines in the k-space.

Precession. The motion experienced by the nuclear magnetic moment under the influence of an external magnetic field. The spin angular momentum of the nucleus means that rather than simply align with the field, it traces out a cone around the direction of the field. A commonly used analogy is the motion of a spinning top in the Earth's gravitational field.

Proton density weighted image. It is equal to the number of hydrogen proton spins per unit volume of tissue. (Neither T1 (due to the long TR), nor T2 (due to the short TE) relaxation has any influence on it).

Pulse sequence. A set of RF and gradient pulses of fixed duration and separation, which are used to produce an MR image. The sequence is usually represented in a pulse sequence diagram. It consists of the following main steps: RF pulses, gradient switching, signal collection.

Radio frequency. It is an electromagnetic wave frequency, which is in the same range that the radio or the television uses. In MR imaging, the RF pulse band is between 1–300 MHz.

Radio frequency pulse (RF). The transient application of the magnetic component of an RF wave (referred to as the B1 field) for the purposes of perturbing the net magnetization. The pulse must be applied at the Larmor frequency and also in a direction that is perpendicular to B_0 .

Refocusing pulse. A specific application of an RF pulse which is used to recover the phase of spins. If it is applied at time TE/2 after an initial RF pulse, it will produce a spin echo at time TE. The optimum refocusing occurs when the refocusing flip angle is 180°.

Relaxation. The mechanisms which effect excited spins once the RF energy (B 1 pulse) has been removed, leading to a return to the equilibrium position where the net magnetization is aligned with the main magnetic field. The spins loses phase coherence due to transverse relaxation (T2) and then the signal recovers along the z-direction due to longitudinal relaxation (T1). The two processes happen at the same time.

Relaxation time. The T1 and T2 relaxation processes are characterized by T1 and T2 relaxation times. T1 relaxation is caused by the nuclei giving up their energy to the surrounding environment or lattice, and it is termed spin lattice relaxation. Energy released to the surrounding lattice causes the magnetic moments of nuclei to recover their longitudinal magnetization (magnetization in the longitudinal plane). The rate of recovery is an exponential process, with a recovery time constant called the T1 relaxation time. This is the time it takes 63% of the longitudinal magnetization to recover in the tissue. The T1 relaxation curve increases exponentially. T2 decay is caused by nuclei exchanging energy with neighboring nuclei. The energy exchange is caused by the magnetic fields of each nucleus interacting with its neighbor. It is termed spin-spin relaxation and results in decay or loss of coherent transverse magnetization (magnetization in the transverse plane). The rate of decay is also an exponential process, so that the T2 relaxation time of a tissue is its time constant of decay. It is the time it takes 63% of the transverse magnetization to be lost. The T2 relaxation curve decreases exponentially.

Repetition time (TR). It is the time between two 90° RF excitation pulses.

Resonance. A phenomenon, that occurs when a system with a natural frequency of f_0 starts vibration due to an external exciter vibration of the same frequency.

Resonance frequency (Larmor frequency). The precessional or resonant frequency (ω_0) of a nuclear spin when it is placed in an external magnetic field. It is related to the magnetic field (B_0) by the Larmor equation:

$$\omega_0 = g \times B_0, \text{ where } g \text{ is the gyromagnetic ratio.}$$

Bandwidth (BW). The frequency range of the receiver. It is related to the frequency used to encode each individual pixel. Hydrogen protons with slightly different resonance frequencies are excited as a function of the excitation RF pulse's bandwidth. The differences are determined by the spatial localization and the chemical environment.

SNR – signal to noise ratio. It is equal to the signal from the imaging slice divided by the noise which is picked up from the entire sensitive volume of the receiver coil.

Spin. It is the intrinsic angular momentum of an elementary particle. Composition of the nuclei (proton, neutron number) determines the magnetic moment, and the spin of the nucleus.

Spin echo (SE). The basic MRI pulse sequence using a 90° excitation pulse followed by a 180° refocusing pulse in order to recover T2* decay and produce a signal echo which has decayed due to T2 relaxation alone.

Slice selection gradient. This is the magnetic gradient which, depending on the slope, determines the localization and thickness of a given slice as a function of the RF pulse bandwidth.

T1 relaxation. T1 relaxation is caused by the nuclei giving up their energy to the surrounding environment or lattice, and it is termed spin lattice relaxation. Energy released to the surrounding lattice causes the magnetic moments of nuclei to recover their longitudinal magnetization (magnetization in the longitudinal plane). The rate of recovery is an exponential process, with a recovery time constant called the T1 relaxation time. This is the time it takes 63% of the longitudinal magnetization to recover in the tissue. The T1 relaxation curve increases exponentially.

T2 relaxation. T2 decay is caused by nuclei exchanging energy with neighboring nuclei. The energy exchange is caused by the magnetic fields of each nucleus interacting with its neighbor. It is termed spin-spin relaxation and results in decay or loss of coherent transverse magnetization (magnetization in the transverse plane). The rate of decay is also an exponential process, so that the T2 relaxation time of a tissue is its time constant of decay. It is the time it takes 63% of the transverse magnetization to be lost. The T2 relaxation curve decreases exponentially.

T2*. Pronounced "T-two-star." This is the effective or apparent transverse relaxation time. It is related to the dephasing of the net magnetization following the removal of the excitation pulse B1. This causes a signal decay in the transverse plane (xy axis) that is referred to as the free induction decay (FID). An image that is essentially T2-weighted although it is formed from a gradient echo so that the contrast is instead governed by T2*.

Transverse magnetization (Mxy). It is the net magnetization in the x-y plane, which depends on the flip angle.

I.3. Patient preparation

Due to significant development in MR imaging, as well as growth in the number of scanners, MRI has attained a key role in diagnostic imaging and intervention. Because it does not use ionizing radiation, this modality may be preferred over other imaging modalities, however, we need to take into account other important aspects regarding the effects of the strong magnetic field. Prevention of accidents, human injuries and damage to equipment is the MR radiographer's duty, therefore it is necessary to overview contraindications and patient preparation.

Screening for MR contraindications

Patient safety is our most important priority and it should be treated accordingly. Elimination of MRI contraindications before examination is the radiographer's task. Before the scan it is important that the examination consent form is carefully read, and all questions are answered with clear answers such as "YES" or "NO." Additional clarifications (any surgical procedures, implants, relevant work, and health history) should be included as well. This form must be signed by the patient or legal guardian and confirmed by MR personnel. The strong magnetic field in the MRI exam room can be dangerous and contraindicated for people who have metallic, electronic, magnetic, or mechanical implants, devices, and objects. Such metal implants are for example, pacemakers, defibrillators, cerebral aneurysm clips, eye prosthetics, built-in hearing devices, projectiles, lead shots, anvil dross, integrated artificial heart valves, joint prosthetics, orthopedic metals (screws, plates, nails, wires).

Patient preparation

Routine MRI exams (eg.: skull, spine, joints) typically do not require special preparation or special diets, and it is also not necessary for the patient to stop taking his medication before or after the contrast study. Mostly it is only necessary for abdominal and pelvic studies that the patient does not eat 6-8 hours before the test. All loosely fixed metal objects (such as hair clips, etc.) must be removed from the patient before the study. It is not allowed to take metal or magnetic objects (eg.: watches, crutches, phones, credit cards) into the examination room.

Depending on the examined region, it is advisable to remove all clothes and jewelries, because these can cause a reduction in image quality. For abdominal, pelvic, breast and multi-region con-

trast angiography studies patients should wear a gown. It may be necessary for women to remove their make-up before a head MRI scan because cosmetics' metallic content may cause artifacts.

If the patient has a medical metal implant the radiographer must make sure that the implant is not contraindicated. To do so, she should obtain the implant's serial number, which may be found in the patient's final surgical report, and check whether it is MR-compatible or not using online databases. The rule of thumb is that 6 weeks after surgery, MR examinations are contraindicated for all MR-compatible and non-compatible implants.

Gravidity

Pregnancy is not a contraindication, because based on current knowledge there is no proven adverse effect of the electrical magnetic field (0.1 T – 3 Tesla) to the fetus. Nevertheless, based on professional recommendations (MDA ESMRMB), examination of the pregnant patient should be avoided during the first trimester of pregnancy. In the II. and III. trimesters the referring physician has to weigh the risks against the benefits. If a nursing mother is about to undergo a contrast-enhanced MR examination, it is advisable for her to squeeze breast milk out before the test, and after intravenous contrast material administration she should not breastfeed for 24 hours.

Intravenous contrast material

It is essential that patients arrive adequately hydrated for the examination. It is the radiographer's job to find out if the patient has had a previous allergic reaction to contrast material, and to identify potential contributing factors of allergic reactions before the examination. Such potential factors are patients with severe allergy and asthma.

According to ESUR guidelines, the administration of intravenous gadolinium contrast agents is contraindicated in high-risk patients (eg.: patients with fourth and fifth stage chronic renal disease [GFR < 30 ml / min], decreased renal function, acute renal failure, patients who are about to or who have received a liver transplant, and finally patients who are on dialysis). In case of moderate risk patients and in uncertain cases, it is essential to check the patient's renal function, either by measuring the GFR or by calculating the eGFR from the serum creatinine level (ml/min/1.73m²).

I.4. Magnetic resonance imaging of the head

Exam preparation

After the general preparation, we make sure that the patient removes all metal containing objects (dentures, hearing aids, hairpins, body jewelry, earrings, etc.) and we also have to confirm that she washes off her make-up (mascara and make-up result in artifacts). Metallic fasteners in women's bra can cause unwanted artifacts, thus the patient should be asked to take it off.

The most common indications:

- congenital abnormalities
- primary and secondary space-occupying lesions (benign and malignant lesions)
- epilepsy
- demyelinating diseases
- vascular diseases
- inflammations
- vascular malformations
- stroke
- metabolic diseases
- trauma

Positioning

For MRI examinations of the brain, the patient is placed in a supine position, arms close to the body. The body axis is in the midline. The glabella should be at the center of the brain coil, chin pointing downward as shown in the figure below. With this position we can avoid the head falling backward – which frequently occurs, especially when imaging elder patients. Because kyphosis may raise the head higher, and since the occiput is larger in young children, we lift the chin. These factors should be considered when planning the slices. Centering is at the glabella. (Figure I.1.)

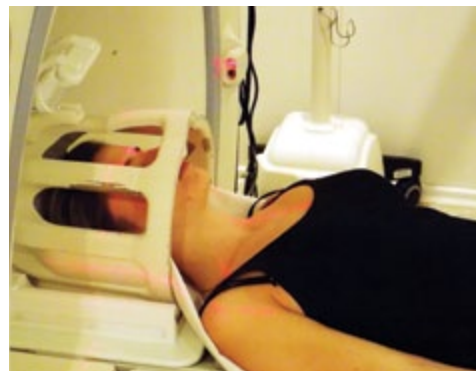

Figure I.1. Positioning of the head

[Video: Positioning for brain MRI scan](http://tamop.etk.pte.hu/tamop412A/Kepalkotasi_gyakorlatok_tananyag/MR/VIDEO_MR_GYAK/BOKA_FINAL.wmv)

http://tamop.etk.pte.hu/tamop412A/Kepalkotasi_gyakorlatok_tananyag/MR/VIDEO_MR_GYAK/BOKA_FINAL.wmv

Magnetic resonance imaging of the Brain

Protocols – imaging planes, sequences

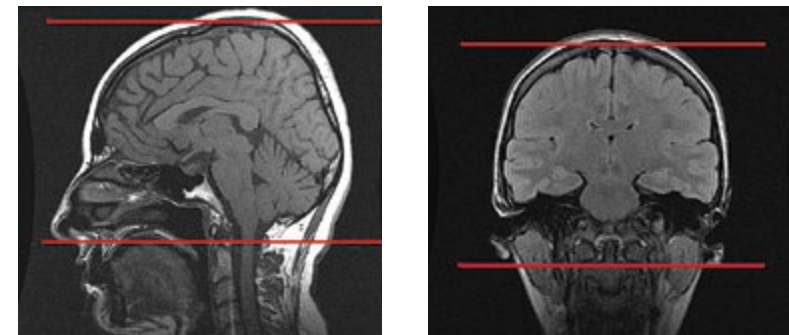
Routine examination planes and sequences may differ depending on local practice and MR equipment, but there are mandatory sequences. Ideally, slices in three orthogonal imaging planes are obtained – axial, sagittal, and coronal.

Recommended sequences:

- DTW – axial
- T2 – axial
- FLAIR – coronal
- T1 – sagittal

Additional sequences:

- Gradient Echo sequences – (GRE) - In case of hemorrhage and vascular malformations.
- CISS, FIESTA – In case of vertigo, and tinnitus.
- T2 – sagittal – Indicated in hydrocephalus.
- FLAIR – sagittal – In case of demyelinating disorders. – Paracoronal IR slices – for detection of epileptic foci
- Isotropic voxel 3D T1 measurements after intravenous administration of contrast material – made in any plane, from which, subsequently, the other two planes can be reconstructed.
- SWI (susceptibility-weighted imaging) – It is sensitive for hemorrhage and axonal damage.



Figures I.2.a, b Positioning of axial slices

Imaging planes:

Axial slices are plotted on the mid-sagittal plane. The plane of axial images should be parallel to the bicommissural line, which connects the anterior to the posterior commissure (AC-PC plane).

On the coronal localizer, images are obtained perpendicular to the center line. We obtain enough slices to cover the brain completely from the vertex to the skull base.

Mapping direction: caudo-cranial

Slice thickness: 3 mm

Gap: 0 mm

FOV: 22-26 cm

(Figures I.2.a, b)

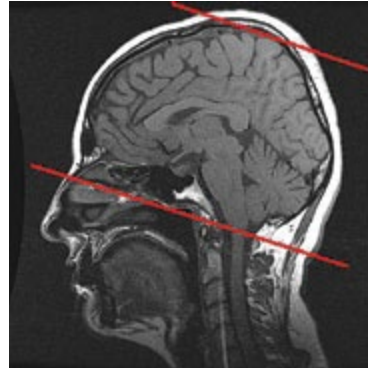


Figure I.3. Positioning of oblique axial slices

The oblique-axial plane is used for DWI and DTW. The plane of axial DWI images should be oblique to the frontobasalis plane. The slices cover the brain completely from the skull base to the vertex.

Mapping direction: caudo-cranial direction

Slice thickness: 3-5 mm

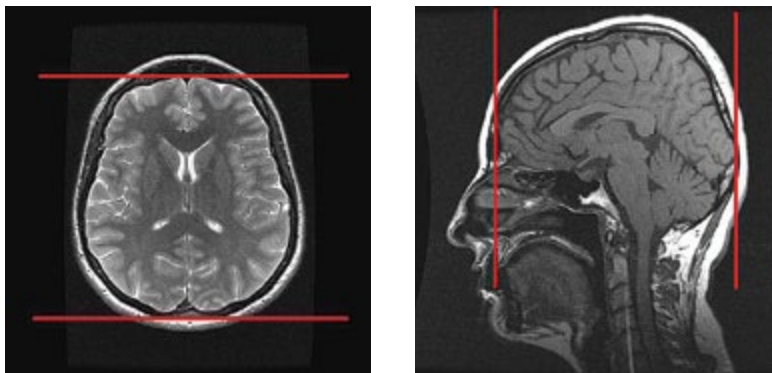
Gap: 0 mm

FOV: 26-28 cm

(Figure I.3.)

Coronal slices are plotted on the sagittal plane and perpendicular to the AC-PC line. If the head is in an optimal position, this plane corresponds to the frontobasalis plane and the pons – medulla oblongata plane. The slices are perpendicular to the center line of the axial images. The slices cover the skull from the frontal sinus to the occipital bone.

Mapping direction: antero-posterior



Figures I.4.a, b Positioning of coronal slices

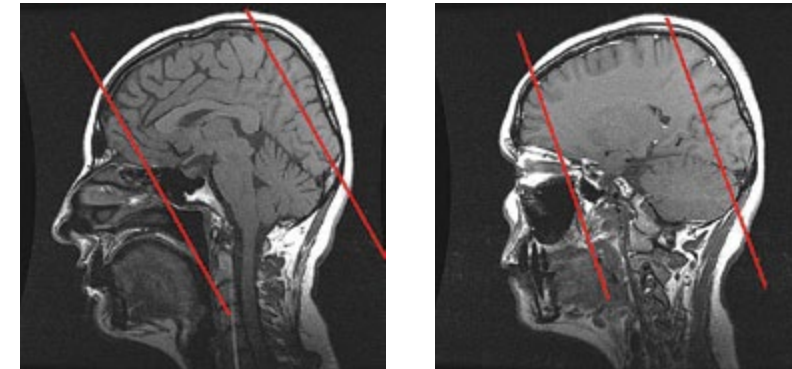


Figure I.5. Positioning of paracoronal slices

Slice thickness: 4 mm

Gap: 0.5 mm

FOV: 22-26 cm

(Figures I.4.a, b)

Oblique coronal slices are used when imaging patients with epilepsy; these slices are perpendicular to the hippocampi. (Figure I.5.)

The sagittal slices are placed parallel to the midbrain line on axial and coronal slices. On sagittal images, check the FOV to avoid (aliasing) artifacts. The slices cover the skull between the parietal bones, and the middle slice goes through the center line (mid-sagittal plane).

Mapping direction: right-to-left

Slice thickness: 4 mm

Gap: 0.5 mm

FOV: 22-26 mm

(Figure I.6.)

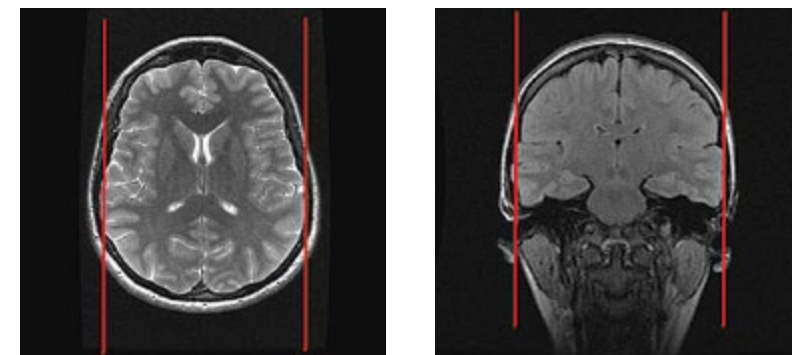
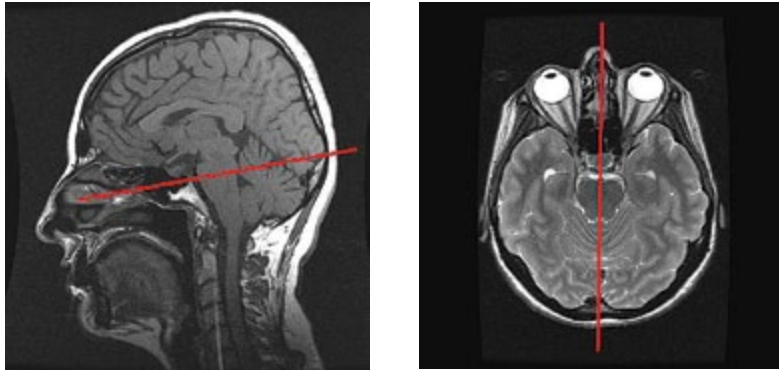


Figure I.6. Positioning of sagittal slices



Figures I.7.a, b Placing axial and sagittal images in CINE MR sequence

After the administration of intravenous contrast material, 3D T1-weighted measurements are made. The mapping is done in any 3 planes without inclination. From the 1-mm isotropic images, we create reconstructions in any plane. If the patient feels uneasy, non-enhanced T1 measurements can be made in all three planes in order to reduce motion artifacts. After administration of the contrast agent, it is recommended to delay the start of the postcontrast measurement by at least three minutes so that blood-brain barrier disruptions can be visualized.

CSF pulsation: (CINE MR)

Useful for the detection of hydrocephalus. Axial slices are perpendicular to the cerebral aqueduct, while sagittal slices, passing through the aqueduct, are perpendicular to the midline. (*Figures I.7.a, b*)

Magnetic resonance imaging of the facial bones

Recommended sequences:

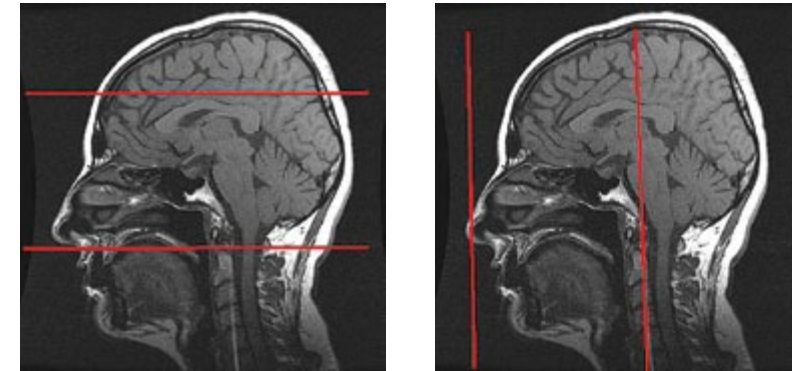
- T2 – axial
- T1 – axial
- T1 – coronal
- STIR – coronal

Additional sequences:

- T1 – parasagittal plane
- after administration of intravenous contrast material: T1 + FATSAT – axial and coronal

Imaging planes:

Axial slices cover the skull from the tongue root to the top of the frontal sinus. The slices are parallel to the plane of the palatum durum (hard palate).



Figures I.8.a, b Planning of the facial bone examination

Mapping direction: caudo-cranial
 Slice thickness: 3-4 mm
 Gap: 0.5 mm
 FOV: 24 cm

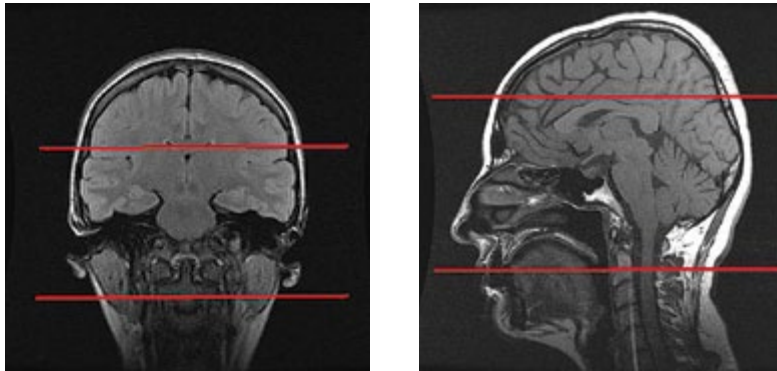
The coronal slices are plotted on sagittal images. The angle of inclination should be perpendicular to the frontobasal plane. The slices cover the entire skull, from nose to the chiasm region or farther, if necessary.

Mapping direction: antero-posterior
 Slice thickness: 3-4 mm
 Gap: 0.5 mm
 FOV: 24 cm
 (*Figures I.8.a, b*)

Magnetic resonance imaging of the inner ear

The most common indications:

- Schwann cell tumours
- acoustic neuroma
- meningioma
- vertigo
- middle ear granulation tissue
- cholesteatoma
- glomus jugulare tumours



Figures I.9.a, b Positioning of the axial slices in 3D Fiesta

Recommended sequences:

- FIESTA, CISS 3D – axial
- T1 – axial
- 3D TOF MRA
- 3D T1 + gadolinium

Imaging planes:

The axial slices cover the area extending from the skull base to the top of the mesencephalon. Plot to the sagittal images and on the coronal localizer images, set the imaging plane perpendicular to the centerline. The angle of inclination should be set to zero

Mapping direction: caudo-cranial

Slice thickness: 3 mm

Gap: 0 mm

FOV: 20-24 cm

Cranial nerves are well visualized on 3D FIESTA images. The study design is similar to that of the axial slices. The angle of inclination should be set to zero.

Slice thickness: less than 1 mm

FOV: 20-24 cm

(Figures I.9.a, b)

Magnetic resonance imaging of the hypophysis

Indication for pituitary MR

- Micro- and macro adenoma

- endocrine disorders
- Rathke's cleft cyst
- craniopharyngioma
- optic glioma

Recommended sequences:

- T1 – coronal
- T1 – sagittal
- 3D T1 dynamic + gadolinium
- After contrast administration, repeated T1 coronal and sagittal measurements

Additional sequences:

- T2 – coronal
- Pre-, and post contrast T1 – axial, if a lesion outside the hypophysis is visible; postcontrast 3D T1 as necessary.

Coronal slices are plotted on the sagittal and axial localizer images. The slices cover the entire sella turcica and are parallel to the infundibulum.

Mapping direction: antero-posterior

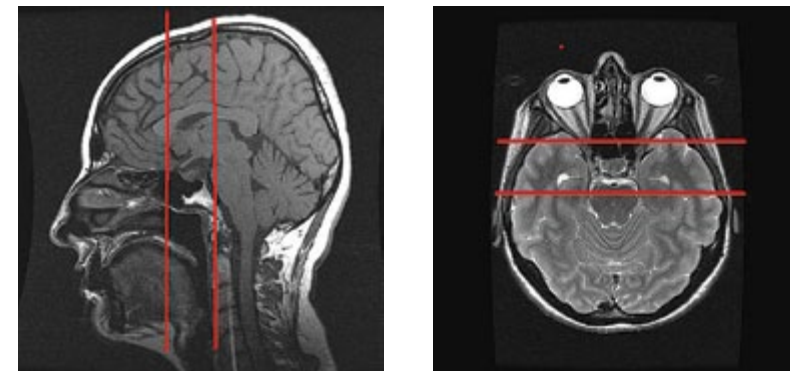
Slice thickness: 2 mm

Gap: 0 mm

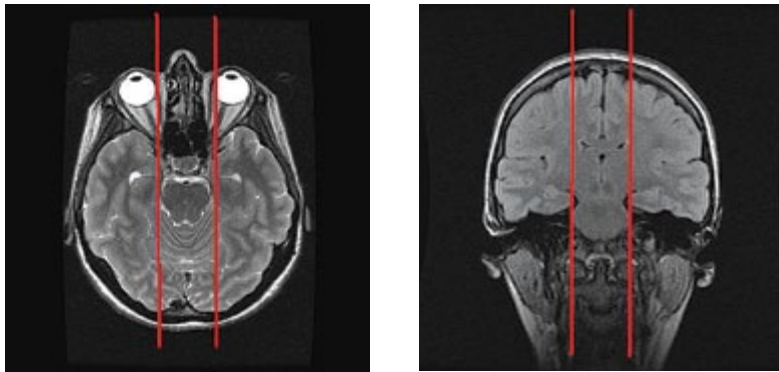
FOV: 22 cm

(Figures I.10.a, b)

Sagittal slices are plotted on the coronal and axial localizer images. The slices are parallel to the midline, and cover the entire sella turcica.



Figures I.10.a, b Positioning of coronal slices



Figures I.11.a, b Positioning of sagittal slices

Mapping direction: right-to-left
 Slice thickness: 2 mm
 Gap: 0 mm
 FOV: 22-24 cm
 (Figures I.11.a, b)

3D T1 measurements are obtained dynamically, in the coronal plane, and in several phases to capture pituitary perfusion. The imaging time is one and a half minutes, about 16-20 seconds per series.

Slice thickness: 1 mm
 Gap: 0 mm
 FOV: 20 cm

Magnetic resonance imaging of the orbita

Indications:

- neoplasms, space occupying lesions of the retrobulbar space
- endocrine-ophthalmopathy

Recommended sequences:

- T2 – axial
- T1 – axial
- T1 – coronal
- STIR – coronal

Additional sequences:

- T1 – sagittal
- T2 – relaxometry
- T1 FATSAT sequence after contrast administration, if necessary, in all three planes.

Imaging planes:

The preferred plane depends on the provisional diagnosis. In case of neoplastic lesions, the axial plane should be chosen, while in endocrine ophthalmopathy, the coronal plane is preferred.

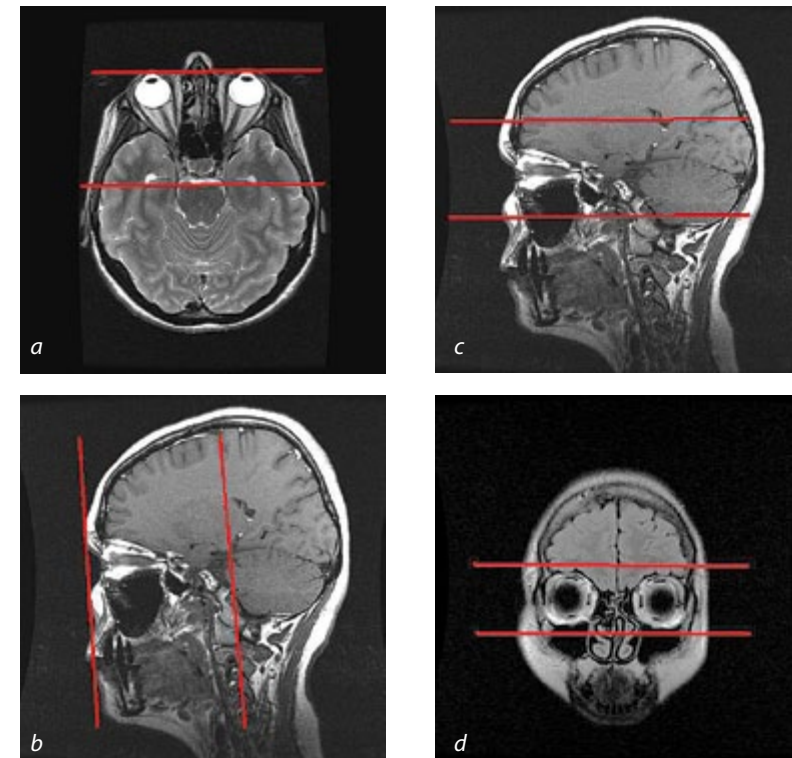
The coronal slices are plotted on the sagittal localizer images, and they cover the entire orbit and the chiasm region. The slices are perpendicular to the plane of the optic nerve.

Mapping: antero-posterior

Slice thickness: 3 mm

Gap: 0.5 mm

FOV: 20-24 cm



Figures I.12.a, b, c, d Positioning of coronal and axial slices

The axial slices are plotted on the sagittal-parasagittal localizer images. The axial slices extend from the lower to the upper edge of the bony orbital cavity, and they are parallel to the optic nerve.

Mapping direction: caudo-cranial

Slice thickness: 3 mm

Gap: 0 mm

FOV: 22-24 mm

Sagittal slices are plotted on the axial images. The slices are parallel to the plane of the optic nerve, and the area of interest covers the whole orbit.

Mapping direction: latero-medial

Slice thickness: 3 mm

Gap: 0 mm


FOV: 24 cm

(Figures I.12.a, b, c, d)

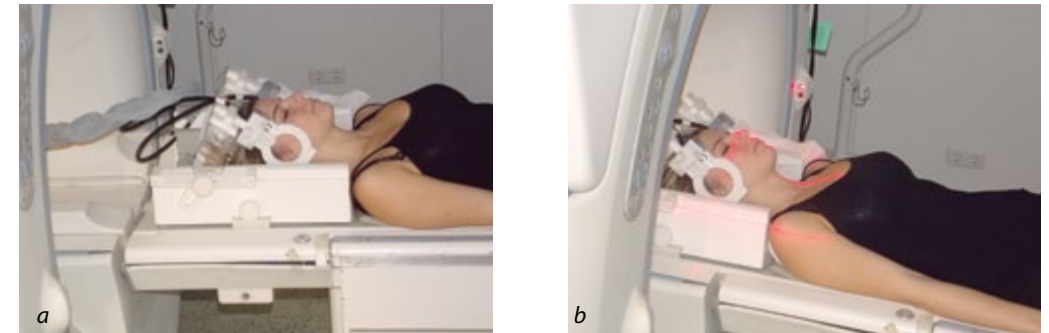
In patients with endocrine ophthalmopathy it is possible to quantitatively measure the water content of the rectus muscles with T2 relaxometry. When the multi-echo sequence is used, approximately 5-7 slices are placed on the "belly" of the rectus muscles in the coronal plane. In case of trauma, for the detection of soft-tissue injuries, an MRI should be performed. This must be preceded by a CT scan to rule out any intraocular metallic foreign body, because if present, the MRI scan must not be performed.

Magnetic resonance imaging of the temporomandibular joint

Better resolution can be achieved by using a dedicated TM coil. The two-part surface coil is placed on the patient's head, over the temporomandibular joint (TMJ) and fastened securely. (Figures I.13.a, b) (Figures I.14.a, b)



Figures I.13.a, b The temporomandibular coil



Figures I.14.a, b Positioning of TMJ examination

Video: Positioning for TMJ MRI scan

http://tamop.etk.pte.hu/tamop412A/Kepalkotasi_gyakorlatok_tananyag/MR/VIDEO_MR_GYAKTMJ_FINAL.wmv

Indications:

- meniscus, and bone degeneration
- trauma
- tumours

A comparison test is required. Both joints are examined both with the mouth open and closed. When examining with the mouth open, put a proper object in the patient's mouth; for example a sterile syringe, which he can bite on.

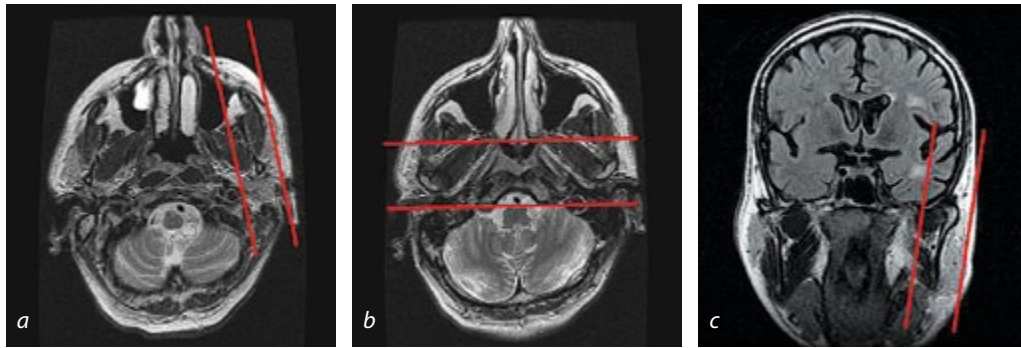
Recommended sequences:

- PD FATSAT – sagittal
- T2 GRE – sagittal
- T2 FATSAT – sagittal
- T1 – coronal
- If necessary, T1 FATSAT after gadolinium administration

Because this is a small anatomic region, we should choose a large submatrix, a small FOV and obtain thin slices. The sagittal slices are perpendicular to the mandibular condyle, and are parallel to the ramus of the mandible. The coronal slices are perpendicular to the sagittal plane, that is, parallel to the condyle, and perpendicular to the ramus.

Mapping direction:

- sagittal plane: latero-medial
- coronal plane: antero-posterior



Figures I.15.a, b Axial and sagittal slices of the TMJ

Slice thickness: 2 mm
 Gap: 0
 FOV: 8-10 cm
 (Figures I.15.a, b)

I.5. Magnetic resonance imaging of the Spine

Patient preparation

Explain the procedure to the patient, and, in particular, ask the patient to refrain from swallowing, and to keep movement to a minimum, so as to avoid artifacts.

Ask the patient to remove all metal containing objects, (dentures, hearing aids, hairpins, body jewelry, etc.) and all clothing that contains metal. If necessary, the patient should change to an MR gown. If the patient has surgical implants, it is the radiologist's duty to make a decision, based on the implant type and its MR compatibility.

Indications

- hernia
- degenerative disorders
- diseases of the bone marrow
- spinal cord involvement
- neoplastic diseases
- trauma
- post-surgery scars
- pre-operative planning
- paravertebral lesions

If needed, have an intravenous line inserted for contrast administration (for example when imaging tumors, spondylodiscitis, abscess, metastasis, inflammation, multiple sclerosis in the paravertebral space, or after surgery when scar tissue cannot be clearly separated from recurrent hernia).

Positioning

For better patient comfort and easier breathing, leg support pads should be placed under the patient's knees. Patient protection headsets and/or immobilization pads should be placed around the head to reduce noise and gross patient motion.

Depending on the type and manufacturer of your magnet, and the type of examination you are going to perform, patients can be positioned either head first or feet first.

The patient lies on his back, arms close to the body. The body axis is in the midline. The shoulders should touch the coil edge. The main advantage of positioning patients feet first is the diminution of claustrophobic feelings. We use a knee support for patient comfort in examinations of the cervical, thoracic and lumbar spine. This straightens out the lumbar lordosis which is favorable for the image quality as patients are less likely to move during the examination. In patients with kyphosis, the head may be higher than usual, in other words, further from the coil, consequently, we do not get sufficient image quality during the cervical spine examination. Therefore we may use a knee support under the patient's back. For a thoracic or a lumbar spine test, we can put a pillow under the head of the kyphotic patient. (Figure I.16.)

For the cervical spine test, centering should be done to the height of the easily palpable thyroid cartilage, which is at the level of the cervical IV.-V. vertebrae. (Figure I.17.)

For the thoracic spine test, centering should be done to the center of the sternum. (Figure I.18.)

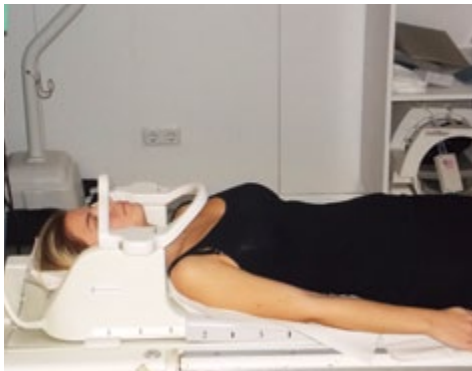

Figure I.16. Patient positioning on a spine coil.

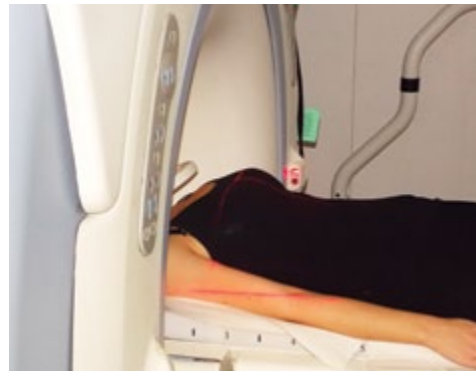

Figure I.18. Patient positioning for thoracic exam

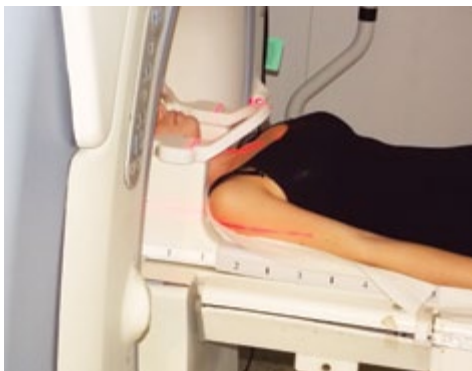

Figure I.17. Patient positioning for cervical exam

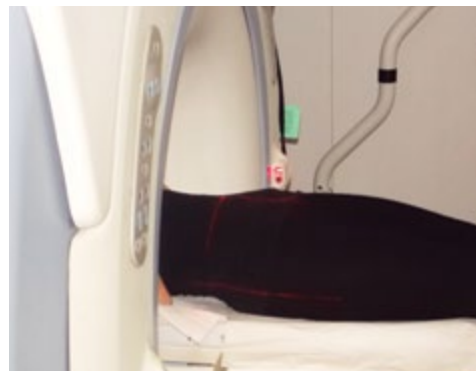
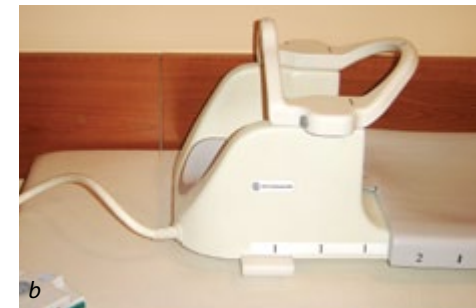
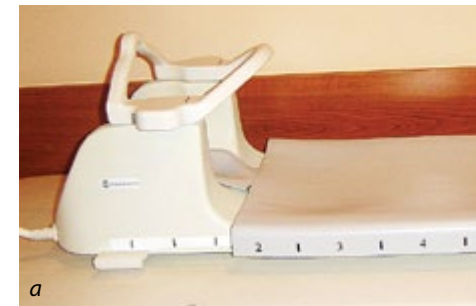Figure I.19. Patient positioning for lumbar exam



Figures I.20.a, b, c, d Spine coils

[Video: Positioning for C spine MRI scan](http://tamop.etk.pte.hu/tamop412A/Kepalkotasi_gyakorlatok_tananyag/MR/VIDEO_MR_GYAK/C_GERINC_FINAL.wmv)
http://tamop.etk.pte.hu/tamop412A/Kepalkotasi_gyakorlatok_tananyag/MR/VIDEO_MR_GYAK/C_GERINC_FINAL.wmv

For the lumbar spine test, centering should be done to the midpoint of the linea interspinalis, which is defined as the line connecting the two anterior superior iliac spines - It is incorrect to center to the umbilicus, because in obese patients, and after abdominal surgery, the location of this point may change. (Figure I.19.) (Figures I.20.a, b, c, d)

Protocols:

Depending on the indication, the implementation of the study may differ.

Recommended sequences:

- T2 – sagittal
- T1 – sagittal
- STIR – sagittal
- T2 – axial

Additional sequences:

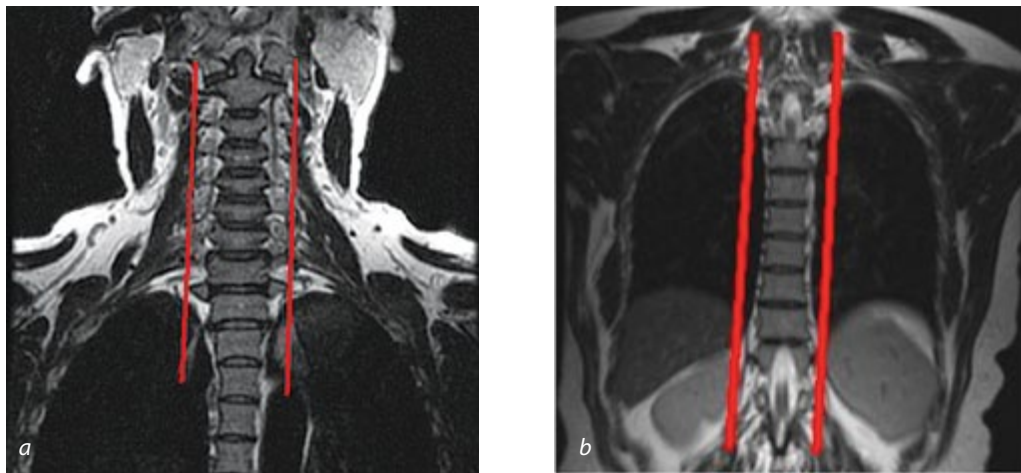
- T1 – axial
- T2 – coronal
- Sagittal and axial T1 after intravenous gadolinium administration, and if necessary with FATSAT and in the coronal plane as well.
- 3D T2 – coronal (if the patient has severe scoliosis)
- DWI
- FLAIR
- T2 GRE (for haemorrhages, and vascular malformations)

Imaging planes

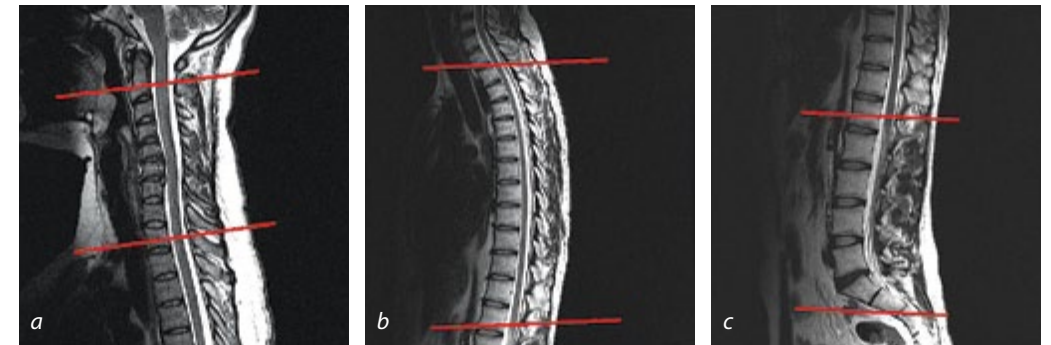
For each spinal segment, the test methodology is similar, but depending on the length of the examined area, the height of the vertebral bodies and intervertebral discs, each section is examined with a different slice thickness and FOV. After patient positioning, axial, sagittal and coronal localizer images are obtained.

Plan sagittal slices on the coronal localizer images, where you can see the spinal cord covering the whole spinal canal. The slices cover the bony spine between the transverse processes. On the axial slices, we can make adjustments so that the plane is not skewed. The FOV of sagittal slices depend on the patient's height. When imaging smaller patients, we apply a smaller FOV for better resolution. (Figures I.21.a, b, c)

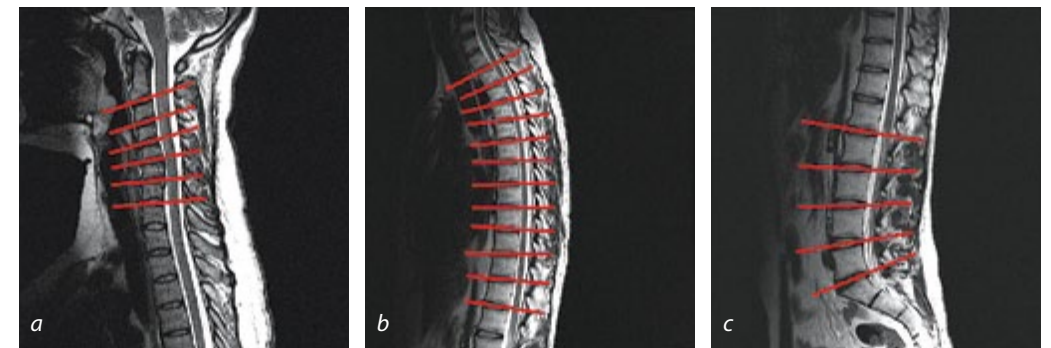
Axial slices are plotted on the sagittal localizing images. When imaging patients with disc hernia, set the angle of inclination parallel to the discs. 3 to 5 slices are enough to cover a disc, but if there is disc fragmentation or sequestration the slices must completely cover the whole lesion. If there is a larger spinal lesion, or if the lesion involves several vertebrae, the axial slices should not be angled parallel to the discs, but instead, we examine the pathologic area as a slab without tilting. On the coronal localizing images, adjust the angle of the slices parallel to the intervertebral discs; this is important when imaging patients with scoliosis. (Figures I.22.a, b, c) (Figures I.23.a, b, c)



Figures I.21.a, b, c Positioning the sagittal slices of the cervical, thoracic and lumbar examinations

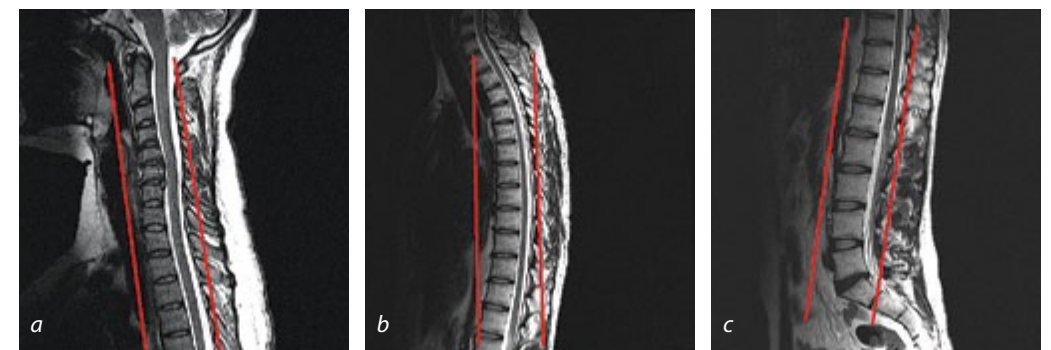


Figures I.22.a, b, c Planning of axial slices as a slab on the sagittal cervical, thoracic and lumbar spine scans.



Figures I.23.a, b, c Planning of axial slices parallel to each disc on the sagittal cervical, thoracic and lumbar spine scans.

Coronal slices are plotted on the sagittal localizing images. The slices include the bony spinal vertebrae, from the ventral edge to the processus spinosi. On the axial and coronal slices the FOV is adjusted to the center of the vertebral bodies, parallel to the long axis of the spine. (Figures I.24.a, b, c, d)



Figures I.24.a, b, c Planning coronal slices to the cervical, thoracic and lumbar spine sagittal images

Imaging parameters of the cervical spine

On sagittal images we can count the vertebrae easily. The spine should be visible from the tentorium to the thoracic II-III. vertebrae.

Mapping direction: right-to-left
 Slice thickness: 3 mm
 Gap: 1 mm
 FOV: 22-26 cm

The axial slices are fitted onto each cervical intervertebral discs, and the number of slices is determined by the magnitude of the potential disorders.

Mapping direction: cranio-caudal
 Slice thickness: 3 mm
 Gap: 1 mm
 FOV: 22 cm

The angle of the coronal slices is set parallel to the myelon.

Mapping direction: antero-posterior
 Slice thickness: 3-4 mm
 Gap: 12 mm
 FOV: 22-26 cm

Imaging parameters of the thoracic spine

Examination of the thoracic spine begins with a so-called "counting" sagittal series.

This is a T2 weighted sequence with a large FOV. It takes approximately one minute, and it consists of 5-7 slices. It covers the entire cervical and thoracic spine, which is helpful when counting off thoracic vertebrae. (Figure I.25.)

On sagittal images, the thoracic spine should be visible from the C. VI-VII. vertebra to L I..

Mapping direction: right-to-left
 Slice thickness: 3-4 mm
 Gap: 1 mm
 FOV: 30-38 cm – depending on the patient's height

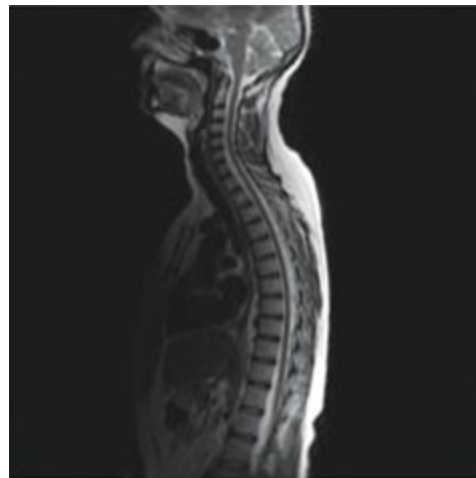


Figure I.25. The "counting" sagittal series

The axial slices are fitted onto each thoracic intervertebral discs, and the number of slices is determined by the magnitude of the potential disorders.

Mapping direction: cranio-caudal
 Slice thickness: 3-3.5 mm
 Gap: 1 mm
 FOV: 20 cm

The coronal slices can not be set parallel to the myelon due to thoracic kyphosis. That is why tilting is done parallel to the area where the most pronounced changes are (hernia, tumour).

Mapping direction: antero-posterior
 Slice thickness: 4-5 mm
 Gap: 1 mm
 FOV: 36-38 cm

Imaging parameters of the lumbar spine

The sagittal lumbar slices extend from the Th X. vertebra to the sacrum (S IV-V).

Mapping direction: right-to-left
 Slice thickness: 4 mm
 Gap: 1 mm
 FOV: 28-36 cm – depending on the patient's height

The axial slices are fitted onto each lumbar intervertebral discs parallel to the angle of the discs, and the number of slices is determined by the magnitude of the potential disorders.

Mapping direction: cranio-caudal
 Slice thickness: 4 mm
 Gap: 1 mm
 FOV: 20 cm

The coronal slices are parallel to the spinal canal; plotting is done on the sagittal slices.

Mapping direction: antero-posterior
 Slice thickness: 4-5 mm
 Gap: 1 mm
 FOV: 28-36 cm, depending on the patient's height

I.6. MRI of the upper extremities

Magnetic resonance imaging of the shoulder

Patient preparation

First, always make sure that there are no contraindications to the examination. Ask the patient to remove all metal containing objects (hearing aids, hairpins, body jewelry, necklace, clothing, etc.).

Indications

- injuries of the rotator cuff muscles and tendons
- cartilage injuries
- osteoarthritis
- bone edema, bone necrosis
- tumour

The shoulder coil is placed on the shoulder to be imaged, and it is fixed with additional straps. The patient lies supine, and the shoulder coil is placed if there is a coil holder or positioning pad on the table. Additional pads should be placed under the patient's arm to make the humerus almost parallel to the table. The palm of the hand should be pointing upward (supine) as well, for best patient position (anatomical position or external rotation). To reduce gross patient motion artifacts, an additional strap should be placed over the patient at the elbow level or a bit more inferior. (Figure I.26.) (Figure I.27.)

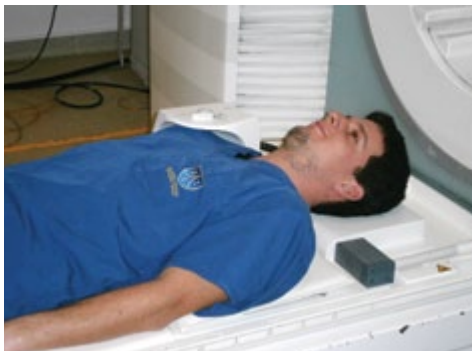

Figure I.26. Sample patient positioning for a dedicated phase array shoulder coil.

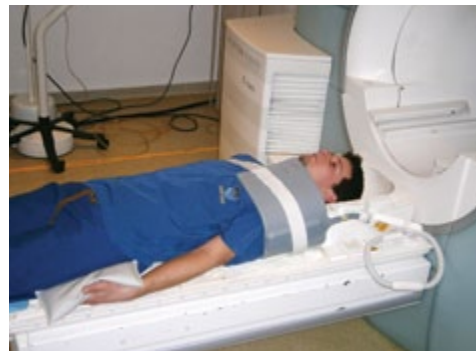

Figure I.27. Sample patient positioning for a flex coil



Figure I.28. Dedicated phase array shoulder coils



Figure I.29. Flex coils

For shoulder imaging, dedicated multi channel phased array coils are preferred. However, general purpose flexible coils or other available surface coils can be used if your site does not have a dedicated shoulder coil or if it cannot be used for any reason (for example, because of the patient's body size). The disadvantage of the flex coil is that motion artifacts will be more pronounced due to lower signal-to-noise ratio, and thoracic breathing movements. For both cases centering is done to the mark - center of the coil -, which coincides with the humeral head. (Figure I.28.) (Figure I.29.)

Video: Positioning for shoulder MRI scan

http://tamop.etk.pt.hu/tamop412A/Kepalkotasi_gyakorlatok_tananyag/MR/VIDEO_MR_GYAK/VALL_FINAL.wmv

Recommended sequences:

- PD FS TSE – axial
- PD FS TSE – paracoronal
- PD FS TSE – parasagittal
- T1 SE – paracoronal
- T1 SE – axial

Additional sequences:

- Contrast enhanced (CE) T1 FS – axial
- Contrast enhanced T1 FS – parasagittal
- Contrast enhanced T1 FS – paracoronal

Imaging parameters:

- Slice thickness: 3-3.5 mm
- Gap: 0.5 mm
- FOV: 20-22 cm

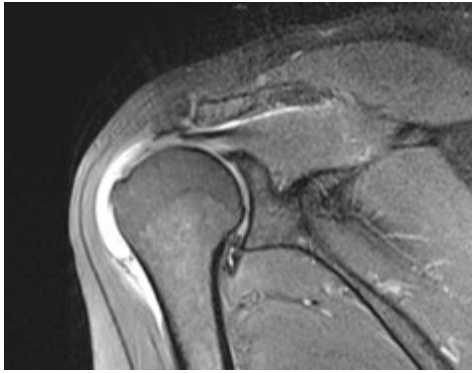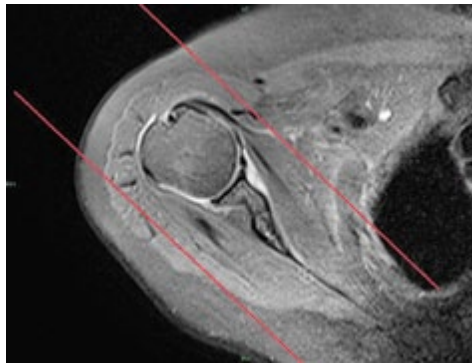


Figure I.30. Paracoronal plane

Imaging planes

For the shoulder joint, the most important planes are paracoronal planes (oblique coronal) and parasagittal, because on these images, the rotator cuff muscles (infraspinatus muscle, supraspinatus muscle, subscapularis muscle, and teres minor) can be perfectly adjudged.

Paracoronal slices are plotted on the axial images, parallel to the supraspinatus muscle tendon and perpendicular to the cavitas gle-



Figures I.31. Positioning of paracoronal slices

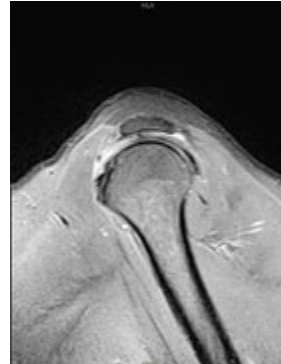
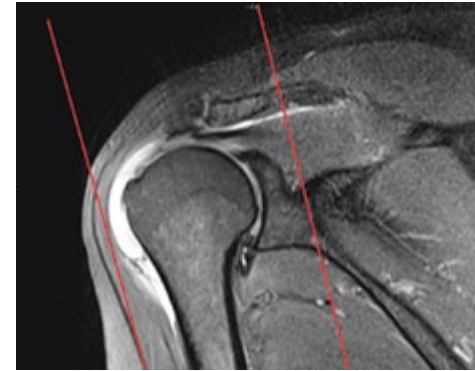

Figure I.33. Parasagittal plane



Figures I.35. Positioning of parasagittal slices

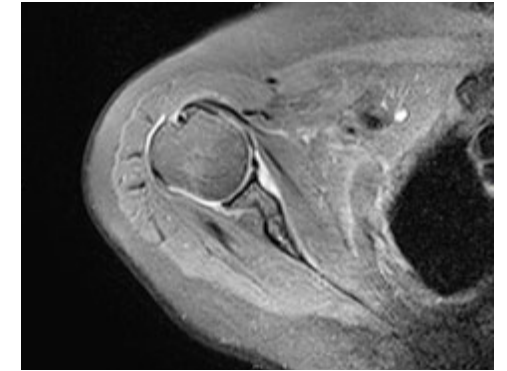
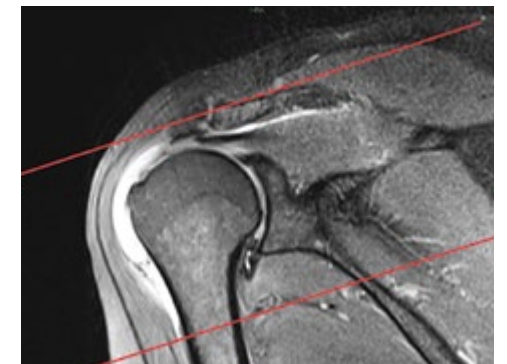

Figure I.36. Axial plane

noidalis, and on sagittal images it is parallel to the humerus. (Figure I.30.) (Figures I.31., I.32.)

The parasagittal slices are perpendicular to the paracoronal slices. (Figure I.33.) (Figures I.34., I.35.)

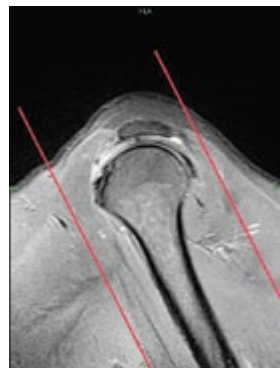The axial slices are perpendicular to the plane of the humerus. Tendon injuries are well visualized on these images. (Figure I.36.) (Figures I.237., I.38.)



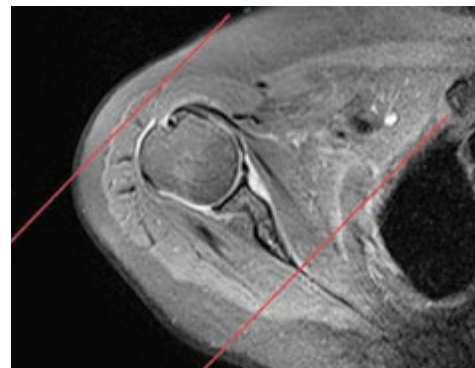
Figures I.37. Positioning of the axial slices

Sequences

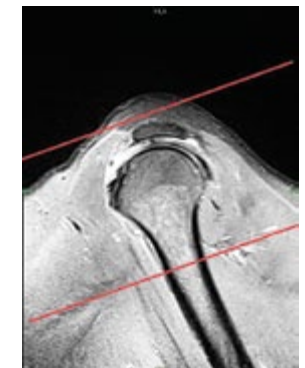It can be said that the most useful sequence is the proton density measurement with fat saturation (PD FS), therefore this should be carried out in all three directions. On these series, strains and tears of muscles and tendons, surrounding edema and fluid are well visualised. Moreover, injuries of the articular cartilage and the labrum may be clearly appreciated, as well. (If necessary, the fat saturated PD sequence can be replaced by a STIR measurement.) A FS PD measurement always needs to be supplemented by some other (T1 or T2) measurement.



Figures I.32. Positioning of paracoronal slices



Figures I.34. Positioning of parasagittal slices



Figures I.38. Positioning of the axial slices

If administration of contrast material is necessary we have to perform T1-weighted measurements that best suit the pathology, before the injection. After the injection of contrast material, fat saturated T1 measurements have to be made.

Magnetic resonance imaging of the elbow

Patient preparation

First, always make sure that there are no contraindications to the examination. Ask the patient to remove all metal containing objects (hearing aids, hairpins, body jewelry, necklace, clothing, etc.).

Indications

- trauma (bone-, ligament-, cartilage injuries)
- inflammation
- degeneration
- bone edema, bone necrosis
- tumour

Elbow imaging can be done with several different coils. If you have a general flexible coil available, you can position the patient supine, feet/head first and let the arms lie at the side with the palms pointing upwards. Then you can wrap the coil around the elbow. This is the most comfortable position

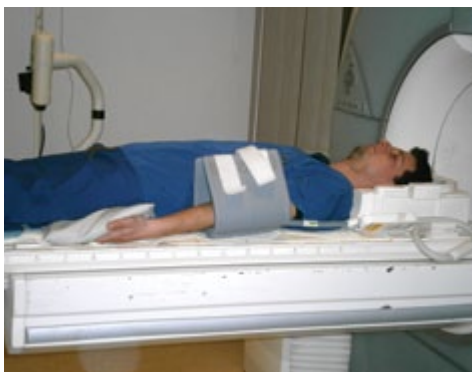

Figure I.39. Patient positioning for elbow in a general purpose flexible coil (supine)

for the patient. Try to position the patient so that the affected side elbow is as close as possible to the magnetic axis. To avoid motion artifacts, use pads and put it around the patient's arm. However, if you do not have any working flexible coils, you can use one of the smaller diameter coils such as knee, foot, or loop coils to scan the patient head first in a prone position. This is also called the superman position.

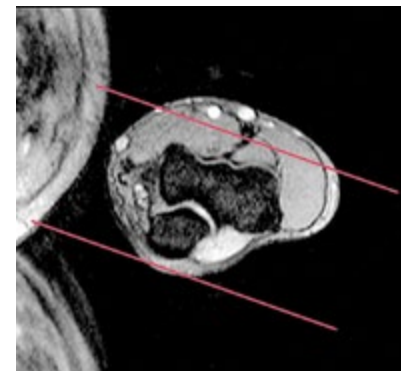
The signal-to-noise ratio of the flex coil is the worse. For each coil, the elbow joint must be located in the middle of the coil, and centering should be done to the mark on the coil. (Figure I.39.)

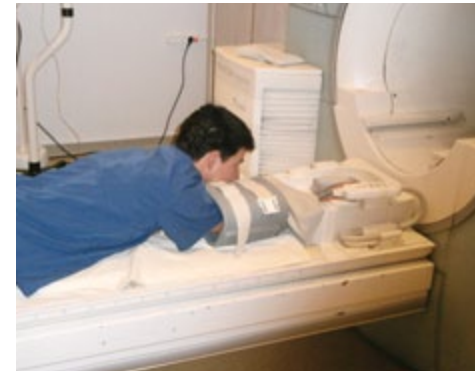

Figure I.40. Patient positioning for elbow in a general purpose flexible coil (prone)

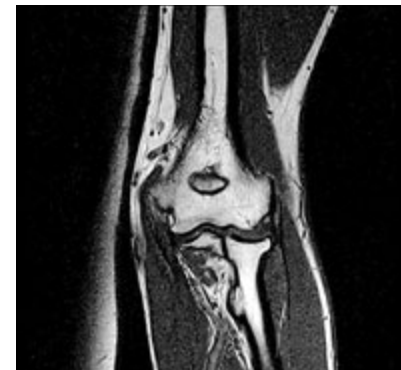

Figure I.41. Coronal plane



Figures I.42. Positioning of the coronal slices

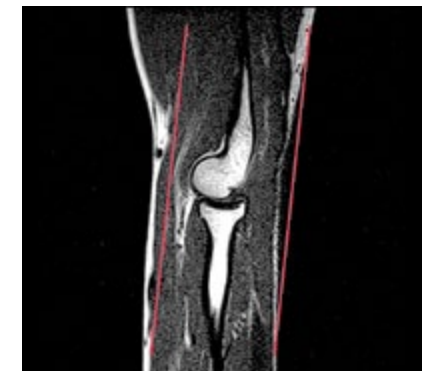However, this is not feasible for obese patients, because their elbows get out of the iso-center easily, therefore we get low-quality images. In this case you can try to scan head first in a prone position, and have the patient put his outstretched arms next to his head with the hands in a supine position. (Figure I.40.)

In both cases, you should choose the direction of the phase and frequency encoding, and saturation cautiously, because the body or head may easily cause aliasing artifacts.

Imaging planes

Plot the coronal slices on the axial plane parallel to the humeral epicondyles (more specifically to the humeroulnar joint) and on the sagittal localizer plot them parallel to the axis of the arm. (Figure I.41.) (Figures I.42., I.43.)

Plot the the sagittal slices on the coronal images parallel to the longitudinal axis of the upper arm and forearm, and on the axial images plot them perpendicular to the humeral epicondyles (humeroulnar joint). (Figure I.44.) (Figures I.45., I.46.)



Figures I.43. Positioning of the coronal slices

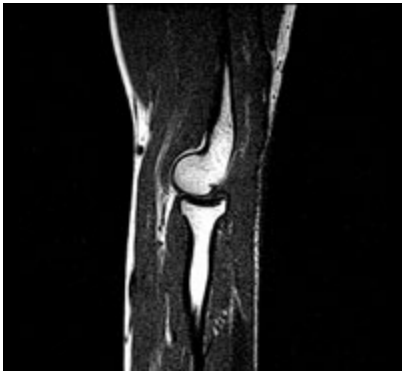

Figure I.44. Sagittal plane

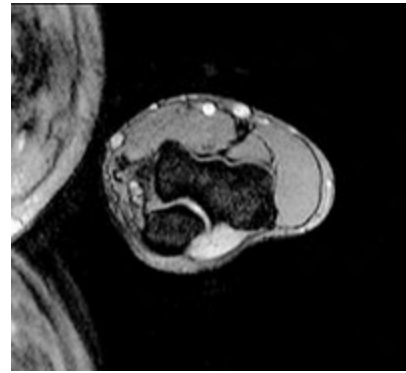
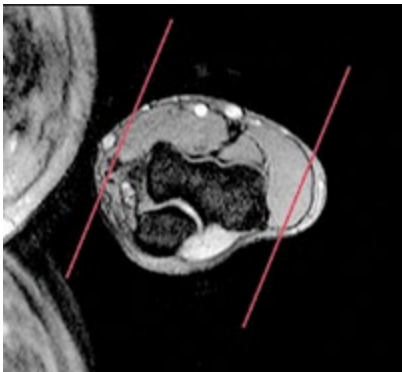
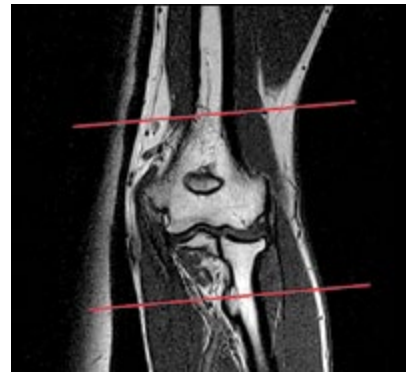

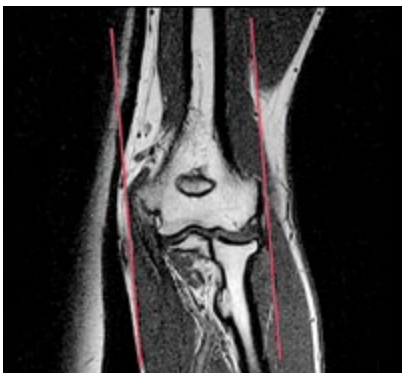Figure I.47. Axial plane



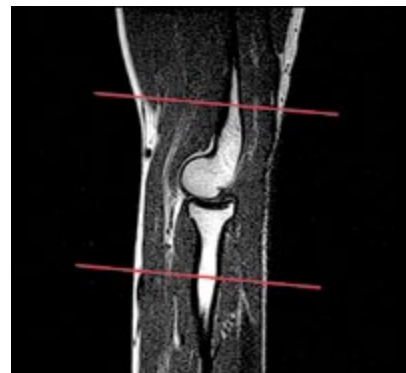Figures I.45. Positioning of the sagittal slices



Figures I.48. Positioning of the axial slices



Figures I.46. Positioning of the sagittal slices



Figures I.49. Positioning of the axial slices

The axial plane is parallel to the straight line connecting the humeral epicondyles. (Figure I.47.) (Figures I.48., I.149.)

Sequences

The inflammation and bone edema appears bright on STIR sequences. The assessment of the cartilaginous surface is best achieved with PD FS measurements. Ligaments should be judged by T1-weighted measurements, while liquid is best appreciated on T2-weighted, STIR and PD FS images.

Magnetic resonance imaging of the wrist and hand

Patient preparation

First, always make sure that there are no contraindications to the examination. Ask the patient to remove all metal containing objects (hearing aids, hairpins, body jewelry, necklace, clothing, etc.).

Indications

- Carpal tunnel syndrome
- trauma (bone, ligament, cartilage injuries)
- inflammation
- degeneration
- bone edema, necrosis
- tumour

Similar to elbow imaging, wrist imaging can be done with several different coils. If you have a dedicated multi channel wrist coil, you can position the patient feet first in a supine position, and the arms can lie next to the body. Then you can place the wrist to be imaged in the center of the coil. This is the most comfortable position for the patient. Try to position the patient so that the affected side wrist is as close as possible to the magnetic axis. However, if you do not have any dedicated coils, you can use one of the smaller diameter coils such as knee or loop coils to scan the patient head first in a prone position. To avoid motion artifacts, use pads and put on the patient's arm.

If the patient's fingers are the indication of the examination, she must stretch them out, and the radiographer should place a sandbag on them (it is preferred when making coronal images). (Figure I.50.)

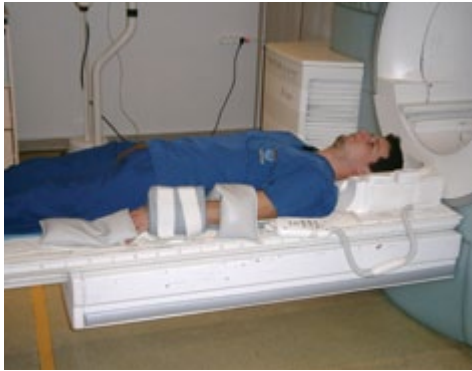

Figure 1.50. Patient positioning for wrist examination in a general purpose flexible coil (supine)

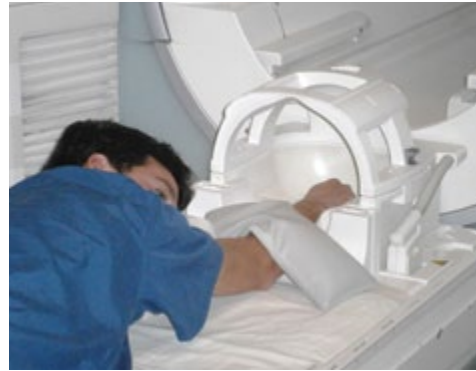

Figure 1.51. Patient positioning for wrist examination in a head coil (prone)

If you use the head coil, the patient is positioned prone, and the wrist is placed in the middle of the coil. (Figure 1.51.)

For each coil, the examined hand or wrist is located in the middle of the coil, and centering is to the coil's mark.

Video: Positioning for wrist MRI scan

http://tamop.etk.pt.e.hu/tamop412A/Kepalkotasi_gyakorlatok_tananyag/MR/VIDEO_MR_GYAK/CSUKLO_FINAL.wmv

Imaging planes

The most important planes are the coronal and axial planes.

Plot the coronal slices on the axial images parallel to the carpal (Guyon's) canal (or perpendicular to the radioulnar joint), and on the sagittal localizer plot them parallel to the forearm or mid carpal bones. (Figure 1.52.) (Figures 1.53., 1.54.)

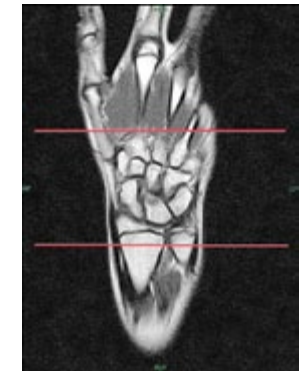
The axial plane is perpendicular to the radius and the ulna. (Figure 1.55.) (Figures 1.56., 1.57.)

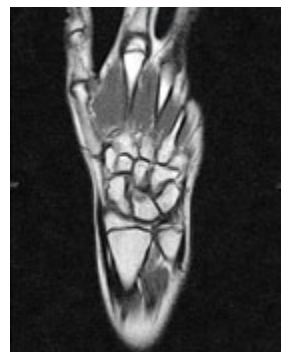
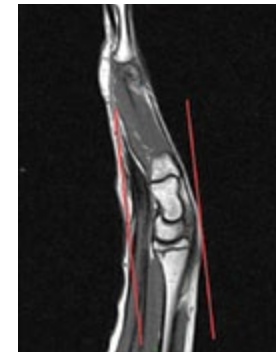

Figure 1.52. Coronal plane



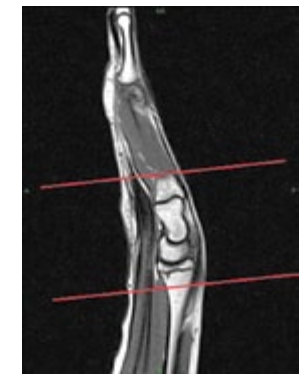Figures 1.53. Positioning of the coronal slices



Figures 1.56. Positioning of the axial slices



Figures 1.54. Positioning of the coronal slices



Figures 1.57. Positioning of the axial slices

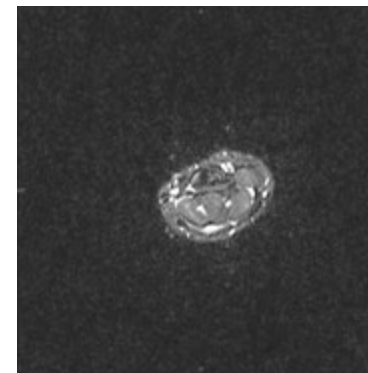


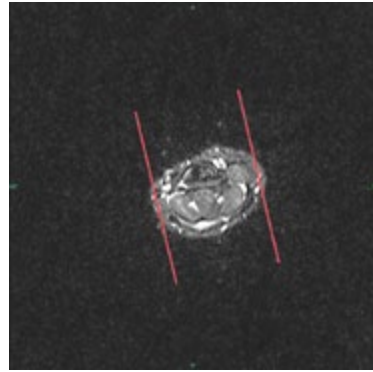
Figure 1.55. Axial plane

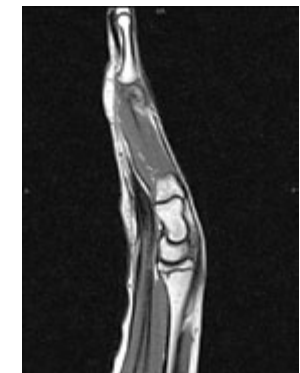
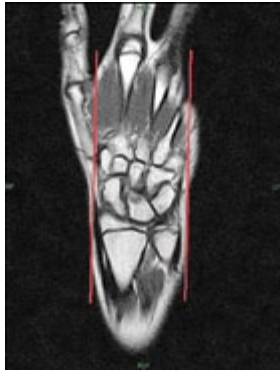
Figure 1.58. Sagittal plane



Figures 1.59.. Positioning of the sagittal slices



Figures 1.59, 1.60. Positioning of the sagittal slices

The sagittal plane is used as a supplement, and it is parallel to the radioulnar joint on the axial images, and it is parallel to the forearm or mid carpal bones on the coronal images. (Figure 1.58.) (Figures 1.59, 1.60.)

1.7. MRI of the lower extremities

Magnetic resonance imaging of the hip

Patient preparation

First, always make sure that there are no contraindications to the examination. Ask the patient to remove everything containing metal (hearing aids, hairpins, body jewelry, necklace, clothing – bra, etc.).

Indications

- femoral head avascular necrosis
- osteoarthritis
- soft tissue injuries
- cartilage injuries
- bone oedema
- tumour

The patient lies down head first, in a supine position. Have the patient cross the arms over the upper abdomen. (Figure 1.61.)

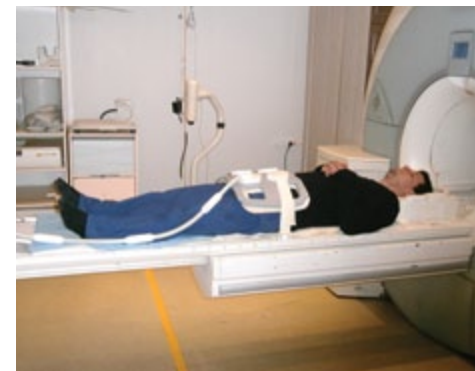


Figure 1.61. Positioning the phased array coil



Figure 1.62. Phased array body coil

The body phased array coil is used for hip imaging, because with this coil both hip joints can be examined simultaneously. Because of its excellent signal-to-noise ratio, imaging can be carried out with high-resolution. Place the coil directly on the patient parallel to the plane of the femoral head, and center on the mark of the coil. (Figure I.62.)

Recommended sequences:

- T1 TSE – coronal
- STIR – coronal
- PD FS – axial
- T2 TSE – sagittal

Additional sequences:

- Contrast enhanced T1 FS – axial
- Contrast enhanced T1 FS – sagittal
- Contrast enhanced T1 FS – coronal

Imaging parameters:

- Slice thickness: 4 mm
- Gap: 0.5 mm
- FOV: 38 cm

Imaging planes

In the coronal and axial planes both femoral heads are imaged, thus we can compare them. Sagittal slices are only acquired of the affected side, or we can image both, but separately.

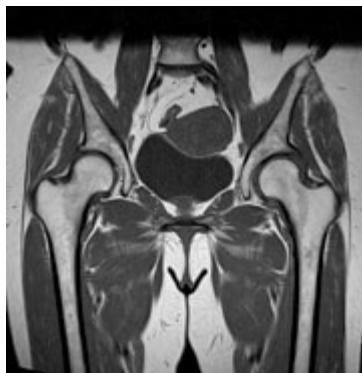


Figure I.63. Coronal plane

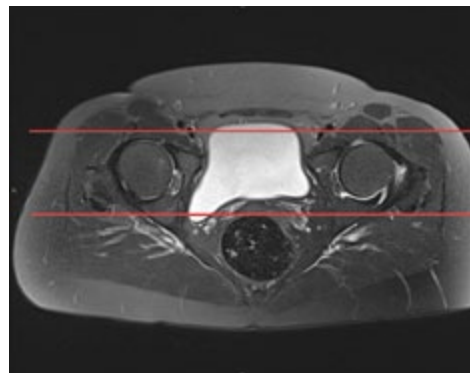


Figure I.64. Positioning of the coronal slices

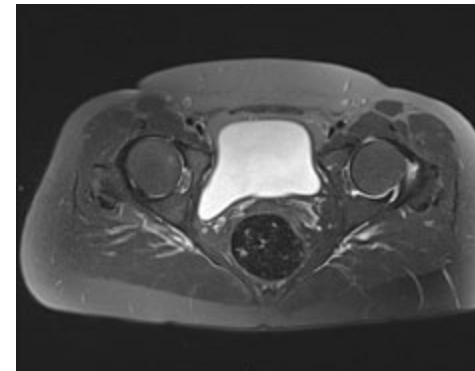


Figure I.65. Axial plane

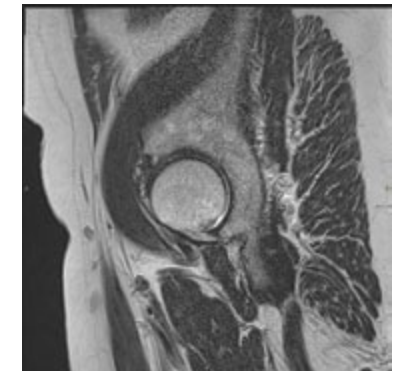


Figure I.67. Sagittal plane

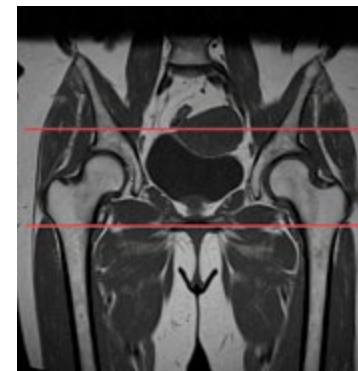
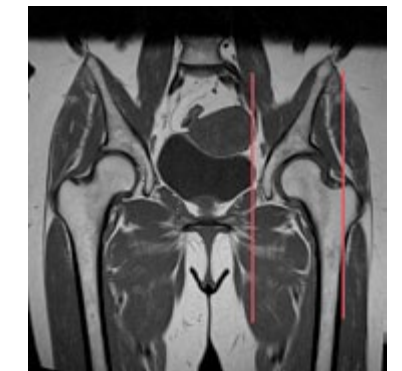

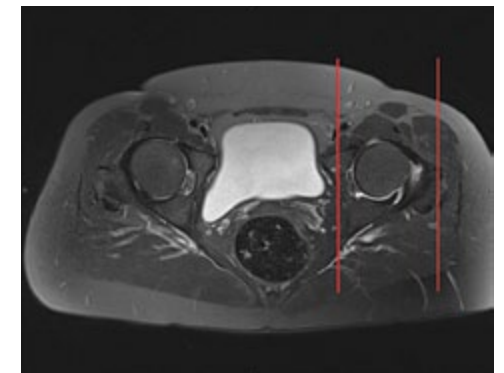
Figure I.66. Positioning of the axial slices



Figures I.68. Positioning of the sagittal slices

The most important plane is the coronal plane which is parallel to the line connecting the femoral heads, and it fully covers both joints. (Figure I.63.) (Figure I.64.)

The axial plane is perpendicular to the longitudinal axis of the body (parallel to the line connecting the hip joints); the upper border is above the hip joint and the lower border is the trochanter minor. (Figure I.65.) (Figure I.66.)



Figures I.69. Positioning of the sagittal slices

Plan the sagittal slices on the coronal plane parallel to the longitudinal axis of the body, while on the axial image, plan them parallel to the edge of the acetabulum and the labrum. (Figure I.67.) (Figures I.68., I.69.)

Sequences

For the assessment of cartilage, T1-weighted images are suitable. For bone edema, necrosis or fluid in the joint, STIR and PD FS sequences are the best.

Magnetic resonance imaging of the knee

Patient preparation

Always make sure that there are no contraindications to the examination. Ask the patient to remove everything containing metal (hearing aids, hairpins, body jewelry, necklace, clothing, etc.).

Indications

- trauma (bone, ligament, cartilage injuries)
- inflammation
- degeneration
- bone edema, bone necrosis
- tumour

The knee joints are usually imaged unilaterally using dedicated coils. The knee and foot coils are usually what we call transmit/receive coils rather than receive only coils. The utilization of dedicated multi channel knee coils can make significant improvements in MR image SNR, and they can be used to either shorten the scan time or increase spatial resolution. If you do not have a dedicated knee coil, it is possible to use other available coils. (Figure I.70.)

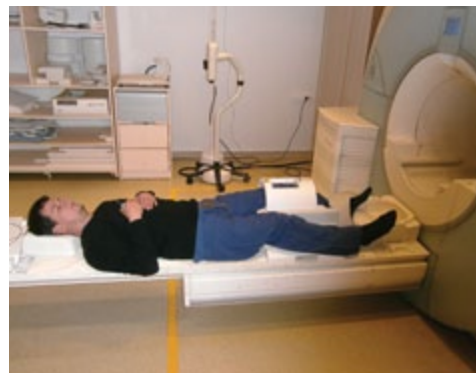


Figure I.70. Positioning in a knee coil

The patient lies down, feet first in a supine position. Place the knee coil right at the center of the MR table. When you place the patient's knee in the coil, insert a small pad under the knee joint to slightly bend the knee (about 15°). The patella should be aligned with the center of the coil for good positioning. When the coil top is attached, place additional pads between the knee and coil to further immobilize the knee. These pads can significantly reduce motion artifacts. The other knee should be placed as far away from the coil as possible to prevent any wrapping or aliasing, especially with the receive-only coil. (Figure I.71.)



Figure I.71. Knee coil

Video: Positioning for knee MRI scan

http://tamop.etk.pte.hu/tamop412A/Kepalkotasi_gyakorlatok_tananyag/MR/VIDEO_MR_GYAK/TERD_FINAL.wmv

Recommended sequences:

- T1 SE – sagittal
- PD FS TSE – sagittal
- PD FS TSE – coronal
- PD FS – axial

Additional sequences:

- T2 TSE – sagittal angled at the ACL (anterior cruciate ligament)
- Contrast enhanced T1 FS – axial
- Contrast enhanced T1 FS – sagittal
- Contrast enhanced T1 FS – coronal

Imaging parameters:

- Slice thickness: 3-4 mm
- Gap: 0.5 mm
- FOV: 22 cm

Imaging planes

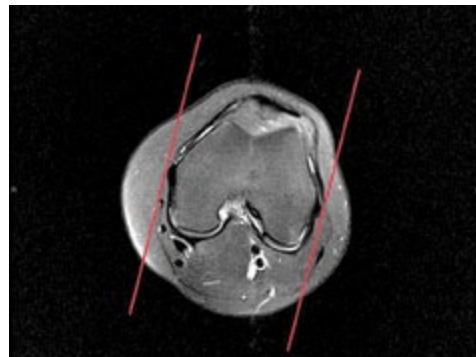
For the knee joint the most useful plane is the sagittal, which is perpendicular to the posterior horns of the femoral condyles. The boundaries are the lateral and medial femoral condyles. On the sagittal plane knee cartilage (articular cartilage surfaces, meniscus, patellar cartilage) is well visualized, just as the bones that form the knee joint and the posterior cruciate ligament. (Figure I.72.) (Figures I.73, I.174.)

The plane of the anterior cruciate ligament does not coincide with the sagittal plane just described, so it must be examined separately, if necessary. In order to fully visualise the ACL, an oblique sagittal plane has to be established.

The coronal plane is perpendicular to the sagittal plane, therefore it is parallel to the posterior horns of the femoral condyles. The boundaries are the anterior surface of the patella, and the posterior horns of the femoral condyle. (Figure I.75.) (Figures I.76, I.177.)

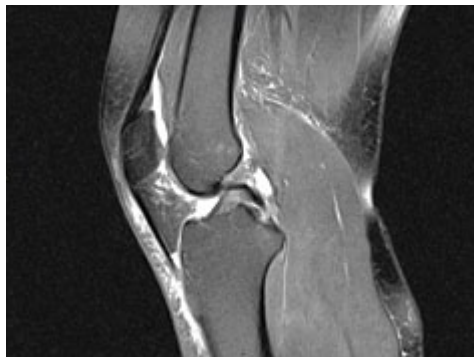

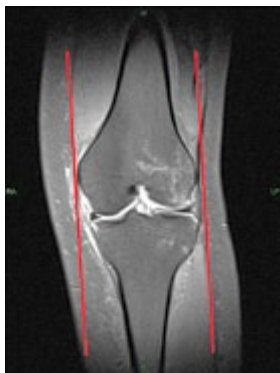Figure I.72. Sagittal plane



Figures I.74. Positioning of the sagittal slices



Figures I.73. Positioning of the sagittal slices

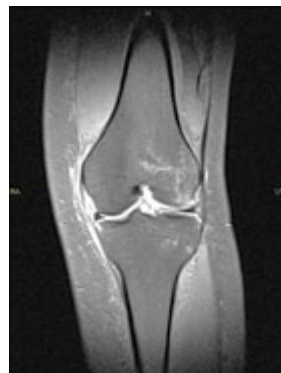
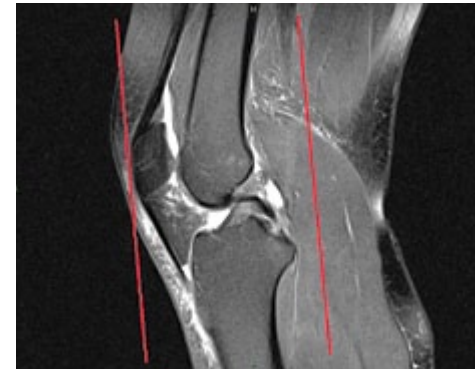

Figure I.75. Coronal plane



Figures I.76. Positioning of the coronal slices

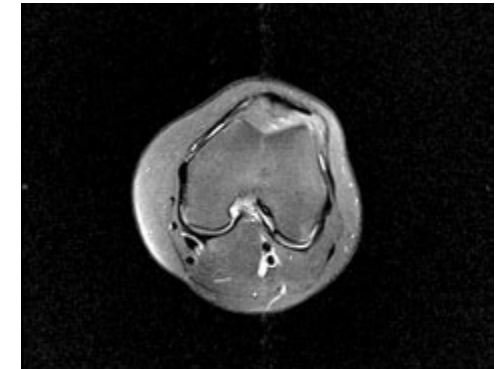
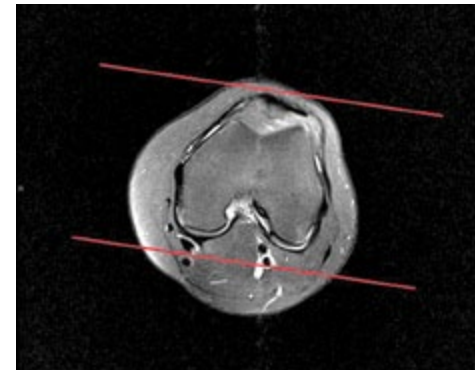
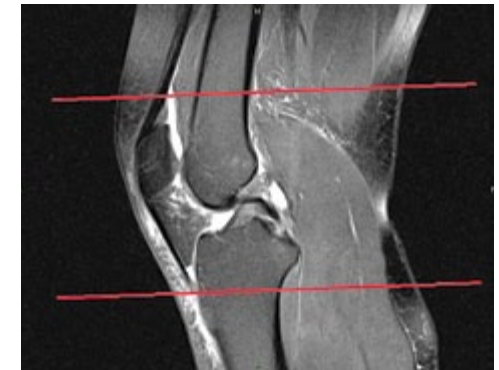

Figure I.78. Axial plane



Figures I.77. Positioning of the coronal slices

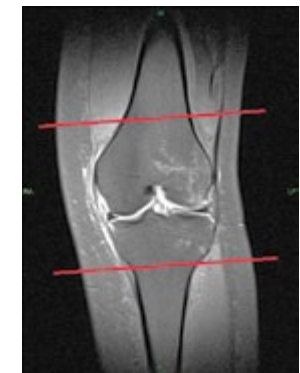

Figures I.79. Positioning of the axial slices

The axial plane is good for the representation and assessment of the patella and the femoro-patellar joint. The sagittal and coronal images are parallel to the joint gap, and the boundaries are the proximal end of the fibula and the top of the patella. (Figure I.78.) (Figures I.79, I.180.)

Sequences

T1 and T2 weighted images are both appropriate for the assessment of cartilaginous articular surface, the ligaments, and tendons.



Figures I.80. Positioning of the axial slices

Meniscus rupture can be seen on the T1-weighted images, when the low signal intensity meniscus is cut in half by a high signal intensity straight line or "C" form band. Synovial fluid and Baker's cyst are most striking on the T2-weighted and proton density measurements.

Magnetic resonance imaging of the ankle

Patient preparation

Always make sure that there are no contraindications to the examination. Ask the patient to remove everything containing metal (hearing aids, hairpins, body jewelry, necklace, clothing, etc.).

Indications

- trauma (bone, ligament, cartilage injuries)
- inflammation
- degeneration
- bone edema, bone necrosis
- tumour

The ankle is usually imaged unilaterally using dedicated coils. The ankle coils can be either transmit/receive or receive-only coils. The utilization of dedicated multi channel ankle/foot coils can make significant improvements in the SNR. If you do not have a dedicated coil, it is possible to use other available coils eg.: flex coil, head coil, knee coil. However, the image parameters should be modified to compensate for the SNR loss. (Figure I.81.)

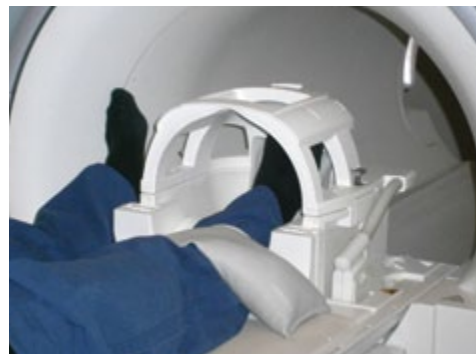

Figure I.81. Positioning in a head coil

The patient lies down feet first in a supine position. Place the ankle coil right at the center of the MR table. When you place the patient's ankle in the coil, you can use patient support pads to immobilize the foot and keep it straight during the scan. The ankle-specific pads can significantly reduce motion artifacts. The other foot should be placed as further away from the coil as possible to prevent any wrapping or aliasing, especially with receive-only coils.

[Video: Positioning for ankle MRI scan](http://tamop.etk.pte.hu/tamop412A/Kepalkotasi_gyakorlatok_tananyag/MR/VIDEO_MR_GYAK/BOKA_FINAL.wmv)

http://tamop.etk.pte.hu/tamop412A/Kepalkotasi_gyakorlatok_tananyag/MR/VIDEO_MR_GYAK/BOKA_FINAL.wmv

Recommended sequences:

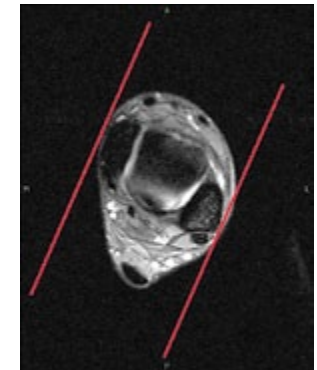
- T1 SE – sagittal
- PD TSE FS – sagittal
- PD TSE FS – coronal
- T2 GRE – axial

Additional sequences:

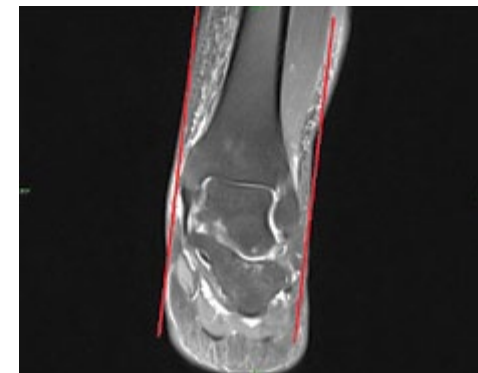
- STIR
- Contrast enhanced T1 FS – axial

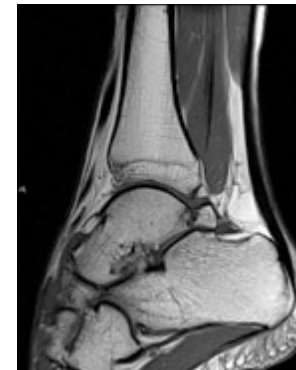

Figure I.82. Sagittal plane



Figures I.84. Positioning of the sagittal plane



Figures I.83. Positioning of the sagittal plane

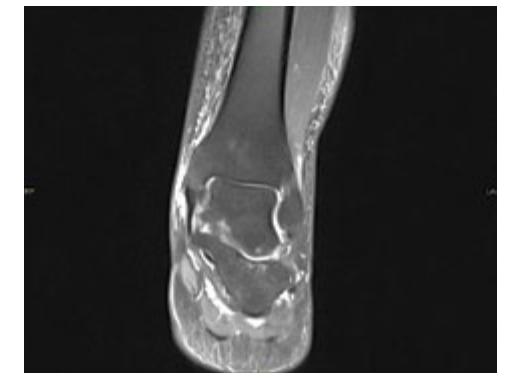


Figure I.85. Coronal plane

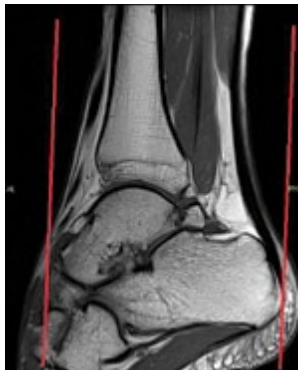- Contrast enhanced T1 FS – sagittal
- Contrast enhanced T1 FS – coronal

Imaging parameters:

- Slice thickness: 4 mm
- Gap: 0.5 mm
- FOV: 18-22 cm

Imaging planes

The most important plane is the sagittal plane, which is perpendicular to the lateral and internal ankles in the axial plane, and parallel to the tibiotalar joint (to the tibia) in the coronal plane. The boundaries are the lateral and internal ankles. (Figure I.82.) (Figures I.83., I.84.)



Figures I.86. Positioning of the coronal plane

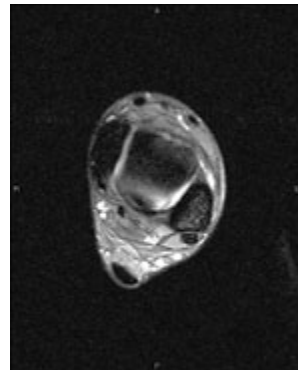
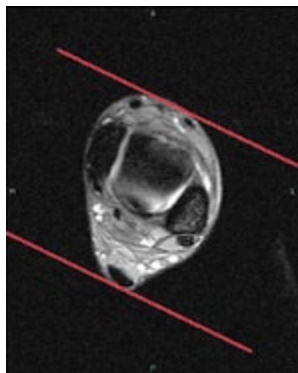
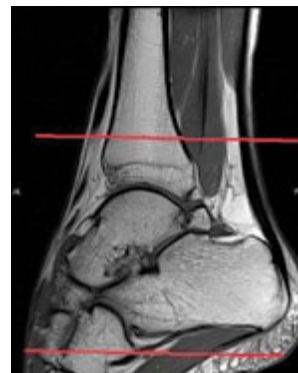

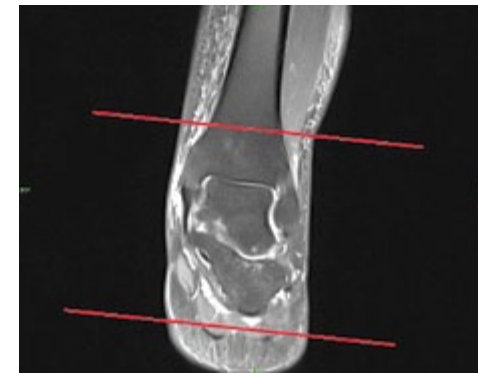
Figure I.88. Axial plane



Figures I.87. Positioning of the coronal plane



Figures I.89. Positioning of the axial plane



Figures I.90. Positioning of the axial plane

The coronal plane is perpendicular to the sagittal plane. The examined region extends from the anterior surface of the talus to the Achilles tendon. (Figure I.85.) (Figures I.86., I.87.)

The axial slices are parallel to the tibiotalar joint, and extend from the distal end of the tibia to the bottom edge of the calcaneus. (Figure I.88.) (Figures I.89., I.90.)

Sequences

Cartilaginous surface injuries are visualized best on PD FS sequences. Ligaments and tendons can be appreciated well on T1-weighted and PD FS images. Fluid in the joint is most striking on the T2-weighted and PD FS measurements. FS PD, STIR and T2-weighted images are good for assessing bone marrow oedema.

Magnetic resonance imaging of the forefoot

The indications, the patient position, the sequences and the coils are the same as those described for ankle MRI. The only differences are positioning of the slices and centering. It is best to use a dedicated ankle coil, but if this is not available, you can use a flex coil, knee coil, or head coil.

Place the coil right at the center of the MR table. When you place the patient's foot in the coil, you can use patient support pads to immobilize the foot and to properly position the forefoot in the coil. The other foot should be placed as far away from the coil as possible to prevent any wrapping or aliasing, especially with receive-only coils. After positioning, center to the metatarsal bones.

Imaging planes

The coronal slices are parallel to the metatarsals in the sagittal plane, and to the line connecting the metatarsals in the axial plane. The examination area extends from skin surface to skin surface. (Figure I.91.) (Figures I.92., I.193.)

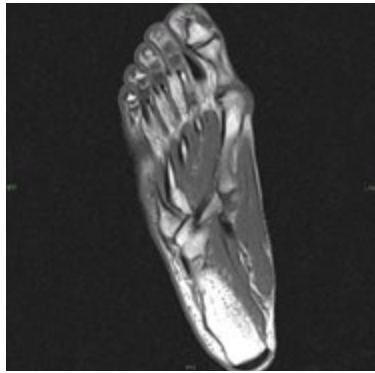


Figure I.91. Coronal plane

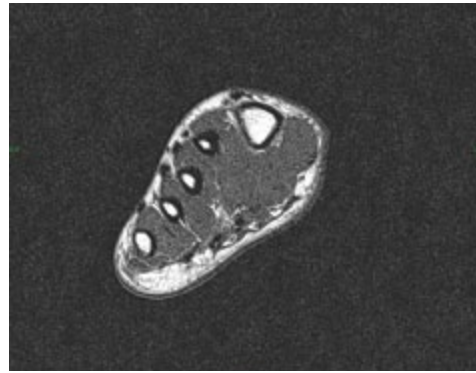


Figure I.94. Axial plane

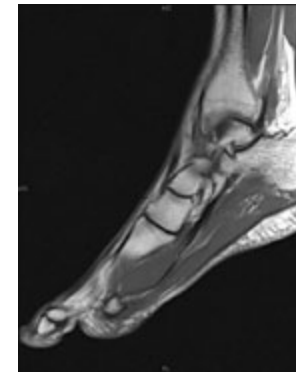
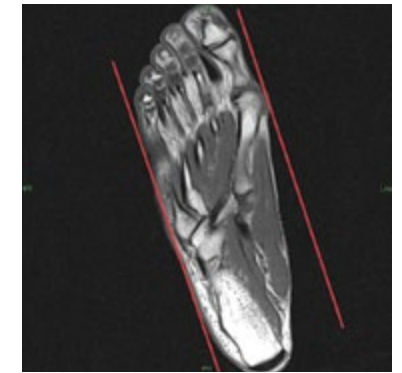
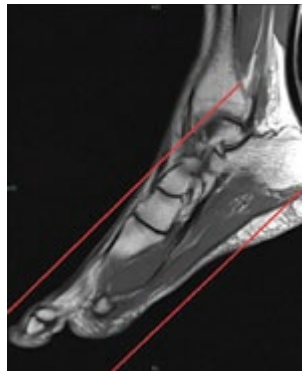

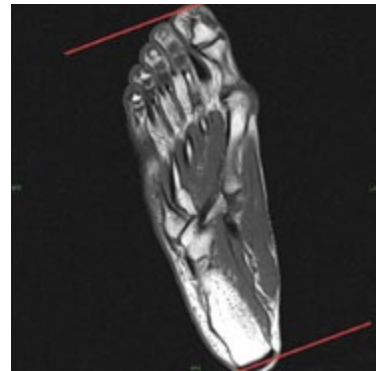
Figure I.97. Sagittal plane



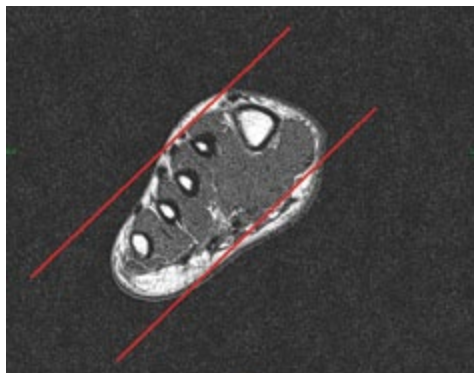
Figures I.98. Positioning of the sagittal slices



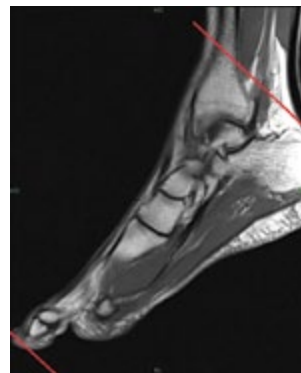Figures I.92. Positioning of the coronal slices



Figures I.95. Positioning of the axial slices



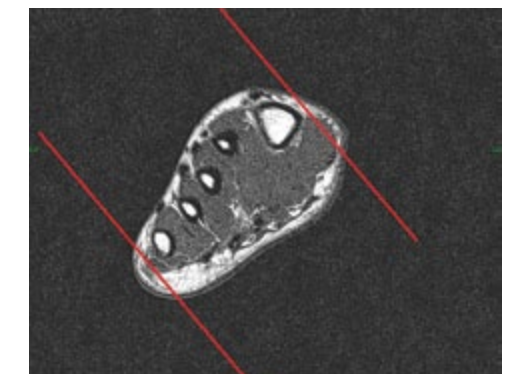
Figures I.93. Positioning of the coronal slices



Figures I.96. Positioning of the axial slices

The axial slices are perpendicular to the metatarsals in both the sagittal and the coronal planes, and it extends from the toes to the posterior edge of the calcaneus. (Figure I.94.) (Figures I.95., I.196.)

The sagittal slices are parallel to the metatarsals in the coronal plane, and they are parallel to the sole in the axial plane. The examination area extends from the medial skin surface to the lateral skin surface. (Figure I.97.) (Figures I.98., I.99)



Figures I.99. Positioning of the sagittal slices

Magnetic resonance imaging of the extremities, soft tissue

Most common indications

- tangible mass in the soft tissue
- muscle rupture
- bone marrow edema, bone necrosis
- bone tumors and bone metastases
- tumour staging

No matter which limb is involved (upper arm, forearm, thigh, leg), the course of the investigation, and the angulation of the imaging planes are mostly the same. The difference is in patient positioning and coil selection.

When imaging the upper arm or the forearm, use a phased array coil. You can position the patient head first, in a supine position, and let the arms lay by their side. Then you can wrap the coil around the arm. This is the most comfortable position for the patient. Try to shift the patient to the opposite side, so that the affected side is as close as possible to the magnetic axis. To avoid motion artifacts, use pads and put them under the patient's arm. Motion artifacts from respiration can be eliminated by saturation or correct selection of the phase encoding direction. When examining the forearm, make sure that the arm is in a supine position, so that the radius and the ulna do not cross each other.

Examination of the thigh can be done feet first or head first as well. In general – if the patient is not too tall – we prefer the head first position, and if it is possible, the integrated spine coil elements (manufacturer dependent) should extend under the patient's knee. If necessary, a two phased array body coil can be used.

When imaging the shin, the patient is in a feet first position. In this case, as well, a phased array body coil has to be used. When positioning the patient, always make sure that at least one, but preferably both joints, are included in the examined region.

Recommended sequences:

- STIR measurements
- T1 measurements
- T1 FS measurements
- T2 measurements
- Contrast enhanced T1 sequences

The best imaging plane is mostly determined by the pathology, but measurements should be performed in all planes. Imaging planes are usually angled perpendicular and parallel to the long axis of the limb.

I.8. Magnetic resonance imaging of the neck

Patient preparation

Always make sure that there are no contraindications to the examination. Ask the patient to remove everything containing metal (hearing aids, hairpins, body jewelry, necklace, clothing, etc.).

The most commonly examined regions are:

pharynx, larynx, parotid gland, tongue, tongue root, sinuses, thyroid gland and lymphatic drainage

Indications

- search for tumors, metastasis
- tumor staging

The patient should be in a supine position, and the larynx centered on the middle of the neck coil. For better patient comfort and easier breathing, leg support pads should be placed under the patient's knees. If necessary (eg. in case of nasal sinus tumors), the head coil is used for better image quality. Centering is on the middle of the neck coil. (Figure I.100.)

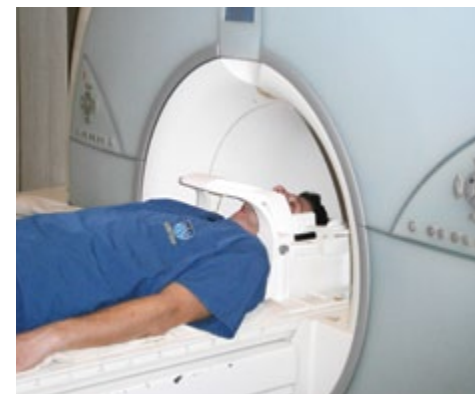

Figure I.100. Examination of cervical soft tissues; patient positioning

In neck imaging, swallowing, gross patient motion, and deep breathing are the main sources of motion-related artifacts. Careful attention to patient comfort, and the use of faster sequences (for shorter scan time) reduce motion-related artifacts resulting from voluntary and involuntary patient motion. To reduce artifacts from metal dentures, it is practical to use spin echo (SE) or STIR sequences.

Recommended sequences:

- STIR – axial
- STIR – coronal

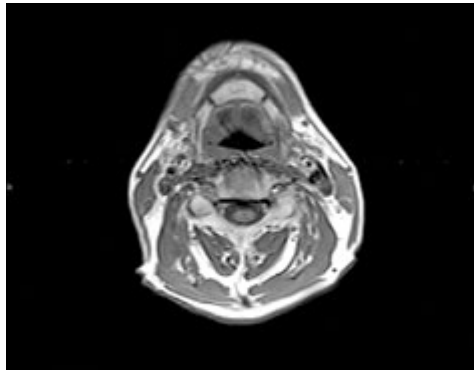


Figure I.101. Axial plane

- T1 TSE – axial
- T2 TSE – sagittal
- Contrast enhanced T1 FS – axial
- Contrast enhanced T1 FS – coronal
- Contrast enhanced 3DT1 VIBE FS – axial

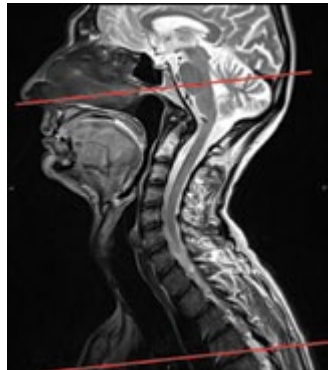
Imaging parameters:

- Slice thickness: 4-6 mm
- Gap: 0.4-1.2 mm
- FOV: 20-25 cm

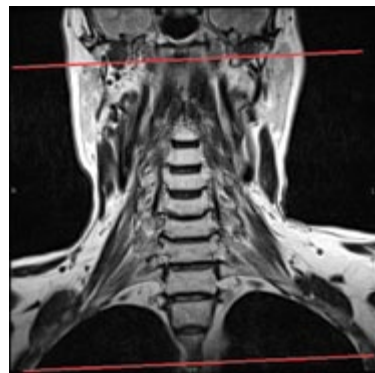
Imaging planes

Of the three major planes, cross-sectional anatomy can be best judged on the axial slices, therefore these images are used most frequently. The axial images extend from the hard plate (palatum durum) to the aortic arch, and they are planned on the sagittal and coronal images, parallel and perpendicular to the centerline of the body. (Figure I.101.) (Figures I.101., I.102.)

Whether the coronal or the sagittal planes are used, depend on the examined region and the indication (e.g., direction of tumour



Figures I.102. Positioning of the axial plane



Figures I.103. Positioning of the axial plane

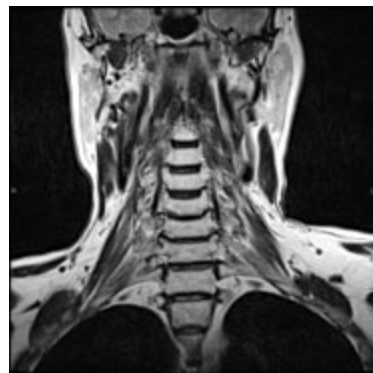
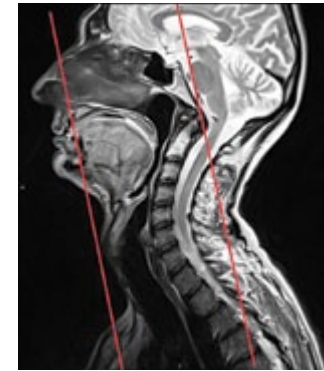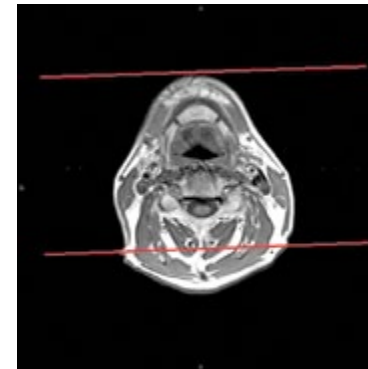


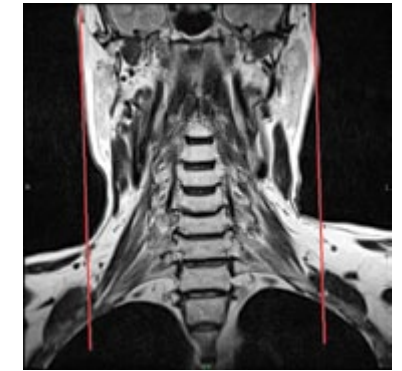
Figure I.104. Coronal plane



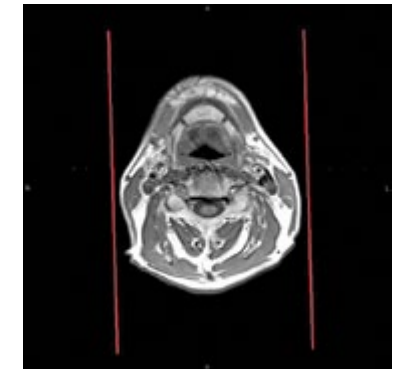
Figures I.105. Positioning of the coronal plane



Figures I.106. Positioning of the coronal plane



Figures I.108. Positioning of the sagittal plane



Figures I.109. Positioning of the sagittal plane

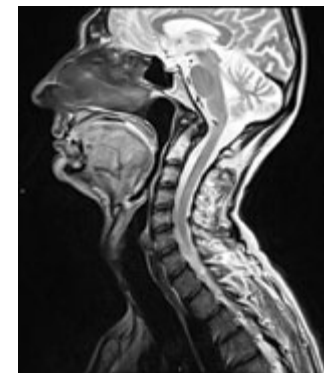


Figure I.107. Sagittal plane

spread). Thus, when imaging the pharynx, larynx and thyroid gland, the second plane that we have to choose is the coronal, which extends from the hyoid bone (or the anterior cervical skin surface) to the spinous processes. The upper boundary is the hard plate, and the lower is the aortic arch. (Figure I.104.) (Figures I.104., I.105.)

When imaging tongue and tongue base pathology, the essential plane is the sagittal. Plan the sagittal slices on the axial and coro-

nal planes parallel to the midline of the neck. (It is rarely used in daily routine.) (Figure I.107.) (Figures I.108., I.109.)

Sequences

In case of a cervical soft tissue examination, the most useful sequence is STIR, because on these images, the tumours, inflammation and other diseases appear hyperintense and they can be easily separated from surrounding tissues. Instead of the STIR sequence, you can also use the T2-weighted sequence. After administration of contrast material, FAT SAT T1-weighted measurements have to be made.

I.9. Magnetic Resonance Imaging of the Chest

Until recently, body imaging was the domain of multislice CT and ultrasound, for most applications, because of its very short acquisition time, high resolution, and widespread availability. However, thanks to the recent sequence, coil and MR hardware advances, MR became a powerful imaging modality due to its inherent multiple tissue contrast, enhanced safety, and its ability to visualize anatomy. The main disadvantage of MR imaging is the longer scan time. However, with the multichannel coil structures and parallel imaging concept, both image quality and routine MR examination times improved significantly and will continue to improve.

Patient preparation

Always make sure that there are no contraindications to the examination. Ask the patient to remove everything containing metal (hearing aids, hairpins, body jewelry, necklace, clothing, etc.). A pacemaker is a contraindication of the examination. If it is necessary, the ECG electrodes are placed on the chest, and additional pads are placed between the coil and the electrodes. Place the respiratory bellows on the level of the diaphragm. Insert an intravenous line before the examination. This prevents displacement during the test. It is always recommended to let the patient know how long the scan is going to take. Instruct the patient how a proper breath holding should be done, and have him or her do some practice breathholds before the exam. Images that are acquired after exhalation are the easiest to reconstruct, and this is the most comfortable for patients, as well. Artifacts that result from respiration can be eliminated by the navigator echo technique. By using a navigator echo – which is placed on the right diaphragm – the patient can breathe freely during the test.

Indications

- tumours
- mediastinal disorders
- diseases of chest vessels

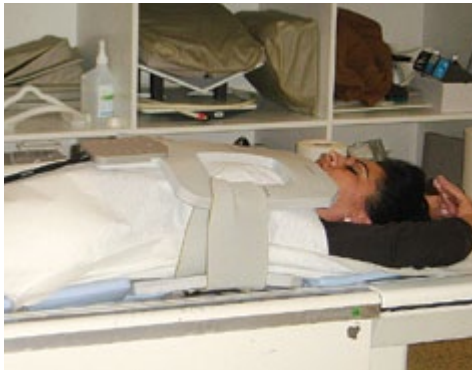

Figure I.110. Positioning of a chest examination

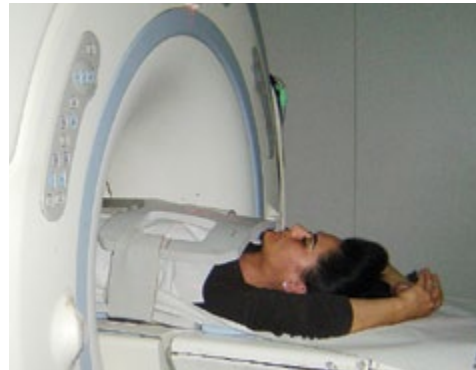

Figure I.111. Centering of a chest examination

Patient positioning

Position the patient supine on the coil while the arms are raised above the head unless there is a physical restriction (pain, age, etc.). The coil center should align with the sternum and centering is done on the middle of the coil. Whether the patient is positioned feet or head first depends on the machine and the coil. The upper edge of the coil is positioned above the axillary region. (Figure I.110.) (Figure I.111.) (Figures I.112.a, b)

Protocols

Recommended sequences for mediastinal disorders:

- T1 - axial, coronal, sagittal
- T2 - axial
- T1 + FAT SAT sequences, in all three planes, after administration of contrast material.



Figures I.112.a, b Torso coil

Recommended sequences for chest wall lesions:

- T1 - axial, coronal
- T2 - axial, coronal
- T1 + FAT SAT sequences, in all three planes, after administration of contrast material.

Recommended sequences for imaging the brachial plexus:

- FAT SAT-PD - sagittal, coronal
- T1 - sagittal, coronal
- T2 FAT SAT - sagittal
- T1 + FAT SAT sequences, in all three planes, after administration of contrast material.

The sagittal series can be compared with each other, thus the subclavian vein, the subclavian artery and the brachial plexus can be assessed in relation to each other

Examination of the lung

With inhaled oxygen or hyperpolarized helium, the lungs can also be imaged. We can perform static, dynamic and perfusion studies.

Plan the axial slices on the coronal and the sagittal series. The slices are perpendicular to the sagittal and the longitudinal axes. For chest wall diseases, the region of interest fully covers the lesion. For a mediastinal lesion we have to examine the lymph nodes around the clavicle and in the axilla, too.

Mapping direction: caudo-cranial

Slice thickness: 5-5.5 mm

Gap: 1-1.5 mm

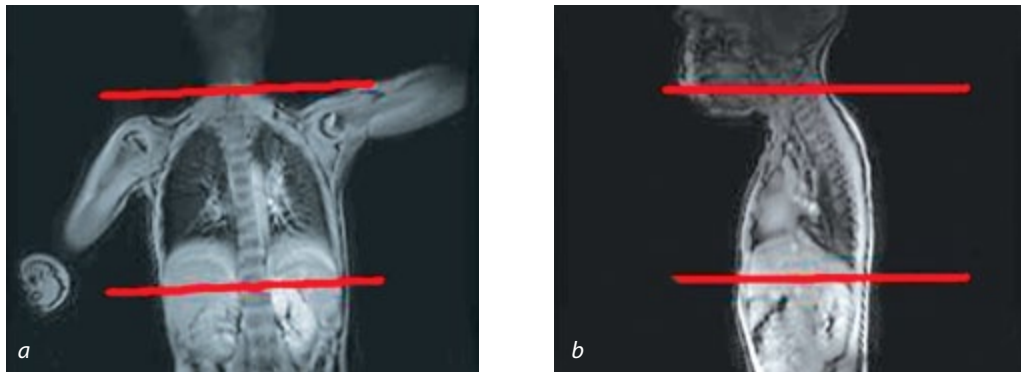
FOV: 30-36 cm

(Figures I.113.a, b)

Plan the coronal slices on the sagittal plane. The slices are perpendicular to the sagittal and transverse axes. On the axial localizing images, we have to make sure that the slices have been set correctly. If the FOV is too small, aliasing may occur, but if it is too large it may hinder the evaluation of the image. The imaging region is the area between the ventral and dorsal chest wall. The slices should cover lesions that extend beyond the chest wall as well.

Mapping direction: antero-posterior

Slice thickness: 5-5,5 mm



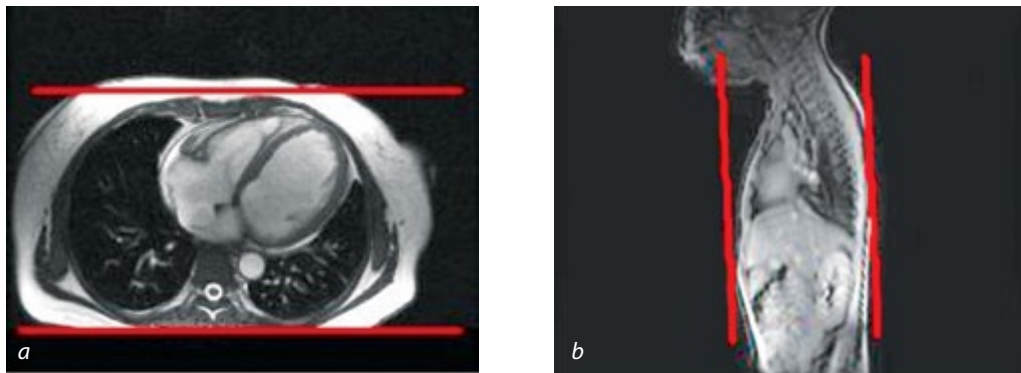
Figures I.113.a, b Positioning of the axial slices on the coronal and the sagittal images

Gap: 1-1.5 mm
 FOV: 30-36 cm
 (Figures I.114.a, b)

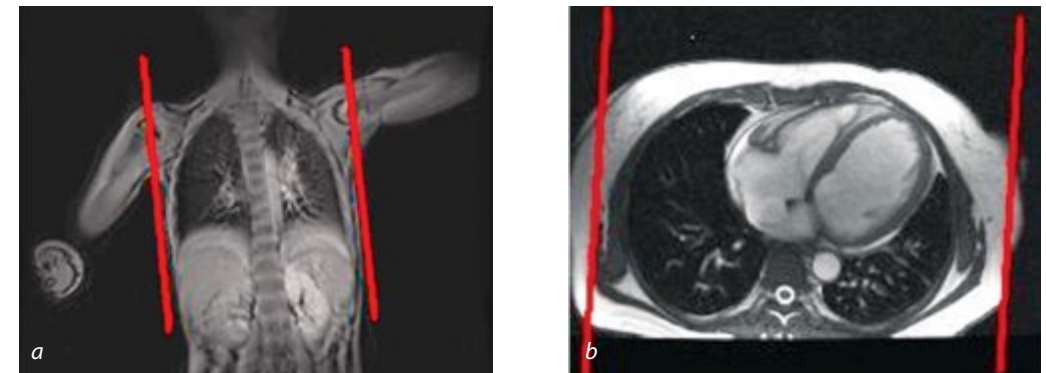
Plan the sagittal slices on the coronal images. The slices are perpendicular to the axial axis. On the axial images, we have to make sure that the planned slices are perpendicular to the longitudinal axis.

The imaging area can be changed to accommodate the size of the lesion. In case of an extensive disease, the test region may exceed the bony chest wall as well.

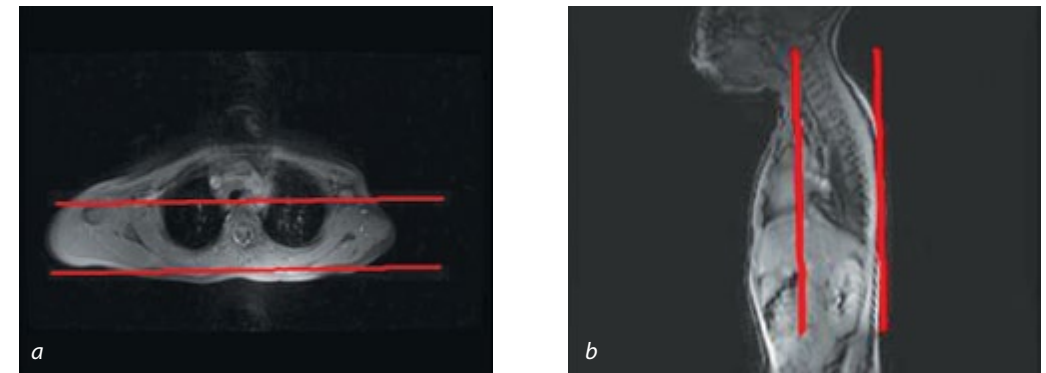
Mapping direction: right-to-left
 Slice thickness 5-6 mm



Figures I.114.a, b Positioning of the coronal slices on the axial and the sagittal images



Figures I.115.a, b Positioning of the sagittal slices on the axial and the coronal images



Figures I.116.a, b Planning the axial and sagittal slices of the brachial plexus examination

Gap: 1-1.5 mm
 FOV: 30-36 cm
 (Figures I.115.a, b) (Figures I.116.a, b)

I.10. Magnetic resonance imaging of the abdomen

Until recently, body imaging was the domain of multislice CT and ultrasound for most applications because of its very short acquisition time, higher resolution, and widespread availability. However, thanks to recent sequence, coil and MR hardware advances, MR became a powerful imaging modality due to its inherent multiple tissue contrast, safer scanning ability, and its ability to visualize anatomy. The main disadvantage of MR imaging is the longer scan time. However, with the multichannel coils and parallel imaging technology, both image quality and routine MR examination times improved significantly and will continue to improve. In body imaging, the biggest challenge for MRI is the need to image moving organs. Gross organ motion creates significant artifacts in MRI and makes it difficult to get reliable diagnostic information. Therefore, the main strategy of body MR imaging is eliminating the gross cardiac and breathing-related motion artifacts by utilizing respiratory gating, cardiac gating, and/or breath holding. All the gating techniques, as well as breath hold, can make a great difference on the resulting image quality.

Respiratory-gating: Respiratory bellows detect the motion of the abdominal wall. Respiratory gating in MRI is useful options for patients unable to hold breath.

Breath-hold: To maintain the quality of breath-hold scans, we strongly recommend that the patient practices breath holding on the MR table before the actual scan, so that he can understand what is required. Breath holding in either inspiration or expiration seems to be a choice of each site depending on their experience. However, expiration breath hold is recommended, because inspiration breath holds will cause a significant chest wall difference compared to expiration.

Navigator-echo: The navigator technique is based on the detection of the abdominal wall motion using a 1D or 2D navigator slice. The navigator is usually put on the right diaphragm.

Patient preparation

The patient should not eat for at least 4-6 hours before the examination, because bowel peristalsis may cause artefacts. If the gastrointestinal tract is examined, the patient has to be on a diet before the test, and plenty of fluid consumption is required. When imaging the gastrointestinal tract with MR, similarly to CT, we give the patient an oral contrast agent (1.5 - 2 liters) one hour before the test. Oral contrast agents can be grouped as positive (high signal on both T1 and T2-weighted images), negative (low signal on both T1 and T2-weighted images) and two-phase (high signal on one type of sequence, and low signal on another type of sequence) materials. Usually we can use water, a variety of juices, milk, green tea, pineapple juice as a per os contrast agent.

First, always make sure that there are no contraindications to the examination. Ask the patient to remove everything containing metal (hearing aids, hairpins, body jewelry, necklace, clothing – bra, etc.).

Before the test, have an intravenous line placed in the patient's arm for intravenous administration of contrast material. This prevents displacement during the test. We can use gadolinium containing paramagnetic contrast agents as well as superparamagnetic iron oxide particles phagocytosed by the reticulo-endothelial system (RES).

If there are no contraindications, an intramuscular or intravenous injection of an anti-peristaltic agent should be considered, since this decreases motion artifacts and improves image quality.

Indications

- differential diagnosis of focal liver lesions
- assessment of the biliary and pancreatic ducts – MRCP
- differential diagnosis of pancreatic processes
- differential diagnosis of kidney tumors, MR urography
- adrenal gland adenomas vs. metastasis
- inflammatory processes of the gastrointestinal tract

Patient positioning

Place the coil straight at the center of the MR table. Then position the patient supine on the coil feet first or head first, while the

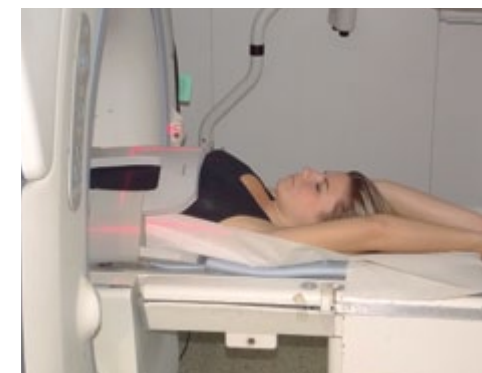


Figure I.117. Abdominal coil positioning

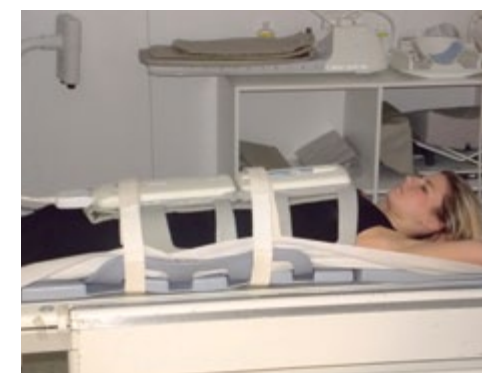

Figure I.118. Positioning the patient in the abdominal coil

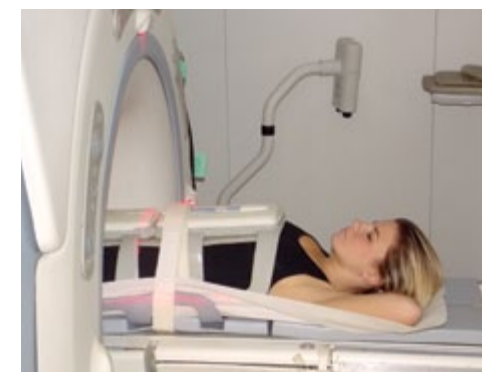

Figure I.119. Abdominal – pelvic coil positioning



Figures I.120.a, b, c, d Abdominal – pelvic and torso coil

arms are raised above the head unless there is a physical restriction (pain, age, etc.). The coil center should be positioned approximately 3 centimeters under the xiphoid process of the sternum – but this may vary depending on the coil type, and the region of interest. It should be taken into account when fitting the coil, that in expiration the diaphragm moves upwards and the subphrenic part of the liver 'may be cut off'. (Figure I.117.) (Figure I.118.) (Figure I.119.) (Figures I.120.a, b, c, d)

Video: [Positioning for abdomen MRI scan](http://tamop.etk.pte.hu/tamop412A/Kepalkotasi_gyakorlatok_tananyag/MR/VIDEO_MR_GYAK/HAS_FINAL.wmv)

http://tamop.etk.pte.hu/tamop412A/Kepalkotasi_gyakorlatok_tananyag/MR/VIDEO_MR_GYAK/HAS_FINAL.wmv

Protocols

Recommended sequences:

- T2 – coronal
- T2 FAT SAT – axial
- T1 – axial
- FIESTA

Additional sequences:

- in-phase – out of phase measurements
- T2 GRE
- MRCP (if needed, done with addition of secretin)
- after administration of contrast material – T1 3D dynamic measurements
- T1- post contrast with FAT SAT – axial
- DWI
- spectroscopy
- MRA of the abdominal arteries

Generally, fast sequences are used in abdominal imaging. The SS FSE (single shot) technique does not use interleaved data collection, but we get the images slice by slice (sequentially), so even non-cooperative patients can be examined easily. With fat saturation, retroperitoneal lesions can be detected, and after administering the contrast material, only contrast enhancing tissues are visualized with high signal intensity. In case of an inflammatory bowel process, on the postcontrast and fat saturated sequences, the extent of disease and surrounding fat tissue involvement are well visualized. On the out of phase images fat has reduced signal intensity compared with the in phase images, thus together these two sequences are suitable for the detection of fat in the adrenal gland, the differentiation of renal space-occupying processes, identification of focal sparing and focal deposition in steatosis hepatis.

Plan the coronal slices on the sagittal localizer. The slices are parallel to the longitudinal axis. Make sure that the axial images are perpendicular to the sagittal axis. The region of interest extends from the diaphragmatic surface of the liver to the bottom of the kidneys, and from the abdominal wall to the back.

Mapping direction: antero-posterior

Slice thickness: 5-7 mm

Gap: 1 mm

FOV: 40-48 cm, depending on the shape of the patient.

(Figure I.121.)

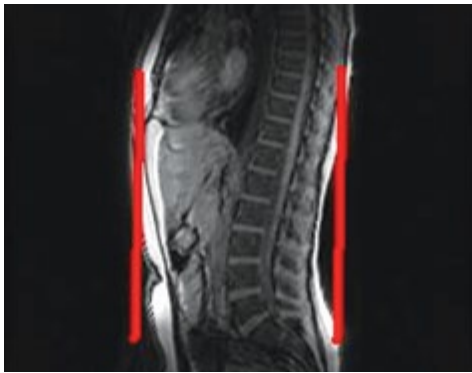


Figure I.121. Positioning of the coronal slices.

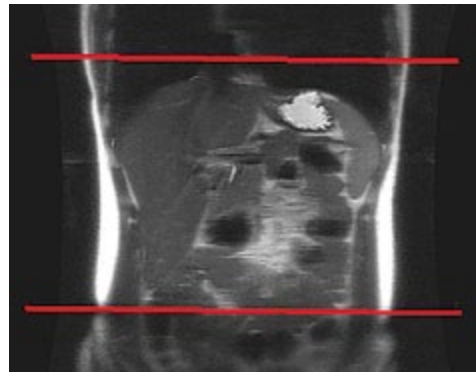


Figure I.122. Positioning of the axial slices

Plan the axial slices on the coronal images. The slices are perpendicular to the sagittal and longitudinal axes. The examined region extends from the diaphragmatic surface of the liver to the bottom of the kidneys.

Mapping direction: cranio-caudal

Slice thickness: 6-8 mm

Gap: 1 mm

FOV: 38-46 cm, depending on the shape of the patient.

(Figure I.122.)

MRCP

Magnetic resonance cholangiopancreatography (MRCP) is a technique that can be used as a non-invasive alternative to endoscopic retrograde cholangiopancreatography (ERCP). MRCP can be done with breath hold or with respiratory triggering. Spasmolytics can be used to reduce intestinal motion artifacts.

In contrast to ERCP, which demonstrates all ductal structures that can be cannulated and filled with contrast material, MRCP demonstrates all biliary ducts and the gallbladder, which are in vivo filled with fluid. MRCP uses heavily 2D or 3D T2-W sequences with TEs longer than T2-relaxation times of soft tissues, thus they do not give signal on MRI images. This technique allows visualization of static fluid and it may be considered as a fluid weighted technique. Usually, a 4-6 h fasting is required prior to MRCP exams. Additionally, a glass of pineapple juice may be used to decrease the T2 time of the fluid within the stomach and duodenum. Intravenous secretin administration can improve the secretion of pancreatic fluid, after which dynamic measurements are made for as long as 10 minutes, so that functional diseases can be identified.

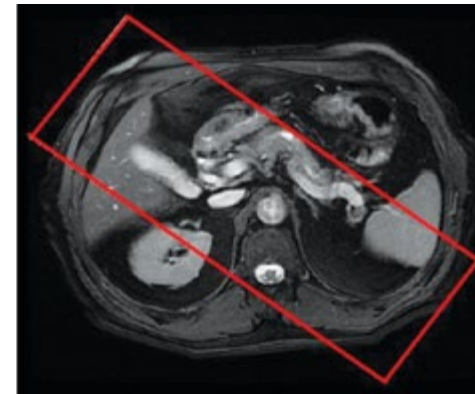


Figure I.123. Positioning the 3D MRCP box in the tilted paracoronar plane

The 2D images are acquired under one breath hold, in about 15-20 seconds. During 3D measurements, images are acquired between two breaths. The examination time is 4-5 minutes. The main plane is the paracoronar, and the slices are perpendicular to the portal vein. Mapping direction: antero-posterior (Figure I.123.)

If necessary, after contrast agent administration, we can perform dynamic FAT SAT 3D T1 measurements. The dynamic range of the measurements is 20-25 seconds. First we acquire a native series, which is followed by repeated post contrast measures at least three times after the administration of contrast material.

If necessary, the 5 measurements are repeated after 10 minutes, in the so-called delayed or secretory phase.

Plan the dynamic 3D T1-weighted axial slices on the coronal and sagittal images as we do on the 2D images. The examined region extends from the diaphragmatic surface of the liver to the bottom of the kidneys.

Mapping direction: cranio-caudal

Slice thickness: 4-5 mm

Gap: 0 mm

FOV: 38-48 cm, depending on the shape of the patient

I.11. Magnetic resonance imaging of the pelvis

For appropriate imaging, a good preparation is essential. The patient should not eat 4-6 hours prior to the examination, because bowel peristalsis can lead to motion artifacts. If there are no contraindications, an intramuscular or intravenous injection of an antiperistaltic agent should be considered as this decreases motion artifacts and improves image quality. For pelvic imaging, a half-full bladder is optimal, and we do not recommend starting the examination with the bladder either totally full or, on the contrary, totally empty.

The patient is usually requested to empty the bladder 2–3 h prior to MRI examination of the pelvis, and then to drink normally afterwards. Assessment of the bladder is facilitated by bladder distension. However, overfilling of the bladder has to be avoided as this may become distressing over the course of the MR examination. In assessing gynecological conditions, a half-full bladder prior to scanning is sometimes preferred. A half-full bladder slightly pushes the uterus upwards, and thus it can straighten out the uterine cervico-corporal junction. Therefore assessing uterine involvement of cervical cancer or cervical infiltration of uterine cancer is more accurate. In addition, the vaginal fornix is better visualized, which is important when assessing for parametrial involvement. On the T2-weighted images, the bladder also has a high signal intensity, that has a contouring effect on the images. Bladder tumours, tumours of the surrounding organs and their infiltration of the bladder can be examined much better with a filled bladder. However, the full bladder is unfortunate, because it may be a source of ghosting and motion artifacts, and it may cause discomfort for the patient. Depending on the clinical indication, gastrointestinal luminal contrast agents may be prescribed. Both positive and negative T1 and T2-weighted contrast agents are available for use. If an endorectal coil is needed, the bladder must be empty. In case of cervical cancer, it is recommended to place a wet tampon in the vagina, for better assessment of tumour extension. If dynamic measurements are necessary, make sure the patient has an intravenous line prepared.

Always make sure that there are no contraindications to the examination. Ask the patient to remove everything containing metal (hearing aids, hairpins, body jewelry, necklace, clothing, etc.).

Indications

- cancer (rectum, bladder, ovary, uterus, cervix, prostate, testis), staging and follow-up
- determination of fetal conditions during pregnancy if the ultrasound examination does not provide a satisfactory result

- endometriosis
- inflammatory diseases
- cystic lesions
- lymph node involvement

Patient positioning

Place the coil right at the center of the MR table. Then, position the patient supine on the coil; the arms can be placed on the sides, above the coil level. The coil center should be around 10 cm below the iliac crest. If you have a body coil with a long coverage, we recommend the top of the coil to be at the level of iliac crest. This way, you can eliminate or significantly decrease breathing-related artifacts. (Figure I.124.) (Figure I.125.) (Figures I.126.a, b)

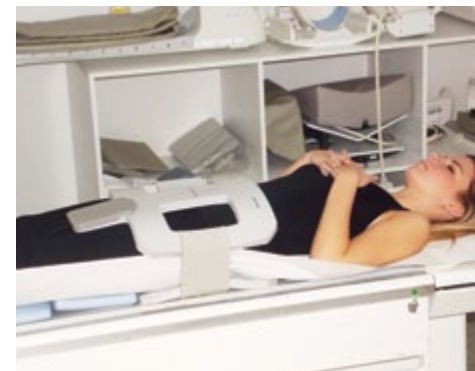

Figure I.124. Positioning of the pelvic examination

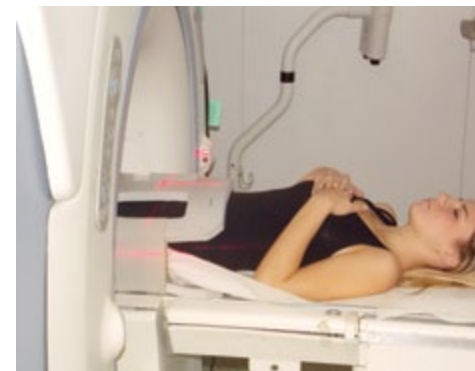

Figure I.125. Centering of the pelvic examination



Figures I.126.a, b Phased array coil

[Video: U for pelvis MRI scan](#)

http://tamop.etk.pte.hu/tamop412A/Kepalkotasi_gyakorlatok_tananyag/MR/VIDEO_MR_GYAK/KISMEDENCE_FINAL_2.wmv

In order to further increase the signal to noise ratio (SNR), we can use endocavitary coils. When imaging the prostate, using an endorectal coil places the receiver array right behind the prostate gland in the rectum. This improves the SNR, and optimizes high resolution imaging of the prostate. It is also possible to combine the use of surface phased-array coils with an endorectal coil simultaneously on some MR systems to maximize image quality. Likewise, using an endovaginal coil in females can be advantageous for visualizing cervical pathologies such as early cervical cancer, and for assessing the presence of parametrial invasion. (Figure I.127.) (Figures I.128.a, b)

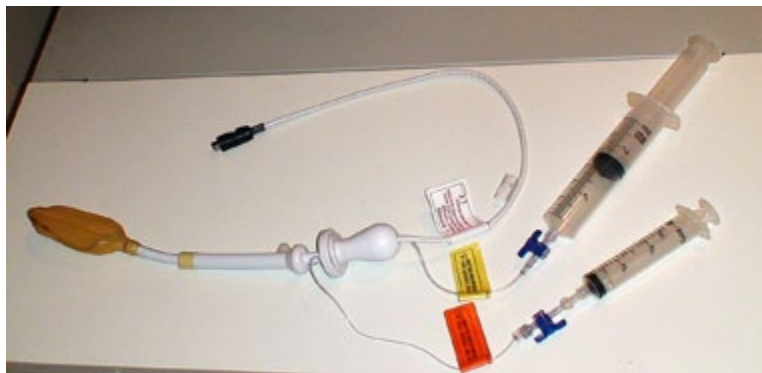
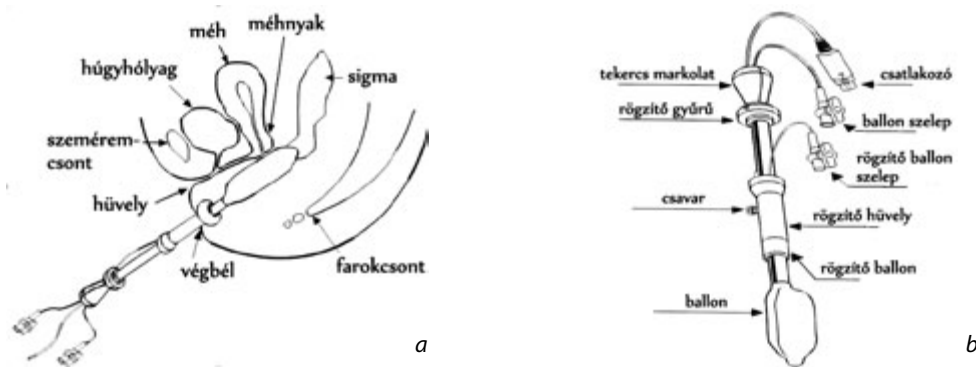


Figure I.127. Intracavitary coil



Figures I.128.a, b Position of the device in the rectum and parts of the device

Protocols

Depending on the indication, the sequences may vary.

Recommended sequences:

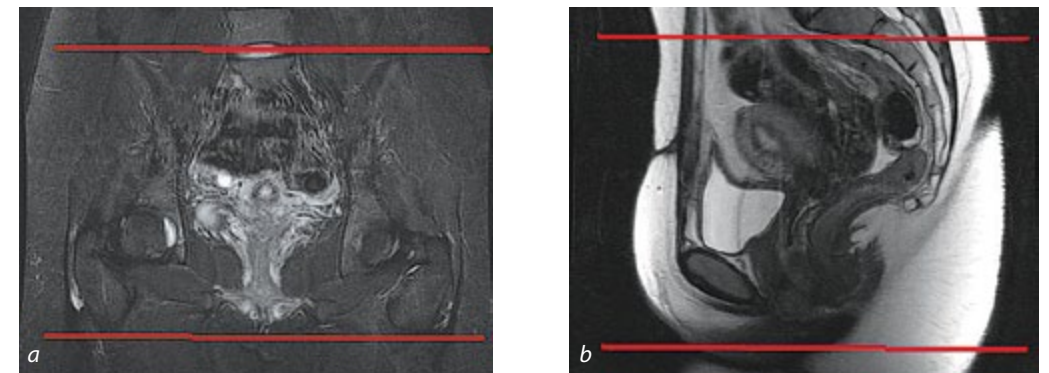
- T2 – axial
- T1 – axial
- T2 FAT SAT – sagittal
- STIR – coronal

Additional sequences:

- T1 – sagittal
- T1 FAT SAT in all three planes after administration of contrast material,
- T1 3D
- DWI

When imaging cervical or bladder tumours, we can perform dynamic FAT SAT 3D T1 measurements. The dynamic range of the measurements are 20-25 seconds. The first series are native, followed by repeated post contrast measurements at least three times after the administration of contrast material. If necessary, the 5 measurements are repeated after 10 minutes in the so-called delayed or secretory phase.

Plan the axial slices on the coronal and sagittal localizer images. The slices are perpendicular to the longitudinal axis and the sagittal slices. On the sagittal images make sure that the axial slices are actually located in the axial plane. The axial slices extend from the iliac crest to the pubic bone (symphysis pubis).



Figures I.129.a, b Positioning of the axial slices

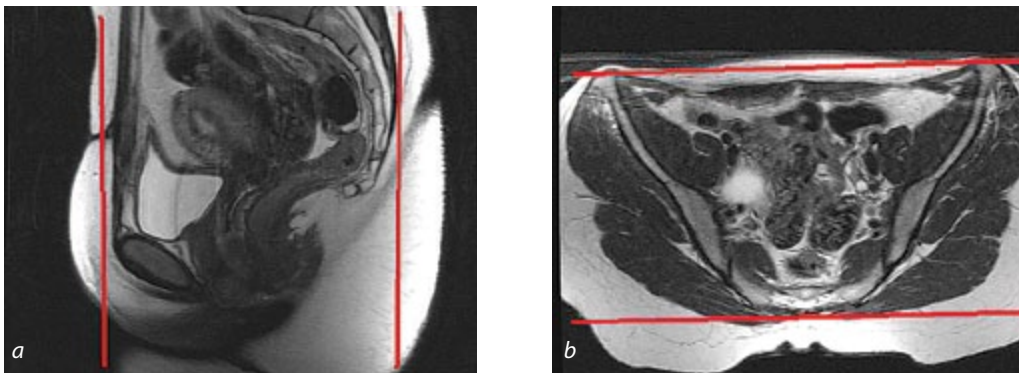
Mapping direction: caudo-cranial
 Slice thickness: 4-4.5 mm
 Gap: 0.5-1 mm
 FOV: 30-36 cm
 (Figures I.129.a, b)

Plan the coronal slices on the sagittal localizer images. The slices are perpendicular to the sagittal and axial axes. On the axial images make sure that the coronal slices are actually located in the coronal plane. The region of interest extends from the abdominal wall to the gluteal region.

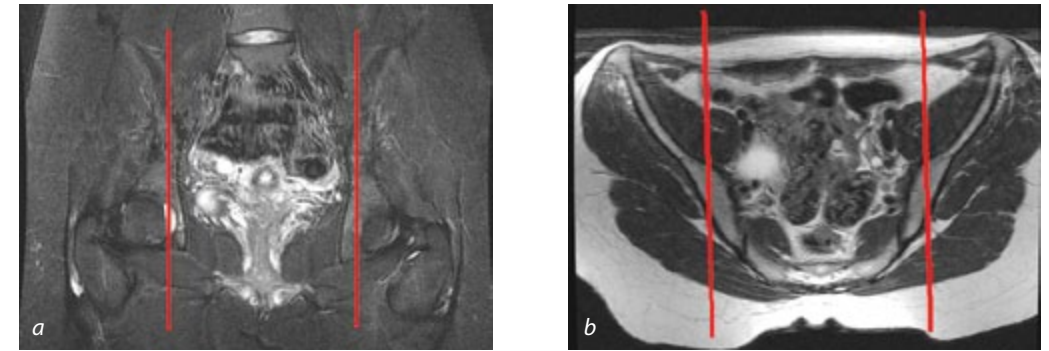
Mapping direction: antero-posterior
 Slice thickness: 5 mm
 Gap: 1 mm
 FOV: 36-46 cm, depending on the shape of the patient
 (Figures I.130.a, b)

Plan the sagittal slices on the coronal localizer images. The slices are perpendicular to the transverse axis. On the axial slices make sure that the slices are perpendicular to the longitudinal axis. The imaging area may vary because of the size of the lesion. If the pathological lesion is infiltrating the surrounding tissues, the examined region may exceed the bony pelvis as well.

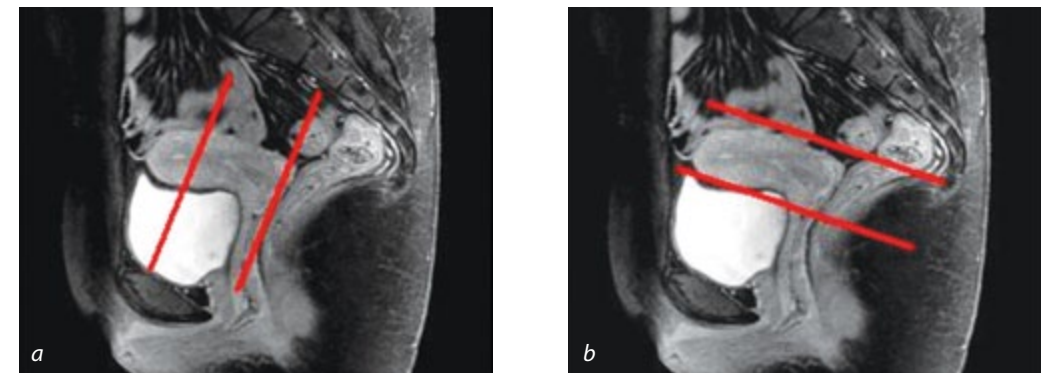
Mapping direction: right-to-left
 Slice thickness: 5 mm
 Gap: 1 mm
 FOV: 24-26 cm
 (Figures I.131.a, b)



Figures I.130.a, b Positioning of the coronal slices



Figures I.131.a, b Positioning of the sagittal slices

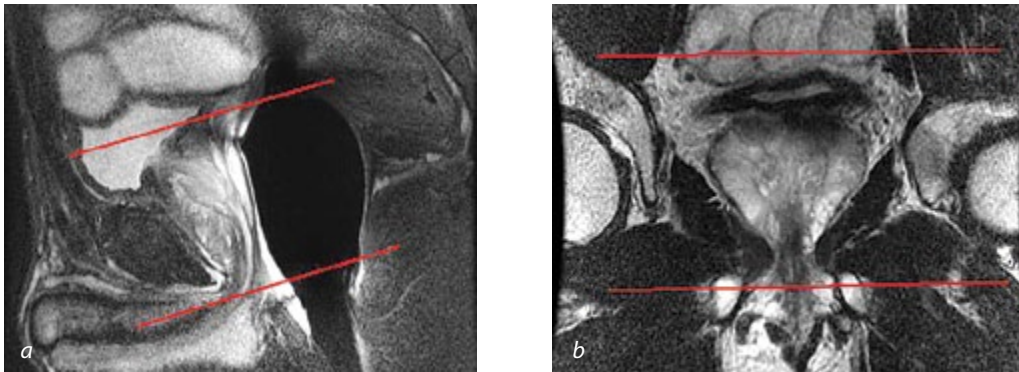


Figures I.132.a, b Positioning of the axial and coronal planes to the endometrium

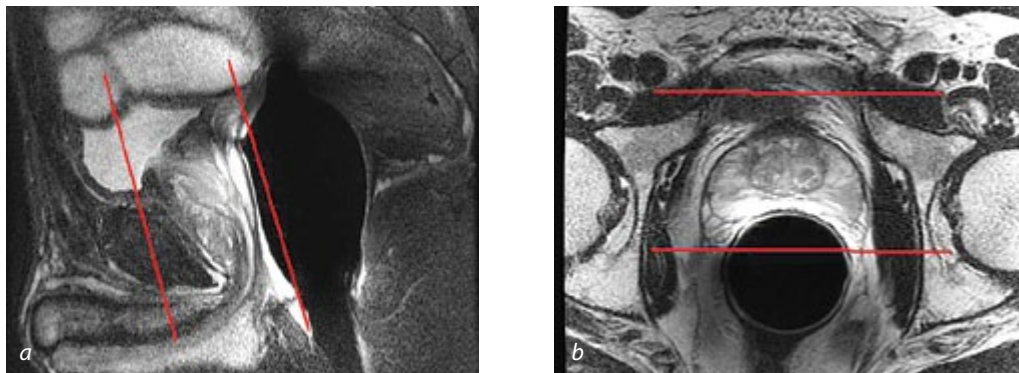
When imaging cervical and uterine cancers, the test plane is different from those described above. In these cases, the coronal plane is parallel to the endometrium, and the axial plane is perpendicular to this coronal plane. (Figures I.132.a, b)

If you are using an endocavitary coil, the following sequences have to be used:

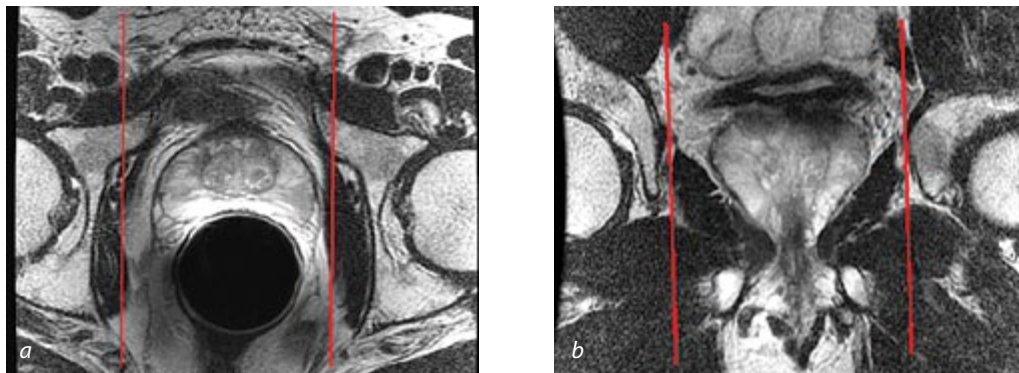
- T2 FAT SAT – axial
- T1 – axial
- T2 FAT SAT – sagittal
- T2 FAT SAT – coronal
- T1 FAT SAT measurements in all three planes after intravenous administration of contrast material, or T1 3D.



Figures I.133.a, b Angling the paraxial plane for prostate examination.



Figures I.134.a, b Angling the paracoronal plane for prostate examination.



Figures I.135.a, b Positioning of the sagittal slices.

Slice thickness: 3 mm

Gap: 1 mm

FOV: 14-16 cm

Depending on the examined region (eg. prostate, cervix, or rectum) the examination planes are angled in accordance with the location of the organ. (Figures I.133.a, b) (Figures I.134.a, b) (Figures I.135.a, b)

I.12. MR Angiography

MR angiography is used for the evaluation of malformations, occlusions, stenoses, vascular anatomy, and to detect flow. These sequences are based mainly on the following principles:

- using the inflow of fresh spins into the slab, which are not subjected to the radiofrequency pulses, unlike the stationary tissue: time-of-flight phenomenon (TOF);
- detecting the phase changes of moving spins subjected to a gradient: phase contrast (PC)

TOF

Time-of-flight sequences are one of the most commonly used sequences among non contrast MRA sequences. In time-of-flight MR angiography, the gradient-echo sequences are optimized to favor the vascular signal over that of the surrounding tissues by saturating the stationary tissue signal with a very short TR.

The strength of the vascular signal is proportional to the flow velocity (faster flow gives higher signal intensity) and depends on:

1. the length and orientation of the vessel (the vascular signal will be higher if the slice is perpendicular to the axis of the vessel, because the spins have a shorter travel time into the slice volume,
2. the measuring parameters (flip angle, slice thickness, repetition time)
3. and the relaxation parameters.

The main limitations of time-of-flight MRA are:

1. signal loss linked to spin dephasing when the flow is complex or turbulent (stenosis),
2. signal loss when the flow is too slow or oriented parallel to the slice plane
3. and poor signal suppression of the stationary tissues when substances with very short T1 relaxation time are present (fat, blood degradation products).

Time of Flight MR angiography can be obtained in both 2D or 3D modes.

2D TOF MRA

In 2D acquisition, single thin slices are obtained in sequence. The main advantage of the 2D technique is better sensitivity to slow flows, with the possibility of using higher flip angles. The main drawback of 2D acquisition is poor spatial resolution due to the thickness of the slices.

3D TOF MRA

3D TOF is the imaging method of the intracranial arteries. It is characterized by high resolution in all three planes. In 3D acquisition, a thicker slice is excited, and many single partitions are reconstructed from this thick slab by different phase encoding steps. The 3D technique is slower than the 2D TOF. (Figure I.136.) (Figure I.137.)

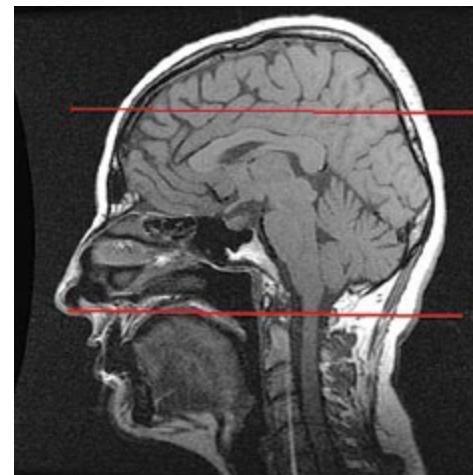

Figure I.136. 3D TOF MRA – Positioning in axial plane

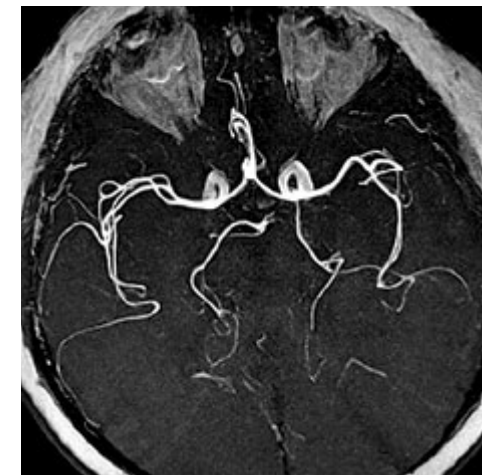


Figure I.137. 3D MRA TOF angiography of the circle of Willis

PC

Phase contrast angiography relies on dephasing the moving spins submitted to a bipolar gradient in gradient echo acquisitions. In the presence of a bipolar gradient of a given intensity and time, the moving spins will dephase in proportion to their velocity while stationary spins will be dephased and rephased by the opposite gradients, returning to their original status. So the flow velocity is proportional to the phase shift and the stationary tissue's phase shift is canceled. Phase data allow the measurement of flow velocity and direction. Because Phase Contrast MR Angiography is more sensitive than time-of-flight to slow flow, its main application is cerebral venous imaging. (Figure I.138.a) (Figure I.138.b) (Figure I.139.a) (Figure I.139.b) (Figure I.139.c)

CE-MRA (Contrast enhanced MRA)

Gadolinium-based agents are the most widely employed agents for CE-MR angiography. They act as positive paramagnetic substances, thus they increase the vascular signal by strongly reducing

the T1 relaxation time of blood. With this technique, we can examine the carotid arteries, the aortic arch, thoracic and abdominal vessels, but a whole body MRA can also be performed. Contrary to the 2D and 3D TOF techniques, with CE-MRA, we can also get information of vessels where the flow is turbulent.

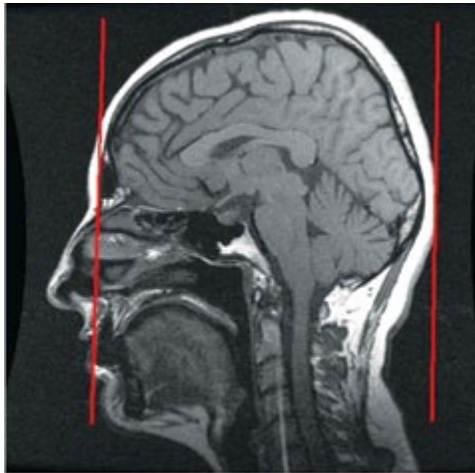


Figure I.138.a 2D PC venography - Positioning in coronal plane

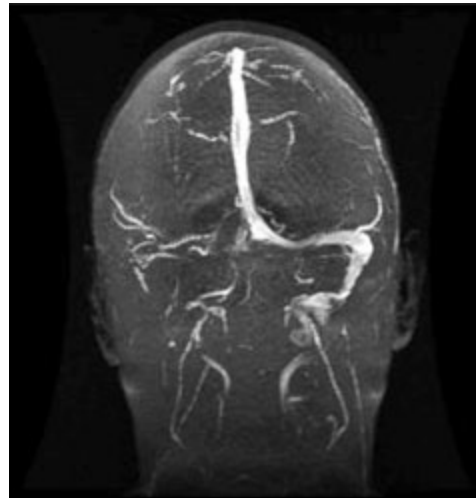


Figure I.139.a Sagittal PC angiography image

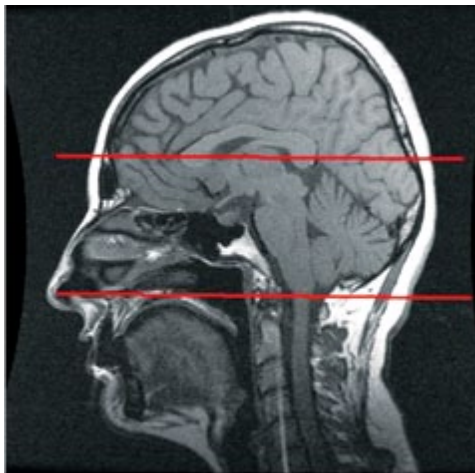

Figure I.138.b 2D PC venography - Positioning in axial plane

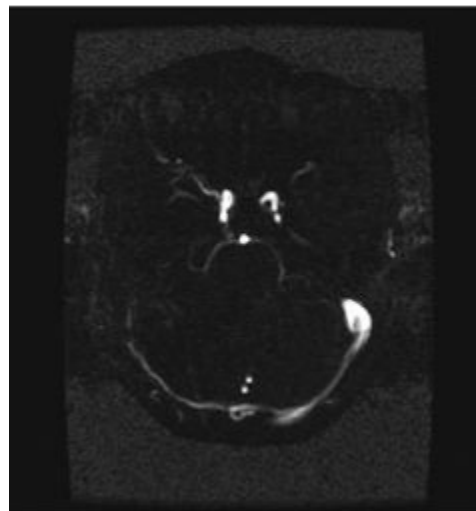


Figure I.139.b Axial PC angiography image

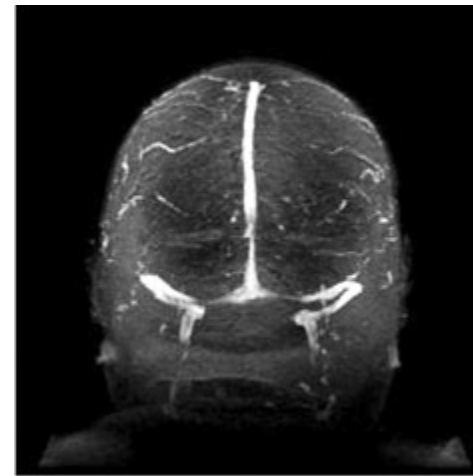


Figure I.139.c Coronal PC angiography images

Cerebral angiography

- 3D TOF- native arterial measurement, if necessary, after contrast material administration
- PC angiography, 2D or 3D
- 2D-TOF venography

I.13. Magnetic resonance imaging of the heart

Introduction

In recent years, cardiovascular MR (CMR) studies have become an integral part of non-invasive diagnostics in clinical radiology and cardiology. In Hungary, clinical cardiac MRI examinations have been carried out routinely, since 1999. Currently, in the U.S. and in Western-Europe, either radiologists or cardiologists who have CMR accreditation perform CMR examinations.

Importance

In Hungary, the number of MR devices suitable for CMR examination has been increasing steadily. During a CMR examination, we can obtain a complex, high diagnostic accuracy set of data non-invasively, which may replace other non-invasive and sometimes invasive tests. This MR diagnostic procedure is widely used and it has a growing role in both the assessment of cardiac status, and in the diagnosis of acute and chronic heart disease. At present, MR imaging is a “gold standard” in the evaluation of cardiac ventricular function.

High quality CMR now offers the following:

- Anatomic imaging for chamber morphology.
- Tissue characterization (high signal from fatty tumors and arrhythmogenic right ventricular cardiomyopathy (ARVD) and definition of myocardial scarring, heart inflammation).
- Myocardial perfusion in ischemic heart disease, non-coronary heart disease).
- Flow quantification (valvular lesions and shunts, congenital malformations).

By monitoring the structure and motion of the heart we can determine which area of the chamber is affected by the infarct, and we can locate wall motion abnormalities. After administration of the contrast agent, the MRI contrast medium accumulates in the dead heart muscle, thus unknown myocardial infarction is also revealed. Not only the infarct can be identified, but also the blood disruption of the heart muscle. Accurate evaluation of the infarcted and viable myocardium is essential. It can be safely decided whether there is a need for revascularization, so as to avoid any unnecessary interventions. Administration of a contrast agent is not necessary if the goal of the examination is to assess ventricular function and to look for wall motion disorders. Implementation and evaluation of the examination without proper expertise can lead to significant diagnostic errors.

Implementation

Cardiovascular MRI is specifically optimized for cardiac imaging, and with it we can examine the morphology and function of the heart, and various heart diseases. Cardiovascular MR imaging is often considered a challenge, because it requires complex planning which is due to cardiac and respiratory motion, and the unique anatomical position of the heart.

In CMR imaging dedicated cardiac coils or body surface coils (phased array body/torso coil) are used, which support parallel imaging. (I.140. ábra)

Dedicated cardiac coil (1.5T and 3T)

Cardiac images free from motion artifacts are possible by a combination of ECG triggering (to compensate for cardiac motion) and either respiratory triggering or navigator echoes to eliminate breathing artifacts. Synchronization of the data occurs with MR-compatible ECG chest electrodes and synchroni-

zation takes place on the R wave. It is advisable to use a vectorcardiogram (VCG), which models the heart's electrical activity in the form of vectors. During the cardiac cycle, the vectors of the P, QRS and T waves appear in different locations. The triggering algorithm detects the heart's electric activity in space, and since the above mentioned vectors originate separately from each other, false T-wave triggering cannot occur. (I.141. ábra)

Figure I.140. X

Typical ECG placement on the body

ECG gating and electrode placement: The skin should be cleaned well in order to acquire good quality images and to avoid skin burns. It is desirable to use a special gel under the electrode pads. (Do not use alcohol because it dries the skin, so it can deteriorate the electrical leads). Use only MR-compatible (carbon) electrodes. The examination is carried out in expiration. The duration of the breath hold is approximately 10-14 seconds per slice.

Figure I.141. X

I. Acute myocardial infarct

1. Imaging of left ventricular morphology and function
2. Optional – dark blood T2-weighted imaging for the assessment of edema
3. Resting first-pass perfusion imaging
4. For the assessment of microvascular obstruction, after the first pass perfusion, delayed contrast enhanced images, 2-3 minutes after contrast administration, have to be acquired.

II. Chronic ischemic heart disease and viability

1. Imaging of left ventricular morphology and function
2. Optional – adenosine stress and rest perfusion or high-dose dobutamine stress test to rule out or confirm ischemia
3. Delayed contrast imaging
4. Optional – low-dose dobutamine stress test (dobutamine infused i.v. for 5-10 min at 10 mg/kg⁻¹ min⁻¹ for the assessment of contractile reserve or wall motion improvement)
5. Analysis:
 - a. It is important to evaluate the cine and contrast delayed images side by side
 - b. If there is wall motion abnormality, the existence, lack and extent of late contrast enhancement must be described

CMR sequences**1. Assessment of left ventricular morphology and function**

1. Localizer images in transverse, sagittal and coronal planes (*Figure I.142.*)
2. Transverse (slice thickness 8-10 mm), whole chest, ECG-triggered steady-state free precession (SSFP) or half Fourier TSE images
3. Localizer images – SSFP cine or single-shot
 - a. two chamber (2CH – vertical long-axis), which crosses the left ventricular apex and the mitral valve
 - b. four chamber (4CH – horizontal long-axis), which crosses the middle third of the mitral valve, the left ventricular apex and the largest diameter of the right ventricle
 - c. left ventricular outflow tract (3CH – LVOT), which crosses the middle third of the mitral valve, the left ventricular apex and the aortic root

Figure I.142. Transverse, sagittal, coronal localizer images and slice planning

4. SSFP short-axis cine images – from the mitral valve to the apex
 - a. slice thickness: 6-8 mm, continuous
 - b. throughout the heart cycle, with a time resolution of up to 45 ms.
 - c. if it is possible, use parallel imaging (SENSE, GRAPPA) with an acceleration factor of 2. (*Figure I.143.*)
5. Long-axis SSFP cine images
 - a. four chamber (4CH), which crosses the middle third of the mitral valve, the left ventricular apex, the inferior septum and the anterolateral wall
 - b. two chamber (2CH), which shows the anterior and inferior wall of the left ventricle
 - c. three chamber (3CH) - left ventricular outflow tract (LVOT) image, which shows the anterior septum and the inferolateral wall. (*Figure I.144.*)
6. Analysis (evaluation)
 - a. planimetric determination of the epicardial and endocardial contours in all end-systolic and end-diastolic short-axis images
 - b. during the determination of left ventricular muscle mass, special attention should be paid to the papillary muscles
 - c. because of left ventricular systolic contraction, careful attention should be paid to the movement of the base of the heart (the slice, on which the base of the left ventricle is visible in diastole, will depict the left atrium in systole)

Figure I.143. SSFP short-axis image

Figure I.144. Long-axis SSFP images (4CH, 2CH, 3CH)

2. First pass perfusion imaging

1. Localizer images as described above
2. Saturation recovery imaging with GRE-EPI hybrid or GRE or SSFP sequences
3. Short-axis images (acquisition of at least 3 slices per heartbeat)
 - a. for the assessment of ischemia, for every heartbeat, three images have to be acquired (after short-axis positioning, we have to take images of the basal, middle and apical third of the left ventricle)
 - b. slice thickness: 8 mm

- c. parallel imaging with an acceleration factor of 2 (if possible)
 - d. image resolution (within slices): 2-3 mm
 - e. read-out time (readout phase): 100 - 125 ms or shorter if available
 - f. contrast medium (0.05 - 0.1 ml/kg, with a flow of 3-5 ml/sec) which is followed by a minimum of 30 ml of saline flush (3-7 ml/sec)
 - g. the breath hold begins in the early contrast phase and will last at least until the contrast material appears in the left ventricular musculature
 - h. the images are acquired (until the contrast agent leaves the left ventricle musculature) for at least 40-50 cardiac cycles. (Figure I.145.)
4. Analysis
- a. a proper evaluation of heart morphology is based on the 16-segment model of the American Heart Association (AHA)
 - b. A significant perfusion defect can only be diagnosed if the contrast material uptake deviation of the muscle is observed in at least 5 consecutive heartbeats. The evaluation of segmental contrast uptake is required in each of the 16 segments.

3. Delayed-enhancement imaging

1. After administration of contrast material (0.15-0.2 mmol/kg), wait for at least 10 minutes. If you use a lower dose, the wait time may be shorter, as the signal intensity of blood will decrease compared to that of contrast filled heart muscle.
2. 2D segmented inversion recovery GRE images – acquisition occurs in diastole (when the heart does not move)
3. The test planes are the same as those used for the long and short-axis planes when imaging left ventricular function
4. Slice thickness is the same as in cine imaging
5. Image resolution (in slices): ~ 1.4-1.8 mm
6. Acquisition time: 200 ms, but this should be shortened in tachycardia
7. Inversion time is zeroed to normal myocardium. When using the phase sensitive inversion recovery sequence, a fixed inversion time may also be used. (Figure I.146.)
8. The read-out usually occurs at every second heartbeat. In case of bradycar-

Figure I.145. First-pass perfusion sequence and slice planning

Figure I.146. TI Scouting (Look-Locker) images, (zero at the time of 286 ms)

Figure I.147. Late scar-weighted images (4CH, 2CH, 3CH)

dia (< 50/min) every heartbeat, and in tachycardia or arrhythmia every third heartbeat can also be used for imaging.

9. Optional
 - a. use the SSFP readout if there is abnormal heart rhythm or the patient has difficulties breathing
 - b. 3D sequence in conjunction with parallel imaging is an advantage
10. analysis
 - a. evaluation according to the AHA 17 segmentum model
 - b. assessment of the amount of delayed contrast (transmural extent of delayed hyperenhancement) is required for each segment, (0%, 1–25%, 26–50%, 51–75%, 76–100%). (Figure I.147.)

4. Tools of stress perfusion imaging and safety measures

Devices:

1. monitoring devices (blood pressure, ECG, patient symptoms)
2. if the patient feels unwell, remove her from the vicinity of the magnet (preparation and training)
3. defibrillator
4. emergency drugs
 - a. immediate access: beta-blockers - metoprolol or esmolol, nitroglycerin and aminophylline
 - b. in the emergency box – emergency drugs
 - c. Dobutamine stress - for online assessment of left ventricular wall motion

Stress drugs:

Dobutamine HCl concentration – 5 mg/ml recommended, intravenously

Atropine – 0.25 mg, in fractions (maximal dose of 2 mg)

Adenosine (Adenoscan) concentration – 30 ml bottle – dose of 140 µg/kg/min

Contraindications:

1. Dobutamine
 - severe hypertension ($\geq 220/120$ mmHg)
 - unstable angina pectoris
 - significant aortic stenosis (aortic valve gradient > 50 mmHg or valve opening $< 1\text{ cm}^2$)
 - complex arrhythmias
 - obstructive cardiomyopathy with hypertrophy
 - myocarditis, endocarditis, pericarditis
2. Adenosine
 - diseases with bronchospasm
 - AV block (second or third degree)
 - sinus bradycardia (< 45 bpm)
 - systemic hypotension (< 90 mm Hg)

Patient preparation:

1. stress testing consent form
2. informing the patient about drugs and nutrients that have to be avoided 24 hours prior to the test

Dobutamine: beta-blockers and nitrates

Adenosine: caffeine (coffee, tea), theophylline

3. fasting is not required prior to testing

Possible side effects:

High-dose of dobutamine – chest pain, palpitations

More severe complications occur in 0.25% of cases:

- infarct (0.07%)
- ventricular fibrillation (0.07%)
- sustained ventricular tachycardia (0.1%)

Adenosine may cause warmth and chest pain.

More serious complications:

- cardiac conduction disorders – blocks
- sinus tachycardia
- bronchospasm

4. a. Dobutamine stress perfusion MRI

1. Imaging of left ventricular morphology and function
2. Administration of Dobutamine every 3 minutes with an increase of 10 µg/kg until the target heart rate is reached. Atropine is given if the target heart rate (150/min) is not reached even after administration of 40µg Dobutamine.

Images: After every dose increase, three short and three long axis SSFP cine images have to be taken. Every cine image should be observed "online". The Dobutamine administration should be stopped if wall motion abnormality or serious adverse events are observed or if the heart rate reaches 150 beats/min.

3. Analysis
 - a. It is important to display the synchronized resting and stress cine images simultaneously.
 - b. Wall motion disorder have to be judged in all 17 segments (normokinetic, slightly hypokinetic, severely hypokinetic, akinetic and dyskinetic).
 - c. Ischemia and viability assessment is important.

4. b. Adenosine stress perfusion MRI

1. Imaging left ventricular morphology and function
2. Two venous catheters (in both arms) have to be used; one is for the contrast agent, and the other one is for the administration of adenosine. The sphygmomanometer must not be inflated during administration of medication.
3. Adenosine stress perfusion (at least 3-4 min with a dose of 40 µg/kg/min).
 - a. first pass perfusion imaging
 - b. contrast medium (0.05 mM/kg) during the maximal effect of adenosine
 - c. imaging – through 40-50 cardiac cycles (until the contrast material leaves the left ventricular musculature), afterwards the administration of adenosine is stopped.
4. Resting perfusion
 - a. 10 minutes after stress perfusion (after contrast agent wash-out). During this period, a detailed analysis of cardiac function can happen.
 - b. First-pass perfusion imaging
 - c. If a discrepancy is not detected during stress perfusion, then we give the remaining contrast agent to achieve delayed enhancement (total of 0.15 – 0.2 mM/kg)
5. Delayed-enhancement imaging
 - a. Wait at least 5 minutes after the last administration of contrast material.
6. Analysis
 - a. 17-segment AHA model (16-segment model without the apex)
 - b. It is important that the cine, perfusion and delayed contrast images are displayed simultaneously.

III. Imaging of anomalies of the coronary arteries

1. Imaging left ventricular morphology and function; assessment of wall motion abnormality.
 - a. High time resolution (20 ms), 4 chamber images for assessing the RCA
2. Navigator-triggered, free-breathing 3D MRA sequence
 - a. axial slices are located between the proximal pulmonary trunk and the diaphragm
 - b. slice thickness: 1-1.5 mm, resolution: 1 mm
 - c. slice number: typically 50-80, according to the examined blood vessels
 - d. parallel imaging is an advantage
 - e. navigator is placed on the middle of the right diaphragm
 - f. optional: contrast agent for better visualization of vessels
3. Optional
 - a. breath hold technique when the image quality is not good, or there is no navigator
 - b. T2-prepared sequence

IV. Examination of pulmonary veins (before and after ablation)

1. Imaging left ventricular morphology and function; assessment of wall motion abnormalities. (before ablation)
2. Breath-hold, non-ECG-triggered 3D contrast MR angiography, in the coronal plane. Angiographic images should include the left atrium and pulmonary veins (optional oblique planes can be used)
 - a. Gd complex (0.1-0.2 mM/kg), with a flow of 2-3
 - b. 3D slab thickness: 6-7 cm; slice thickness: 1-1.5 mm
 - c. slices: 60-80
 - d. if possible, use parallel imaging (use multi-channel phase array coils)
 - e. acquisition time: typically 15-18 seconds in multiple breath-holds, acquisition of 2-3 3D slabs (control, maximum contrast, late phase)
3. Optional flow measurement in the pulmonary veins.
4. Analysis

Evaluation of contrast angiography begins with viewing all coronal slices. The following have to be determined: number of pulmonary veins; presence of common orifices and anomalous veins; existence and extent of possible pulmonary vein stenosis; possible presence and extent of a thrombus. For evaluation, a 3D workstation is necessary. Furthermore, comparison of pre-and post-ablation MRA images is also required.

V. Non-ischemic left ventricular myocardial diseases and myocarditis

1. Left ventricular structure and function.
2. T2-weighted "dark blood" MRI in case of necrosis and edema (eg.: recent myocardial infarct or myocarditis)
 - a. breath-hold, TSE MR images with double inversion pulse (dark blood MRI)

- b. the morphological images are acquired before contrast administration
- c. in cine mode, the selected MRI slices: 2CH, 4CH, LVOT, true short-axis
- d. slice thickness: 8 mm

3. Delayed-contrast imaging

4. Analysis

It is important to identify patterns and to determine predilection sites.

5. Optional: adenosine stress – rest perfusion MRI or high-dose dobutamine stress functional MRI (see stress protocol) to assess mixed cardiac diseases, such as coronary artery disease and myocarditis
6. In case of hypertrophic cardiomyopathy, short-axis LVOT and LVOT examinations also have to be carried out.

VI. Arrhythmogenic right ventricular dysplasia ARVD/C

1. Imaging left ventricular structure and function: 5-6 mm slice thickness
 - a. determination of left and right ventricular function; examination of the volume curves
2. SSFP MRI cine images in the whole right ventricular short-axis, and in the right ventricular outflow tract planes
3. Optional sequences
 - a. selected short and RVOT planes "dark blood" imaging (TSE)
 - b. repeated fat saturated images
 - c. delayed-enhancement images (T1 phase zero on the right ventricle wall)

Cardiac MRI can add one major and one minor criterium (right ventricular dilatation, right ventricular free wall dyskinesia, or aneurysm) to the McKenna conventional criteria. The recommendations do not consider either the presence of transmural fat or right ventricular delayed contrast as criteria.

VII. Valve disorders

Patients with a prosthetic valve can be safely imaged with a 1.5T or a 3T MRI.

1. Imaging left ventricular morphology and function; the assessment of wall motion abnormality.
 - a. 4CH images – for the assessment of valve anatomy as well as the observed turbulence on the mitral and the tricuspid valves
 - b. LVOT images – for the assessment of the mitral and the aortic valves
 - c. 2CH images – for examination of the mitral valve
 - d. coronal images – for examination of the aortic valve
 - e. other planes for examining the longitudinal axis of the right ventricle, the right ventricle outflow tract, and movement of the pulmonary valve

2. Optional
 - a. valve morphology with SSFP sequence (the diseased valve). The valve should be imaged.
 - b. GRE or hybrid EPI MRI shows flow disturbances and regurgitation with high sensitivity
3. Measurement of flow and volume distal from the valve (phase contrast MRI sequence).
 - a. optimal setting of velocity encoding is essential
 - b. TE should be as short as possible
 - c. velocity values are normalized to the static reference tissue
4. Analysis
 - a. determination of left and right ventricular volume and assessment of valve regurgitation
 - b. mitral regurgitation is easily assessed by the difference of left ventricular stroke volume calculated from left ventricular volume and aortic flow measurements.
 - c. in case of multiple valve disease, mitral and tricuspidal regurgitation are also easily assessed by the aortic and the pulmonary anterograde and retrograde flow/volume and the left and right ventricular stroke volume
 - d. aortic valve opening area calculations

VIII. Pericardial diseases

1. Imaging left ventricular morphology and function; assessment of wall motion abnormality.
2. T1 and T2 – weighted TSE images;
 - 2-3 representative long-axis and 2-4 representative short-axis images. In case of a pericardial cyst, the examination should be carried out according to *the lesions and masses protocol* (see section IX. below).
3. Optional – if the pericardial wall is thick – T1-weighted GRE tagging cine MRI for the assessment of epicardial/pericardial displacement.
4. Optional, but if it is available, it must be carried out – short-axis real-time imaging, during respiratory maneuvers.
5. Delayed-enhancement images

IX. Heart masses, and masses surrounding the heart

1. Imaging left ventricular morphology and function; assessment of wall motion abnormalities.
2. T1-weighted TSE sequence
3. T2-weighted fat saturated TSE sequence (see also non-ischemic heart disorders).
4. First-pass perfusion images (the slices should cover the mass as well)
5. Repeated T1-weighted TSE sequence
6. Optional – after contrast administration, repeated SSFP cine images
7. Delayed-enhancement images

X. Congenital heart diseases

In all cases:

1. Imaging left ventricular morphology and function
 - a. transverse SSFP cine images from the aortic arch to the inferior wall (diaphragma level)
 - b. gradient echo cine images or hybrid GRE/EPI MRI can improve the assessment of turbulence
2. Localizer images at the region of the ascending aorta and the pulmonary artery.
3. Qp and Qs flow measurements transversely to proximal end of the aorta and the pulmonary artery; in perpendicularly inserted slices; velocity encoded (phase) cine MRI.
4. MRA following a fast, dynamic 3D contrast bolus in the coronal plane.

Specific diagnoses need special protocols.

1. For shunt assessment
 - a. velocity encoded cine images in the plane of the shunt and perpendicular to it
2. For lesions that involve major blood vessels
 - a. SSFP cine MRI in a parasagittal plane with the aorta
 - b. assessment of valve function (see valve diseases)
 - c. SSFP cine or GRE MRI and velocity encoded cine images on the pulmonary branches

I.14. Magnetic resonance imaging of the breast

Traditionally, X-ray and ultrasound have been the main diagnostic tools for breast imaging due to their worldwide availability, ease of use, adequate sensitivity, and short acquisition times. However, with the development of new software and hardware, modern MRI emerged as a key diagnostic tool with the highest sensitivity and specificity. Multiple imaging contrast, better soft tissue differentiation, higher resolution, and the safer nature of MR imaging make breast MR one of the fastest growing imaging modality, especially for high-risk patients.

In women of reproductive age, MR imaging must be performed at the second week of the menstrual cycle (within 7-14. days), because the menstrual cycle and hormonal effects can influence test results.

During dynamic measurements, the patient is given an intravenous contrast material. Therefore, an intravenous line must be inserted, preferably in the antecubital vein, before the start of the examination. An extension tube is used to connect the intravenous line with the injector while the patient is positioned in the MRI system. The dose of the contrast agent gadolinium is 0,1-0,2 mmol/kg, which is washed in with 20 ml of saline.

MRI must be performed with the patient lying in a prone position. It is recommended that the arms be placed alongside the body. For small breasts, cushion the inside of the coil with some padding (this reduces motion artifacts). The coil center should align with the center of breast for females and with the nipple for male patients. Breast MR imaging should be done using multichannel or multielement coils for better SNR. Centering is on the coil's mark. (Figure I.148.) (Figure I.149.)



Figure I.148. Breast Coil

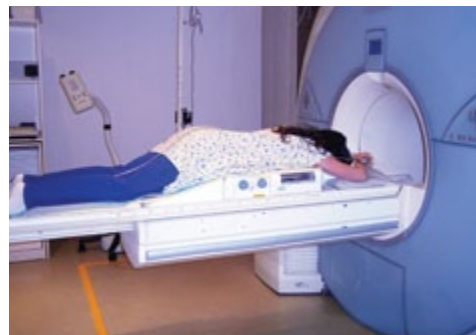

Figure I.149. Breast examination and patient positioning

Video: Positioning for breast MRI scan

http://tamop.etk.pte.hu/tamop412A/Kepalkotasi_gyakorlatok_tananyag/MR/VIDEO_MR_GYAK/EMLO_FINAL.wmv

Indications

- searching for an occult primary tumor and metastases
- preoperative tumor staging
- screening high-risk patients
- chemotherapy follow up
- implant status assessment

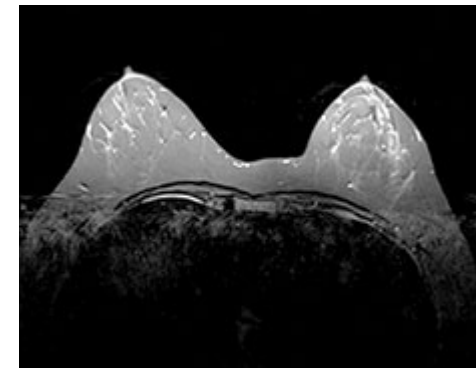
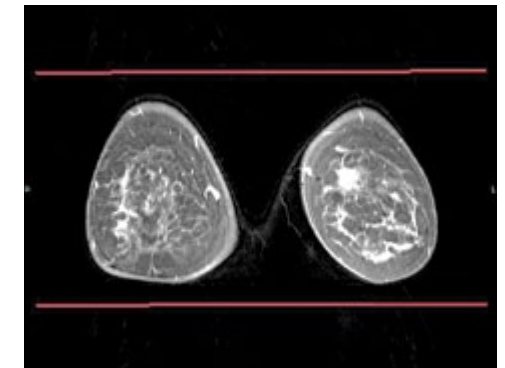
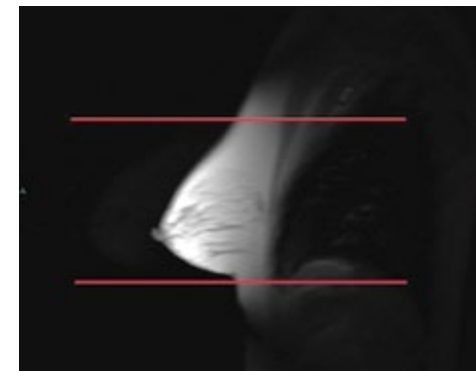


Figure I.150. Axial plane



Figures I.151. Positioning of the axial slices



Figures I.151. Positioning of the axial slices

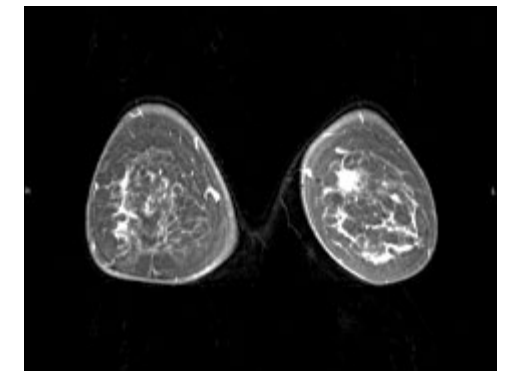


Figure I.153. Coronal plane

Recommended sequences:

- T2 STIR - axial
- T1 GRE - axial
- Dynamic contrast enhanced T1 - axial
- Contrast enhanced T1 FS - coronal or sagittal

Imaging planes

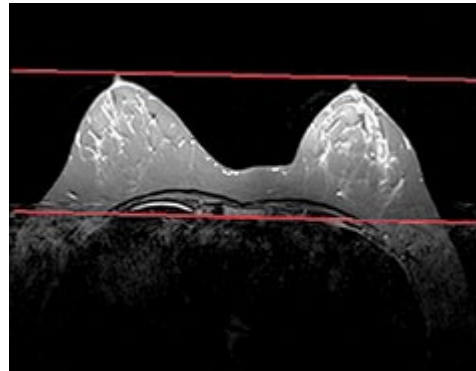
Plan the axial plane on the sagittal images perpendicular to the sternum, and, parallel to the line connecting the breasts on the coronal images. (Figure I.150.) (Figures I.151., I.152.)

Tilt the coronal plane parallel to the sternum and perpendicular to the breasts. (Figure I.153.) (Figures I.154., I.155.)

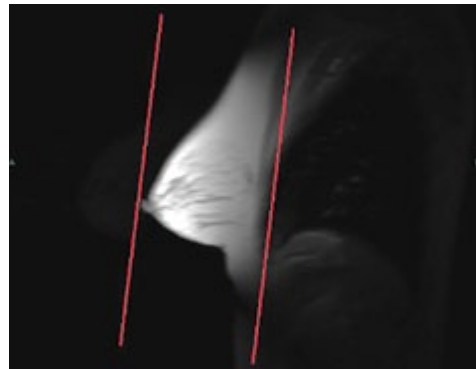
Postprocessing

Dynamic breast imaging can provide a great deal of information, especially for mass-like lesions. The dynamic imaging series includes at least one T1 precontrast image and several T1 postcontrast images acquired during contrast injection. The lesion's signal enhancement within the first 2 minutes, and the following signal enhancement pattern can be used to classify the contrast enhancement into different types. The image processing software can be used to create and display contrast enhancement curves.

The combined use of breast MR images and image processing software can make lesion detection and quantification much more efficient. A number of different post-



Figures I.154. Positioning of the coronal slices



Figures.155. Positioning of the coronal slices

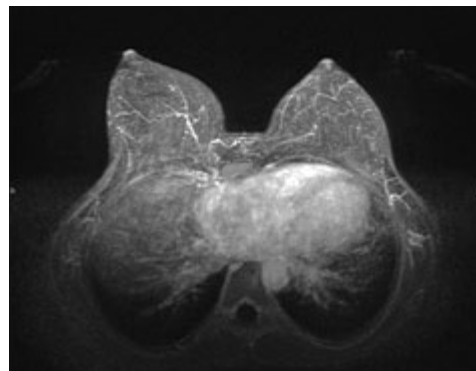


Figure I.156. Substraction

processing software can be used to display signal enhancement curves in absolute values or as percentages, and also wash-in and washout signal changes. (Figure I.156.)

Multiple contrast imaging of masses or non-mass-like breast lesions are very important. However, dynamic contrast enhanced breast MRI can provide a great deal of information about the type and characteristics of lesions (benign: slow "wash in" – plateau phase – slow "wash out"; or malignant: fast "wash in" at 3 minutes - fast "wash out").

Here is where the importance of the menstrual cycle comes in, because if the examination is carried out in a bad week, that may result in false malignant or false benign lesions. However, there are exceptions, some malignant lesion may have characteristics of benign masses, and vice versa (adenomatous fibroadenoma, medullary carcinoma). An accurate diagnosis is only possible after biopsy!

Probably all invasive breast cancers and the majority of intraductal carcinomas are associated with increased vascularization due to tumor angiogenesis. MRI allows the visualization of breast cancer because these tumors are associated with signal enhancement after peripheral administration of a contrast material. Thus, MRI gives information on the hemodynamics as well as the morphologic aspects of a tumor.

Quiz

1. **For an MR examination of the shoulder it is optimal to use a**
 - A dedicated shoulder coil
 - B flex coil
2. **During positioning for a shoulder MR examination, centering is done to the mark on the coil, which coincides with the**
 - A olecranon
 - B head of the humerus
3. **When planning a shoulder MR examination the paracoronal plane is tilted on the axial slices.**
 - A parallell to the supraspinatus muscle
 - B perpendicular to the supraspinatus muscle
4. **The patient's hand is during an elbow MR examination.**
 - A supine
 - B prone
5. **In case of a wrist MR examination the coronal plane is tilted to the carpal tunnel (Guyon) on transversal slices, and it is to the bones of the forearm and the metacarpal bones on sagittal slices.**
 - A perpendicular/parallell
 - B parallell/parallel
6. **For a knee MR examination you center to the end of the patella, which concides with the popliteal fossa.**
 - A proxymal
 - B distal
7. **In case of a knee MR examination the sagittal plane is tilted to the posterior edges of the femoral condyles on transversal slices.**
 - A perpendicular
 - B parallell
8. **In case of an ankle MR examination the sagittal plane is to the line connecting the lateral and medial malleoli on transversal slices, and to the tibiotalar joint on coronal slices.**
 - A perpendicular
 - B paralell
9. **For a humerus, elbow or forearm MR, you should position the patient so that**
 - A his arm is as far as possible from the midline of the table.
 - B his arm is as close as possible to the midline of the table.
10. **In women of reproductive age, breast MR imaging must be performed, because hormonal effects may influence test results.**
 - A during the second week of the menstrual cycle (between the 7-14. days)
 - B at the fourth weekof menstrual cycle (within 22-28. days)
11. **Contrast enhancement of breast parenchyma can be assessed on T1 weighted images. From the acquired data enhancement curves can be generated. Fast "wash-in" and fast "wash-out" are characteristic of**
 - A benign lesions
 - B malignant lesions
12. **In case of a cervical soft tissue MR examination, the most useful sequence is STIR, because on these images, tumours, inflammation and other diseases appear and thus they can be easily differentiated from surrounding tissues.**
 - A hypointens
 - B hyperintens
13. **The signal to noise ratio of dedicated extremity coils is better than that of flex coils, that is why for extremity and joint MR examinations these coils should be chosen.**
 - A True
 - B Fals
14. **In case of a joint MR examination T1 is the most important sequence, because on this sequence the capsule itself and any intracapsular fluid can be well visualized.**
 - A True
 - B False

15. **One of the indications of a hip MR examination is carpal tunnel syndrome.**
A True
B Flase
16. **In case of a hip MR examination the transversal plane is perpendicular to the axis of the body (parallel to the line connecting the two hip joints), and the upper edge is above the hip joint while the lower edge is at the height of the greater trochanters.**
A True
B Flase
17. **On sagittal knee MR images the PLC is well visualized, while the location of the ACL is less obvious.**
A True
B False
18. **MR is the primary screening method of breast cancer.**
A True
B False
19. **Breast MR is suitable for assessing breast implants.**
A True
B False
20. **Perfusion curves made from data that were acquired during breast MR are specific for benign and malign lesions. Therefore breast MR can provide an accurate pathological diagnosis.**
A True
B False
21. **The radiation safety officer of the radiology department is the same as the MRI safety officer.**
A True
B False
22. **Since MR imaging has no proven long term harmful effects, this modality is safe for both radiographers and patients.**
A True
B False

23. **For radiographers working with MR, the and the effects of cryogen fluids are risk factors.**
A strong magnetic field
B ionizing radiation
24. **The kinetic speed of the body may influence the magnitude of the induced current.**
A True
B False
25. **Due to the static magnetic field, the radiographer may experience biological effects.**
A temporary
B durable
26. **The most dangerous zone in the MR examining room is the so called controlled zone where the magnetic field is than 0,5 mT.**
A smaller
B greater
27. **During MR examinations implanted metals may get warm or even move.**
A True
B False
28. **It is prohibited to take ferromagnetic metals into the MR examining room.**
A True
B False
29. **The most important biological effects of the alternating gradient fields are, muscle stimulation, and acoustic noise.**
A central nerve stimulation
B periferial nerve stimulation
30. **Electric currents induced by the alternating gradient fields may affect nerves and/or muscle fibers.**
A True
B False

31. Increase of the core body temperature by 1°C is acceptable for healthy humans, however a greater increase may cause harmful effects in patients and radiographers, particularly those with cardiovascular disease.
- A True
B False
32. Contact burn injuries may occur during, if the patient's skin is in contact with metal objects, coil cables, etc.
- A alternating gradient fields
B RF excitation
33. The Specific Absorption Rate (SAR) limits the energy admissible by the body during the MR examination between 10 Wkg⁻¹ and 40 Wkg⁻¹
- A True
B False
34. Under normal operational circumstances, the liquid cryogen gases that are used for the supramagnetic bores are not dangerous.
- A True
B False
35. During quenching the energy of the static magnetic field is converted into heat, therefore much of the liquid helium and sodium
- A freezes
B evaporate
36. A magnetic quench may cause in those who are in the examination room.
- A dysphagia
B asphyxia
37. It is important that the patient gives a statement about contraindications before the MR examination.
- A verbal
B written
38. Routine MR examinations (eg: head, spine, joint) do not require specific preparations or diet.
- A True
B False

39. Depending on the region of interest it is advisable to remove all jewelries and clothes in order to avoid loss of image quality.
- A True
B False
40. For women it may be necessary to remove make-up because cosmetics may contain metal that can cause artifacts.
- A True
B False
41. As a rule of thumb, MR imaging is contraindicated within 6 weeks after implantation of all implants.
- A MR compatible
B MR compatible and non-compatible
42. Pregnancy is basically a contraindication of MR imaging, because based on current data, the electric magnetic field (between 0.1 T and 3 Tesla) poses no harm to the fetus.
- A True
B False
43. When positioning for a cervical spine MR examination, centering is done to the mark on the coil, which coincides with the
- A jugular fossa
B thyroid cartilage
44. In case of a spine MR examination, planning of the axial slices is done on the images.
- A sagittal
B coronal
45. In case of disc herniation the axial plane is set according to the
- A angular off-set of the discus
B myelon
46. When scoliosis is present, the axial slices are planned
- A only on the sagittal images
B on both the sagittal and the coronal images taking the angular off-set of the discus into consideration.

47. For a spine MR examination contrast material administration is not necessary.
A True
B False
48. In case of an abdominal MR exam the patient should not eat before the examination.
A 4-6 hours
B 6-8 hours
49. In case of an abdominal MR exam we place the on the patient to monitor his breathing.
A respiratory sensor
B ECG electrodes
50. On the out-of-phase abdominal MR images the intensity of fat containing areas iscompared to the in-phase images.
A higher
B lower
51. On MRCP images fluid in the bowels has signal intensity.
A high
B low
52. In case of an abdominal MR examination we do not give oral contrast to the patient.
A True
B False
53. We plan the slices on the sagittal images during a head MR examination. The slices are parallel to the line connecting the anterior commissure (AC) and the posterior commissure (PC).
A axial
B coronal
54. In case of a head MR examination we plan the coronal slices on the sagittal images perpendicular to the line connecting the anterior commissure and the posterior commissure. Optimally, this plane is identical to the and the pons-midbrain plane.
A aqueduct plane
B frontobasal plane

55. During a head MR exam the most common indication for liquor pulsation imaging (CINE MR) is
A epilepsy
B hydrocephalus
56. During MR imaging of the orbits, if the patient has EOP, using it is possible to measure the water content of the rectus muscles.
A T2 relaxometry
B out of phase measure
57. For imaging the temporo-mandibular joint the head coil provides the best temporal resolution.
A True
B False
58. During a chest MR examination the navigator echo is placed on the diaphragm
A on the right
B on the left
59. If the patient has a Starr-Edwards prosthetic valve and/or a MR is contra-indicated.
A biological prosthetic valve
B pacemaker
60. The lungs cannot be imaged with MR, due to their low proton content.
A True
B False
61. During MR imaging of the pelvis a urinary bladder smoothes out the angulation between the cervix and the corpus uteri by slightly lifting the uterus.
A half-filled
B fully-filled
62. During a pelvis MR exam planning of the axial slices is done on both the coronal and the images.
A sagittal
B longitudinal

63. In case of a pelvis MR exam the coronal slices are planned from the abdominal wall to the

- A rectum
- B gluteal region

64. When using the endocavital coil the FOV is cm.

- A 14-16
- B 20-22

65. In pelvis MR imaging we use the intracavital coil only for prostate imaging.

- A True
- B False

66. The basic principle of TOF (time-of-flight) is that it can differentiate the of static and moving tissues.

- A signal amplitude-differences
- B signal phase-differences

67. In 2D TOF MRA the signal of static tissues is saturated using a

- A long echo time
- B short repetition time

68. We can image the vessels of the neck, chest and abdomen, and the aortic arch using

- A PC MRA
- B CeMRA

69. If there is turbulent flow we do not get any information about the vessels with MRA.

- A False
- B True

70. 3D TOF MRA is not carried out after intravenous contrast administration.

- A True
- B False

71. The saturation band is used in 3D TOF MRA.

- A True
- B False

72. The endocavital coil is a coil.

- A Phased array
- B Surface

73. The endocavital coil is suitable for examining the prostate.

- A True
- B False

74. The endocavital coil is suitable for examining the uterus.

- A True
- B False

75. The TMJ may be visualized with the highest temporal resolution using a surface coil.

- A True
- B False

76. For abdominal MR breath-hold measurements are used.

- A True
- B False

77. During abdominal MR we can make dynamic post-contrast measurements.

- A True
- B False

78. After surgery of a herniated disc, a contrast material has to be use.

- A T1-weighted
- B T2-weighted

79. We can visualize the whole spine in one FOV.

- A True
- B False

80. During cervical spine MR the motion artifact that is caused by swallowing may be decreased by using the saturation band.

- A True
- B False

81. The pulsation artifact may arise during thoracic spine MR.

- A True
- B False

82. The respiratory artifact may arise during thoracic spine MR.

- A True
- B False

83. Lumbar spine MR examinations are carried out in breath-hold.

- A True
- B False

84. In case of a magnetic quench injury may occur in those who are in the examination room.

- A freezing
- B burning

85. Increase of the core body temperature by 10°C is acceptable for healthy humans, however a greater increase may cause harmful effects in patients and radiographers, particularly those with cardiovascular disease.

- A True
- B False

Solutions

- | | | |
|-------|----------|-------|
| 1. A | 30. A | 59. B |
| 2. B | 31. A | 60. B |
| 3. A | 32. B | 61. A |
| 4. A | 33. B | 62. A |
| 5. B | 34. A | 63. B |
| 6. B | 35. B | 64. A |
| 7. A | 36. B | 65. B |
| 8. B | 37. B | 66. B |
| 9. B | 38. A | 67. B |
| 10. A | 39. A | 68. B |
| 11. B | 40. A | 69. A |
| 12. B | 41. B | 70. B |
| 13. A | 42. B | 71. A |
| 14. A | 43. B | 72. B |
| 15. B | 44. A | 73. A |
| 16. B | 45. A | 74. A |
| 17. A | 46. B | 75. A |
| 18. B | 47. B | 76. A |
| 19. A | 48. A | 77. A |
| 20. A | 49. A | 78. A |
| 21. B | 50. B | 79. B |
| 22. B | 51. A | 80. A |
| 23. A | 52. B | 81. A |
| 24. A | 53. A | 82. A |
| 25. A | 54. B | 83. B |
| 26. B | 55. B | 84. A |
| 27. A | 56. A | 85. B |
| 28. A | 57. B | |
| 29. B | 58. A, B | |

II. CT

II.1. Principles of CT Imaging, radiation dose optimization

The essence of CT imaging is that the examined object's inner structure is calculable if we do measurements on it from different directions. Its basis is that the collimated, fan shaped x-ray beams derive from the x-ray tube, go through the examined object, and they are absorbed by detectors behind the object. The detectors detect the location and level of diminishment of the x-ray beams, in other words, their attenuation. The tube is moving in a 360° circle, perpendicular to the patient. The detected values make up the image (matrix) which consists of voxels. These voxels correspond to tissue attenuation. The position of the relative attenuation values are found in a table, called the Hounsfield-table. This table contains some fixed points: e.g.: water (0 HU), air (-1000 HU). Its range goes from about -1000 to +3000.

Table 1. Hounsfield values

Tissue	HU value
Bone	+500–1500
Water	0
Air	-1000
CSF	~ +15
Liver	~ +40-60
Soft tissues	~ +60 – -100
Blood	~ +50-60

The basic principle of CT was laid down in 1924 by Radon, although the first device was only operational in the early 70's. Nowadays, we can only find multislice CTs, which are naturally the product of a long technological development. The first scanners were able to operate only in sequential mode. In one full 360 degree rotation of the x-ray source, the scanner could acquire data only on 1 slice. Acquisition of the next slice commenced after the necessary table movement was carried out. These CTs gave place to helical devices in 1989 which are faster than their predecessors. In these devices, the table is moving continuously with a constant velocity during the examination. Later, dual-slice, then multislice CTs appeared on the market. Nowadays we can find CTs with up to 256 or even more detector rows, and dual-source CTs with two x-ray tubes. In the latter, the tubes are perpendicular to each other and with the help of both of these tubes, examinations can be carried out faster than before.

Parts of CT:

- high voltage generator
- gantry (http://tamop.etk.pte.hu/tamop412A/Kepalkotasi_gyakorlatok_tananyag/CT/CT_Videok/gantry_en.avi)
- patient table
- computer
- control panel

Dose optimization

Before carrying out CT examinations, we should always consider the risks of ionizing x-rays. We should cut down the examined region (FOV) and time to a minimum. A CT exam is contraindicated if the patient is pregnant (except, in case of vital indication) and it should be carried out only in select cases when the patient is a child or a newborn. If we have to exam several regions, we should cut down the dose to a minimum. An average person receives approximately a dose of 3,6 mSv every year, 80% of which comes from natural sources (water, food, atmosphere). 20% of it is derived from artificial ray exposition (smog, detectors) and medical usage – 60% of this derives from CT scans. A few examples to radiation dose can be seen in table 2.

Table 2 The radiation dose of different CT scans

Scan type	Radiation dose (mSv)
Chest CT	7
Head CT	2
Neck and head CTA	16.4
Neck CT	6
Coronary CTA	16
Abdomen CT	8
Abdomen- and pelvis CT	14
Pelvis CT	6

Dose reduction alternatives:

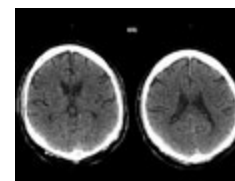
- kV reduction
- mAs reduction
- increasing slice thickness
- increasing the interval
- dismissing the non-enhanced series or acquiring it in low dose mode

- examining only the essential phases
- minimizing the examined region (FOV) and examination time; acquiring only carefully considered control scans; scanning in AEC (automatic exposure control) mode

Basic terms

- **kV**: tube voltage – a lower kV can enhance contrast in case of small or medium sized patients. The use of a high kV in big patients results in higher permeability that reduces image noise.
- **mA**: amperage – a higher mA improves the signal-to-noise ratio, therefore the image quality, but it also increases radiation dose received by the patient and the loading of the tube.
- **CTDIvol**: absorbed radiation dose - it determines the values of relative radiation received by the patient which fall into one slice. It is measured in mGy.
- **DLP**: the total amount of radiation exposure during a scan received by the patient. Calculation: CTDIvol × scan length. It is measured in mGy × cm.
- **Pitch**: table speed / collimation - pitch is a ratio, which shows the relationship between the speed of table movement and slice thickness.
- **Collimation**: reducing the collimation also reduces slice thickness, but the patient dose is not affected. (http://tamop.etk.pte.hu/tamop412A/Kepalkotasi_gyakorlatok_tananyag/CT/CT_Videok/kollimator-test_en.avi)
- **Filter (kernel)**: during the scan we have to do everything to reduce the radiation dose to the minimum where good quality images are still possible (ALARA) however, during this, a lot of measurement errors emerge. To solve this problem we use different kernels. Kernels are noise-canceling, or edge enhancing algorithms. With the use of various kernels the signal to noise ratio (SNR) can be improved, but the use of kernels come with a trade-off. Some density values, which are true values, are “cut off”, because they are deemed to be noise since they diverge so much from the surrounding tissue. The sharper kernel we use, the more useful information is removed from the image, so using kernels is at the expense of sharpness.

This can be seen in this animation:



[Animation II.1: Kernels](http://tamop.etk.pte.hu/tamop412A/Kepalkotasi_gyakorlatok_tananyag/CT/CT_Animaciok/kernel/index.html)

http://tamop.etk.pte.hu/tamop412A/Kepalkotasi_gyakorlatok_tananyag/CT/CT_Animaciok/kernel/index.html

More details on kernels can be found in the next chapter titled "CT image characteristics, post-processing".

- **FOV (field of view):** extent of the examined region.
- **Hounsfield values:** water: 0 HU, air: 1000 HU, bone: 400–1500 HU. The Hounsfield scale extends from –1000 to + 3000 HU.
- **Windowing:** The human eye can distinguish only a limited number of gray levels (from about 40 to 100, depending on viewing conditions). Consequently, there is no point in assigning the complete diagnostic range of CT numbers (some 4000 HU) to the available range of gray levels (from white to black) because discrimination between structures with small differences in CT numbers would no longer be possible. It is therefore better to display just a portion of the CT scale. This so-called window is defined by its width, which affects image contrast, and by its level (center), which determines image brightness.

According to their density, tissues are characterised as follows:

- hypodens: less dense than the surrounding tissue
- isodens: it is the same density as the surrounding tissue
- hyperdens: more dense than the surrounding tissue

In table 3. some window parameters can be seen:

Table 3.

Examined region	Window width (W)	Window center (C)
Brain	90-120	35-40
Neck	300	50
Lung	1500	–650
Liver	200	40
Bone	2000	500
Soft tissue	400	40

II.2. CT image characteristics, postprocessing

During computed tomography imaging, the x-ray beam, originating from the x-ray tube, passes through a thin axial section of the patient from various directions and it is picked up by detectors. The detector signals registered during a scan are preprocessed to compensate for inhomogeneities in the detector system and to correct for beam-hardening effects within the patient. After various correction steps and transformation from signal intensities into x-ray attenuation values, these data are called the CT raw data. The raw data consist of the attenuation profiles of some 500 to 2300 projections for each 360° rotation of the x-ray tube. Each projection in turn is composed of some 500 to 900 single attenuation values. Image reconstruction from the raw data set finally yields the image data set. Image reconstruction starts with the selection of the desired field of view. Each x-ray photon that passes through this field of view is used for reconstruction. The attenuation coefficient for each image point is determined by averaging the attenuation values for all x-ray photons that cross this point (back projection). But this type of unfiltered back projection yields a very unsharp image with blurred edges, therefore multiple rays are assembled into a projection, and the resulting attenuation profile is subjected to an edge-enhancing mathematical filtering (convolution) process. After the image appears on the display, we can modify it by windowing and (depending on slice thickness and collimation) we can reconstruct our data in another planes (such as paracoronal, parasagittal). Nowadays there are many available secondary reconstruction techniques, depending on what we wish to display.

Overall, it is true of all the secondary reconstruction techniques that they will give satisfactory results only if the image set which is generated during the primary image reconstruction – spatial matrix, which will be the basis of secondary reconstruction - meet certain criteria. In other words, we carry out the examination and generate primary images by taking the clinical data and the clinical question into account, and we must not forget which postprocessing techniques might be necessary during the evaluation of that examination. The primary images for postprocessing have to be acquired by observing the following criteria:

- Approximately isotropic voxel size. The axial image elements are usually, incorrectly, called image points or pixels, but they are voxels. If we want to precisely formulate the difference between the two, the pixel name is only used in 2D projection. The primary axial images are also made with determined (> 0) slice thickness, so they are not only displayed in the X and Y dimensions, but due to the extent of slice thickness, they are also displayed in the Z direction. But this will only gain importance during the postprocessing procedures. (Figures 1–2.)




Figure 1. 8 mm slice thickness

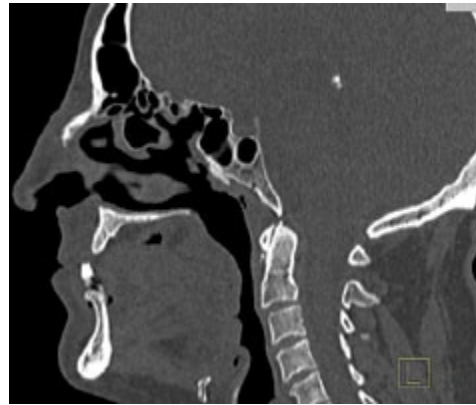

Figure 2. 1,25 mm slice thickness

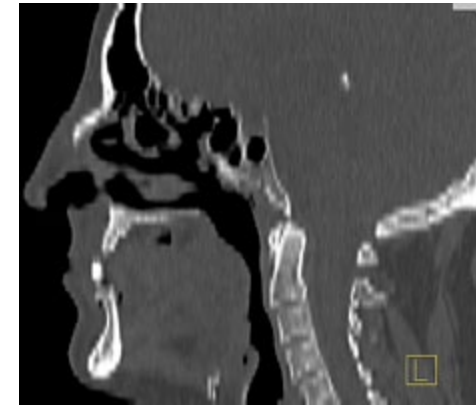

Figure 5. 3 mm increment

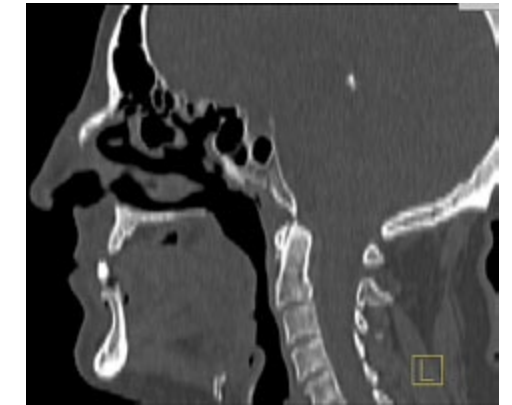

Figure 6. 2 mm increment

- The primary axial images must be acquired with a 1/3 overlap (for example, between two 3 mm thick slices there is a distance of 2 mm). This parameter is called reconstruction increment. This procedure is done after the measurement, so it has no radiation effect on the patient. Obviously, these techniques can only be used in the helical mode. (Figures 3–4.)

Newer imaging softwares use antialiasing algorithms, therefore the image quality will be much better, but it is still easy to see the difference. (Figures 5–6.)

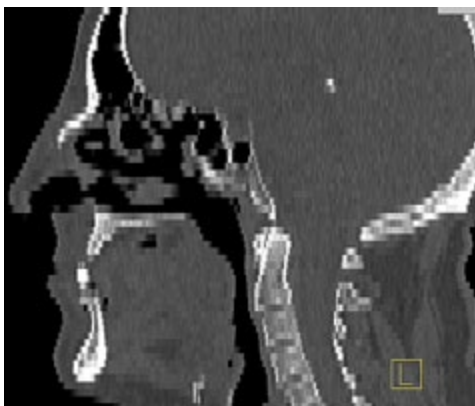


Figure 3. 3 mm increment

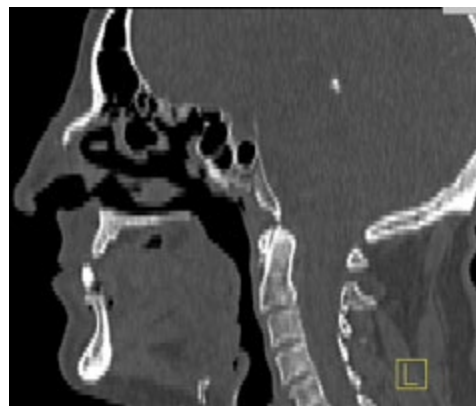

Figure 4. 2 mm increment

- Each postprocessing technique – which certainly depends on the software - are extremely sensitive to the kernel that is used to acquire the image. Generally, kernel, window width and slice thickness are interchangeable. The reason for this is image noise that comes from measurement errors. Since the examinations are carried out with the smallest possible dose to the patient, consequently a considerable amount of measurement error emerges and the kernel is meant to eliminate these errors. The softer the kernel is, the more aggressively it will cut off the prominent density differences. This process softens the image, therefore it also blurs it.

However, when using a wide window (bone or lung), the prominent density differences are smaller than the window width, therefore if a harder kernel is used, noise will not cause interference on the reconstructed image, however, due to a smaller noise cut, the resulting image will be much sharper.

We can also reduce the effects of measurement errors by acquiring thicker primary slices or by reconstructing thicker slices. Measurement errors are randomly generated during mapping, and it is unlikely that they will fall into the same voxels, thus they are averaged. Therefore, when using a smaller window width and a harder kernel, the average values of these errors will be smaller than the window width. Obviously, in this case, the thickness of the slice, or the thickness resulting from several adjacent planes will ruin sharpness, which can be compensated by harder kernels.

Let us take a look at the kernel – window width – slice thickness correlation with a few examples. First look at these images that were made with a cerebrum window and observe how changing the kernel and slice thickness affects the image quality: (Figure 7.)

Let us take a look at how the different window and kernel types affect image quality, while the slice thickness is kept at a constant 1.25 mm. (Figure 8.)

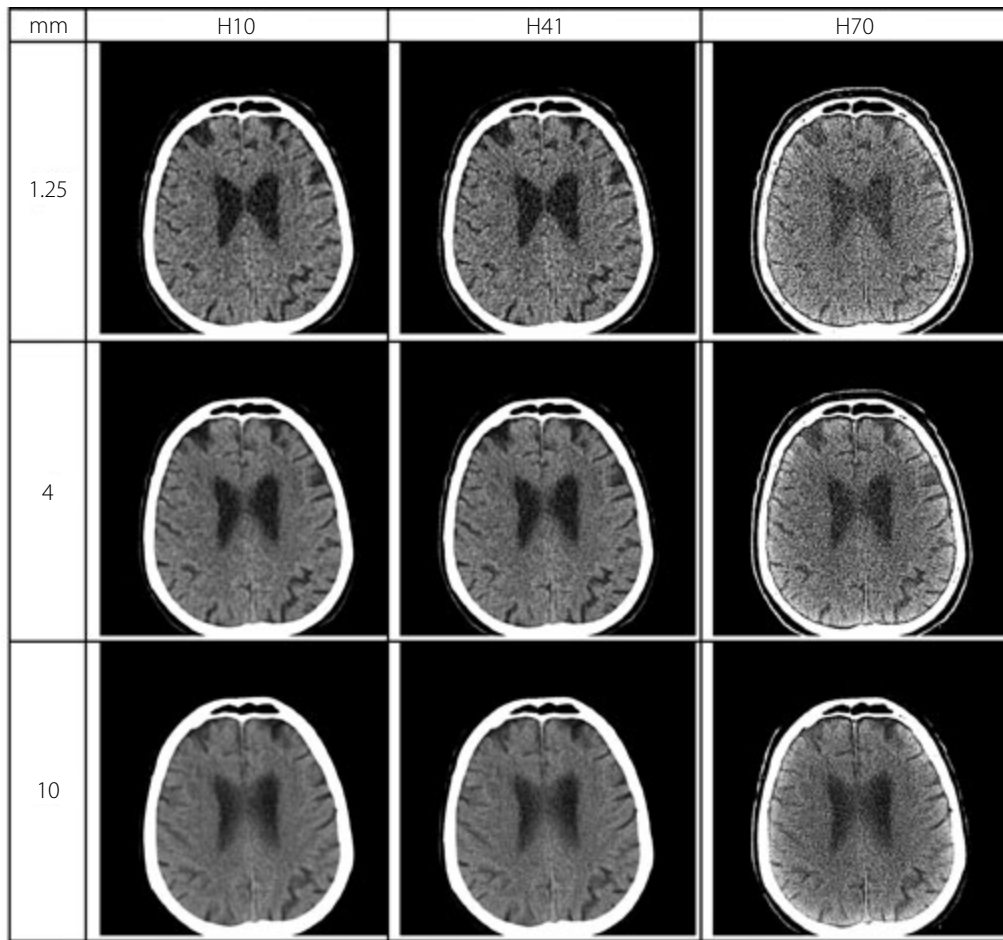


Figure 7. Effect of kernel and slice thickness on image quality.

It is obvious that for a slice thickness of 1,25 mm we have to choose the smoothest kernel, otherwise noise from the measurement errors will make evaluation of the image impossible. However, the soft kernel will make the bone window image blurry, therefore in this case, we have to choose the hard kernel, since the amount of measurement error will be negligible compared to the large density range of the wide window.

More examples on how to choose the appropriate kernel can be found in the SSD reconstruction section.

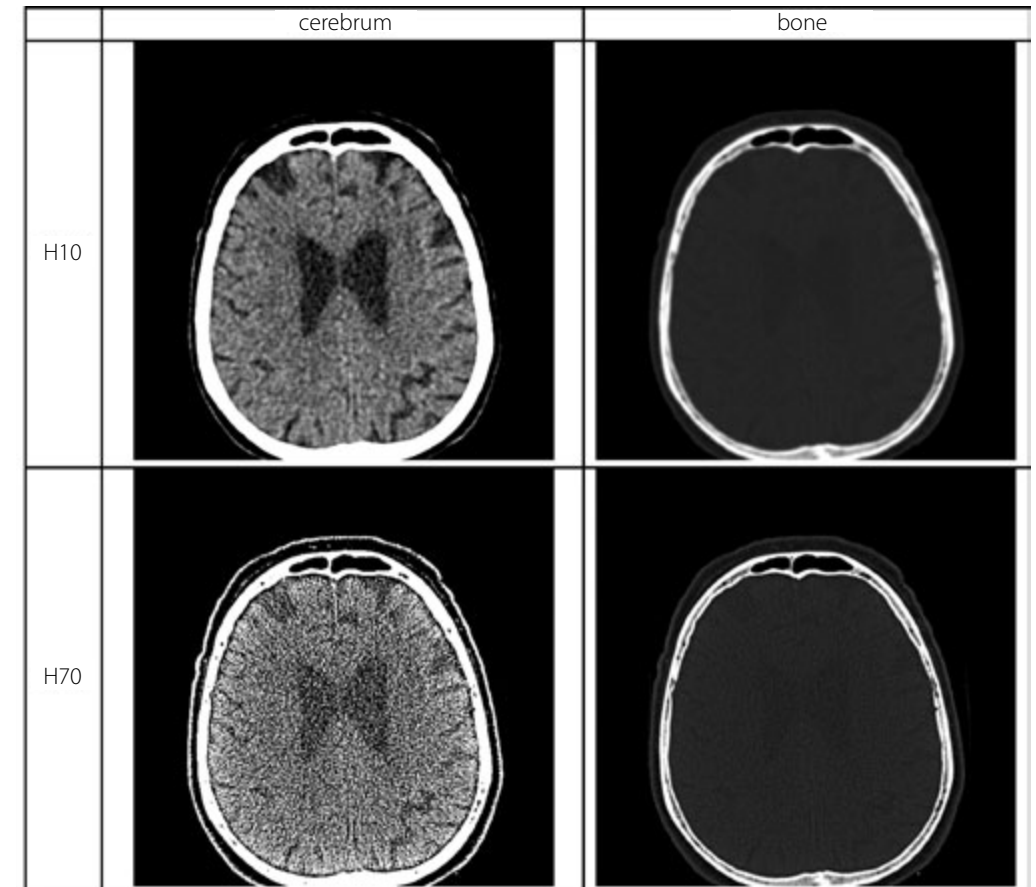


Figure 8. Effect of windowing and kernel on image quality.

Finally let us take a look at how windowing and slice thickness affect image quality while using the H70 kernel. (Figure 9.)

Secondary or postprocessing techniques

For each technique it is true that you should not think of the initial state as a process of putting together an image from separate images. During the study, we create a three-dimensional voxel set, (3D matrix of data), from which various planes are created from several directions and with different slice thicknesses during postprocessing. We create the necessary space segment for the given technique by truncating the data space, and then we assign different colors, shades,

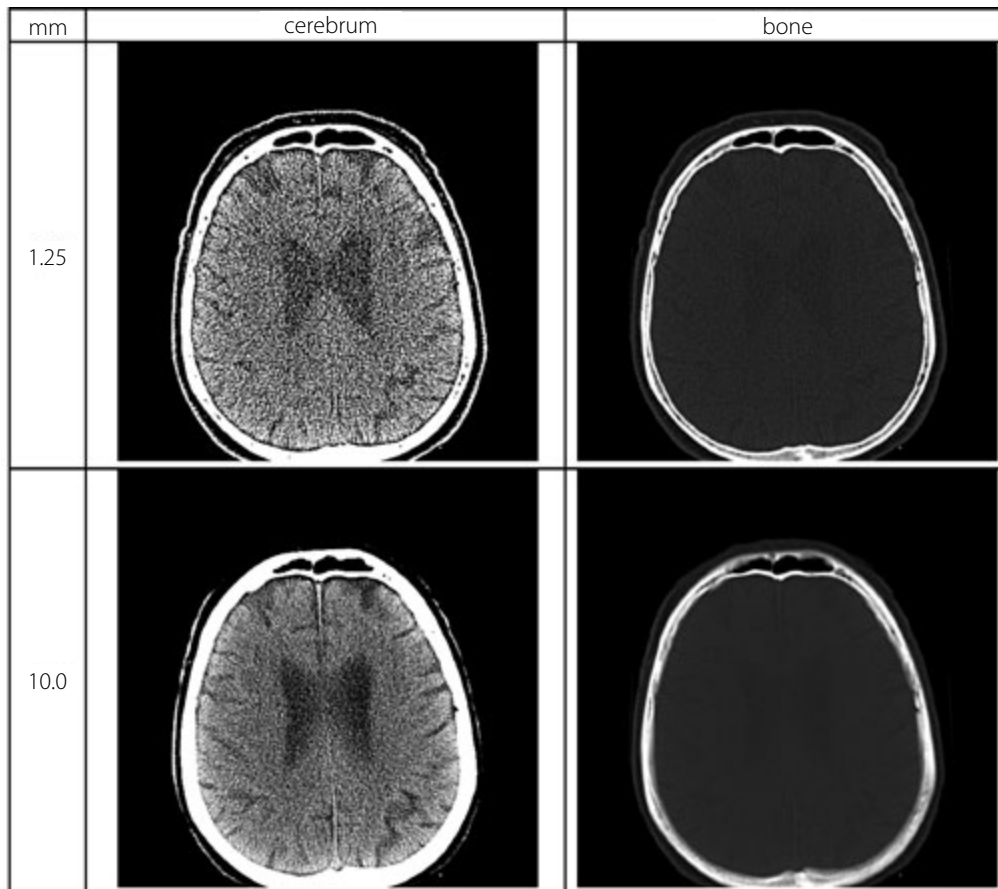


Figure 9. Effects of slice thickness and windowing on CT image quality

opacity values, shadows, and lighting conditions. Finally we get the end result that we want to display.



Animation II.2. Still life

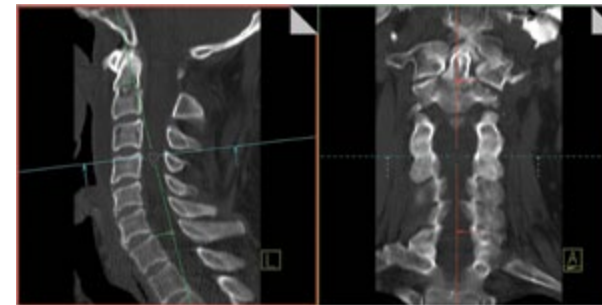
Teaser:

http://tamop.etk.pte.hu/tamop412A/Kepalkotasi_gyakorlatok_tananyag/CT/CT_Animaciok/csendelet/index.html

- *MPR – CPR (Multiplanar – Curved-planar Reformation)*

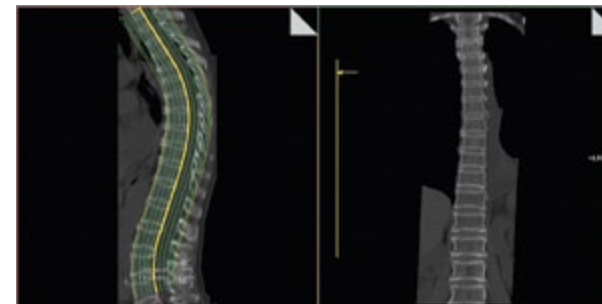
With this 2D reconstruction technique you can create reconstructions in any direction from the axial slices (sagittal, coronal, or different curved planes). With the CPR technique you can create curved planes that are aligned to even hand-drawn curves. The importance of the multiplanar reconstruction technique is that structures and lesions, which are not parallel to the primary axial plane, are evaluated easier if we depict them in a more suitable plane. These reconstruction techniques must be used in almost all of the examination protocols.

For example, when the cervical lordosis is straightened out, it is enough to use MPR reconstruction for the representation of the bony spine in the coronal plane, but when the anatomy is normal, for all spinal segments, the CPR reconstruction should be applied: (Figure 10–11.)



Animation II.3. MPR reconstruction of the cervical spine

http://tamop.etk.pte.hu/tamop412A/Kepalkotasi_gyakorlatok_tananyag/CT/CT_Animaciok/MPR_CPR_Cv/index.html



Animation II.4. CPR reconstruction of the thoracic spine

http://tamop.etk.pte.hu/tamop412A/Kepalkotasi_gyakorlatok_tananyag/CT/CT_Animaciok/MPR_CPR_Th-L/index.html

These reconstructions may be downloaded in DICOM format from this source.

http://tamop.etk.pte.hu/tamop412A/Kepalkotasi_gyakorlatok_tananyag/CT/CT_DICOM_Kepek/01_koponya.zip
http://tamop.etk.pte.hu/tamop412A/Kepalkotasi_gyakorlatok_tananyag/CT/CT_DICOM_Kepek/02_arckoponya.zip
http://tamop.etk.pte.hu/tamop412A/Kepalkotasi_gyakorlatok_tananyag/CT/CT_DICOM_Kepek/03_belsőful.zip
http://tamop.etk.pte.hu/tamop412A/Kepalkotasi_gyakorlatok_tananyag/CT/CT_DICOM_Kepek/04_orbita.zip
http://tamop.etk.pte.hu/tamop412A/Kepalkotasi_gyakorlatok_tananyag/CT/CT_DICOM_Kepek/07_vall.zip
http://tamop.etk.pte.hu/tamop412A/Kepalkotasi_gyakorlatok_tananyag/CT/CT_DICOM_Kepek/08_felkar.zip
http://tamop.etk.pte.hu/tamop412A/Kepalkotasi_gyakorlatok_tananyag/CT/CT_DICOM_Kepek/09_konyok.zip
http://tamop.etk.pte.hu/tamop412A/Kepalkotasi_gyakorlatok_tananyag/CT/CT_DICOM_Kepek/10_csuklo.zip
http://tamop.etk.pte.hu/tamop412A/Kepalkotasi_gyakorlatok_tananyag/CT/CT_DICOM_Kepek/11_medence.zip
http://tamop.etk.pte.hu/tamop412A/Kepalkotasi_gyakorlatok_tananyag/CT/CT_DICOM_Kepek/12_csipo.zip
http://tamop.etk.pte.hu/tamop412A/Kepalkotasi_gyakorlatok_tananyag/CT/CT_DICOM_Kepek/13_terd.zip
http://tamop.etk.pte.hu/tamop412A/Kepalkotasi_gyakorlatok_tananyag/CT/CT_DICOM_Kepek/14_boka.zip
http://tamop.etk.pte.hu/tamop412A/Kepalkotasi_gyakorlatok_tananyag/CT/CT_DICOM_Kepek/15_nyak.zip
http://tamop.etk.pte.hu/tamop412A/Kepalkotasi_gyakorlatok_tananyag/CT/CT_DICOM_Kepek/16_th_L_go.zip
http://tamop.etk.pte.hu/tamop412A/Kepalkotasi_gyakorlatok_tananyag/CT/CT_DICOM_Kepek/17_lgo_seq_hernia.zip
http://tamop.etk.pte.hu/tamop412A/Kepalkotasi_gyakorlatok_tananyag/CT/CT_DICOM_Kepek/18_nyak_mellkas_has.zip

The following CPR reconstructions were made with a voxel size of one. (Figure 12.)

Let us take a look at the following images, and analyze why there might be a need for MPR reconstructions with several voxel sizes: (Figure 13.)

We reconstructed a sagittal image that is one voxel thick with the proper kernel. Although the examination was not carried out with the recommended overlap (slice thickness*2/3 increment), and the software that we used for reconstruction did not apply an antialiasing filter, image quality is acceptable and it provides for good evaluation. However, homogenous structures are depicted heterogeneously because of measurement errors.

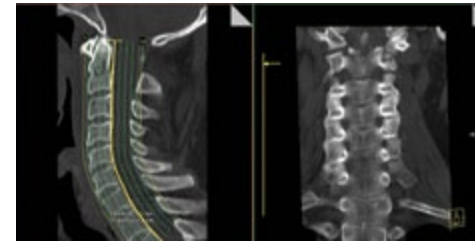


Figure 10. Depiction of the vertebral column and spinal canal using CPR reconstruction.

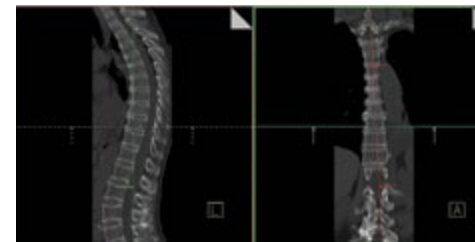

Figure 11. MPR reconstruction of the thoracolumbar spine

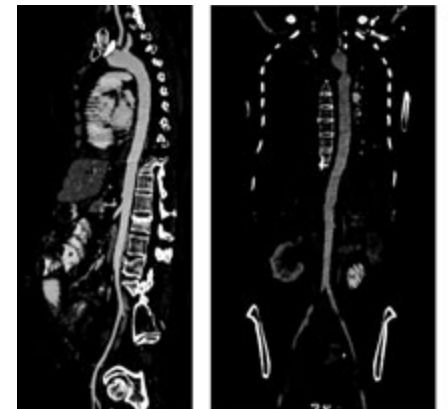


Figure 12. The importance of the CPR reconstruction technique is also evident during CTA

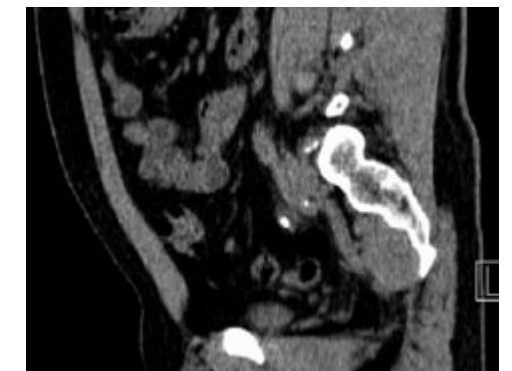

Figure 13. Sagittal MPR reconstruction with a thickness of 1 voxel

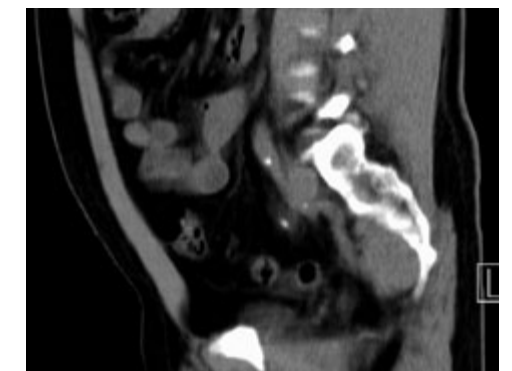


Figure 14. Sagittal MPR image with a thickness of 10 mm

If we carry out an MPR reconstruction in this same plane, but with a slice thickness of 10, we get the following image: (Figure 14.)

Analyzing the difference between the two images, we can see that:

- The image noise derived from the measurement errors is almost completely gone; image homogeneity is much better than when the slices are one voxel thick
- On the previous image, as well, there were two calcifications in front of the sacrum, superimposed on the iliac artery and the ureter, which are now less dense due to partial volume effect, but owing to less image noise, they are now better depicted
- Another calcification appeared on the second image, which is due to the larger (10 mm) slice thickness.
- On the images without the antialiasing filter, the contours appear without perpendicular zigzaggedness.

About the so-called partial volume effect:

- If there are several different types of tissue, all with different densities, in one voxel
- Or, as in our case: a lot of voxels that are orthogonal to each other have different density values (calcium and soft tissue), and if we use the thick slice MPR reconstruction, these values are averaged $D = (d_1 + d_2 + \dots + d_n) / n$.

This can be seen on the second image. One point of the image shows the arithmetical average of the superimposed density values.

- MIP (Maximum Intensity Projection), MinIP (Minimum Intensity Projection) AverIP

For the visualisation of voxels with the highest/lowest attenuation value in a reconstructed space segment with a thickness of more than 1 voxel. (Figure 15.)

What kind of changes can be seen on the 1 voxel thick image compared to the 10 mm thick MPR image?

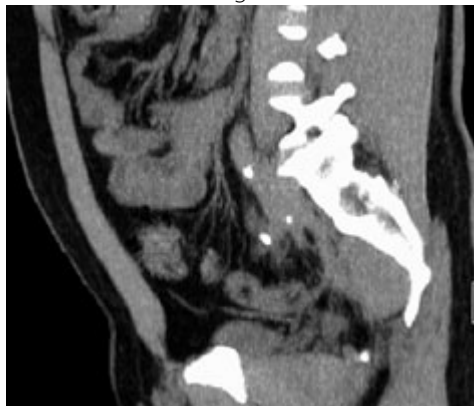

Figure 15. Sagittal 10mm thick MIP image

MPR image?

- Image noise and zigzaggedness reappear but the image is more homogeneous than the 10 mm thick MPR
- The intensity of calcifications are maximised, thus they are better visualized. Ventral to these calcifications, the mesenteric arteries are seen more clearly.

MIP reconstruction consists of the projection of image pixels with the highest density values - $D = \text{MAXIMUM}(d_1, d_2, \dots, d_n)$.

Reappearance of image noise is due to

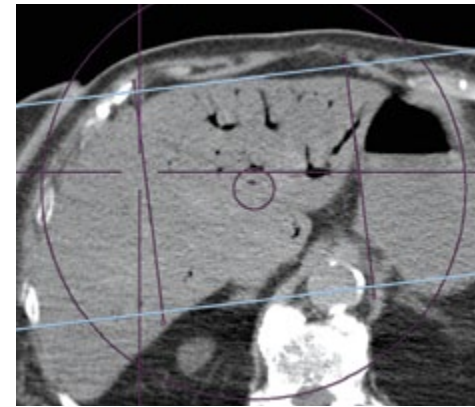


Figure 16. Reconstructions are made from the area between the two blue lines

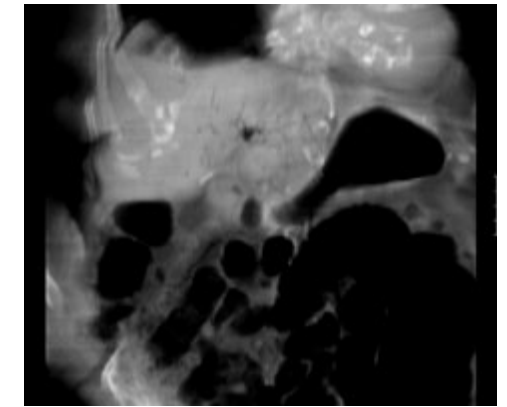


Figure 17. Paracoronaral AverIP reconstruction

the fact that maximum values are visualized without averaging.

The following images are made with MIP, MinIP and AverIP reconstructions. (Figure 16.)

An AverIP image is just like an x-ray image, but the spine of the patient is not visualized on the image, since it does not lie in the plane of reconstruction. Calcification within the wall of the aorta, and air within the hepatic vessels can be vaguely made out. The difference between AverIP and MIP is that in the case of AverIP the geometric and not the arithmetical average of voxels are depicted: $D = (d_1 * d_2 * \dots * d_n)^{1/n}$. (Figure 18.)

On this MIP reconstruction calcifications within the aorta and its branches, the ribs and the

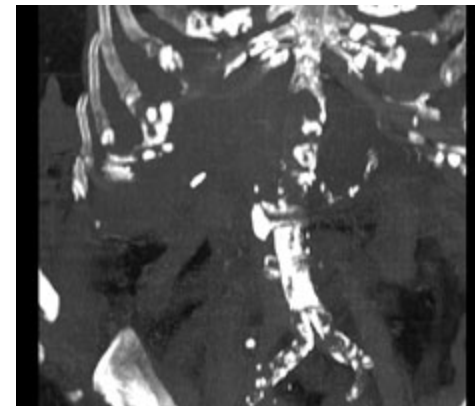


Figure 18. Paracoronaral MIP reconstruction

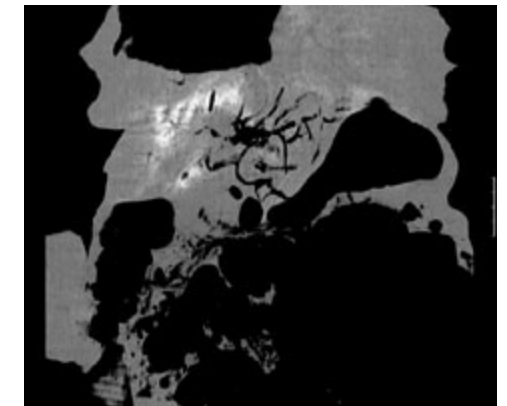


Figure 19. Paracoronaral MinIP reconstruction

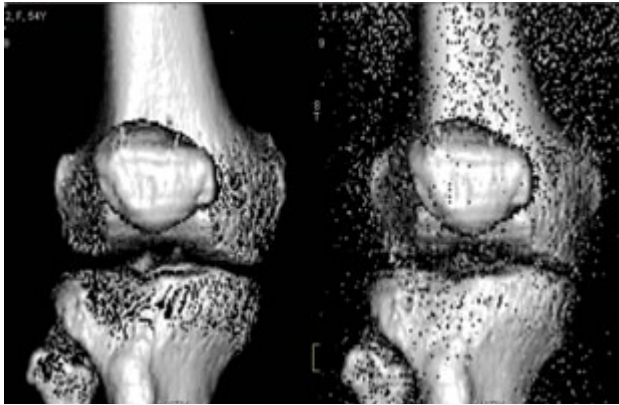


Figure 20. SSD reconstruction made from images using a U90 kernel

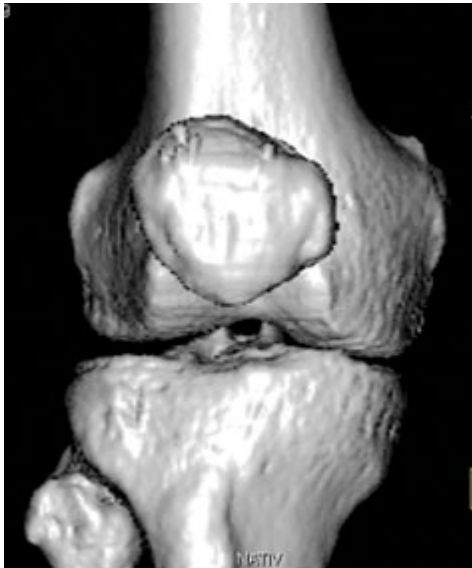

Figure 21. SSD reconstruction made from images using a B40 kernel

with a sharp kernel, because these images will be sharp and less noisy, however these images are not appropriate for SSD reconstruction: (Figure 20.)

Namely, images acquired with a bone window are read with a wide window because the density range of bones is very wide. If images of bones are acquired with a sharp kernel or due to details with too little density, bones may have a moth-eaten (permeative) appearance, or if we

right os ilium are well visualised. (Figure 19.)

On MinIP images we can see the gas within the wall or lumen of bowels and in portal vessels very well.

MIP, MinIP and AverIP reconstructions are only justified if the reconstruction is done from a layer that is more than 1 voxel thick. If it is only 1 voxel thick, than the resulting image equals the MPR reconstruction image. These techniques are used to enhance visualization of vessels, ureters and to facilitate the separation of bones and soft tissues.

These techniques are used to enhance visualization of vessels, ureters and to facilitate the separation of bones and soft tissues.

- *SSD (Surface Shaded Display)*

It is used for the visualisation of surfaces. This is a volumetric reconstruction technique. First, we determine a density range. Only the voxels within this range will take part in image creation. If the software finds a part in the spatial matrix where neighbouring voxels are in this range, those voxels will be depicted as a surface. Different colors and lighting directions can be assigned. This technique is usually used for the visualisation of bones.

Examples of SSD reconstruction:

SSD is very sensitive to the applied kernel. Imaging of the bones is usually carried out

with a sharp kernel, because these images will be sharp and less noisy, however these images are not appropriate for SSD reconstruction: (Figure 20.)

Namely, images acquired with a bone window are read with a wide window because the density range of bones is very wide. If images of bones are acquired with a sharp kernel or due to details with too little density, bones may have a moth-eaten (permeative) appearance, or if we

want to visualise the bone in it's whole density range, then measurement errors will degrade the image. Thus for a 3D spatial reconstruction we always use a softer kernel, although in this case small fracture lines disappear due to unsharpness. (Figure 21.)

These two animations show the effect of changing the kernel. In the first case (animation II.5.) the density value is not changed. In the second animation (animation II.6.) the lower threshold of the density range is continuously increased. In summary, it is true for SSD reconstruction that we have to choose between unsharp and less noisy and sharp but noisy images. Although we have to compromise, there is one more thing we can do in order to highlight subtle details: we can change the direction of the lighting (animation II.7.).

[Animation II.5.](http://tamop.etk.pte.hu/tamop412A/Kepalkotasi_gyakorlatok_tananyag/CT/CT_Animaciok/SSD/kernel.htm)

http://tamop.etk.pte.hu/tamop412A/Kepalkotasi_gyakorlatok_tananyag/CT/CT_Animaciok/SSD/kernel.htm

[Animation II.6.](http://tamop.etk.pte.hu/tamop412A/Kepalkotasi_gyakorlatok_tananyag/CT/CT_Animaciok/SSD/threshold.htm)

http://tamop.etk.pte.hu/tamop412A/Kepalkotasi_gyakorlatok_tananyag/CT/CT_Animaciok/SSD/threshold.htm

[Animation II.7.](http://tamop.etk.pte.hu/tamop412A/Kepalkotasi_gyakorlatok_tananyag/CT/CT_Animaciok/SSD/index.htm)

http://tamop.etk.pte.hu/tamop412A/Kepalkotasi_gyakorlatok_tananyag/CT/CT_Animaciok/SSD/index.htm
http://tamop.etk.pte.hu/tamop412A/Kepalkotasi_gyakorlatok_tananyag/CT/CT_Animaciok/SSD/light.htm

- *VR (Volume Rendering)*

In order to understand VR, let us go back a little to SSD. In SSD reconstruction, for one density range we can assign only one color and one opacity value. If this value is zero, than the tissue is non-transparent (opaque). VR is basically the simultaneous depiction of several of these density ranges that each can assume its own color and opacity. (Figure 22.)



Figure 22. Density histogram which is used for creating VR reconstruction

The process of VR reconstruction is demonstrated on a patient with lung hernia. First we assign a homogenous pink color to the density range of the lung (animation II.8.). Then, to visualize the respiratory tracts, we make this range transparent (animation II.9.). To simultaneously visualise the bones and the lungs, we determine the density range of the bones and assign it a different colour (animation II.10.). After this, we make the lungs transparent again (animation II.11.). The whole process can be seen in animation II.12. To get more details about the hernia, we can make the VR images using different parameters (animations II.13., II.14.).

[Animation II.8.](#)

http://tamop.etk.pte.hu/tamop412A/Kepalkotasi_gyakorlatok_tananyag/CT/CT_Animaciok/tudoserv/tudoopac.htm

[Animation II.9.](#)

http://tamop.etk.pte.hu/tamop412A/Kepalkotasi_gyakorlatok_tananyag/CT/CT_Animaciok/tudoserv/tudotrans.htm

[Animation II.10.](#)

http://tamop.etk.pte.hu/tamop412A/Kepalkotasi_gyakorlatok_tananyag/CT/CT_Animaciok/tudoserv/csonttudotrans.htm

[Animation II.11.](#)

http://tamop.etk.pte.hu/tamop412A/Kepalkotasi_gyakorlatok_tananyag/CT/CT_Animaciok/tudoserv/csonttudoopac.htm

[Animation II.12.](#)

http://tamop.etk.pte.hu/tamop412A/Kepalkotasi_gyakorlatok_tananyag/CT/CT_Animaciok/tudoserv/tudoserv.htm

[Animation II.3.](#)

http://tamop.etk.pte.hu/tamop412A/Kepalkotasi_gyakorlatok_tananyag/CT/CT_Animaciok/tudoserv/mellureg.htm

[Animation II.14.](#)

http://tamop.etk.pte.hu/tamop412A/Kepalkotasi_gyakorlatok_tananyag/CT/CT_Animaciok/tudoserv/mellkas.htm

The next example is a patient who suffered a car accident. In his case, MPR and axial slices are not enough to depict the several fractures on his face, that is why VRT reconstruction has to be made for surgery planning (animations II.15., II.16.).

[Animation II.15.](#)

http://tamop.etk.pte.hu/tamop412A/Kepalkotasi_gyakorlatok_tananyag/CT/CT_Animaciok/arc/vizsz.htm

[Animation II.16.](#)

http://tamop.etk.pte.hu/tamop412A/Kepalkotasi_gyakorlatok_tananyag/CT/CT_Animaciok/arc/fugg.htm

A tumor which is infiltrating the pleura can be seen on animation II.17.

[Animation II.17.](#)

http://tamop.etk.pte.hu/tamop412A/Kepalkotasi_gyakorlatok_tananyag/CT/CT_Animaciok/tudoserv/daganat.htm

As seen on the animations, with VR reconstruction, we can create quite real images. The possibilities are almost endless, however this technique requires a lot of work and experience. VR software does not depict voxels like spatial elements, but instead it attempts to find and depict objects such as bones, organs, and tissues. On VR images noise is nearly removed, because this technique is not as sensitive to noise.

- *Vessel reconstruction*

This technique is useful for the evaluation of CT angiography and cardio CT. The essence of this software is that it is able to independently identify the vessels due to the high density value of the contrast agent. Advanced software are able to even identify vessels by their names, and to create CPR reconstructions along the vessels' axis. Automatic identification of vessel narrowing and occlusion, and the distinction between soft and hard plaques are also readily available. Vessel reconstruction software with these features also belong to the realm of CAD (Computer Aided Detection or Computer Aided Diagnosis).

II.3. Information on the handling of the injector

Nowadays, for better tissue contrast, the majority of CT scans are carried out with intravenous contrast agent administration, except if it is contraindicated or not necessary (e.g.: bone fracture). Contrast administration is done using an injector. Using an injector is necessary, because it allows for a permanent velocity (ml/sec – flow) contrast administration, and it allows for precise timing. Timing is essential, because we need to time the different phases (series) according to the indication. Preparation and cleaning of the injector is always the radiographer's task.

Parts of the injector:

- console
- feedhead

Additional parts:

- syringe cradle
- syringe sheath
- syringe warmer

Preparation steps: (http://tamop.etk.pte.hu/tamop412A/Kepalkotasi_gyakorlatok_tananyag/CT/CT_Videok/injektor_elokeszites_en.avi)

- insert the syringe into the cradle (feedhead in a standing position)
- suck up the contrast material into the syringes
- connect the cables to the injector – „Y” and straight connectors (remove it after every measurement)
- GASSING! (wash the cables with a small amount of contrast agent and saline until the connectors are clear of air bubbles)
- turn down the feedheads and „arm” the injector
- connect the injector to the patient
- after the examination is done, remove the cables and the process may be repeated

Possible errors:

- not appropriate preparation steps
- not appropriate gassing – air embolism may occur
- contaminated fluid gets into the syringes and afterwards into the patient – infection
- swapping of the contrast agent and saline

Parameters of contrast agent administration may differ based on the examined region and indication. Parameter settings (http://tamop.etk.pte.hu/tamop412A/Kepalkotasi_gyakorlatok_tananyag/CT/CT_Videok/injektor_beallitasa_en.avi) and administration of the contrast material is done on the console where we can save several injection protocols. We can set the velocity and the amount of the contrast agent and the phase delay time, too. Then we accept these parameters and arm the system. Injection begins after pushing of the START mark. In „dropping” mode, saline ensures the penetrability of vessels. Some systems may be interconnected, in this case, the injector is synchronized with the CT controls, and administration of contrast material will be controlled by the CT control panel. (http://tamop.etk.pte.hu/tamop412A/Kepalkotasi_gyakorlatok_tananyag/CT/CT_Videok/has-HF-SUP-craniocaudal_en.avi)

II.4. CT scan procedure, and the radiographer's tasks

Filling out the examination consent form

Before the CT scan, it is important that the examination consent form is carefully read, and all the questions are answered with clear answers such as "YES" or "NO" (in case of a non-enhanced scan, too). This form must be signed by the patient or legal guardian and confirmed by CT personnel.

Important questions to ask:

- Have you ever had a CT scan before?
- Have you ever got intravenous contrast material? If yes, did you have any problems associated with it?
- Do you have allergies?
- Do you have any of the following conditions:
 - high blood pressure
 - diabetes
 - asthma
 - heart disease
 - liver disease
 - renal disease/insufficiency
 - thyroid disease
 - multiplex myeloma
 - haemophilia
- What kind of medicine do you take regularly?
- Are you pregnant?

Contraindications

Before the examination, it is very important to find out if any contraindications of contrast administration are present. In the following cases, administration of contrast material is either prohibited or should be used cautiously:

The patient ate before the examination. It is only important in case of contrast enhanced exams.

If the patient did not stop taking his diabetes medication (containing metformin) two days before the contrast enhanced exam, there is a high risk of renal insufficiency. Metformin containing medications are: Adimet, Competact, Eucreas, Gluformin, Janumet, Maformin, Meforal, Meglucon, Merckformin, Metfogamm, Metformin 1A Pharma, Metformin Aurobindo, Metformin Bluefish, Metformin Mylan, Metrivin, Metrivin Xr, Metwin, Normaglyc, Stadamet, Velmetia.

According to ESUR guidelines, the administration of intravenous iodine containing contrast agents is contraindicated in high-risk patients (eg.: patients with stage IV. and stage V. chronic renal disease [GFR < 30 ml/min; Creatinin > 160 µmol/l], decreased renal function, acute renal failure) except if the patient will be put on dialysis.

In case of iodine allergy, if the patient received an iodine containing contrast agent previously, and he was sick from it.

In case of uncontrolled hyperthyreosis, contrast agent administration may cause thyreotoxicosis.

After a contrast-enhanced examination of a pregnant or nursing mother, her baby's thyroid function must be controlled. Although there is no data on renal damage, it is advisable to avoid contrast agent administration during pregnancy and nursing.

Preparation according to the examined region

Before the exam it is essential to carry out certain processes.

Tools preparation:

- supporting pads
- fixing pants
- for venous preparation: intravenous line, cotton, tourniquet, tape, 5 ml syringe, disinfectant
- injector (http://tamop.etk.pte.hu/tamop412A/Kepalkotasi_gyakorlatok_tananyag/CT/CT_Videok/injektor_elokeszitese_en.avi)

Patient preparation, contrast agents

During the examination, if it is not contraindicated, the patient will most likely get an intravenous contrast agent. Contrast agents are given to patients either intravenously or through the mouth (per os). When examining the abdomen, oral contrast agents may be water or gastrografin, depending on the indication. Gastrografin (15 ml gastrografin dissolved in 1,5-2 liters of water) must be drunk approximately 1-1,5 hours before the exam. Water (1,5-2 liter) must be drunk 1/3-3/4 hours before the exam. The patient should drink one more glass of contrast agent before he lies down on the table to ensure appropriate filling up of the ventricle and duodenum.

In case of an enhanced CT exam, venous preparation is essential. The intravenous line, if it is possible, must be inserted into the right cubital vein, because the contrast agent reaches the heart faster from the right side. Administration velocity and quantity depend on the concentration of contrast agent, the patient's height and the examined region. Usually (non angiography exams) this quantity is 0.2 ml/kg, and the velocity is 2-2.5 ml/sec (flow).

Before using the contrast agent you should read its description.

The patient should remove all metallic objects (e.g.:dresses, jewelleryes, hairgips) from the examined region. The patient lies head-first (http://tamop.etk.pte.hu/tamop412A/Kepalkotasi_gyakorlatok_tananyag/CT/CT_Videok/mellkas-has_HF-SUP-craniocaudal_en.avi) or feet-first (http://tamop.etk.pte.hu/tamop412A/Kepalkotasi_gyakorlatok_tananyag/CT/CT_Videok/medence_FF-SUP-craniocaudal_en.avi), prone (http://tamop.etk.pte.hu/tamop412A/Kepalkotasi_gyakorlatok_tananyag/CT/CT_Videok/Sinus_axialis_HF-Prone_en.avi) or supine on the table according to the examined region. The patient's arm in which the intravenous line is inserted should not be bent because a paravasatum may arise due to resistance, or it may flip out of his arm. Patient positioning is done using lasers, as indicated by the examined region.

In case of a non-cooperative or apprehensive patient we have to restrain the patient's examined body parts (http://tamop.etk.pte.hu/tamop412A/Kepalkotasi_gyakorlatok_tananyag/CT/CT_Videok/nyugtalan_koponya_rogz_en.avi) and arms (http://tamop.etk.pte.hu/tamop412A/Kepalkotasi_gyakorlatok_tananyag/CT/CT_Videok/nyugtalan_karok_rogzitese_en.avi).

Radiographer's tasks

- to carry out the examination only if the examination consent form is completely filled out and all the questions are answered
- to instruct and inform the patient
- to question about gravidity
- to check the patient's personal data
- to enter the patient's personal data into the CT control panel
- to prepare the tools
- to carry out the examination according to the rules of our profession
- to ensure the patient's safety
- to observe radiation safety
- to prepare the documentation for the radiologist
- to record the used materials
- to archive the examination (PACS, CD/DVD)

Documentation

The radiographer should record the following:

- name of the radiographer doing the examination; velocity, type, quantity and concentration of administered intravenous contrast agent
- velocity, quantity of administered saline
- complications and steps done to treat them

II.5. CT imaging of the head

(http://tamop.etk.pte.hu/tamop412A/Kepalkotasi_gyakorlatok_tananyag/CT/CT_Videok/Koponya-craniocaudal_en.avi)

Over the past decade, imaging of the skull - as well as the whole of diagnostic imaging - has changed considerably. Where CT is available, conventional radiography has been pushed into background. Two-way x-ray imaging of the skull is still relatively common, but other types of images of the brain and the facial bones are rarely made today. The number of summation x-ray images for traumatology, neurology, otolaryngology and ophthalmology have been minimized due to CT imaging. Only the significance of infants' screening ultrasonography was not decreased because of the radiation exposure of the patient during CT imaging. The importance of neurological CT has increased to a lesser extent compared to other areas, but this was not due to x-ray images. Rather, it happened because the diagnostic value of MRI has increased due to major technological developments in MRI technology, and due to better availability of MRI scanners.

Imaging of the regions of head:

- Routin head CT
- Facial bone CT
- Inner ear CT
- Orbit CT
- Hypophysis CT
- Perfusion CT

Routin head CT

(http://tamop.etk.pte.hu/tamop412A/Kepalkotasi_gyakorlatok_tananyag/CT/CT_DICOM_Keppek/01_koponya.zip)

Because of the high attenuation of skull bones and the small density range of brain tissue, the test is usually prepared in a sequential mode, in order to achieve a good signal-to-noise ratio but in some cases (using a higher-yield X-ray tube, or in case of a non co-operative patient) helical mode is also available. Since several bones form the skull base, the examination is divided into two distinct regions that are imaged with different scan parameters: the base and cerebrum.

Indications

From a neurological point of view, the most important and the most common indication for a head CT is to determine whether the patient's stroke is ischemic or hemorrhagic. Bleeding is obvious on CT images; the location of fresh blood is clearly visible in the intracranium. If there is subarachnoid hemorrhage, CT angiography should be considered to locate the source of bleeding.

When there is fresh ischemic stroke, the CT image is not so clear and in many cases, we are forced to be satisfied with the fact that we excluded hemorrhage. But sometime there are certain subtle, difficult to locate signs that might point to the source of ischemia.

These signs are the following:

- The density of the occluded cerebral artery is increased slightly. Occlusion is frequently located in the medial cerebral artery. This is called the hyperdens media sign.
- The ischemic area becomes oedemic, and its density decreases. Due to volume increase, the sulci become narrower.

In case of acute ischemic stroke, intraarterial lysis therapy must be done within three hours. To begin lysis therapy it is essential to precisely locate the occluded artery, and to evaluate brain perfusion. Usually this should be done by MRI but due to its long acquisition time and poor availability, CT perfusion and angiography should be done.

Traumatology

- traumatic bleeding in the skull
- fracture

When assessing for fractures, the presence of air bubbles, and surrounding bleeding can be helpful.

Air-containing cavities within bones are often bordered by very thin bone flakes. For the proper assessment of these structures, scan resolution has to be chosen correctly (slice thickness, FOV), but even in these cases, it is common that air bubbles within the soft tissues or inside the cranium help in the localization of bony defects. Fluid that is of blood density, may also suggest fracture.

From the oncological point of view, non-enhanced and contrast enhanced CT exams should be carried out to diagnose primary and secondary tumours, and to stage cancer.

Patient preparation:

The patient should not eat 5 hours before the contrast enhanced test. Make sure that all anti-diabetic medication, which are on the black list, are omitted before the study. The patient should remove all metallic objects (e.g.: jewellery, hairgrips) from the examined region. In case of an enhanced CT exam, venous preparation is essential. The intravenous line, if it is possible, must be inserted into the right cubital vein. Then the patient can be connected to the injector, or we can manually administer the contrast agent.

Patient positioning:

For CT examinations of the brain, the patient is placed in a head-first supine position with the arms close to the body. His head is placed in the head support.

Centering:

Patient positioning is done using lasers.

Examination process:

First, we make a topogram (scout view) in the lateral direction. The topogram must cover the whole cerebrum. Then we have to set the region of interest. The field-of-view (FOV) covers the area from the skull base to the vertex, and it is tilted 20° to the orbitomeatal plane. In case of trauma, we also have to examine the craniocervical junction, because fractures occur very frequently in this region. After setting the FOV, the non-enhanced and contrast enhanced series have to be made. Acquisition of the contrast enhanced series starts 20 sec after contrast administration. If required (e.g. enhancing space occupying lesion) the post contrast series also have to be made. In case of traumatic injuries, images with both bone window (sharp kernel H70) and cerebrum window (W/C = 1500/450) have to be made. (Figure 23.) (Table 4.)

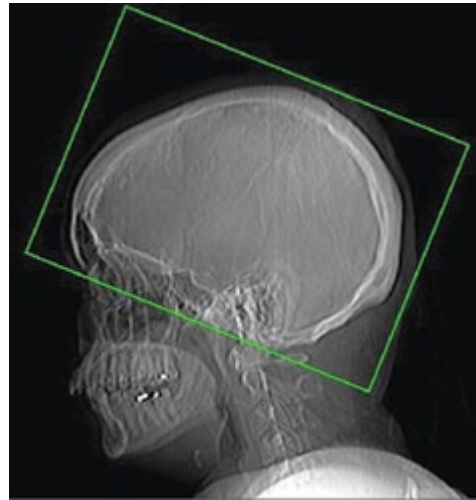


Figure 23. Planning of the head CT exam

Table 4. Parameters

Scan type	sequential
Slice thickness	base: 4 mm, cerebrum: 6 mm
Interval	40 mm
kV	130
mAs	260
Pitch	-
CM volume	30 ml (350 cc.)
CM speed	1 flow (ml/sec)
Delay	20 sec

CT imaging of the facial bones

http://tamop.etk.pte.hu/tamop412A/Kepalkotasi_gyakorlatok_tananyag/CT/CT_DICOM_Keppek/02_arckoponya.zip

Indications

Air content and mucous membranes of the paranasal sinuses, mucosal polyps, mucocele, trauma, foreign bodies and tumours.

Patient preparation

The patient should not eat 5 hours before the contrast enhanced test. Make sure that all anti-diabetic medication, which are on the black list, are omitted before the study. The patient should remove all metallic objects (e.g.: jewellery, hairpins) from the examined region. In case of an enhanced CT exam, venous preparation is essential. The intravenous line, if it is possible, must be inserted into the right cubital vein. Then the patient can be connected to the injector, or we can manually administer the contrast agent.

Patient positioning:

For CT imaging of the facial bones, the patient is placed in a head-first supine position, arms close to the body. His head is placed in the head support.

Centering:

Patient positioning is done using lasers.

Examination process:

First we make a topogram (scout view) in the lateral direction. The topogram must include the whole face and the cerebrum. Then we have to set the region of interest. The field-of-view (FOV) covers the area from the hard palate to the frontal sinus without tilting. In case of trauma this region is extended from the mandible to the frontal sinus. After setting the FOV, the non-enhanced and the contrast enhanced series have to be made. If required (e.g. enhancing space occupying lesion) the post contrast series has to be made as well. We use a sharp kernel (H70) and

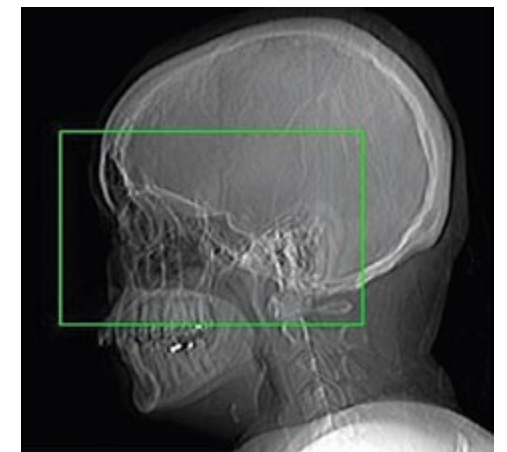


Figure 24. Planning of the facial bone CT (nontraumatic)

bone window setting (W/C = 2000/400). If necessary, for soft tissues, we use a softer kernel (H41) and soft tissue window settings (W/C = 400/40). In case of traumatic injuries, we do only the non-enhanced series, with bone window settings, MPR and 3D reconstructions. (Figure 24.) (Table 5.)

Table 5. Parameters

Scan type	helical
Slice thickness	1.25 mm
Interval	1.25 mm
kV	130
mAs	200
Pitch	0.9
CM volume	50 ml (350 cc.)
CM speed	2.5 flow (ml/sec)
Delay	after administration

Inner ear CT

http://tamop.etk.pte.hu/tamop412A/Kepalkotasi_gyakorlatok_tananyag/CT/CT_DICOM_Kepek/03_belfsul.zip

Indications

Acute and chronic inflammatory processes and their destructive morphology, pyramidal and pontocerebellar tumors, trauma (e.g.: oozing of blood or cerebrospinal fluid from the ear).

Patient preparation:

The patient should not eat 5 hours before the contrast enhanced test. Make sure that all anti-diabetic medication, which are on the black list, are omitted before the study. The patient should remove all metallic objects (e.g.: jewellery, hairgrips) from the examined region. In case of an enhanced CT exam, venous preparation is essential. The intravenous line, if it is possible, must be inserted into the right cubital vein. Then the patient can be connected to the injector, or we can manually administer the contrast agent.

Patient positioning:

For CT examinations of the inner ear, the patient is placed in a head-first supine position, arms close to the body. His head is placed in the head support.

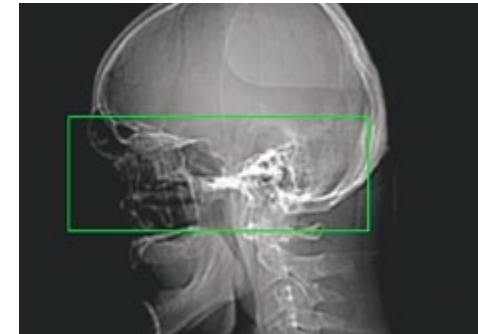

Figure 25. Planning of the inner ear CT examination

Centering:

Patient positioning is done using lasers.

Examination process:

First we make a topogram (scout view) in the lateral direction. The topogram must include the whole face and cerebrum. Then we have to set the region of interest. The field-of-view (FOV) covers the area from the hard palate to the mastoid cells without tilting. After setting the FOV the non-enhanced and contrast enhanced series have to be made. If required (e.g. space occupying lesion) the post contrast series has to be made as well. Images with bone window setting (sharp and ultra sharp kernel H70-H90) and soft tissue window setting (W/C = 400/40) have to be made. Coronal and two parasagittal (parallel to the inner ears) MPR reconstructions have to be made. (Figure 25.) (Table 6.)

Table 6. Parameters

Scan type	helical
Slice thickness	1.25 mm
Interval	1.25 mm
kV	130
mAs	200
Pitch	0.9
CM volume	50 ml (350 cc.)
CM speed	2.5 flow (ml/sec)
Delay	after administration

Orbit CT

http://tamop.etk.pte.hu/tamop412A/Kepalkotasi_gyakorlatok_tananyag/CT/CT_DICOM_Kepek/04_orbita.zip

Indications

Imaging of the orbit is primarily done with MRI, but to assess bone destruction (in case of a space occupying lesion), in the setting of trauma, and when foreign bodies are sought after, it is advised to make a CT scan.

Patient preparation:

The patient should not eat 5 hours before the contrast enhanced test. Make sure that all anti-diabetic medication, which are on the black list, are omitted before the study. The patient should remove all metallic objects (e.g.: jewelleries, hairgrips) from the examined region. In case of an enhanced CT exam, venous preparation is essential. The intravenous line, if it is possible, must be inserted into the right cubital vein. Then the patient can be connected to the injector, or we can manually administer the contrast agent.

Patient positioning:

For CT examinations of the orbits the patient is placed in a head-first supine position, arms close to the body. His head is placed in the head support.

Centering:

Patient positioning is done using lasers.

Examination process:

First we make a topogram (scout view) in the lateral direction. The topogram must include the whole face and cerebrum. Then we have to set the region of interest. The field-of-view (FOV) covers the whole orbit without tilting. The axial slices are parallel to the optical nerves. After setting the FOV the nonenhanced and the contrast enhanced series have to be made. If required (e.g.: space occupying lesion) the post contrast series has to be made as well. Images with bone window setting (sharp kernel H70) and soft tissue window setting (W/C=400/40) have to be made. In case of trauma only the non-enhanced series has to be made with MPR and 3D reconstructions. Coronal and two parasagittal (parallel to the optic nerves) MPR reconstructions had to be made. (Figure 26.) (Table 7.)

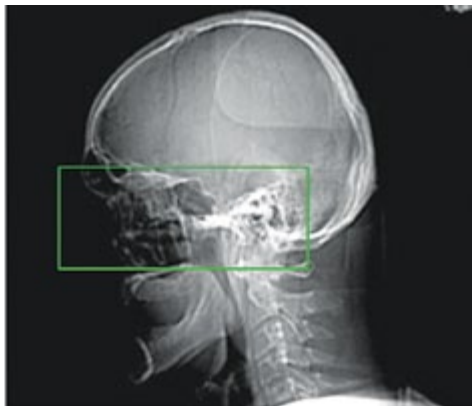

Figure 26. Planning of orbit CT

Table 7. Parameters

Scan type	helical
Slice thickness	1.25 mm
Interval	1.25 mm
kV	130
mAs	200
Pitch	0.9
CM volume	50 ml (350 cc.)
CM speed	2.5 flow (ml/sec)
Delay	after administration

Hypophysis CT

The primary testing method of the sella is MRI. In case of tumours that destroy bones (macroadenoma, chordoma, metastasis) CT scanning is essential.

Indications

Suspected hypophyseal space occupying processes (if MR imaging is impossible), imaging the bony sella, as well as in intra- or parasellar calcifications.

Patient preparation:

The patient should not eat 5 hours before the contrast enhanced test. Make sure that all anti-diabetic medication, which are on the black list, are omitted before the study. The patient should remove all metallic objects (e.g.: jewelleries, hairgrips) from the examined region. In case of an enhanced CT exam, venous preparation is essential. The intravenous line, if it is possible, must be inserted into the right cubital vein. Then the patient can be connected to the injector, or we can manually administer the contrast agent.

Patient positioning:

For CT examinations of the sella the patient is placed in a head-first supine position, arms close to the body. His head is placed in the head support.

Centering:

Patient positioning is done using lasers.

Examination process:

First we make a topogram (scout view) in the lateral direction. The topogram must include the whole face and the cerebrum. Then we have to set the region of interest. The field-of-view (FOV) covers the area between the bottom of the sphenoid sinus and the corpus callosum without tilting. The axial slices are parallel to the hard plate (palatum durum). After setting the FOV, the non-enhanced and contrast enhanced series have to be made. If required (e.g. space occupying lesion) the post contrast series has to be made as well. Coronal and sagittal MPR reconstructions must be performed. (Figure 27.) (Table 8.)

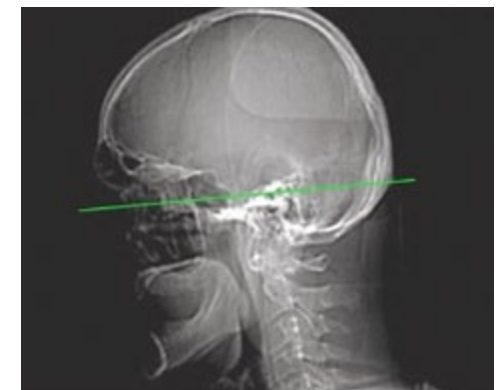

Figure 27. Planning of hypophysis CT

Table 8. Parameters

Scan type	helical
Slice thickness	1.25 mm
Intervallum	0.4 mm
kV	130
mAs	200
Pitch	0,5
CM volume	70-80 ml (350 cc.)
CM speed	3-4 flow (ml/sec)
Delay	after administration

CT perfusion

For the separation of ischemic and hemorrhagic stroke CT imaging is the recommended modality. The high density of fresh blood becomes immediately apparent.

Clinical application:

CT perfusion imaging:

- recommended in acute stroke patients whose condition will likely be improved by thrombolysis
- may help to determine the relationship, location and size of infarct and penumbra and the „time-window“ can also be judged
- helps to predict the final extent of infarction thus the prognosis of stroke outcome
- helps to monitor patients who are unsuitable for thrombolysis and to determine their prognosis

Patient preparation:

The patient should not eat 5 hours before the contrast enhanced test. Make sure that all anti-diabetic medication, which are on the black list, are omitted before the study. The patient should remove all metallic objects (e.g.: jewellery, hairgrips) from the examined region. In case of an enhanced CT exam, venous preparation is essential. The intravenous line, if it is possible, must be inserted into the right cubital vein. Then the patient can be connected to the injector, or we can manually administer the contrast agent.

Patient positioning:

For CT examinations of the brain, the patient is placed in a head-first supine position, arms close to the body. His head is placed in the head support. Position the patient's head so that his hard plate is parallel to the plane of the x-ray beam.

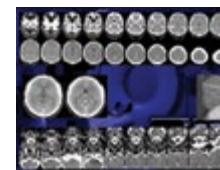
Centering:

Patient positioning is done using lasers.

Examination process:

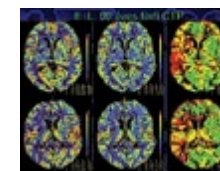
First we make a topogram (scout view) in the lateral direction. The topogram must include the whole cranium. Then we have to set the region of interest. The field-of-view (FOV) covers the area from the skull base to the vertex, tilted 20° to the orbitomeatal plane. After setting the FOV non-enhanced series has to be acquired. After reviewing the clinical history and the non-enhanced CT images, we determine which slices might give the most information about the disease. Usually we image only 2-3 slices. When planning the thick slices we have to make sure that at least one of the slices include the basal ganglia. The density changes of the selected slices are measured by the voxel-by-voxel method, at a speed of one acquisition per second for 35-45 seconds (the measurement begins before the contrast material arrives and it will continue until the contrast material leaves the examined tissue). The recommended amount of administered contrast agent (350 cc.) is about 40-60 ml with a flow of 5-8 ml/sec. The measurement starts 5 seconds after the administration of the contrast agent. The examination parameters are the same as in a conventional head CT, except for the voltage, which is 80 kVp in this case, because the selective absorption of iodine is 80 kV. By applying this voltage, the density information increases and so does the SNR.

The following animation illustrate the examination process of perfusion CT:



Animation 5. Examination process

http://tamop.etk.pte.hu/tamop412A/Kepalkotasi_gyakorlatok_tananyag/CT/CT_Animaciok/perfusio_vizsgalat/index.html



Animation 6. Evaluation of perfusion CT

http://tamop.etk.pte.hu/tamop412A/Kepalkotasi_gyakorlatok_tananyag/CT/CT_Animaciok/perfusio_ertekeles/index.html

The following parameters can be measured:

- regional cerebral blood flow (rCBF): – ml/100g/min; /normal value: 50ml/100g/min/
- regional cerebral blood volume (rCBV): – ml/100g tissue; /normal value: 4 ml/100g tissue/

- *mean transit time (MTT)*: mean transit time – $rCBF / rCBV$ (sec); /normal value: 5 sec/
- *time-to-peak (TTP)*, at a fixed region, the time between the start of contrast administration and its peak concentration

The penumbra is the area which may be saved: $rCBF-rCBV$. If these two parameters are equal there is no available area to be rescued. If CBF is much larger than CBV, it is expected that after therapy, only a small infarcted area will remain.

II.6. CT imaging of the musculoskeletal system and spine

Musculoskeletal imaging relies primarily on plain films and MRI for diagnosis, while the use of high-resolution ultrasound is increasing. Computed tomography has seen a revival with the introduction of helical and multislice CT techniques. CT is the technique of choice for detailed evaluation of skeletal trauma: the use of multiplanar reformations and 3D rendering has revolutionized trauma diagnosis, especially when complex fractures are present or articular involvement is suspected. It is also used for complications in fracture healing, for selected bone tumors, in infectious diseases, to guide musculoskeletal interventions and for some miscellaneous indications such as quantifying rotational deformities before and after corrective surgery.

Imaging of the regions of the MSK system:

- Upper extremities CT
- Lower extremities and pelvis CT

Indications:

Trauma: Screening of polytraumatized patients, complex fractures, fractures in anatomically complex areas and fracture detection in patients with equivocal plain films. Preoperative planning and postoperative follow-up and in case of osteonecrosis. For joint diseases and in case of shoulder instability, CT arthrography has to be carried out.

CT as a second-line imaging tool:

- Cervical and thoracic spine in degenerative diseases (MRI first).
- Bone tumors (radiography, MRI).
- Soft-tissue tumors (MRI, ultrasound.)
- Arthritis, osteoarthritis (radiography, MRI, ultrasound).

When examining orthopedic and traumatic injuries it is important to reconstruct thin slices for the joints, and the FOV has to be set according to the examined joint. Thanks to the helical mode, MPR reconstructions can be made from the thin primary images. Because of the short acquisition times, motion artifacts can be minimized when imaging sick patients.

Upper extremities CT

Patient preparation:

The patient should remove all metallic objects (e.g.: jewelleries, clothes) from the examined region. For an enhanced CT exam, venous preparation is essential.

Patient positioning:

Patient positioning is done according to the examined region. During examination of the upper extremities, the patient is usually in a head-first supine position, or he may lie prone. We have to do our best to position the patient's extremity in the center of the gantry (or as close to it as possible). Additional pads should be placed over the hand to avoid motion artifacts. The palm is in a supine position. During functional imaging, it is possible that the examined extremity is flexed, or held in an upright position as in the case of shoulder imaging.

Centering:

Patient positioning is done using lasers to the center of the examined joint.

Examination process:

First we make an AP topogram (scout view) image. The topogram must include the problematic region. Then we have to set the region of interest.

The field-of-view (FOV)

Shoulder: It extends from the acromioclavicular joint to the small tubercule of the humerus. For comparison views, both shoulders must be depicted. (http://tamop.etk.pte.hu/tamop412A/Kepalkotasi_gyakorlatok_tananyag/CT/CT_DICOM_Kepek/07_vall.zip)

Humerus: It is practical to depict both joints (shoulder and elbow), but at least one of them. (http://tamop.etk.pte.hu/tamop412A/Kepalkotasi_gyakorlatok_tananyag/CT/CT_DICOM_Kepek/08_felkar.zip)

Elbow: Depending on the indication, the elbow is a part of the humerus or forearm exam. We can examine only the elbow region, too. (http://tamop.etk.pte.hu/tamop412A/Kepalkotasi_gyakorlatok_tananyag/CT/CT_DICOM_Kepek/09_konyok.zip)

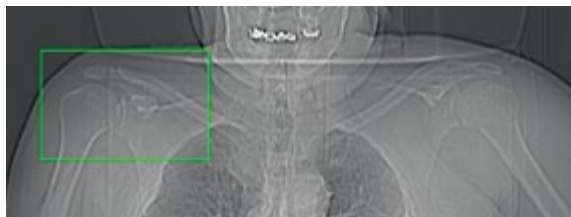

Figure 28. Planning of shoulder CT

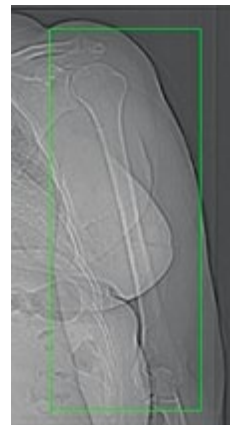


Figure 29. Planning of humerus CT

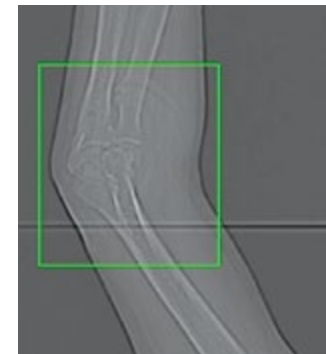

Figure 30. Planning of elbow CT

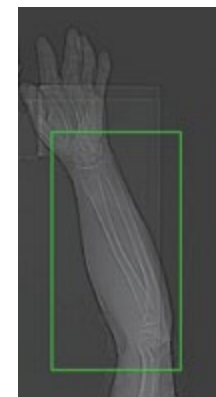

Figure 31. Planning of forearm CT

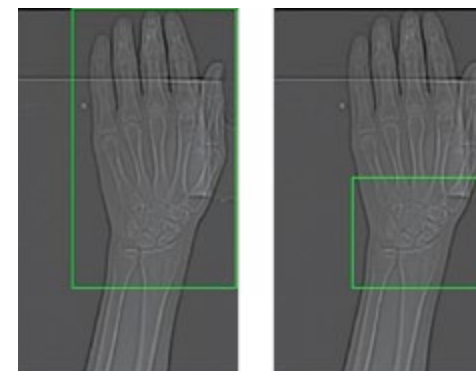


Figure 32. Planning of wrist and hand CT

Forearm: It is practical to depict both joints (wrist and elbow), but the joint closest to the lesion is definitely included in the FOV.

Wrist, hand: It extends from the styloid process of the ulna to the midcarpal bones or phalanges. (http://tamop.etk.pte.hu/tamop412A/Kepalkotasi_gyakorlatok_tananyag/CT/CT_DICOM_Kepek/10_csuklo.zip)

Bone window (C/W: 450/2500) and soft tissue kernel (C/W: 30/300) has to be used. If there is a soft tissue lesion, contrast material administration is required – but in this case, MRI is the most sensitive method - and the post contrast series has to be made as well. Coronal and two parasagittal MPR and 3D reconstructions have to be reconstructed. (Figures 28, 29, 30, 31., 32.) (Table 9, 10.)

Table 9. Parameters (shoulder, humerus, elbow, forearm):

Scan type	helical
Slice thickness	1.25 mm
Interval	1 mm
kV	130
mAs	260
Pitch	0.9
CM volume	(if required) 60-70 ml (350 cc.)
CM speed	2.5 flow (ml/sec)
Delay	0 sec

Table 10. Parameters (wrist, hand)

Scan type	helical
Slice thickness	0.65 mm
Intervallum	0.4 mm
kV	130
mAs	260
Pitch	0.5
CM volume	(if required) 50-60 ml (350 cc.)
CM speed	2.5 flow (ml/sec)
Delay	0 sec

Lower extremities CT

Patient preparation:

The patient should remove all metallic objects (e.g.: jewellery, clothes) from the examined region. For an enhanced CT exam, venous preparation is essential.

Patient positioning:

Patient positioning takes place according to the examined region. During the examination of the pelvis and hip, the patient is in a feet-first (http://tamop.etk.pte.hu/tamop412A/Kepalkotasi_gyakorlatok_tananyag/CT/CT_Videok/medence_FF-SUP-craniocaudal_en.avi) (sometimes head-first – http://tamop.etk.pte.hu/tamop412A/Kepalkotasi_gyakorlatok_tananyag/CT/CT_Videok/medence-csipo-HF-SUP-craniocaudal_en.avi) supine position, while during the examination of the femur, knee, leg, ankle and foot, the patient is in feet first supine position (http://tamop.etk.pte.hu/tamop412A/Kepalkotasi_gyakorlatok_tananyag/CT/CT_Videok/terd_FF-SUP-craniocaudal_en.avi). We have to do our best to position the patient's extremity in the center of the gantry (or as close to it as possible). If required, additional pads should be placed over the legs to avoid motion artifacts. Examination of the pelvis and hips take place with the leg extended and the foot internally rotated. Examination of the femur, knee and leg take place with the leg extended, while during an exam of the ankle and foot the patient steps onto table, legs bent. If required, additional pads should be placed over the legs to avoid motion artifacts.

Centering:

Patient positioning is done using lasers to the center of the examined joint.

Examination process:

First we make an AP or lateral topogram (scout view) image. The topogram must include the problematic region. Then we have to set the region of interest.

The field-of-view (FOV)

Pelvis: It extends from the top of the iliac crest to the small trochanter of the femur. (<http://>

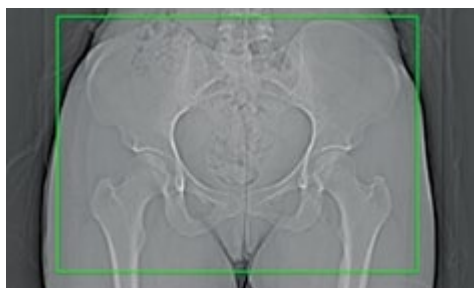


Figure 33. Planning of pelvis CT

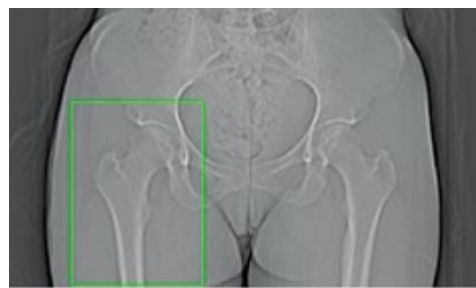

Figure 34. Planning of hip CT

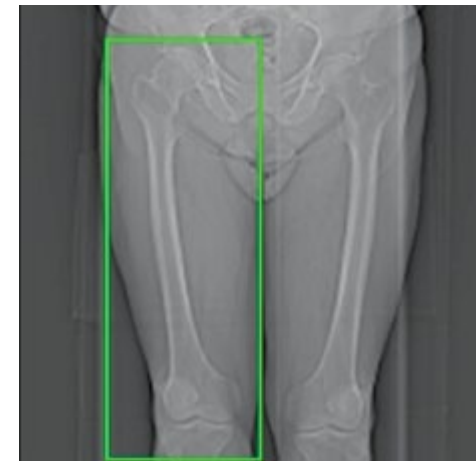

Figure 35. Planning of femur CT

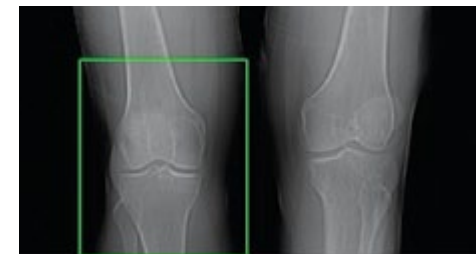


Figure 36. Planning of knee CT

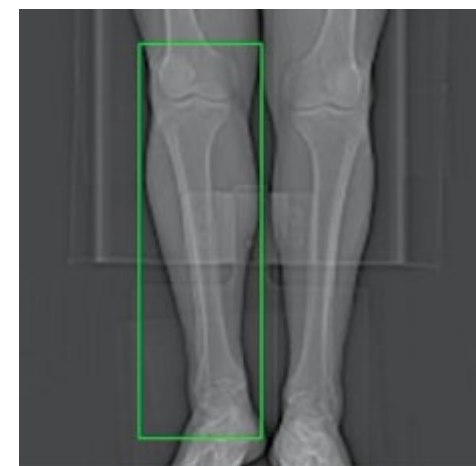

Figure 37. Planning of leg CT




Figure 38. Planning of foot and ankle CT

tamop.etk.pte.hu/tamop412A/Kepalkotasi_gyakorlatok_tananyag/CT/CT_DICOM_Kepek/11_medence.zip

Hip: It covers from the top of the acetabulum to the small trochanter of the femur. (http://tamop.etk.pte.hu/tamop412A/Kepalkotasi_gyakorlatok_tananyag/CT/CT_DICOM_Kepek/12_csipo.zip)

Femur: It is practical to depict both joints (hip and knee), but the joint closest to the lesion is definitely included in the FOV.

Knee: According to the lesion. Normally it covers the area from the distal third of the femur to the proximal third of the tibia. (http://tamop.etk.pte.hu/tamop412A/Kepalkotasi_gyakorlatok_tananyag/CT/CT_DICOM_Kepek/13_terd.zip)

Leg: It is practical to depict both joints (hip and knee), but the joint closest to the lesion is definitely included in the test region.

Foot, ankle: It covers from the malleoli to the bottom of the calcaneus or phalanges. (http://tamop.etk.pte.hu/tamop412A/Kepalkotasi_gyakorlatok_tananyag/CT/CT_DICOM_Kepek/14_boka.zip)

Bone window (C/W: 450/2500) and soft tissue kernel (C/W: 30/300) have to be made. In case of a soft tissue lesion, contrast material administration is required – but in this case, MRI is the most sensitive method – and the post contrast series also has to be made. Coronal and two parasagittal MPR and 3D reconstructions have to be reconstructed. (Figures 33., 34., 35., 36., 37., 38.) (Table 11., 12.)

Table 11. Parameters (femur, knee, leg, ankle)

Scan type	helical
Slice thickness	1.25 mm
Interval	1.25 mm
kV	130
mAs	260
Pitch	0.9
CM volume	(if required) 60-70 ml (350 cc.)
CM speed	2.5 flow (ml/sec)
Delay	0 sec

Table 12. Parameters (pelvis, hip):

Scan type	helical
Slice thickness	2.5 mm
Interval	2.5 mm
kV	130
mAs	260
Pitch	0.9
CM volume	(if required) 50-60 ml (350 cc.)
CM speed	2,5 flow (ml/sec)
Delay	0 sec

Spine CT

For spinal diseases associated with bone degeneration the initial imaging method is X-ray in two or more directions, but for traumatic and orthopedic imaging CT has also gained importance. For the assessment of the severity of spinal injury, CT is the most optimal method. It is more sensitive than conventional radiography for the detection of small fractures and dislocations. By performing a CT scan, we may avoid missing injuries and lesions that may not be seen on conventional x-ray images (such as the displacement of fragments). This will prevent the establishment and use of inappropriate treatment due to the wrong diagnosis. CT is a useful method for surgical planning in case of instability and spinal canal stenosis. However, for the assessment of spinal cord injury and damage, MRI has to be chosen first. Depending on the suf-

fered spinal trauma, several injury types can be distinguished (flexion, extension, compression, rotation, translation). With the use of CT, the main questions that need to be answered involve the degree of stability of the fracture, and the determination of myelon and/or nerve compression. Injuries involving the spine occur most commonly in the cervical and cervico-thoracic junction. MRI has assumed a leading role for imaging the intervertebral disc space and its relationship to the myelon but imaging of the lumbar spine (http://tamop.etk.pte.hu/tamop41-2A/Kepalkotasi_gyakorlatok_tananyag/CT/CT_DICOM_Kepek/17_lgo_seq_hernia.zip) is still a frequent indication for CT scanning. CT offers the advantages of its ready availability and the better delineation of skeletal structures.

Bone density measurement is possible with the Osteo CT scan (this is an optional software), although their use is continuously fading because DEXA centers are becoming more and more available. In addition to non-enhanced CT scanning, we can make myelographic studies, too. In case of CT myelography, the patient receives the contrast agent at least 4-6 hours before the test, to avoid the disturbing artifacts due to high contrast density. To avoid the sedimentation of the contrast agent, the patient should turn prone and supine repeatedly before the exam. In MR-myelography, it is not necessary to administer a contrast agent to the patient, because the high signal intensity of the liquor is detected by heavily T2 weighted sequences. In this case, when we make the primary images only for 3D reconstruction (SSD, VR) we have to choose an overlap of 50% between the slices and use a soft kernel (B10) to achieve proper image quality without noise. Only for SSD reconstruction can we reduce the dose up to 50% by decreasing the kV.

Imaging of the regions of spine:

- Cervical spine CT
- Thoracic spine CT
- Lumbar spine CT

Cervical spine CT

Indications:

Degenerative changes, spondylosis, spondylarthrosis, fractures, traumatic spinal canal involvements, tumor lesions. (http://tamop.etk.pte.hu/tamop412A/Kepalkotasi_gyakorlatok_tananyag/CT/CT_DICOM_Kepek/15_nyak.zip)

Patient preparation:

The patient should remove all metallic objects (e.g.: jewellery, hairgrips) from the examined region.

Patient positioning:

For CT examinations of the cervical spine, the patient is placed in a head-first supine position, arms close to the body. His head is placed in the head support.

Centering:

Patient positioning is done using lasers to the center of the neck.

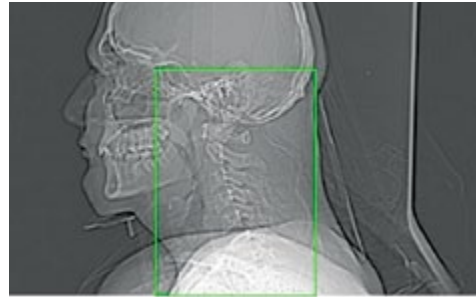

Figure 39. Planning of cervical spine CT

Examination process:

First we make an AP and a lateral topogram (scout view) image. The topogram must include the whole cervical spine. Then we have to set the region of interest. The field-of-view (FOV) extends from the external auditory meatus to T I.-II. When examining the cervico-thoracic junction, the FOV have to be set according to the trauma region. Make sure that above and below the injured site one intact segment is included in the FOV. Thin slice images with bone window (C/W: 500/2500) have to be acquired. Coronal and two parasagittal MPR and 3D reconstructions also have to be reconstructed. (Figure 39.) (Table 13.)

Table 13. Parameters

Scan type	helical
Slice thickness	0.625 mm
Interval	0.625 mm
kV	130
mAs	260
Pitch	0.9

Thoracic spine CT

When examining the thoracic spine normally you should depict only the injured region because examining the whole thoracic spine (T I.-XII.) will cause a high radiation exposure to the patient. (http://tamop.etk.pte.hu/tamop412A/Kepalkotasi_gyakorlatok_tananyag/CT/CT_DICOM_Keppek/16_th_L_go.zip)

Indications:

Intervertebral disc lesions, degenerative diseases, tumours, trauma.

Patient preparation:

The patient should remove all metallic objects (e.g.: jewelleries, clothes) from the examined region.

Patient positioning:

For CT examinations of the thoracic spine, the patient is placed in a head-first supine position, with the arms raised above his head.

Centering:

Patient positioning is done using lasers to the xyphoid process.

Examination process:

First we make an AP and a lateral topogram (scout view) image. The topogram must include the whole cervical spine. Then we have to set the region of interest. In order to count the vertebrae safely it is useful to make at least one topogram of the whole spine. The FOV has to be set according to the trauma region. Make sure that above and below the injured site one intact segment is included in the FOV. Thin slice images with bone window (C/W: 500/2500) have to be taken. Coronal and two parasagittal MPR and 3D reconstructions, for surgical planning, also have to be reconstructed. (Figure 40.) (Table 14.)

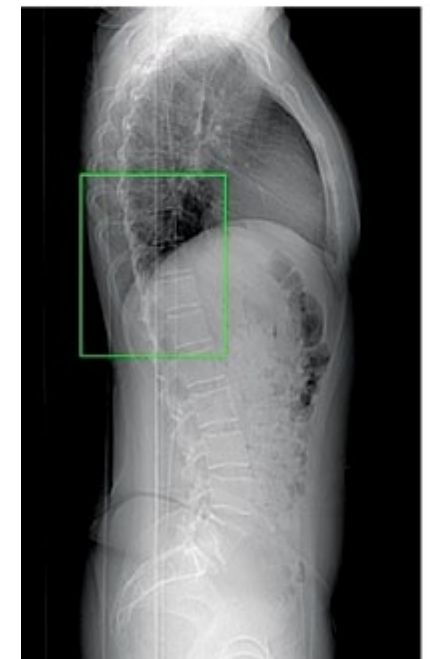
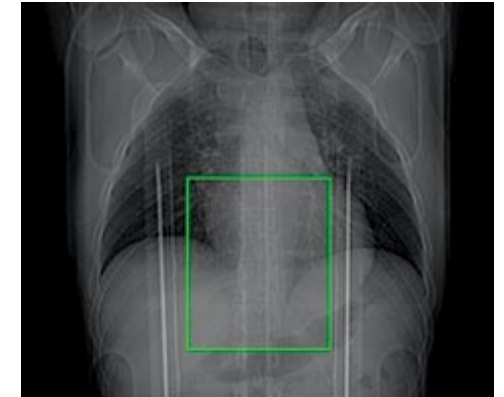
Figure 40. Planning of T VIII.-XII. vertebra CT on AP and lateral topograms

Table 14. Parameters

Scan type	helical
Slice thickness	0.625 mm
Interval	1 mm
kV	130
mAs	260
Pitch	0.9

Lumbar spine CT

As already mentioned, the lumbar spine discs can be examined using CT (http://tamop.etk.pte.hu/tamop412A/Kepalkotasi_gyakorlatok_tananyag/CT/CT_DICOM_Kepek/17_Igo_seq_hernia.zip) instead of MRI. In addition, trauma and bony destruction may also be indications of lumbar spine CT.

Patient preparation:

Patient should remove all metallic objects (e.g.: jewellery, clothes) from the examined region.

Patient positioning:

For CT examination of the lumbar spine, the patient is placed in a head-first supine position, with the arms raised above his head. (http://tamop.etk.pte.hu/tamop412A/Kepalkotasi_gyakorlatok_tananyag/CT/CT_Videok/lumbalis-HF-SUP-craniocaudal_en.avi)

Centering:

Patient positioning is done using lasers to the xyphoid process.

Examination process:

First we make an AP and a lateral topogram (scout view) image. The topogram must include the whole lumbar spine. Then we have to set the region of interest. In order to count the ribs safely, it is useful to make at least one topogram of the whole spine (from the jugulum to the iliac crest). The FOV has to be set according to the trauma region or in case of a hernia it extends from L II. to S. I.. Make sure that above and below the injured site one intact segment is included in the FOV. Thin slice images with bone window (C/W: 500/2500) and/or soft tissue window (C/W: 40/350) have to be taken. If the patient had a surgery due to lumbar hernia, contrast material administration may be necessary to distinguish recidiv hernia from scar. In this case, after the non-enhanced series we have to acquire a post-contrast series, too. Paracoronal CPR (to visualize the nerve secessions), sagit-

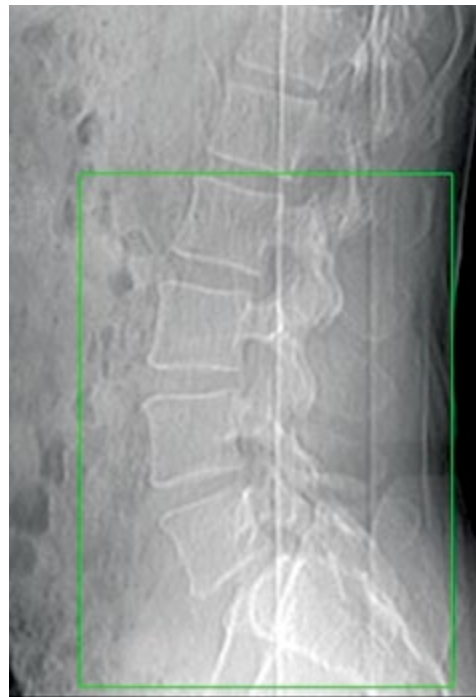

Figure 41. Planning of lumbar spine CT

tal MPR, paraaxial MPR (slices are parallel to each disc) and for surgical planning 3D reconstructions also have to be made. (Figure 41.) (Table 15.)

Table 15. Parameters

Scan type	helical
Slice thickness	0.625 mm
Interval	0.625 mm
kV	140
mAs	350
Pitch	1.3
CM volume	(if required) 50-60 ml (350 cc.)
CM speed	2.5 flow (ml/sec)
Delay	0 sec

II.7. CT imaging of the neck, mediastinum and chest wall

CT imaging of the neck

CT is an established imaging modality for the examination of the head and neck, but is increasingly being superseded by magnetic resonance imaging, especially in cooperative patients. A simple rule of thumb is that CT is preferable for inflammatory pathology, while MRI is preferred for tumor imaging. The development of short bore magnets, fast imaging sequences, phased array neck coils, and dedicated protocols have led to an increased use of MRI, while with the advent of multislice helical CT some of the indications may shift back to CT.

CT has advantages and should be used as the primary modality in several circumstances:

- intensive care patients: shorter examination time, better monitoring
- severely debilitated patients: shorter examination time, less motion artifact
- patients with suspected destructive bone lesions or bone erosion

All in all, in many patients, CT and MRI are complementary imaging modalities. Modern ultrasonography also has a major role in imaging the neck. This is a primary modality

for evaluating the superficial parotid and the thyroid glands. Combined with ultrasound guided fine needle aspiration it is probably the most reliable technique for evaluation of lymph node staging.

Neck soft tissue CT

http://tamop.etk.pte.hu/tamop412A/Kepalkotasi_gyakorlatok_tananyag/CT/CT_DICOM_Keppek/18_nyak_mellkas_has.zip

Indications:

Detection, characterization, TNM-staging of tumours and depiction of bone erosion. Assessment of the extent of infectious processes, and abscess formation. Differentiation of infection from tumour. Evaluation of the extent, and characterization of congenital diseases. Trauma: laryngotracheal injury and vascular injury.

Patient preparation:

The patient does not eat 5 hours before the contrast enhanced test. Make sure that all diabetes medication (which are on the black list) are omitted before the study. The patient should remove all metallic objects (e.g.: jewellery, hairpins, denture) from the examined region. In case of an enhanced CT exam, venous preparation is essential. The intravenous line, must be inserted into the right cubital vein, then the patient has to be connected to the injector, or we can manually administer the contrast agent.

Patient positioning:

For CT examinations of the neck, the patient is placed in a head-first supine position, arms close to the body. His head is in the head support.

Centering:

Patient positioning is done using lasers.

Examination process:

First we make a topogram image (scout view) in the AP and lateral directions. The topogram must include the whole skull and the upper part of the chest. Then we have to set the region of interest. The field-of-view (FOV) covers the area between the skull and the aortic arch without tilting. After setting the FOV, the non contrast series has to be made. Before acquiring the contrast enhanced series, we take one slice at the height of the aortic arch. We do this to measure the density of the administered contrast agent, and to acquire precise contrast enhanced images by putting the ROI into the aortic arch. If required (e.g. tumour), the post contrast series with thin slices has to be made, too. For laryngeal diseases, during the examination, the patient is asked to say the letter "e". MPR and virtual bronchoscopy reconstructions have to be made, too. (Figure 42.) (Table 16.)

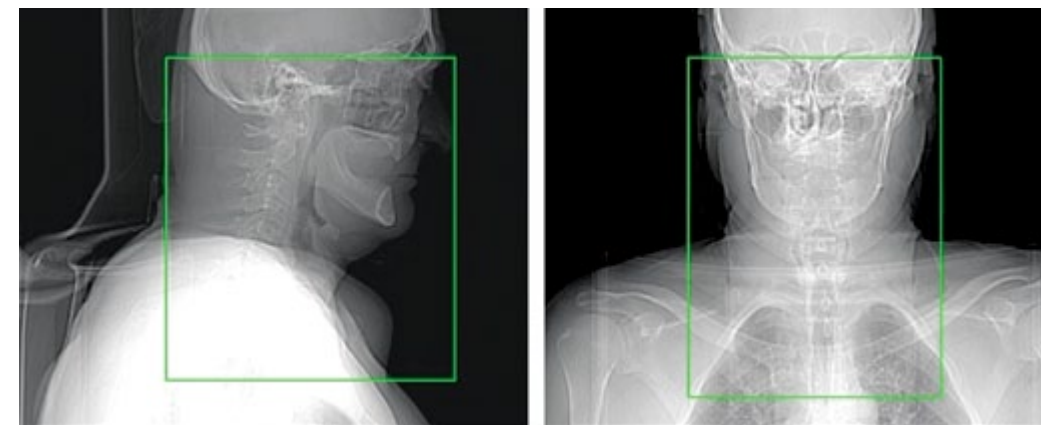


Figure 42. Planning of neck CT

Table 16. Parameters

Scan type	helical
Slice thickness	n.e.: 2.5 mm, post cm.: 1.25 mm
Interval	n.e.: 2.5 mm, post cm.: 1.25 mm
kV	130
mAs	260
Pitch	1.325
CM volume	70 ml (350 cc.)
CM speed	2.5 flow (ml/sec)
Delay	0 sec (only postcontrast series: 50 sec)

CT imaging of the mediastinum and chest wall

http://tamop.etk.pte.hu/tamop412A/Kepalkotasi_gyakorlatok_tananyag/CT/CT_DICOM_Kep/18_nyak_mellkas_has.zip

Imaging of the mediastinum is possible with transoesophageal ultrasound, x-ray, fluoroscopy, CT and MRI. Compared to x-rays, CT and US give much more information. Functional imaging fluoroscopy may give appropriate answers in many cases, but regarding morphological information, it is not comparable to CT and transoesophageal US. The advantages of CT are good spatial resolution, the availability of multiplanar imaging, and the better visualisation of calcified lesions. Transoesophageal US is much more of a strain on the patient compared to CT, and it requires a longer preparation. In comparison, a CT exam is faster and easier to carry out than US. MRI is used only when CT is unavailable to provide answers in certain cases.

Scanning of the mediastinum, pleura, or chest wall is usually done as part of a general thoracic CT examination. A more focused examination of tumors, hilar lymph nodes, or the chest wall benefits from coronal or sagittal reformations.

Indications:

Tumor – characterization – staging, lymph node assessment, oesophagus disease, empyema, abscess, pleural lesions, calcifications, pleural and chest wall lesions, chest trauma, pulmonary embolism and other vascular diseases.

Patient preparation:

The patient does not eat 5 hours before the contrast enhanced test. Make sure that all diabetes medication (which are on the black list) are omitted before the study. The patient should remove

all metallic objects (e.g.: jewellery, hairpins, denture) from the examined region. For an enhanced CT exam, venous preparation is essential. The intravenous line - if it is possible - must be inserted into the right cubital vein, then the patient is connected to the injector, or we can manually administer the contrast agent. The exam is carried out in breath-hold. In case of an oesophageal lesion, the patient may have to drink a small amount of gastrografin solution immediately before the non-enhanced series.

Patient positioning:

For CT examinations of the chest, the patient is placed in a head-first supine position, arms lifted above the head. (http://tamop.etk.pte.hu/tamop412A/Kepalkotasi_gyakorlatok_tananyag/CT/CT_Videok/mellkas-has-HF-SUP-craniocaudal_en.avi)

Centering:

Patient positioning is done using lasers.

Examination process:

First we make a topogram image (scout view) in the AP and lateral directions. The topogram must include the whole chest and the upper abdomen. Then we have to set the region of interest. The field-of-view (FOV) covers the area from the jugular fossa to the lower pole of the kidneys without tilting. After setting the FOV, the non-contrast series has to be made. Before the contrast enhanced series, we acquire one slice at the height of the pulmonary trunk. This is done to measure the density of the administered contrast agent (100 HU) and to acquire precise contrast enhanced images by putting the ROI into the pulmonary trunk. The post contrast series has to be made, too. Sagittal and coronal MPR and virtual bronchoscopy reconstructions also have to be made. For visualization of the soft tissues, use a soft kernel (B41) with a narrow window (C/W:40/400); for visualisation of the lung use a sharp kernel (B60-B70-B80) with a wide window (C/W: 650/1500). (Figure 43.) (Table 17.)

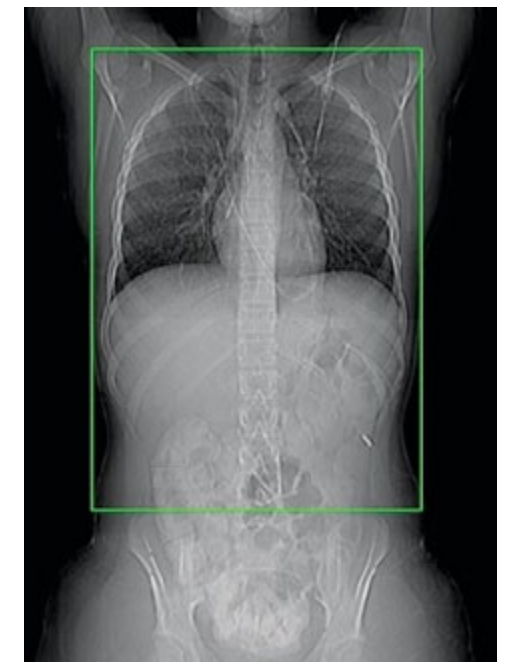

Figure 43. Planning of chest CT

Table 17. Parameters

Scan type	helical
Slice thickness	5 mm
Interval	5mm
kV	130
mAs	260
Pitch	1.375
CM volume	70-90 ml (350 cc.)
CM speed	2.5 flow (ml/sec)
Delay	ROI (100 HU)

II.8. CT imaging of the lung

http://tamop.etk.pte.hu/tamop412A/Kepalkotasi_gyakorlatok_tananyag/CT/CT_DICOM_Kep/18_nyak_mellkas_has.zip

Because of their high air content, the lungs are invisible for US. For this reason US and MRI are not part of the imaging modalities of the lungs. For the same reason, due to its low tissue density, x-ray imaging of the lungs is possible at a lower dose compared to other body regions. Almost all lung diseases can be diagnosed with x-ray or fluoroscopy, although, much more information can be obtained by using CT and HRCT due to their better spatial resolution, and the lack of overlap between high density tissues. With virtual bronchoscopy we may see much farther within the tracheo-bronchial system than using conventional bronchoscopy, but of course, virtual bronchoscopy does not replace conventional bronchoscopy.

Imaging of the regions of the chest:

- Lung CT
- HRCT
- Virtual bronchoscopy

Indications:

Tumor diagnosis (pulmonary and mediastinal tumors, metastases), tumor characterization (solitary nodule), tumor staging. Detection and quantification of infectious processes, cavitation, asbestosis, silicosis, emphysema, bronchiectasis.

Congenital anomalies (trachea, bronchi, pulmonary vessels, heart and major blood vessels), sequestration, AVM, assessment of the nature and number of lesions and tracking their growth. Localization prior to biopsy, bronchoscopy, bronchoalveolar lavage. Differentiation of pulmonary from pleural lesions. Localization for open lung biopsy or bronchoalveolar lavage.

Patient preparation:

The patient does not eat 5 hours before the contrast enhanced test. Make sure that all diabetes medication (which are on the black list) are omitted before the study. The patient should remove all metallic objects (e.g.: jewellery, hairgrips, denture) from the examined region. For an enhanced CT exam, venous preparation is essential. The intravenous line – if possible – must be inserted into the right cubital vein, then the patient is connected to the injector, or we can manually administer the contrast agent. The exam is carried out in breath-hold.

Patient positioning:

For CT examinations of the chest, the patient is placed in a head-first supine position, arms lifted above his head. In the supine position, the density of the lungs increase from anterior to posterior (in inhalation: by 20 ± 10 HU, in expiration: by 150 ± 20 HU). This hypostatic density increase has a similar appearance as subpleural fibrosis, that is why the exam may be carried out in two patient positions (prone and supine) to differentiate the two. This method can be used to differentiate oedema and infiltrates, too. ([http://tamop.etk.pte.hu/tamop412A/Kepalkotasi_gyakorlatok_tananyag/CT/CT_Videok/mellkas-has HF-SUP-craniocaudal_en.avi](http://tamop.etk.pte.hu/tamop412A/Kepalkotasi_gyakorlatok_tananyag/CT/CT_Videok/mellkas-has-HF-SUP-craniocaudal_en.avi))

To aid differential diagnosis, the exam can be taken in inhalation and expiration.

The following diseases can be differentiated with this method:

- cavities, bullae – early cavities with an obstructive origin: the size of the area behind the obstruction does not change
- oedema – fibrosis: the size of fibrosis does not change
- lesion fixation close to the chest wall refers to chest wall propagation

Centering:

Patient positioning is done using lasers.

Examination process:

First we make a topogram image (scout view) in the AP and the lateral directions. The topogram must include the whole chest and the upper abdomen. Then we have to set the region of interest. The field-of-view (FOV) covers the area from the jugular fossa to the lower pole of the kidneys without tilting. After setting the FOV, the non-contrast series has to be made. Before acquiring the contrast enhanced series, we take one slice at the height of the pulmonary trunk. This is done to measure the density of the administered contrast agent (100 HU) and to acquire precise contrast enhanced images by putting the ROI into the pulmonary trunk. After administration of the contrast material, injecting 20-30 ml of saline can extend the contrast effect. The post contrast series has to be made, too. Sagittal

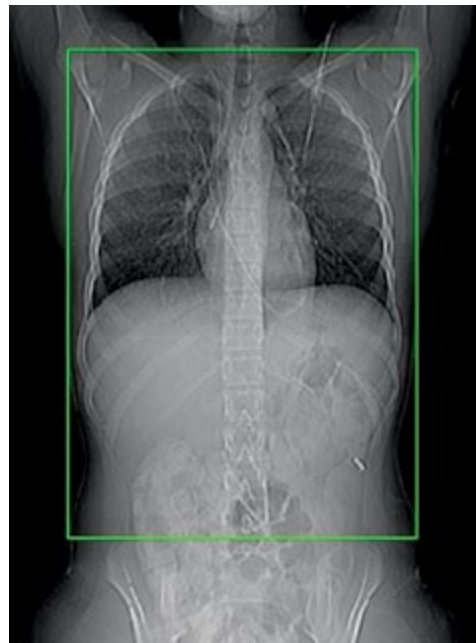

Figure 44. Planning of lung CT

and coronal MPR and virtual bronchoscopy reconstructions have to be made as well. For visualization of the soft tissues use a soft kernel (B41) with a narrow window (C/W:40/400); for visualisation of the lung use a sharp kernel (B60-B70-B80) with a wide window (C/W: -650/1500). (Figure 44.) (Table 18.)

Table 18. Parameters

Scan type	helical
Slice thickness	5 mm
Interval	5 mm
kV	130
mAs	260
Pitch	1.375
CM volume	70-90 ml (350 cc.)
CM speed	2.5 flow (ml/sec)
Delay	ROI (100 HU)

HRCTIndications:

Diffuse lung diseases, detection of subtle parenchymal changes, morphologic characterization, quantification of parenchymal changes.

Patient preparation:

The patient does not eat 5 hours before the contrast enhanced test. Make sure that all diabetes medication (which are on the black list) are omitted before the study. The patient should remove all metallic objects (e.g.: jewellery, hairgrips, denture) from the examined region. In case of an enhanced CT exam, venous preparation is essential. The exam is carried out in breath-hold (inhalation and expiration).

Patient positioning:

For CT examinations of the chest, the patient is placed in a head-first supine position, arms lifted above his head. ([http://tamop.etk.pte.hu/tamop412A/Kepalkotasi_gyakorlatok_tananyag/CT/CT_Videok/mellkas-has HF-SUP-craniocaudal_en.avi](http://tamop.etk.pte.hu/tamop412A/Kepalkotasi_gyakorlatok_tananyag/CT/CT_Videok/mellkas-has-HF-SUP-craniocaudal_en.avi))

Centering:

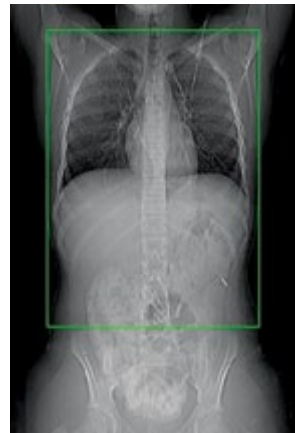Patient positioning is done using lasers.

Examination process:

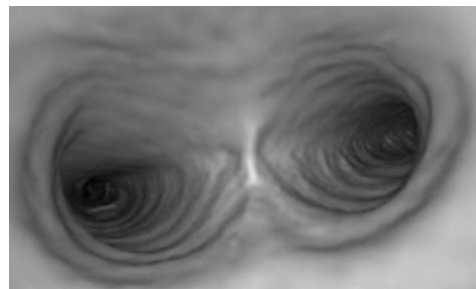
First we make a topogram image (scout view) in the AP and the lateral directions. The topogram must include the whole chest and the upper abdomen. Then we have to set the region of interest. The field-of-view (FOV) covers the area from the lung apex to the phrenicocostal sinus without tilting. After setting the FOV, the non contrast series has to be made. For visualization of the lungs, use a sharp kernel (B70) with a wide window (C/W: -500/1500). (Figure 45.) (Table 19.)

Table 19. Parameters

Scan type	sequential
Slice thickness	1.2 mm
Interval	10 mm
kV	130
mAs	260
Pitch	-
CM volume	-
CM speed	-
Delay	-

**Figure 45. Planning of HRCT****Virtual bronchoscopy**

Virtual bronchoscopy reconstruction is recommended for all neck and chest examinations. It helps to assess space-occupying processes and lesions that cause dislocation of the trachea. Planning of the virtual bronchoscopy reconstruction is done from the non-enhanced series. On coronal cross-sectional images we find the trachea, and at the height of the thyroid cartilage we insert the navigator into it. With auto run, we direct the navigator to the desired branches, and thus we get a continuous series of images. (Figure 46.)

**Figure 46. Image of virtual bronchoscopy reconstruction at the height of the trachea bifurcation****Animation 7. Virtual bronchoscopy**

http://tamop.etk.pte.hu/tamop412A/Kepalkotasi_gyakorlatok_tananyag/CT/CT_Animaciok/virtend/index.html

II.9. CT imaging of the vascular and lymphatic system**Imaging of vascular system**

CT angiography (CTA) has revolutionized vascular imaging. Vessels smaller than 1 mm in diameter can be visualized with single slice CTA, and vessels 2 mm or more in diameter can be diagnostically evaluated. The acquisition of 3D data volumes makes it possible to generate "angiographic" views that facilitate anatomic orientation. With the advent of multislice CTA, near isotropic resolution becomes available for most applications and allows for evaluation of even smaller vessels. Multislice scanning makes CTA less technically challenging and more robust. It reduces scan time and the vulnerability to motion artifacts, and may be used to substantially decrease the required contrast material volume to as little as 50 ml in selected cases. The advantages of CTA over arterial angiography (DSA) include substantially lower invasiveness, less cost, less radiation exposure, and better patient tolerance.

Diagnostic advantages include the simultaneous visualization of vessel wall and lumen, and the ability to study vascular anatomy from arbitrary viewing angles using only one data acquisition. CTA even allows for projections (such as caudocranial) that cannot be obtained with conventional angiographic techniques. Although CTA can replace diagnostic intra-arterial DSA for many indications, the poorer spatial resolution in comparison with intra-arterial DSA is a limiting factor in patients in whom diagnostic evaluation of small vessels is required. Ultrasound with its various Doppler techniques may be preferred over CTA in regions that are easily accessible by sonography or when flow information is required. It also holds advantages whenever bedside imaging is to be preferred. Contrast-enhanced magnetic resonance angiography (MRA) offers competitive results to CTA, although spatial resolution is often lower than with multislice CT scanning.

The lack of ionizing radiation of MRA is important in young patients, for vascular screening, and for patients requiring repeated follow-up examination. In patients with impaired renal function, contrast-enhanced MRA requires less (and therefore less nephrotoxic) contrast material. Dynamic MRA examinations offer therapeutically relevant additional information in only a relatively small number of cases. Flow quantification with MR may gain increasing importance for therapeutic decision-making. In acute lifethreatening diseases such as aortic aneurysm, aortic rupture, or pulmonary embolism, CTA is the procedure of choice owing to the short examination time, easier patient monitoring, and less reliance on patient compliance. The most commonly examined regions are the head, neck, chest, abdomen and lower extremities.

Advantages of CTA:

- due to sub-mm resolution, higher speed injection and higher contrast agent concentration, a lesser volume of contrast agent is sufficient with fast measurement times
- the lumen and wall of the vessel and the perivascular region are visualized simultaneously, which is good for the evaluation of dissection, inflammatory conditions, and tumors
- different vascular stents cause less artifacts, and there are fewer artifacts due to perfusion
- less invasive
- high spatial resolution
- good tissue characterization
- rapid mapping
- making MPR, MIP, 3D and special (vessel) reconstructions

Disadvantages of CTA:

- radiation exposure
- stationary imaging, not dynamic
- direct multiplanar imaging not possible

Indications:

Aorta: all lesions affecting the aorta or its wall (arch anomaly, coarctation, aneurysm, dissection, stenosis, occlusion, arteritis, trauma)

Renal: suspected stenosis, evaluation for arteries PTA

Hepatic: preoperative vascular anatomy, detection of stenosis or occlusion after liver transplantation

Carotid: suspected stenosis, aneurysms, dissection

Pulmonary: pulmonary embolism, AV malformation, arteritis, chronic thromboembolic pulmonary hypertension, congenital anomalies

Vena cava: suspicion of thrombosis, tumor invasion (equivocal ultrasound findings)

Complications: hemorrhage, infections, bypass thrombosis, anastomotic aneurysm

To perform CTA it is very important that in the examined region contrast enhancement of the blood vessels is sufficient. To achieve the best spatial resolution try to select the lowest effective slice thickness for the study. For very small slice thickness, the signal-to-noise ratio increases, that is why a slice thickness of 1.25 to 3 mm is best, depending on the patient's physique and the test region as well.

Head CT angiography*Indications:*

Stroke (ischemic, hemorrhagic), non-traumatic subarachnoid hemorrhage (SAV) and various malformations (aneurysm).

Patient preparation:

The patient should not eat 5 hours before the contrast enhanced test. Make sure that all anti-diabetic medication, which are on the black list, are omitted before the study. The patient should remove all metallic objects (e.g.: jewellery, hairpins, denture) from the examined region. Preparation of a venous access is essential. The intravenous line, if it is possible, must be inserted into the right cubital vein. Then the patient can be connected to the injector, or we can manually administer the contrast agent.

Patient positioning:

For CTA examinations of the brain, the patient is placed in a head-first supine position, arms close to the body. His head is in the head support. (http://tamop.etk.pte.hu/tamop412A/Kepalkotasi_gyakorlatok_tananyag/CT/CT_Videok/Koponya-craniocaudal_en.avi)

Centering:

Patient positioning is done using lasers.

Examination process:

First we make a topogram (scout view) in the lateral direction. The topogram must include the whole face and cerebrum. Then we have to set the region of interest. The field-of-view (FOV) covers the area from the skull base to the vertex without tilting. Before the contrast enhanced series we take one slice at the height of the aortic arch. This is done to measure the density of the administered contrast agent (100 HU) and to acquire precise contrast enhanced images by putting the ROI into the aortic arch. After the administration of contrast material, injecting 20-30 ml of saline can extend the contrast effect. Coronal and sagittal MPR, MIP and 3D reconstructions have to be made. Images with a soft kernel (B41) and a narrow window (C/W:50/300) have to be made (Figure 47.) (Table 20.).

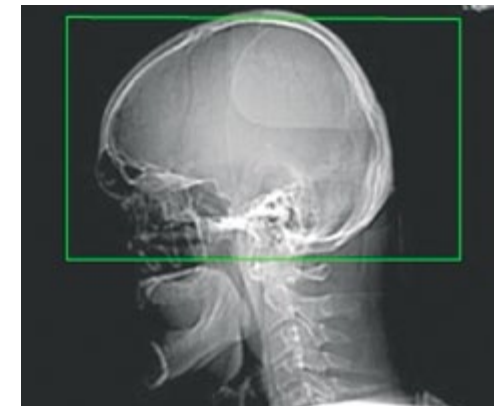

Figure 47. Planning of head CTA

Table 20. Parameters

Scan type	helical
Slice thickness	0.625 mm
Interval	0.625 mm
kV	110
mAs	200
Pitch	0,9
CM volume	80 ml (350 cc.)
CM speed	3.5-4 flow (ml/sec)
Delay	ROI

Neck CTA

Indications:

Carotid arteries, intracranial arteries, evaluation of various vascular obliterative processes, accurate detection of the location of the aneurysm.

Patient preparation:

The patient should not eat 5 hours before the contrast enhanced test. Make sure that all anti-diabetic medication, which are on the black list, are omitted before the study. The patient should remove all metallic objects (e.g.: jewelleries, hairgrips, denture) from the examined region. Venous preparation is essential. The intravenous line, if it is possible, must be inserted into the right cubital vein. Then the patient can be connected to the injector, or we can manually administer the contrast agent.

Patient positioning:

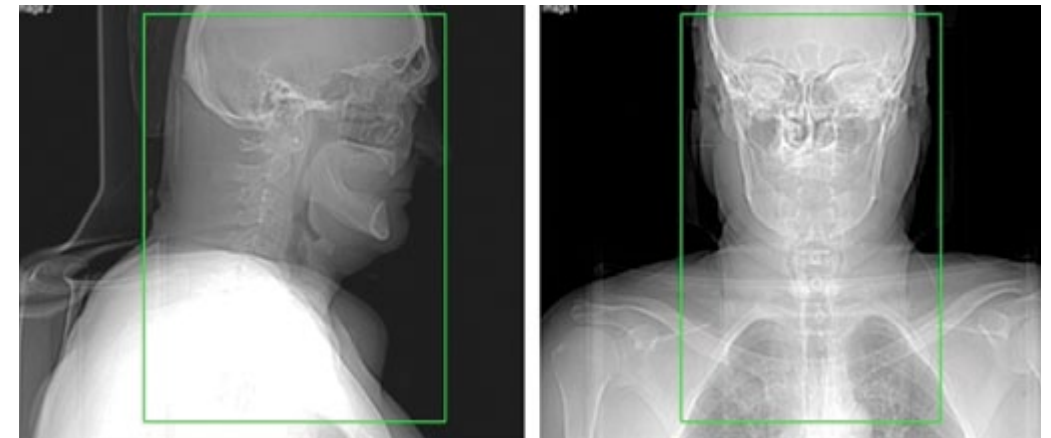
For CTA examinations of the brain, the patient is placed in a head-first supine position, arms close to the body. His head is in the head support.

Centering:

Patient positioning is done using lasers.

Examination process:

First we make a topogram (scout view) in the lateral and AP directions. The topogram must include the whole skull and the upper part of the chest. Then we have to set the region of interest. The field-of-view (FOV) covers the region between the mastoid cells

*Figure 48. Planning of neck CTA*

and aortic arch without tilting. After setting the FOV, the contrast enhanced series has to be made. Before acquiring the contrast enhanced series, we take one slice at the height of the aortic arch. This is done to measure the density of the administered contrast agent and to acquire precise contrast enhanced images by putting the ROI into the aortic arch. After the administration of the contrast material, injecting 20-30 ml of saline can extend the contrast effect. If required, the post contrast series with a thin slice thickness has to be made as well. Coronal and sagittal MPR and MIP, 3D reconstructions also have to be made. Images with a soft kernel (B41) and with a narrow window (C/W:40/350) have to be made. (Figure 48.) (Table 21.)

Table 21. Parameters

Scan type	helical
Slice thickness	2.5 mm
Interval	2.5 mm
kV	130
mAs	260
Pitch	1.3
CM volume	90 ml (350 cc.)
CM speed	3.5-4 flow (ml/sec)
Delay	ROI

Chest CTA

Indications:

Thoracic aortic aneurysm, aortic dissection, assessing vascular conditions of tumours before surgery.

Patient preparation:

The patient should not eat 5 hours before the contrast enhanced test. Make sure that all anti-diabetic medication, which are on the black list, are omitted before the study. The patient should remove all metallic objects (e.g.: jewellery, dresses) from the examined region. Venous preparation is essential. The intravenous line, if it is possible, must be inserted into the right cubital vein. Then the patient can be connected to the injector, or we can manually administer the contrast agent. The exam is carried out in breath-hold. (http://tamop.etk.pte.hu/tamop412A/Kepalkotasi_gyakorlatok_tananyag/CT/CT_Videok/mellkas-has_HF-SUP-craniocaudal_en.avi)

Patient positioning:

For CT examinations of the chest, the patient is placed in a head-first supine position, arms lifted above his head.

Centering:

Patient positioning is done using lasers.

Examination process:

First we make a topogram (scout view) in the lateral and AP directions. The topogram must include the whole chest and the upper abdomen. Then we have to set the region of interest. The field-of-view (FOV) covers the area from the jugular fossa to the phrenicocostal recess without tilting. After setting the FOV, the contrast enhanced series has to be made. Before the contrast enhanced series we take one slice at the height of the aortic arch. This is done to measure the density of the administered contrast agent (100 HU) and to acquire precise contrast enhanced images by putting the ROI into the aortic arch. After the administration of the contrast material, injecting 20-30 ml of saline can extend the contrast effect. If required, the non-enhanced and post contrast se-

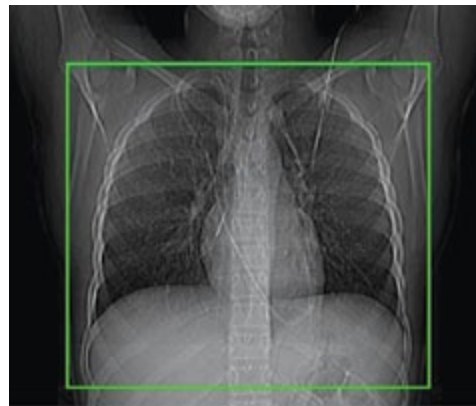

Figure 49. Planning of chest CTA

ries also have to be made as well. Images with a soft kernel (B41) and with a narrow window (C/W:30/340) have to be made. Sagittal and coronal MPR, MIP and 3D reconstructions also have to be made. (Figure 49.) (Table 22.)

Table 22. Parameters

Scan type	helical
Slice thickness	1.25 mm
Interval	1.25 mm
kV	130
mAs	260
Pitch	1.375
CM volume	90-100 ml (350 cc.)
CM speed	3.5-4 flow (ml/sec)
Delay	ROI (100 HU)

Pulmonary embolism CT

In suspected pulmonary embolism the first testing method is CT, especially if the emboli is in the pulmonary arteries. Nowadays, detection of subsegmental emboli is possible with CT, but in this case, in some centers, the isotope diagnostic test is still applied.

Patient preparation:

The patient should not eat 5 hours before the contrast enhanced test. Make sure that all anti-diabetic medication, which are on the black list, are omitted before the study. The patient should remove all metallic objects (e.g.: jewellery, dresses) from the examined region. Venous preparation is essential. The intravenous line, if it is possible, must be inserted into the right cubital vein. Then the patient can be connected to the injector, or we can manually administer the contrast agent. The exam is carried out in breath-hold.

Patient positioning:

For CT examinations of the chest, the patient is placed in a head-first supine position, arms lifted above his head.

Centering:

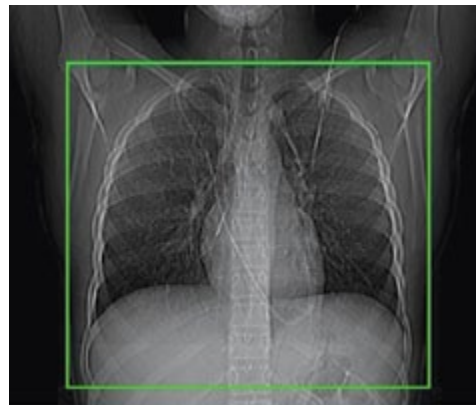Patient positioning is done using lasers.

Examination process:

First we make a topogram (scout view) in the lateral and AP directions. The topogram must include the whole chest and the upper abdomen. Then we have to set the region of interest. The field-of-view (FOV) covers the area from the jugular fossa to the phrenicocostal recess without tilting. After setting the FOV, the contrast enhanced series has to be made. Before the contrast enhanced series, we take one slice at the height of the pulmonary trunk. This is done to measure the density of the administered contrast agent (80 HU) and to acquire precise contrast enhanced images by putting the ROI into the pulmonary trunk. After the administration of the contrast material, injecting 20-30 ml of saline can extend the contrast effect. If required, the non-enhanced and post contrast series also have to be made as well. Images with a soft kernel (B41) and with a narrow window (C/W:30/340) and with lung window (C/W: -500/1000) have to be made. Sagittal and coronal MPR, MIP, virtual bronchoscopy and 3D reconstructions also have to be made. (Figure 50.) (Table 23.)

Table 23. Paramétere

Scan type	helical
Slice thickness	2.5 mm
Interval	2.5 mm
kV	130
mAs	260
Pitch	1.375
CM volume	100 ml (350 cc.)
CM speed	3.5-4 flow (ml/sec)
Delay	ROI (80 HU)

**Figure 50. Planning of pulmonary embolism CT****Abdominal CTA****Indications:**

Abdominal aortic aneurysm, aortic dissection, vascular conditions before surgical removal of abdominal tumors, and renal hypertension.

Patient preparation:

The patient should not eat 5 hours before the contrast enhanced test. Make sure that all anti-diabetic medication, which are on the black list, are omitted before the study. The patient should remove all metallic objects (e.g.: jewellery, dresses) from the examined region. Venous preparation is essential. The intravenous line, if it is possible, must be inserted into the right cubital vein. Then the patient can be connected to the injector, or we can manually administer the contrast agent. The exam is carried out in breath-hold.

Patient positioning:

For CTA examinations of the abdomen the patient is placed in a head-first supine position, arms lifted above his head. (http://tamop.etk.pte.hu/tamop412A/Kepalkotasi_gyakorlatok_tananyag/CT/CT_Videok/has-HF-SUP-craniocaudal_en.avi)

Centering:

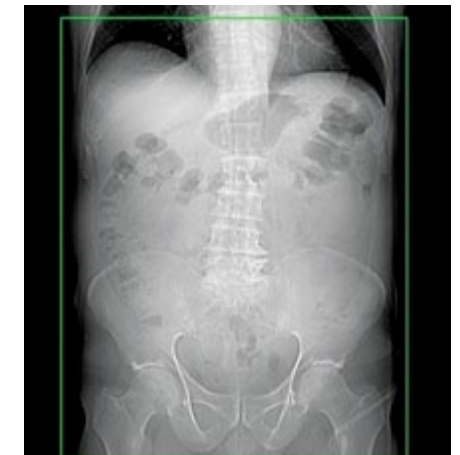Patient positioning is done using lasers.

Examination process:

First we make a topogram (scout view) in the lateral and AP directions. The topogram must include the whole abdomen. Then we have to set the region of interest. The field-of-view (FOV) covers the area from the basal lung segments to the symphysis without tilting. After setting the FOV, the contrast enhanced series has to be made. Before the contrast enhanced series, we take one slice at the height of the descending aorta. This is done to measure the density of the administered contrast agent (100 HU) and to acquire precise contrast enhanced images by putting the ROI into the descending aorta. After the administration of the contrast material, injecting 20-30 ml of saline can extend the contrast effect. If required the non-enhanced and post contrast series have to be made as well. Images with a soft kernel (B41) and with a narrow window (C/W:50/400) have to be made. Sagittal and coronal MPR, MIP and 3D reconstructions also have to be made. (Figure 51.) (Table 24.)

Table 24. Parameters

Scan type	helical
Slice thickness	1.25 mm
Interval	1.25 mm
kV	130
mAs	260
Pitch	1.375
CM volume	100-120 ml (350 cc.)
CM speed	3,5-4 flow (ml/sec)
Delay	ROI (100 HU)

**Figure 51. Planning of abdominal CTA**

In some cases (eg, aortic dissection, extended aortic aneurysm) chest-abdominal angiography may be required. In this case, the parameters are the same as those of the chest and abdominal CTA, the only difference is the FOV, which now covers the area between the the lung apex to the symphysis. (Figure 52.)

Lower extremities CTA

Indications:

Determining the exact location and extent of stenosis occlusion, and collateral circulation.

Patient preparation:

The patient should not eat 5 hours before the contrast enhanced test. Make sure that all anti-diabetic medication, which are on the black list, are omitted before the study. The patient should remove all metallic objects (e.g.: jewellery, dresses) from the examined region. Venous preparation is essential. The intravenous line, if it is possible, must be inserted into the right cubital vein. Then the patient can be connected to the injector, or we can manually administer the contrast agent.

Patient positioning:

For CTA examinations of the lower extremities the patient is placed in a head-first supine position, arms lifted above his head.

Centering:

Patient positioning is done using lasers.

Examination process:

First we make a topogram (scout view) in the lateral and AP directions. The topogram must include the whole abdomen and lower extremities. Then we have to set the region of interest. The field-of-view (FOV) covers the area from the renal arteries to the ankle without tilting. After setting the FOV, the contrast enhanced series has to be made. Before the contrast enhanced series we take one slice at the height of the renal arteries. This is done to measure the density of the administered contrast agent (100 HU) and to acquire precise contrast enhanced images by putting the ROI into the descending aorta. After the administration of the contrast material, injecting 20-30 ml of saline can extend the contrast effect. If required the non-enhanced and post-contrast series have to be made as well. Images with a soft kernel (B41) and with a narrow window (C/W:50/400) have to be made. Sagittal and coronal MPR, MIP and 3D reconstructions also have to be made. (Figure 53.) (Table 25.)

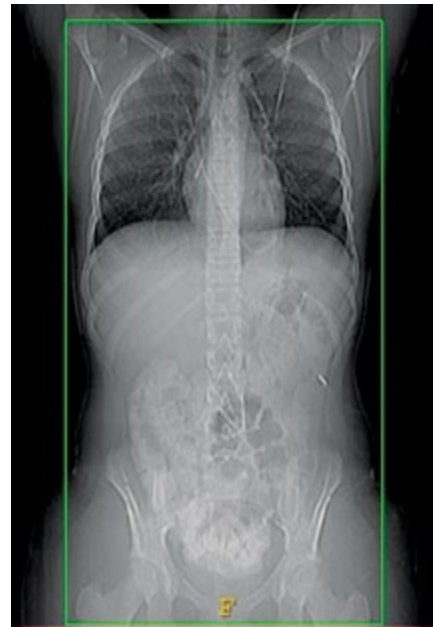

Figure 52. Planning of chest-abdomen CT

Table 25. Parameters

Scan type	helical
Slice thickness	1.25 mm
Interval	0.8 mm
kV	130
mAs	260
Pitch	1.375
CM volume	100-120 ml (350 cc.)
CM speed	3,5-4 flow (ml/sec)
Delay	ROI (100 HU)

Imaging of lymphatic system

Cross-sectional imaging modalities have all but replaced conventional lymphography in examinations of the lymph nodes. When cross-sectional modalities are used, the diagnostic evaluation is based primarily on the size of the lymph nodes and to a lesser degree on morphologic criteria. In doubtful cases the diagnosis should be established by biopsy. Only a few cases currently require exploratory laparotomy or mediastinoscopy. High image quality and reproducibility make CT the primary modality for investigating the mediastinal and abdominal lymph nodes. CT can also image the cervical, axillary, and inguinal nodes, but ultrasound is preferred in these regions because it costs less and provides additional morphologic criteria that aid in the differentiation benign versus malignant of these superficial nodes. Regarding lymphatic imaging, MR lymphangiography should be mentioned as well, although it is used less, however, in some indications (eg, anatomical variants) it proves much more effective than CT.

Indications:

We emphasize CT when imaging the lymphatic system in the following cases:

- Tumours that metastasize to the lymph nodes.
- Staging oncologic patients.

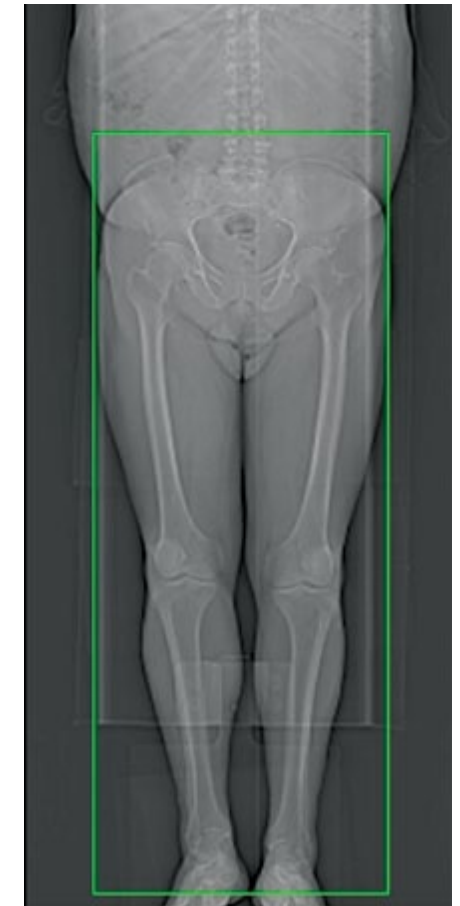


Figure 53. Planning of lower extremities CTA

- Diseases associated with enlarged lymph nodes (sarcoidosis, tuberculosis, amyloidosis, cystic fibrosis).
- Primary tumors that affect the lymphatic system (Hodgkin's and non-Hodgkin's lymphoma).

CT examination of the lymphatic system, is an integral part of tumor staging. In most cases, the imaging area are chosen in accordance with the primary tumour's region. That is why, these protocols and preparation processes are applicable to lymph nodes. Assessment of the lymphatic system is made easier with MPR reconstructions in different directions.

II.10. CT imaging of the liver and the biliary tract

The liver is not only one of our most versatile organs due to the high number of its functions, but its diagnostic imaging is perhaps the most diversified. Ultrasound imaging is not expensive, it is noninvasive, and it provides good morphological characterization; the only downside with this modality is that a very experienced person is needed to overview the total volume of the liver. MR dynamic testing (with the use of Gd containing, and other liver-specific contrast agents) has a substantial role in the imaging of liver function and so does scintigraphy (Tc99m sulfur colloidal or IDA) which is good for the examination of fatty degeneration, liver tumours and focal nodular hyperplasia (FNH) – although the latter is mostly diagnosed by multiphasic CT or MRI. SPECT is an excellent diagnostic test for imaging hemangiomas. The significance of PET is manifested in the oncological disease processes of the liver. Imaging of the bile ducts may be carried out with ultrasound, ERCP (endoscopic retrograde cholangiopancreatography) and MRCP.

Indications:

Tumors – lesions, primary tumors, metastases. Vascular disease – portal vein thrombosis, preoperative arterial anatomy is very helpful in surgery planning. Postoperative conditions – bleeding, abscesses bilioma, malperfusion. Other diseases – trauma, abscess, etc. Invasive CT guided interventions - fluid aspiration, biopsy, cytology.

The liver test is usually part of the total abdominal examination, but depending on the indication it may only be carried out specifically over only the region of the liver.

Abdominal CT

http://tamop.etk.pte.hu/tamop412A/Kepalkotasi_gyakorlatok_tananyag/CT/CT_DICOM_Kepk/18_nyak_mellkas_has.zip

The patient should not eat 5 hours before the contrast enhanced test. Make sure that all anti-diabetic medication, which are on the black list, are omitted before the study. The patient should remove all metallic objects (e.g.: jewellery, dresses) from the examined region. CT of the abdomen/pelvis requires 1000-1500 ml of an oral contrast agent (water or gastrografin) that the patient starts drinking 1-1,5 hours before the test according to the examined region. Venous preparation is essential. The intravenous line, if it is possible, must be inserted into the right cubital vein. Then the patient can be connected to the injector, or we can manually administer the contrast agent. The exam is carried out in breath-hold.

Patient positioning:

For CT examinations of the abdomen the patient is placed in a head-first supine position, arms lifted above his head. (http://tamop.etk.pte.hu/tamop412A/Kepalkotasi_gyakorlatok_tananyag/CT/CT_Videok/has-HF-SUP-craniocaudal_en.avi)

Centering:

Patient positioning is done using lasers.

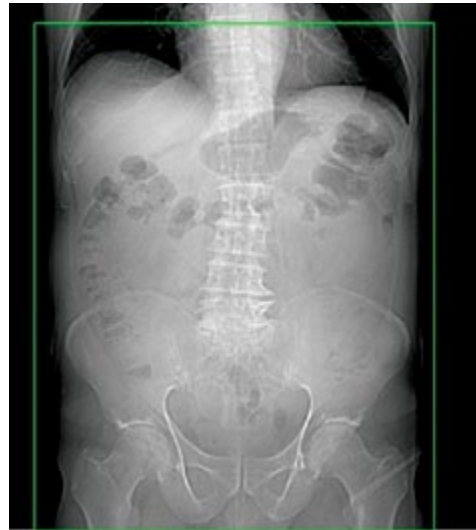Examination process:

First we make a topogram (scout view) in the lateral and AP directions. The topogram must include the whole abdomen. Then we have to set the region of interest. The field-of-view (FOV) covers the area from the basal lung segments to the symphysis without tilting. After setting the FOV, the non-enhanced series has to be made. Before the contrast enhanced series, we acquire one slice at the height of the diaphragm. This is done to measure the density of the administered contrast agent (100 HU) and to acquire precise contrast enhanced images by putting the ROI into the descending aorta. After the administration of contrast material, injecting 20-30 ml of saline can extend the contrast effect. The post contrast series is acquired 30-40 seconds, while the delayed phase images are acquired 5-6 minutes after contrast administration. In case of hemangiomas, the delayed phase images are taken 15 minutes after contrast administration. Sagittal and coronal MPR reconstructions also have to be made. Images are taken with a soft kernel and a narrow window (C/W:70/400). (Figures 54., 55.) (Table 26.)

Table 26. Parameters

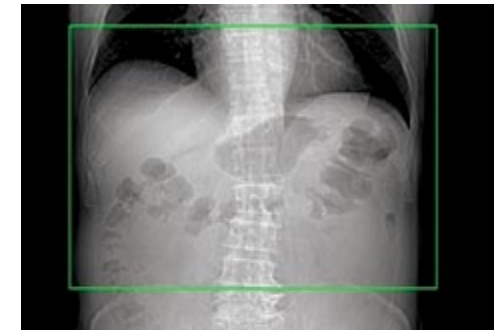Scan type	helical
Slice thickness	5 mm
Interval	5 mm
kV	130
mAs	260
Pitch	1.375
CM volume	90-100 ml (350 cc.)
CM speed	2.5 flow (ml/sec)
Delay	c.e. ROI (100 HU); post cm.: 30-40 sec; late 5-6 min, late vascular 10-15 min

In case of a selective liver CT examination, the acquisition parameters are the same as in

**Figure 54. Planning of abdominal CT**

a routine abdominal CT, except for the delay times and the volume of contrast material. These are:

In case of orientation exams, 100 ml of contrast agent has to be administered with a flow of 2.5 ml/sec and a delay time of 65-70 sec. When imaging the portal venous phase, 150 ml of contrast agent has to be administered with a flow of 4 ml/sec and a delay time of 70-80 sec. For the biphasic series, the contrast enhanced phase is acquired 25 seconds after contrast administration. The late vascular phase can be acquired with a 3-5 minute delay, and the late parenchymal phase with a delay of up to 10-15 minutes (hemangioma). (Table 27.)

**Figure 55. Planning of selective liver CT****Table 27. Parameters**

Scan type	helical
Slice thickness	5 mm
Interval	5 mm
kV	130
mAs	260
Pitch	1.375
CM volume	100-150 ml (350 cc.)
CM speed	2.5-3 flow (ml/sec)
Delay	c.e.: ROI (100 HU); portal 70-80 sec; biphasic 25 sec; late vascular 3-5-15 min

II.11. CT imaging of the pancreas, spleen and gastrointestinal tract

Pancreas CT

Often it is the primary purpose of CT imaging, but we usually make it as part of an abdominal CT. The primary diagnostic tool of the pancreas is ultrasound but a number of factors – e.g. the patient's body size, meteorism, stomach contents – have an influence on it. Small pancreatic tumors, pancreatitis or biliary stones may also be well demonstrated with endoscopic ultrasonography. ERCP is suitable for pancreatitis. If therapeutic intervention is not planned, MRCP is the best imaging method, because it is a non-invasive technique. The most morphological information may be obtained by CT.

Indications:

In case of tumorous processes: localization of carcinomas and pancreatic endocrine tumors; surgical planning. We can get important information about therapeutic response.

Pancreatitis: differential diagnosis (differentiation of exudative and necrotising forms), gravity, edema, pseudocysts, abscesses, assessment of spread, therapeutic planning and follow-up.

Patients with acute pancreatitis must not be given oral contrast material because the resulting secretion may cause peritonitis, and in extreme cases death. If only the pancreatic/hepatic region is to be examined, then only 500-600 ml of oral contrast material is given 30 minutes before the test. Total abdominal CT requires 1000-1500 ml of contrast which the patient consumes in 1-1,5 hours before the test. In both cases, it is essential that the final 2 dl of contrast agent is drunk immediately before the test, therefore the duodenum will be fully filled up.

The patient should not eat 5 hours before the contrast enhanced test. Make sure that all anti-diabetic medication, which are on the black list, are omitted before the study. The patient should remove all metallic objects (e.g.: jewellery, dresses) from the examined region. Venous preparation is essential. The intravenous line, if it is possible, must be inserted into the right cubital vein. Then the patient can be connected to the injector, or we can manually administer the contrast agent. The exam is carried out in breath-hold.

Patient positioning:

For CT examinations of the abdomen the patient is placed in a head-first supine position, arms lifted above his head. (http://tamop.etk.pte.hu/tamop412A/Kepalkotasi_gyakorlatok_tananyag/CT/CT_Videok/has-HF-SUP-craniocaudal_en.avi)

Centering:

Patient positioning is done using lasers.

Examination process:

First we make a topogram (scout view) in the lateral and AP directions. The topogram must include the whole abdomen. Then we have to set the region of interest. Since the investigation can be targeted specifically only for the pancreas or it can be a part of the total abdominal examination, short or long topograms have to be made. After setting the FOV, the non-enhanced series has to be made. Before the contrast enhanced series, we take one slice at the height of the diaphragm. This is done to measure the density of the administered contrast agent (100 HU) and to acquire precise contrast enhanced images by putting the ROI into the descending aorta. After the administration of contrast material, injecting 20-30 ml of saline can extend the contrast effect.

Contrast material phases:

Contrast enhanced: 15-20 seconds after the administration- the hypervascular neuroendocrine tumors become isodense very quickly, that is why these should be imaged in the early arterial phase. Parenchymal: 30-40 seconds after the administration (peak around 40) – carried out in the case of carcinomas, necrosis and pseudocyst. Portal phase: 60-90 seconds after the administration – carried out in the case of upper mesenteric and portal vein thrombosis, hypovascular hepatic metastases.

Sagittal and coronal MPR, CPR reconstructions also have to be made. For imaging of vessels, MIP and VRT are used. For the detection of the Wirsung duct MinIP reconstruction is necessary. Images are taken with a soft kernel and with a narrow window (C/W:70/400).

In case of targeted CT examination of the pancreas, different imaging modes can be selected for the various disorders. When searching for a pancreatic tumor, the pancreas and the liver (search for metastases, assessment of biliary obstruction) have to be in the examined region. To separate the normal parenchyma from the tumor, thin-slice imaging is required.

- In case of suspected carcinoma, parenchymal phase images are obtained from the pancreas and portal venous phase images from the liver and the pancreas.
- Arterial phase images are obtained in case of benign islet cell tumor only from the pancreas; from both the liver and the pancreas, and portal phase images of the liver and pancreas in case of malignancy.
- In acute pancreatitis the abdomen and pelvis also have to be in the examined region, we acquire images in the parenchymal phase.
- In case of chronic pancreatitis, it is sufficient to visualize only the pancreas region, if calcification is seen, it is enough to acquire just the native series. For more accurate assessment of the status of the pancreatic parenchyma, we can complement the exam with a contrast enhanced phase.

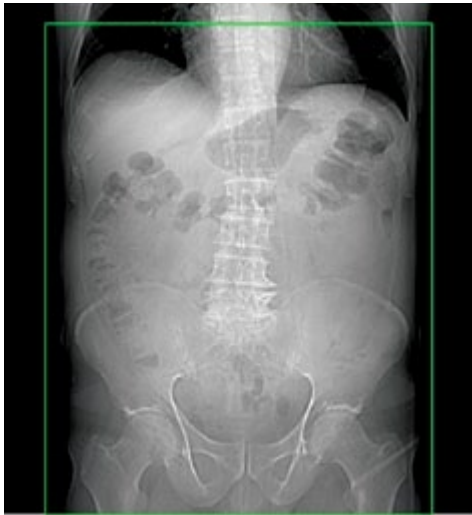

Figure 56. Planning of abdominal CT

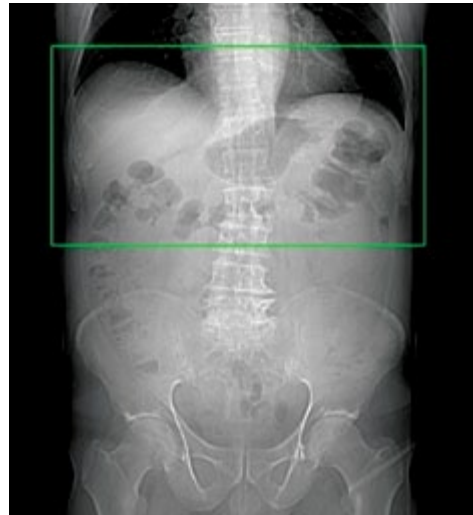

Figure 57. Planning of selective pancreas CT

- In case of suspicious pancreatic trauma, the entire abdomen and pelvis have to be examined, the non-enhanced images are complemented by the late parenchymal phase series. (http://tamop.etk.pte.hu/tamop412A/Kepalkotasi_gyakorlatok_tananyag/CT/CT_DICOM_Kepek/18_nyak_mellkas_has.zip) (Figures 56., 57.) (Table 28.)

Table 28. Parameters

Scan type	helical
Slice thickness	5 mm
Interval	5 mm
kV	130
mAs	260
Pitch	1.375
CM volume	90-100 ml (350 cc.)
CM speed	2.5 flow (ml/sec)
Delay	ROI (100 HU)

Spleen CT

The primary imaging modality of the spleen is ultrasound. A CT scan is relevant when the assessment of the spleen is difficult with ultrasound. CT imaging of the spleen is often the part of abdominal CT. MR may also be used for imaging the spleen, however in case of lymphoma a CT has to be made.

Indications:

Trauma with bleeding or abscess – if ultrasound is equivocal. Malignant lymphoma of the spleen and splenomegaly are not indications for CT evaluation of the spleen.

Patient preparation:

The patient should not eat 5 hours before the contrast enhanced test. Make sure that all anti-diabetic medication, which are on the black list, are omitted before the study. The patient should remove all metallic objects (e.g.: jewellerys, dresses) from the examined region. Venous preparation is essential. The intravenous line, if it is possible, must be inserted into the right cubital vein. Then the patient can be connected to the injector, or we can manually administer the contrast agent. The exam is carried out in breath-hold.

Patient positioning:

For CT examinations of the abdomen the patient is placed in a head-first supine position, arms lifted above his head. (http://tamop.etk.pte.hu/tamop412A/Kepalkotasi_gyakorlatok_tananyag/CT/CT_Videok/has-HF-SUP-craniocaudal_en.avi)

Centering:

Patient positioning is done using lasers.

Examination process:

First we make a topogram (scout view) in the lateral and AP directions. The topogram must include the whole abdomen. Then we have to set the region of interest. Since the investigation can be made specifically only for the spleen or as a part of the total abdominal examination, short or long topograms have to be made. After setting the FOV, the non-enhanced series has to be made. Before the contrast enhanced series, we take one slice at the height of the diaphragm. This is done to measure the density of the administered contrast agent (100 HU) and to acquire precise contrast enhanced images by putting the ROI into the descending aorta. After the administration of contrast material, injecting 20-30 ml of saline can extend the contrast effect.

After the administration of 120 ml of contrast medium with a flow of 2 ml/sec, images are acquired with a 40-70 seconds delay. The arterial phase is not suitable for the assessment of the

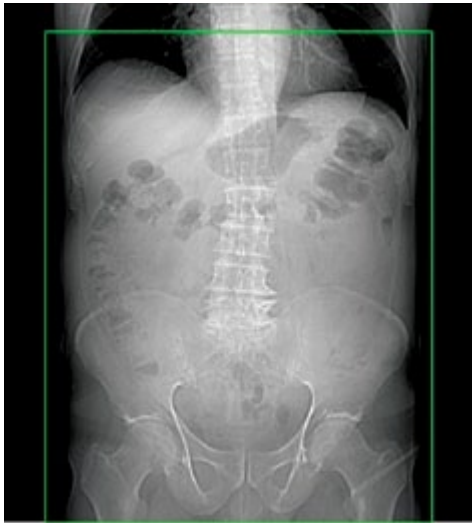

Figure 58. Planning of abdominal CT

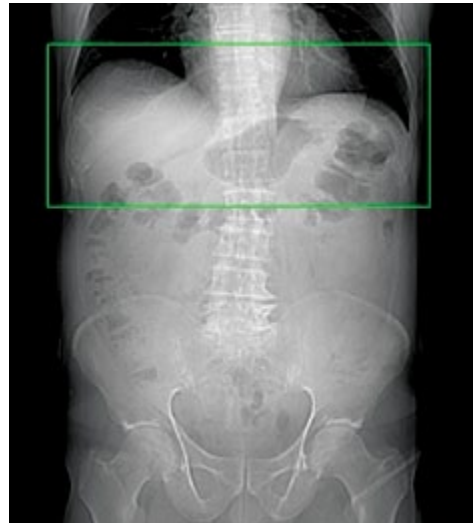


Figure 59. Planning of selective spleen CT

spleen, because it appears heterogeneous in the early arterial phase, and the early parenchymal phase may even mimic lesions (red and white pulp), so in case of trauma we definitely acquire the late parenchymal series (60–90 sec). Sagittal and coronal MPR reconstructions also have to be made. Images are taken with a soft kernel and with a narrow window (C/W:70/400). (http://tamop.etc.pte.hu/tamop412A/Kepalkotasi_gyakorlatok_tananyag/CT/CT_DICOM_Kepek/18_nyak_mellkas_has.zip) (Figures 58., 59.) (Table 29.)

Table 29. Parameters

Scan type	helical
Slice thickness	5 mm
Interval	5 mm
kV	130
mAs	260
Pitch	1.375
CM volume	90-100 ml (350 cc.)
CM speed	2.5 flow (ml/sec)
Delay	ROI (100 HU)

CT imaging of the gastrointestinal tract

Endoscopy is the most common initial diagnostic procedure for evaluating diseases of the upper and lower gastrointestinal tract which may also include biopsy. Presently, new techniques in computed tomography such as hydro-CT, CT enteroclysis, and CT colonography, especially when combined with multislice scanning, have increased the sensitivity of CT in detecting and staging gastrointestinal tumors or in evaluating inflammatory diseases, although the relative merits of these techniques have not yet been clearly established. Virtual colonoscopy, in particular, holds great potential as a screening tool for colorectal cancer but has not yet been shown to be cost-effective. CT has gained new indications, such as the evaluation of suspected appendicitis, acute abdomen, suspected bowel ischemia, diverticulitis, and acute bleeding although the role of ultrasound is not negligible either. MRI holds great potential for the evaluation of benign disease such as inflammatory bowel disease, localization of acute gastrointestinal bleeding and for the evaluation of rectal cancer, but has so far failed to be widely accepted for indications concerning the alimentary tract.

Indications:

Esophageal, gastric, and colorectal cancer: therapy planning in advanced tumor stages, M staging (liver). Detection of small bowel tumors and lymphomas. Inflammatory bowel disease, mural involvement, skip lesion, fistulae, conglomerate masses, obstruction. Acute abdomen (appendicitis, ileus, obstruction, search for hemorrhage). Equivocal radiographic, sonographic, or endoscopic findings.

Esophagus CT

CT examination of the esophagus is part of a chest CT. The scan length may have to be extended in the cranial or caudal direction, depending on the site of a suspected esophageal tumor. The use of oral contrast medium is controversial. Positive oral contrast material may improve delineation of the esophageal lumen. Barium have a high viscosity and therefore may improve the coating of the esophageal mucosa but they are contraindicated if there is a risk of aspiration. Administration of intravenous contrast agent is necessary.

Patient preparation:

The patient should not eat 5 hours before the contrast enhanced test. Make sure that all anti-diabetic medication, which are on the black list, are omitted before the study. The patient should remove all metallic objects (e.g.: jewellery, dresses) from the examined region. Venous preparation is essential. The intravenous line, if it is possible, must be inserted into the right cubital vein. Then the patient can be connected to the injector, or we can manually administer the contrast

agent. The exam is carried out in breath-hold. The patient may have to drink a compact gastrografin solution immediately before the non-enhanced series.

Patient positioning:

For CT examinations of the oesophagus the patient is placed in a head-first supine position, arms lifted above his head. (http://tamop.etc.pte.hu/tamop412A/Kepalkotasi_gyakorlatok_tananyag/CT/CT_Videok/mellkas-has-HF-SUP-craniocaudal_en.avi)

Centering:

Patient positioning is done using lasers.

Examination process:

First we make a topogram image (scout view) in the AP and lateral directions. The topogram must include the whole oesophagus and chest. Then we have to set the region of interest according to the lesion. After setting the FOV, the non-contrast series has to be made. Before the contrast enhanced series, we take one slice at the height of the pulmonary trunk. This is done to measure the density of the administered contrast agent (100 HU) and to acquire precise contrast enhanced images by putting the ROI into the pulmonary trunk. The post contrast series also has to be made. Sagittal and coronal MPR and virtual bronchoscopy reconstructions also have to be made. For visualization of soft tissue use a soft kernel (B41) with a narrow window (C/W:40/400), for visualisation of the lung use a sharp kernel (B60-B70-B80) with a wide window (C/W: 650/1500). (Figure 60.) (Table 30.)

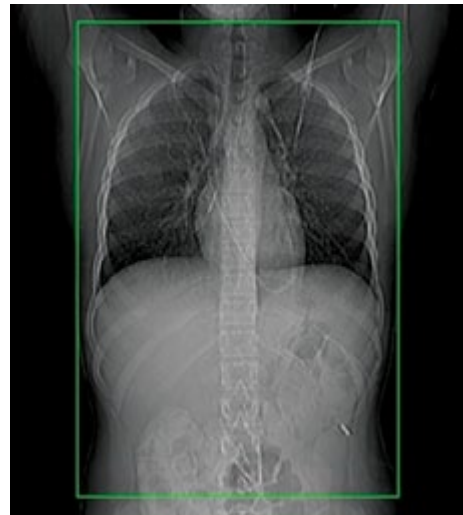

Figure 60. Planning of chest-oesophagus CT

Table 30. Parameters

Scan Type	helical
Slice thickness	5 mm
Interval	5mm
kV	130
mAs	260
Pitch	1.375
CM volume	70-90 ml (350 cc.)
CM speed	2.5 flow (ml/sec)
Delay	ROI (100 HU)

CT imaging of the stomach, small intestines and colon are all part of the abdominal CT. However, there are some differences in patient preparation as discussed below.

Stomach CT

Patient preparation:

An empty and distended stomach is an essential prerequisite for a good examination. Thus, the patient should not eat for 12 hours nor drink for 6 hours prior to the CT examination.

Hydro-CT is based on optimum distention of the stomach with negative oral contrast medium (water, juice, or a methylcellulose preparation) in conjunction with intravenous contrast material. The patient drinks 500-1000 ml of contrast medium shortly before the examination. While on the CT table, the patient should be asked to drink another 250 ml of contrast medium. According to the location of the lesion, the examination can be made in prone or in the lateral position. An antispasmodic agent may be administered for optimum distention of the stomach and relaxation of the gastric muscles.

For virtual gastroscopy, gas is required as a negative contrast agent. The patient has to be examined early in the morning to reduce the amount of gastric secretions in the stomach. The stomach is distended by giving the patient a CO₂-producing powder and a little water. Then the patient has to wait for 2-3 minutes to make sure the powder is completely dissolved.

Small intestines CT

Patient preparation:

Standard examinations require that a sufficient volume of oral contrast medium (1500-2000 ml) is given to the patient over a period of at least 60 to 90 minutes before the examination. It is essential that the final 2 dl of the contrast agent is drunk immediately before the test, therefore the duodenum is completely filled up.

CT enteroclysis is a superior technique for indications that focus on the small bowel. Prior to CT a duodenal tube is placed distal to the duodenojejunal flexure, under fluoroscopic guidance. Then the patient is brought to the CT suite and a total volume of up to 2000 ml contrast medium is instilled rapidly. The contrast material may consist of a highly diluted barium suspension, a methylcellulose preparation, or a stearin-containing preparation. We prefer negative contrast for most indications because it allows for excellent visualization of the bowel wall following intravenous contrast administration. Positive contrast material is better suited to demonstrate stenoses

or fistulous tracts. An antispasmodic agent may be administered for optimum distension of the small intestine.

Colon CT

Patient preparation:

For a standard abdominal examination that includes the colon, the administration of a large volume of positive or negative oral contrast material (1500-2000 ml) should be given to the patient over a period of at least 60 to 90 minutes prior to the examination.

CT colonography is a focused examination of the colon, which requires the same patient preparation (bowel cleansing). Colon distension is achieved by rectally insufflated air or CO₂ as a negative contrast material. Colonic distension is better with CO₂, and there is less colonic spasm and discomfort for the patient. According to the lesion the patient position may change. An anti-spasmodic agent may be administered for optimum distension of the colon.

Patient positioning:

For CT examinations of the abdomen the patient is placed in a head-first supine position, arms lifted above his head. (http://tamop.etk.pte.hu/tamop412A/Kepalkotasi_gyakorlatok_tananyag/CT/CT_Videok/has-HF-SUP-craniocaudal_en.avi)

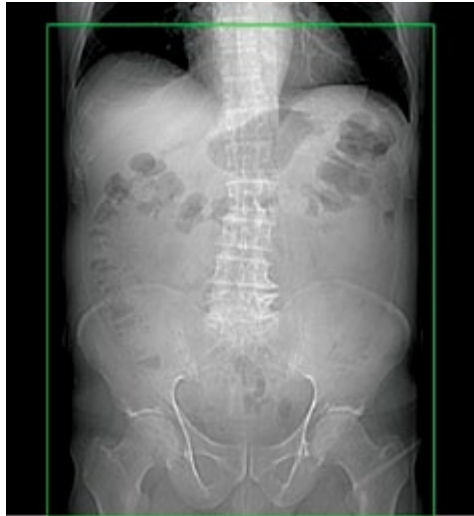

Figure 61. Planning of abdominal CT

Centering:

Patient positioning is done using lasers.

Examination process:

First we make a topogram (scout view) in the AP and lateral directions. The topogram must include the whole abdomen. Then we have to set the region of interest. The FOV covers the area from the basal lung segments to the symphysis. After setting the FOV, the non-contrast series has to be made. Before the contrast enhanced series, we take one slice at the height of the diaphragm. This is done measure the density of the administered contrast agent (100 HU) and to acquire precise contrast enhanced images by putting the ROI into the descend aorta. After the

administration of contrast material, injecting 20-30 ml of saline can extend the contrast effect. The post contrast series is acquired 30-40 sec after the administration of contrast material. Sagittal and coronal MPR and 3D reconstructions also have to be made. Images are taken with a soft kernel and with a narrow window (C/W:70/400). (http://tamop.etk.pte.hu/tamop412A/Kepalkotasi_gyakorlatok_tananyag/CT/CT_DICOM_Kepek/18_nyak_mellkas_has.zip) (Figure 61.) (Table 31.)

Table 31. Parameters

Scan type	helical
Slice thickness	5 mm
Interval	5 mm
kV	130
mAs	260
Pitch	1.375
CM volume	90-100 ml (350 cc.)
CM speed	2.5 flow (ml/sec)
Delay	ROI (100 HU)

II.12. CT imaging of the abdomen, retroperitoneum and adrenal glands

CT has become the diagnostic method of choice for the evaluation of the peritoneal cavity and the retroperitoneum, except for pediatric patients and the young, slim patients, in whom ultrasonography is preferable. CT is superior for patients who are hard to examine by ultrasound due to obesity or superimposition of bowel gas. The reproducibility of sectional planes makes CT particularly useful for follow-up examinations. CT is also used to guide diagnostic needle aspirations and biopsies and to direct interventional procedures such as percutaneous drainage of abscesses.

Indications:

Tumor diagnosis: Primary evaluation of peritoneal or retroperitoneal masses, staging of other tumors and oncologic follow-up. Suspected abscess. Detection, localization, active bleeding. Lesions indeterminate by ultrasound and trauma.

Diagnostic imaging of adrenal glands is performed by ultrasonography, CT and MR. The primary diagnostic method is ultrasonography but diagnostic evaluation usually starts with the clinical examination and laboratory tests since their findings will determine the need for imaging procedures and direct their selection. The only primary indication for a selective CT examination of the adrenal glands is an abnormality of adrenal function. Because of its superiority for estimating the fat content of the lesion (with in-phase and opposed phase gradient echo images), MRI offers great potential, especially for the differentiation of benign and malignant enlargement of the adrenals. CT is the primary method for excluding metastatic disease in the adrenals. This is why we always visualize the adrenal glands during chest CT, because primary lung cancer primarily metastasizes into the adrenals.

Indications:

Hormonal disorders, benign and malignant tumors, and staging, but mostly CT is used for imaging metastases.

Abdominal CT

http://tamop.etk.pte.hu/tamop412A/Kepalkotasi_gyakorlatok_tananyag/CT/CT_DICOM_Kepek/18_nyak_mellkas_has.zip

CT imaging of the retroperitoneum and the adrenal glands are usually part of the abdominal CT. Only the administration of the oral contrast agent differs.

Patient preparation:

The patient does not eat 5 hours before the contrast enhanced test. Make sure that all anti-diabetic medication, which are on the black list, are omitted before the study. The patient should remove all metallic objects (e.g.: jewellery, dresses) from the examined region. Venous preparation is essential. Total abdominal CT requires 1000-1500 ml of oral contrast agent that the patient starts drinking 1-1.5 hours before the scan (adrenal glands – usually water; retroperitoneum – gastrografin). The intravenous line, if it is possible, must be inserted into the right cubital vein, and then the patient can be connected to the injector, or we can manually administer the contrast agent. The exam is carried out in breath-hold.

Patient positioning:

For CT examinations of the pancreas, the patient is placed in a head-first (or feet-first) supine position, arms lifted above his head. (http://tamop.etk.pte.hu/tamop412A/Kepalkotasi_gyakorlatok_tananyag/CT/CT_Videok/has-HF-SUP-craniocaudal_en.avi)

Centering:

Patient positioning is done using lasers.

Examination process:

First we make a topogram (scout view) image in the AP and lateral directions. The topogram must include the whole abdomen. Then we have to set the region of interest. The FOV covers the area from the basal lung segments to the symphysis. After setting the FOV, the non-contrast series has to be made. Before the contrast enhanced series, we take one slice at the height

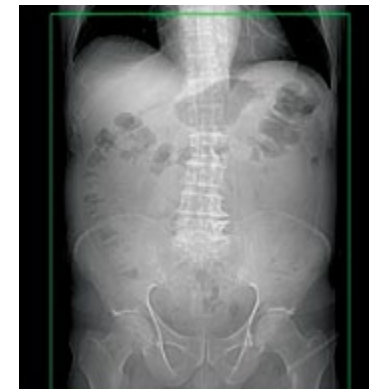

Figure 62. Planning of abdominal CT

of the diaphragm. This is done to measure the density of the administered contrast agent (100 HU) and to acquire precise contrast enhanced images by putting the ROI into the descend aorta. After the administration of contrast material, injecting 20-30 ml of saline can extend the contrast effect. The post contrast series is acquired 30-40 sec after contrast administration. Sagittal and coronal MPR and 3D reconstructions also have to be made. Images are taken with a soft kernel with a narrow window (C/W:70/400). (http://tamop.etk.pte.hu/tamop412A/Kepalkotasi_gyakorlatok_tananyag/CT/CT_DICOM_Kepek/18_nyak_mellkas_has.zip) (Figure 62.) (Table 32.)

Table 32. Parameters

Scan type	helical
Slice thickness	5 mm
Interval	5 mm
kV	130
mAs	260
Pitch	1.375
CM volume	90-100 ml (350 cc.)
CM speed	2.5 flow (ml/sec)
Delay	ROI (100 HU)

II.13. CT imaging of the urinary tract

The primary imaging modality of the urinary tract is usually ultrasound; CT has an increasing role, while conventional radiography is being neglected. Ultrasound is cheap, easily accessible, and poses no radiation exposure for the patient. The kidneys and the urinary bladder are well visualized with ultrasound. From a morphological point of view, only the imaging of the ureters is troublesome. Nowadays, the urological ultrasound examination is carried out in the urology ambulance and not in the radiology department. Among conventional x-ray techniques, the number of plain urinary x-rays has not decreased, however i.v. urography was changed by CT urography. Nowadays conventional tomographic studies are not prepared. As opposed to conventional ultrasonography, CT urography is not limited by meteorism, and the visualisation of the excretory phase is much better with CTU. Morphological lesions that cause compression of the ureters are better visualized. Due to better contrast resolution of CT, there is less need for external compression of the ureters. The parenchyma of the kidney, parenchymal lesions and space occupying lesions are well visualized with CT. Only the non-enhanced series is good enough to visualize stones in the ureters and pyelons, and stagnation or obstruction due to stones. In case of hydronephrosis CT is an excellent differential diagnostic tool (ureter calculi, tumour, external compression). The only disadvantage of CT is the associated radiation exposure. In young patients, or if CT is contraindicated, MR urography (with or without contrast agent) may be used.

Indications:

Tumor and staging: kidney carcinoma, transitional cell carcinoma, nephroblastoma, lymphoma.

Trauma: hemorrhage, contusion, vascular lesions, rupture, occlusion.

Inflammation, abscess, pyelonephritis, cysts, and polycystic conditions, malformations, hydronephrosis, small kidney in chronic renal failure, etc.

The non-enhanced series may help to identify microbleedings and lesions with high fat content (e.g.: the differential diagnostics of angiomyolipomas). In case of hypervascular tumours and cysts, CT can help distinguish them from each other.

Patient preparation:

The patient should not eat 5 hours before the contrast enhanced test. Make sure that all anti-diabetic medication, which are on the black list, are omitted before the study. The patient should remove all metallic objects (e.g.: jewellery, dresses) from the examined region. CT of the urinary tract requires 1000-1500 ml of oral contrast agent (water) that the patient starts drinking 0.5-1 hours before the test according to the examined region. Gastrografin in the bowels is undesired when we make MIP reconstructions. Venous preparation is essential. The intravenous line, if it is

possible, must be inserted into the right cubital vein. Then the patient can be connected to the injector, or we can manually administer the contrast agent. The exam is carried out in breath-hold.

Patient positioning:

For CTA examinations of the abdomen the patient is placed in a head-first supine position, arms lifted above his head. (http://tamop.etk.pte.hu/tamop412A/Kepalkotasi_gyakorlatok_tananyag/CT/CT_Videok/has-HF-SUP-craniocaudal_hu.avi)

Centering:

Patient positioning is done using lasers.

Examination process:

First we make a topogram (scout view) in the lateral and AP directions. The topogram must include the whole abdomen. Then we have to set the region of interest. The field-of-view (FOV) covers the area from the basal lung segments to the symphysis without tilting. After setting the FOV, the non-enhanced series has to be made. Before the contrast enhanced series, we take one slice at the height of the diaphragm. This is done to measure the density of the administered contrast agent (100 HU) and to acquire precise contrast enhanced images by putting the ROI into the descending aorta. After the administration of contrast material, injecting 20-30 ml of saline can extend the contrast effect. Based on the indication, we acquire different contrast enhanced series:

Contrast-enhanced series: 20-25 seconds after the start of contrast administration.

Nephrogram – early parenchyma series: 100-180 seconds delay. Cortex and medulla have the

same density in this phase while lesions are hypodens. That is why this phase is the best for tumour detection.

Excretory phase – 5-7 minutes delay. Visualisation of the urinary tract.

Late excretory phase – 15 minutes. In this phase we can detect the contrast retention of the renal tubules.

In case of obstructive uropathy, when excretion is delayed we may have to make another series after 30-60 minutes. If we make a coronal MPR reconstruction with a slice thickness of 3-4 mm, we can depict small focal lesions. The MIP reconstruction with slice thickness of 0,5-3 mm is good for investigating for renal- and urether calculi. With SSD and VR reconstructions we can visualize the

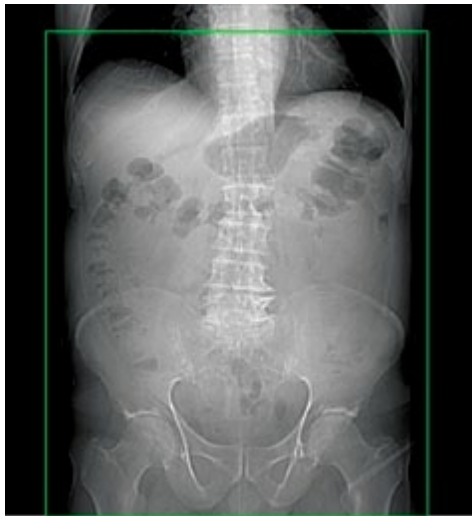

Figure 63. Planning of CTU

whole urinary tract, these reconstructions help to plan surgeries and help to assess vascular anatomy.

Timed triple-bolus CT urography can provide excellent quality images of the kidneys and the urinary tract, with low radiation exposure. By administering three limited volumes of contrast material with good timing we can visualize all three phase (parenchymal, excretory, vascular) at the same time in one acquisition. The effective dose of this protocol is half of that of conventional protocols, without any loss of image quality. (Figure 63.) (Table 33.)

Table 33. Parameters

Scan type	helical
Slice thickness	n.e.:1,25 mm; others: 5 mm
Interval	n.e.: 0,8 mm; others: 5 mm
kV	130
mAs	n.e. and late: 100 mAs (low dose)
Pitch	1,375
CM volume	90-100 ml (350 cc.)
CM speed	2,5 flow (ml/sec)
Delay	ROI (100 HU)

II.14. CT imaging of the male and female pelvis

CT is not among the first-line modalities that are used in the diagnosis of female pelvic diseases. Unlike ultrasound and MRI, CT cannot define the structures of the uterine wall, particularly the endometrium and its changes during the menstrual cycle. On the other hand, the pelvis is often included as part of an abdominal CT study, and therefore knowledge of the normal and pathologic appearances of the pelvic structures is essential. Similar to MRI, the multiplanar imaging capabilities of CT (sagittal and coronal views) are most helpful for delineation of the interfaces between the pelvic organs and should be used for assessment of pathologic structures. The first imaging modality that is used after the physical examination of the pelvis is ultrasound, preferably using a transvaginal probe. In diseases of the female pelvic organs, such as the staging of uterine tumors, MRI is increasingly being used as the first-line modality, although multislice CT techniques may yield similarly good results in patients with more advanced diseases. CT scanning of the female pelvis is usually performed for reasons other than primary gynecologic indications.

Diseases of the spermatic cord, testis, epididymis, and penis are primarily evaluated with ultrasound. CT scanning of the male pelvis is indicated only for lymph node staging or if there is suspicion of spread of a tumor of the prostate or seminal vesicles into adjacent tissues. The key modalities for diagnosing the early stages of prostatic carcinoma are laboratory tests, transrectal ultrasound, fine needle aspiration biopsy, and MRI, preferably using an endorectal or a combined endorectal and phased array pelvic coil. The role of CT is limited because it is not able to differentiate between normal, hyperplastic, and cancerous glandular tissue. CT is important for nodal staging, the evaluation of extracapsular tumor extension, and for the follow-up of prostatic and testicular tumors. Characteristic findings in the male pelvic organs, especially the prostate, are frequently noted as incidental findings in pelvic CT examinations.

Indications:

In women:

Tumor diagnosis – for cervical and endometrial cancer MR is the primary method –, radiation therapy and treatment, oncology follow-up. For abscesses and intervention procedures. In cases when ultrasound is equivocal.

In men:

Just as in women: cancer diagnosis and radiation therapy, oncology follow-up.

Abdominal-pelvis CT

http://tamop.etk.pte.hu/tamop412A/Kepalkotasi_gyakorlatok_tananyag/CT/CT_DICOM_Keppek/18_nyak_mellkas_has.zip

Imaging of the pelvis is usually part of abdominal CT, so preparations should be done according to that.

Patient preparation:

The patient should not eat 5 hours before the contrast enhanced test. Make sure that all anti-diabetic medication, which are on the black list, are omitted before the study. The patient should remove all metallic objects (e.g.: jewellery, dresses) from the examined region. CT of the abdomen-pelvis requires 1000-1500 ml of oral contrast agent (water or gastrografin) that the patient starts drinking 1-1,5 hours before the test according to the examined region. Venous preparation is essential. The intravenous line, if it is possible, must be inserted into the right cubital vein. Then the patient can be connected to the injector, or we can manually administer the contrast agent. The exam is carried out in breath-hold.

Patient positioning:

For CTA examinations of the abdomen the patient is placed in a head-first (http://tamop.etk.pte.hu/tamop412A/Kepalkotasi_gyakorlatok_tananyag/CT/CT_Videok/medence-csipo-HF-SUP-craniocaudal_en.avi) or feet-first (http://tamop.etk.pte.hu/tamop412A/Kepalkotasi_gyakorlatok_tananyag/CT/CT_Videok/medence_FF-SUP-craniocaudal_en.avi) supine position, arms lifted above his head.

Centering:

Patient positioning is done using lasers.

Examination process:

First we make a topogram (scout view) in the lateral and AP directions. The topogram must include the whole abdomen. Then we have to set the region of interest. The field-of-view (FOV) covers the area from the basal lung segments to the symphysis (abdomen-pelvis) or from the iliac crest to the symphysis (only pelvis) without tilting. After setting the FOV, the non-enhanced series has to be made. Before the contrast enhanced series, we take one slice at the height of the diaphragm. This is done to measure the density of the administered contrast agent (100 HU) and to acquire precise contrast enhanced images by putting the ROI into the descending aorta. After the administration of contrast material, injecting 20-30 ml of saline can extend the contrast effect. The post-contrast series is made with a 20 second delay. Coronal and sagittal MPR reconstructions also have to be

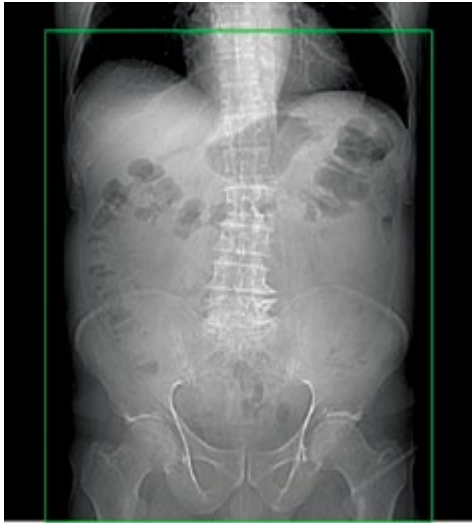

Figure 64. Planning of abdominal-pelvis CT

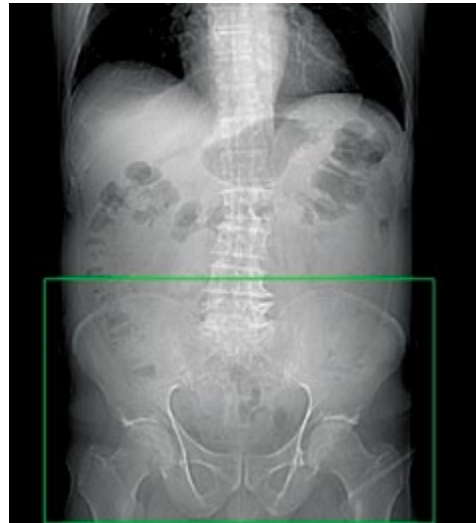

Figure 65. Planning of pelvis CT

made. Images are taken with a soft kernel and a narrow window ($W/C=400/70$). (Figures 64., 65.) (Table 34.)

(http://tamop.etk.pte.hu/tamop412A/Kepalkotasi_gyakorlatok_tananyag/CT/CT_DICOM_Keppek/18_nyak_mellkas_has.zip) (Figurea 64., 65.) (Table 34.)

Table 34. Parameters

Scan type	helical
Slice thickness	5 mm
Interval	5 mm
kV	130
mAs	260
Pitch	1.375
CM volume	90-100 ml (350 cc.)
CM speed	2.5 flow (ml/sec)
Delay	sROI (100 HU)

II.15. CT imaging of the heart

Accurate diagnosis of heart disease is very important, because today it is one of the major leading causes of death. Several imaging modalities are available for its detection, which are the following:

- 2-direction x-rays
- Echocardiography
- CT
- MRI
- Nuclear Medicine
- Conventional angiography

X-ray is used for the assessment of the shape and size of the heart, and for the evaluation of pulmonary circulation. Echocardiography is the non-invasive workhorse for many cardiac diseases, including septal defects, valvular disease, and motion abnormalities of the myocardial wall. With US, we can measure the size of the chambers, the ejection fraction and the pressure gradient. CT imaging allows for the visualisation of the coronary arteries, the assessment of the size of the heart and wall thickness, and determination of coronary artery sclerosis. CT is used in cases when MR is not applicable (e.g.: pacemaker). MRI is a useful technique to determine the size, motion and thickness of the wall of the heart, and to measure perfusion. Cardio-angiography is frequently combined with interventional procedures (angiocardiography, coronary angiography, thrombolysis, angioplasty, stent implantation). Functional imaging of the myocardial perfusion is based on thallium scintigraphy (SPECT) or PET.

Indications:

- small or medium probability of coronary disease and chest discomfort:
 - If the stress test is not evaluable or non-diagnostic
 - If the non-invasive test results are contradictory
 - If the ischaemic provocation test can not be performed
- In case of acute chest pain and a moderate cardiovascular risk, when cardiac enzymes are negative
- Clarification of etiology of a recent heart failure
- If there is a suspected coronary abnormality
- In case of a complex congenital vitium, for the accurate mapping of valve abnormalities, coronaries and cavities
- Before electrophysiological procedures (biventricular pacemaker, atrial fibrillation ablation)

therapy) for the mapping of anatomy

- For repeated heart surgery planning
- When good quality ultrasound or MRI exams can not be acquired due to heart chamber or pericardial pathology.
- When invasive coronary angiography can not be performed or it is unsuccessful
- To confirm or rule out congenital heart defects (diseases of the coronaries, the heart, the great vessels of the cardiac chambers)
- Assessment of cardiac tumors (lesions)
- Examination of pathological conditions of the pericardium
- Assessment of the cardiac venous system and pulmonary venous valve before electrophysiological ablation
- Before heart surgery (previous arterial and venous bypasses)
- For visualisation of the morphology of the heart and coronary status

Diagnostic application of heart CT:

- in chest pain syndrome when interpretability of ECG and/or the stress test results are not clear
- in chest pain syndrome if the stress ECG, cardiac scintigraphy and/or stress echo are not clear

Visualization of the coronary arteries ("coronary angiography") is a central diagnostic tool in cardiology. The coronary arteries are small and move very rapidly, so that non-invasive imaging is difficult and catheter-based, invasive coronary angiography constitutes the clinical gold standard. In recent years, computed tomography technology has progressed to a stage that allows relatively reliable visualization of the coronary artery lumen after intravenous injection of a contrast agent ("coronary CTA"). Based on the axial cross-sections that are acquired, 2- and 3-dimensional reconstructions of the coronary arteries can be rendered and allow analysis concerning the presence of atherosclerotic lesions and coronary artery stenoses. However, temporal resolution is still a limiting factor for CT visualization of the coronary arteries. It has been convincingly demonstrated that regular and low heart rates are a prerequisite for reliable imaging of the coronary arteries by 16- to 64-slice MDCT, thus, the administration of short-acting beta-blockers prior to an MDCT scan is strongly recommended. The aim is to lower heart rates to less than 65 bpm (optimally less than 60 bpm). With the new dual source CT scanners, which provide a heart-rate independent temporal resolution of 82 ms, it is not necessary to lower the heart rate, because diagnostic image quality can be obtained even at higher heart rates in the majority of cases. Use of sublingual nitroglycerine is also recommended for all scanners immediately before data acquisition in order to achieve coronary vasodilation, which substantially improves image quality. Numerous studies have compared the accuracy of coronary artery stenosis detection by MDCT to invasive coronary angiography. It turns out that the accuracy and specificity of CT are almost the same as that of conventional angiography.

Contrast application must be optimized in order to achieve adequate enhancement of the coronary lumen throughout the scan to avoid excessive contrast in other structures (such as the right heart cavities) and to limit the amount of contrast agent given to patients. Measures to keep the radiation dose within reasonable limits should be applied. ECG pulsing should always be activated. The best images are usually obtained in diastole for heart rates up to 65 bpm, and often in systole for higher rates.

Patient preparation:

The patient should not eat 5 hours before the contrast enhanced test. Make sure that all diabetes medication (which are on the black list) are omitted before the study. The patient should remove all metallic objects (e.g.: jewellery, hairpins, denture) from the examined region. Venous preparation is essential. The intravenous line, if it is possible, must be inserted into the right cubital vein then the patient have to be connected to the injector, or we could manually administered the contrast agent. The exam is carried out in breath-hold. If it is not contraindicated, give the patient nitroglycerin. Apply the ECG electrodes on the patient's chest.

Patient positioning:

For CT examinations of the chest, the patient is placed in a head-first supine position, arms lifted above his head. ([http://tamop.etk.pte.hu/tamop412A/Kepalkotasi_gyakorlatok_tananyag/CT/CT_Videok/mellkas-has HF-SUP-craniocaudal_en.avi](http://tamop.etk.pte.hu/tamop412A/Kepalkotasi_gyakorlatok_tananyag/CT/CT_Videok/mellkas-has-HF-SUP-craniocaudal_en.avi))

Centering:

Patient positioning is done using lasers.

Examination process:

Place the ECG electrodes on the chest, according to regulations (make sure that the electrodes will not interfere with sampling). When setting the ECG it is important to set the R value high, and to achieve a background noise free curve. If necessary, a beta blocker is given to the patient (50-100 mg Metoprolol per os 1 hour before the test).

First we make a topogram image (scout view) in the AP and lateral directions. The topogram must include the whole chest. Then we have to set the region of interest. The field-of-view (FOV) covers the area between the trachea bifurcation to the lower pole of heart without tilting. The ECG electrodes should not be within the examined region. After setting the FOV, an ECG triggered noncontrast series has to be made with thin slices. From these images, we can make the reconstruction for calcium scoring (postprocessing). Even without CTA this method is good for the evaluation of the extent of sclerosis in the coronary arteries. Thanks to calcium scoring even very small calcifications can be detect (Agatston score). Before the contrast enhanced series we take one slice at the height of the ascending aorta. This is done to measure the density of the adminis-

tered contrast agent (at least 100 HU) and to obtain precise contrast enhanced images by putting the ROI into the ascending aorta. Sagittal and coronal MPR, 3D, MIP, CPR and SSD reconstruction also have to be made. There are special postprocessing options, as well, such as left chamber analysis (EF, SV, EDV, EST, motion analysis), and myocardium analysis (e.g.: Polar map). (Table 35.)

Table 35. Parameters

Scan mód	dual source, ECG triggered
Slice thickness	0.75 mm
Interval	0.4 mm
kV	120
mAs	360
Pitch	depending on heart frequency 0.2-0.5
CM volume	min. 60 ml (350 cc.)
CM speed	5 flow (ml/sec)
Delay	ROI

The amount of coronary calcification is usually given by the Agatston score which depends on the area of calcified plaques and their density. Patients are classified into 4 groups (minimal, moderate, and increased and significant) based on calcification – under 10, 11–99, 100–400, and values above 400. Infarct-related morbidity and mortality can be match for each group – depending on age.

Coronary-stent

MR imaging after coronary stent placement provides limited visualisation due to increased susceptibility artifacts. You can use an image protocol and image quality, similar to the protocol used for standard coronary CT angiography. You can also use an injection protocol similar to the protocol used for standard coronary CT angiography. Reconstruction with a sharp kernel (B46) may help to better visualize stent lumen.

Cardiac Morphology

Compared to coronary CTA, a lower but more constant enhancement level through the heart is required for the evaluation of cardiac morphology. Monophasic contrast material injection is not ideally suitable for evaluating cardiac morphology because it leads to a gradual increase in int-

ravascular contrast over time, until a maximum is reached and enhancement rapidly decreases thereafter. This effect will occur at different points in time for the right and left side of the heart and will therefore make homogeneous enhancement of the heart chambers difficult, if not impossible. In addition, there is a rapid contrast uptake in the myocardium, which will decrease contrast between lumen and wall as the scan progresses. Biphasic injection protocols are more suitable for overcoming this problem. To reduce the high-contrast streak artifacts in the right atrium, contrast material concentration may be reduced while maintaining the flow rate during the second phase of contrast injection. This is cumbersome with single barrel injectors but is easily possible with double-barrel injectors by simultaneously injecting contrast material and saline at suitable flow rates. To maintain enhancement in the right side of the heart the injection time has to be prolonged by the right heart transit time of some 5-15 s, depending on cardiac output. Because cardiac output is hard to estimate, we suggest determining the required injection time by increasing it over the scan duration by 10-15 s. The first phase of the biphasic injection should last some 10-15 s. A flow rate of 3-4 ml/s is generally sufficient. The duration of the second phase is calculated from the injection time, and a flow rate of 2-2.5 ml/s is used. A saline chaser bolus of some 30 ml is advisable but not mandatory because of the relatively low flow rates.

II.16. Image quality, quality assurance

Nowadays, quality assurance has been essential due to legal regulations in some areas. Within healthcare, as a service, the one sector that is most dependent on technology is radiology. Therefore within radiology, the physical and technical aspects of quality assurance has paramount importance. The quality of equipment is closely linked to security. It is important that the X-ray equipment are operated in perfect condition as long as possible, and they meet the purposes for which they are intended, such that they provide the best possible quality of CT images and also minimize the radiation dose, and they are operated safely in all other respects. In short, you can say that a good machine - although not sufficient – is a necessary prerequisite for good radiological diagnostics.

Many decades of international experience proves that the “good” machine can only be achieved through continuous technical quality assurance. These goals can only be achieved if the technical parameters of the CT equipment are periodically checked by professionals and they are monitored for performance consistency. It is also preferable if so called quality control tests are done, which are carried out by staff independent of the manufacturer. The money and time spent on this is refunded by the higher standard of diagnosis, safety, and savings of materials, energy, environment, load, machine time and labor time, but most of all patient dose. Slightly simplifying terms, quality assurance, in roentgen diagnostics, is made up of the evaluation of the status of the equipment, the quality of the resulting images and of the regular monitoring of patient doses, and the system of actions arising from evaluation (“corrective measures”); while quality control (QC) is mainly made up of specific visual, operational and measured controls. Instinctively, “quality assurance” has long existed. This means that if a radiologist or an assistant finds that a CT image is not as good quality as expected, he or she will try to find the reason for it and will also try to fix it.

Quality control tests are divided into three levels:

1. *Acceptance test*: A thorough condition test that has to be performed prior to installation of the equipment. It requires special measuring tools and specialized knowledge (ie.: involvement of physicists or engineers). One purpose of the acceptance test is to verify that the delivered equipment meets the specified technical parameters of the transport contract (and any local regulations); the other purpose of the quality program is to determine the basic values which will subsequently serve as reference. The acceptance test is therefore a single test.
2. *Status test*: Repeating the thorough condition test as often as it is required by local regulations (in most cases, yearly), and “if necessary” (this usually means when there is a major service intervention, such as X-ray tube replacement) out of turn, as well. The main purpose

of the status test is to establish the change of the parameters that were measured during the acceptance test. These parameters need to be measured again and compared with the original values.

3. *Consistency test*: This is performed by the users, daily, weekly, or monthly. It is a simple control test, which is designed to monitor the consistency in performance.

Let us see a short list of duties for CT equipment that need to be carried out during an acceptance test according to standards that were in effect between 2002 and 2010.

I. Visual and functional assays

1. Do you have the protocol of the acceptance or previous status test?(yes – no) Were actions carried out according to it? (yes – no)
2. Is the user's manual available? (yes – no)
3. Are consistency tests carried out and documented? (yes – no)
4. Screening of the X-ray tube (s) and the nominal value of focus of the X-ray source unit (according to manufacturer's specifications or data table)
5. Are the controls functioning properly? (yes – no)

II. Measured parameters at the CT workplace

1. CT dose index (CTDI) measurements, CT ionization chamber and CT dose phantoms
2. Accuracy of the patient table positioning
3. Patient positioning accuracy
4. Slice thickness
5. Noise, CT numbers, homogeneity
6. Spatial resolution

More on image quality and its influencing factors can be found in Chapter 3.

Quiz

Simple choice

1. What is the Hounsfield value of air?

- A -1000
- B 0
- C 1500
- D -450

2. Which one of the following statements is true for a dual-source CT scanner?

- A It has only one x-ray tube
- B It operates only in sequential mode
- C It has two x-ray sources
- D It increases scan time compared to a single source scanner

3. How much radiation does a patient receive in one year?

- A 1 mSv/year
- B 3,6 mSv/year
- C 10 mSv/year
- D 5 mSv/year

4. Which is not a dose reducing technique?

- A Increasing the kV
- B Increasing the slice thickness
- C Increasing the reconstruction increment
- D Minimizing the FOV

5. Which one of the following statements is true for the postprocessing techniques?

- A They have a considerable influence on the patient radiation dose
- B We can reconstruct slices in different planes and with different thickness
- C We can reconstruct only straight planes
- D We can display the reconstructed images only in monochrome

6. Which is not a 3D reconstruction technique?

- A SSD
- B VRT
- C Vessel
- D MPR

7. Which one of the following statements is false?

- A In MPR reconstruction density values in a given region are averaged
- B MIP reconstruction is used for visualizing the highest intensity in a given region
- C In AverIP the arithmetical average of voxels are depicted
- D On MinIP images bowel gas is hypodense

8. What is the unit of the speed of contrast agent administration?

- A ml/min
- B ml/sec
- C ml/kg
- D ml/sec²

9. What is the correct sequence?

- A Gassing
- B Filling the syringe with CM and saline
- C Connecting the injector and the patient's i.v. line
- D Connecting the tube to the injector

10. The radiographer is responsible for

- A Entering the patient's personal data precisely into the CT control panel
- B Fixing the CT scanner when it goes wrong
- C Making sure the patient arrives on time for the examination
- D The impression in the radiologist's report

11. What do you have to pay attention to when positioning the patient?

- A That the patient's arms are always lifted.
- B It is not necessary for the patient to lie straight.
- C The patient has to be located in the middle of the gantry.
- D The patient always lies in a feet-first position

12. Of the following cases, when is intravenous contrast agent administration prohibited?

- A The patient has renal failure (GFR=12 and Creatinin=80 umol/l), and dialysis is impossible
- B The patient is under 18 years of age.
- C The patient fasted 2 hours prior to imaging
- D The patient is diabetic, and she omitted her metformin containing antidiabetic medicine 48 hours prior to the exam

13. Which statement is true?

- A In case of subdural hemorrhage, if the routine head CT exam is complemented by CT angiography, we can get information about the source of hemorrhage.
- B SAH is most frequently caused by traumatic injury.
- C Fresh hemorrhage is always hypodens on CT.
- D A suspected ACA (art. cerebri anterior) aneurysm is an indication for a head CT examination.

14. Which statement is true?

- A In a traumatic head CT exam the FOV extends from the skull base to the vertex.
- B Head CTA images are parallel to the orbitomeatal plane.
- C During a routine head CT the patient gets 60-70 ml of intravenous contrast material.
- D In case of an enhancing intracranial space occupying lesion, the post contrast series has to be made, as well.

15. Which is not true for a perfusion CT examination?

- A Contrast administration is not necessary.
- B Patient positioning is the same as in routine head CT.
- C We acquire thick slices.
- D The measurement begins 5 minutes after contrast administration.

16. CT imaging of the facial bones should not be carried out in case of:

- A a foreign body in the orbit
- B complications of sinusitis
- C Nasal bone fracture
- D Polyposis

17. Which one is the correct answer? If there is a foreign body in one of the orbits:

- A The primary imaging method is always MRI
- B With CT we only acquire images with bone window
- C CT is the most informative imaging modality
- D Conventional radiography is good enough

18. How much contrast material have to be administered during a perfusion CT exam?

- A 20 ml
- B 40-60 ml
- C 2 ml/kg
- D 100 ml

19. The basic criteria of CT examinations of traumatic and orthopedic injuries:

- A thin slice bone window images
- B Administration of contrast material
- C Only soft tissue images
- D Reconstruction of MinIP images

20. Which of the following is not an indication for a cervical spine CT examination?

- A Suspected fracture
- B Traumatic spinal canal involvement
- C Disc herniation
- D Spondylarthrosis

21. After a lumbar spine CT, which of the following reconstructions is not required?

- A Coronal CPR
- B Sagittal MPR
- C Axial MPR parallel to the discs
- D Coronal AverIP

22. Which of the following does not require contrast administration during a lumbar spine CT?

- A Myelography
- B Tumour
- C Disc herniation
- D Distinguishing recidive hernia from scar tissue

23. The examination protocol of the mediastinum is equal to a(n)...

- A Chest CT
- B Abdominal CT
- C Neck soft tissue CT
- D HRCT

24. When imaging for a laryngeal disease (eg.: vocal paresis), the patient has to phonate the letter...

- A „e“
- B „a“
- C „á“
- D „l“

25. Which is not true for a mediastinum CT?

- A The patient lies supine with the arms close to the body
- B In almost all cases it is a part of chest CT
- C Administration of a contrast agent is required
- D MPR reconstruction plays an important role

26. The FOV in HRCT extends

- A From the lung apex to the adrenal glands
- B From the jugulum to the diaphragm
- C From the lung apex to the phrenicocostal angle
- D From the lung apex to the lower pole of the kidneys

27. What is the location of the ROI in chest CT?

- A The pulmonary trunk
- B The arcus aortae
- C The descending aorta
- D The left ventricle

28. Which is not true for HRCT?

- A Contrast administration is not required
- B It is used for the detection of diffuse lung diseases and parenchymal disorders
- C Images are acquired in breath-hold and in expiration as well
- D Images are taken with a soft kernel

29. What is the primary imaging modality of lung diseases?

- A 2-way radiography
- B MR
- C CT
- D US

30. Which statement is false?

- A Chest CT is made in spiral mode
- B Chest CT may be taken in expiration or in breath-hold
- C In case of lung cancer contrast administration is not required
- D Routine chest CT always extends to the adrenal glands

31. Windowing and kernel parameters in HRCT:

- A soft kernel - W/C=400/40
- B sharp kernel - W/C=400/40
- C sharp kernel - W/C=1500/-500
- D sharp kernel - W/C=2000/400

32. What is the location of the ROI in CT pulmonary angiography?

- A The arcus aortae
- B The pulmonary trunk
- C The descending aorta
- D The carotids

33. Which statement is false?

- A With CTA the lumen and walls of vessels and the perivascular space can also be assessed
- B Radiation exposure of CT is smaller compared to DSA
- C CTA is a less invasive technique compared to DSA
- D Using CTA we can not acquire direct multiplanar images

34. Which is not an indication for CTA?

- A Renal artery stenosis
- B Aorta dissection
- C Suspected middle cerebral artery aneurysm
- D Traumatic intracranial hemorrhage

35. In case of a non-traumatic SAH which exam complements routine head CT?

- A Head CTA
- B Two-way radiography
- C Contrast enhanced MRA
- D Routine head MR

36. What do we have to attend to during a CTA exam?

- A To acquire as thin slices as possible
- B That the flow of contrast material administration is 1,5-2
- C We always acquire a venous series, too
- D Postprocessing work is not required

37. The FOV of a chest-abdominal CT exam extends

- A From the jugular fossa to the diaphragm
- B From the lung apex to the bottom of the pubic symphysis
- C From the diaphragm to the bottom of the pubic symphysis
- D From the descending aorta to the aortic bifurcation

38. Which one of the following modalities does not provide functional images of the liver?

- A Dynamic MR
- B Multiphase CT
- C Scintigraphy (Tc⁹⁹ – sulfur colloid or IDA)
- D ERCP

39. When imaging a hemangioma what time delay do we choose for the late phase images?

- A 10-15 min
- B 1-2 min
- C 20 min
- D 5-6 min

40. Which statement is not true for a liver CT?

- A For a targeted liver CT, up to 150 ml of contrast material may be necessary
- B In a dynamic liver CT, the arterial phase is essential
- C Liver CT is acquired in sequential mode
- D Delay for the portal phase is 70-80 sec

41. Which statement is not true for CT examination of acute pancreatitis?

- A Intravenous contrast administration is not required
- B It is prohibited to give oral contrast to the patient
- C The patient lies prone during the examination
- D Non-enhanced images are enough for the diagnosis

42. For spleen imaging, which imaging modality is chosen primarily?

- A US
- B MR
- C CT
- D PET/CT

43. Which statement is false?

- A Oesophagus CT is included in the chest region with an extended FOV
- B For imaging the oesophagus we can either give an iodine or a barium containing oral contrast agent
- C In suspected aspiration, you have to give a little more oral contrast agent
- D Administration of i.v. contrast material is required for all oesophagus CT examinations

44. What does hydro-CT mean?

- A This is an examination technique for imaging the small intestines
- B During this technique, prior to the exam, the patient's stomach is filled with a negative oral contrast agent in order to dilate it
- C Hydro-CT means, that the whole GI tract is fully filled with water before the examination
- D This is a reconstruction technique

45. Which statement is true for CT colonography?

- A It does not require preparation
- B The bowels are filled with water
- C It is necessary to acquire thin slice images
- D Postprocessing is not required

46. Which statement is false?

- A The primary imaging modality of the adrenal glands is US
- B For visualizing the fat content of lesions in the adrenal glands MRI is the most suitable
- C Of all the imaging modalities, CT is better suited for detecting metastases
- D Clinical and laboratory parameters do not influence the imaging protocol of the adrenal glands

47. Regarding conventional urography, US and CT urography, which statement is false?

- A US is cheap, easily accessible, and it does not utilize ionizing radiation. The kidneys and the bladder are easy to assess on US.
- B Conventional iv. urography is being replaced by CT urography
- C CT has better contrast resolution than conventional urography
- D CT urography means less radiation exposure to the patient than conventional urography

48. Administration of contrast media is contraindicated in which case?

- A GFR < 30 and creatinin > 160 umol/l
- B GFR < 30 and creatinin > 100 umol/l
- C GFR < 60 and creatinin > 100 umol/l
- D GFR < 60 and creatinin > 160 umol/l

49. In case of renal colic, for the detection of kidney stones and urinary tract dilatation..... Which is true?

- A a non-enhanced CT examination might be enough
- B oral contrast media is required for the examination
- C we only take a plain x-ray image
- D US does not give sufficient information

50. Which reconstruction technique is used for visualizing the filled urinary tract?

- A MinIP
- B MIP
- C Vessel
- D MPR

51. Which statement is true for triple-bolus CT urography?

- A It means more radiation exposure for the patient than in conventional CT urography
- B It has better image quality than CT urography
- C It allows visualization of the parenchymal, secretory and vascular phases at the same time
- D A small volume of intravenous contrast material (20 ml) is enough for the exam

52. Of the following techniques which one depicts the zonal anatomy of the uterus best?

- A MRI using T2 weighted sequence
- B Arterial phase CT
- C Transabdominal US
- D Transvaginal US

53. Which statement is true for the male pelvis CT?

- A CT's role is limited in the differentiation between prostate hyperplasia, normal tissue and prostate cancer .
- B This is the primary imaging tool for the testes.
- C It is of little value for lymph node staging
- D Surrounding tissue infiltration is better visualized by US

54. Where is the ROI placed in a pelvis CT?

- A In the pulmonary trunk
- B In the ascending aorta
- C In the aorta bifurcation
- D In the descending aorta at the level of the diaphragm

55. Which modality is not used for imaging heart diseases?

- A CT
- B DEXA
- C Nuclear medicine (NM)
- D Conventional angiography (DSA)

56. Which is not true for coronary CT?

- A The examination is carried out using ECG triggering
- B The examination is carried out in diastole if the patient's heart rate is under 65 beats per minute (bpm). If it is above 65 bpm, the exam is carried out in systole.
- C 3 ml/kg of contrast material administration is required
- D When imaging with the latest dual-source CT scanners, it is not necessary to give beta-blockers to the patient

57. What is the name of the scale that grades the extent and the density of calcium deposition in the coronaries?

- A Hounsfield
- B Agatston
- C Curie
- D Ashworth

58. Where is the ROI placed in a heart CT?

- A In the right atrium
- B In the ascending aorta
- C In the left ventricle
- D In the aortic arch

59. What is an acceptance-test?

- A This is a technique for measuring the patient's status before the examination
- B This is a control test made regularly (daily, weekly or monthly) by users
- C A thorough test that is carried out prior to the installation of the equipment
- D This is the competence test of the radiographer

60. Among others, why is quality control needed?

- A Because it is important that the X-ray equipment operates perfectly as long as possible
- B To make bad quality CT images
- C So that patients get more radiation
- D So that the equipment consume more energy

True or false

61. CT images are made up of voxels.

62. In case of a traumatic facial bone CT, the FOV extends from the mandible to the frontal sinus.

63. Fresh blood is always hypodense on CT images.

64. Perfusion CT always has to be carried out in stroke patients.

65. For CTA examinations slice thickness is 5-10 mm.

66. Penumbra is the regional cerebral blood volume minus the regional cerebral blood flow.

67. When imaging the soft tissues of the extremities, CT is a second line modality.

68. Cervical disc hernia is verifiable very well on CT images.

69. For a heart CT, the FOV extends from the lung apex to the lower pole of the kidneys.

70. During CT urography, the late (secretory) phase series always has to be made.

Solutions

- | | | |
|---------------|-------|-----------|
| 1. a | 25. a | 49. a |
| 2. c | 26. c | 50. b |
| 3. b | 27. a | 51. c |
| 4. a | 28. d | 52. a |
| 5. b | 29. a | 53. a |
| 6. d | 30. c | 54. d |
| 7. c | 31. c | 55. b |
| 8. b | 32. b | 56. c |
| 9. b, d, a, c | 33. b | 57. b |
| 10. a | 34. d | 58. b |
| 11. c | 35. a | 59. c |
| 12. a | 36. a | 60. a |
| 13. d | 37. b | 61. True |
| 14. d | 38. d | 62. True |
| 15. a | 39. a | 63. False |
| 16. c | 40. c | 64. False |
| 17. c | 41. b | 65. False |
| 18. b | 42. a | 66. False |
| 19. a | 43. c | 67. True |
| 20. c | 44. b | 68. False |
| 21. d | 45. c | 69. False |
| 22. c | 46. d | 70. True |
| 23. a | 47. d | |
| 24. a | 48. a | |

III. X-ray

III.1. Conventional radiology and the radiology workplace

Conventional radiology is based on X-rays.

In 1895, the German physicist, Wilhelm Roentgen, accidentally discovered made. X-ray photons diverge outwards from this area. They travel in straight lines, and they can be detected by a variety of devices used for medical imaging. As the X-rays pass through the body, some will be absorbed by the organs and structures within the body, whilst others will reach the equipment used to form the image. During radiographic imaging, we create x-ray images by a physical phenomenon that is not detectable by the human eye. In short, by using imaging, we are visualizing the invisible.

Primary indications of conventional radiology:

- bone injuries, trauma
- certain diseases of the spine
- the basic method of investigating chest and lung diseases

Within conventional radiology we distinguish:

- static radiography – which is done either in the radiology department, in the ward (field shots) or in the operating room
- fluoroscopy

Static radiography provides information on current state; multiple images from different directions can be taken to facilitate spatial orientation.

The workplace consists of:

- examination table
- X-ray tube and tube stand
- vertical grid device

(Figures 1., 2., 3., 4., 5.)

Images can be acquired in several different imaging department.

These are:

- conventional film/screen technic
- fluoroscopy
- digital imaging

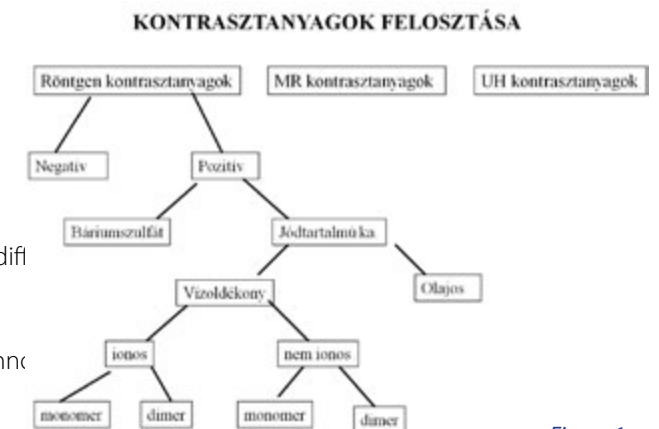

Figure 1.

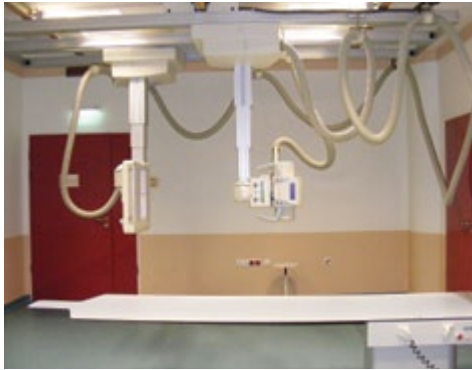

Figure 2.

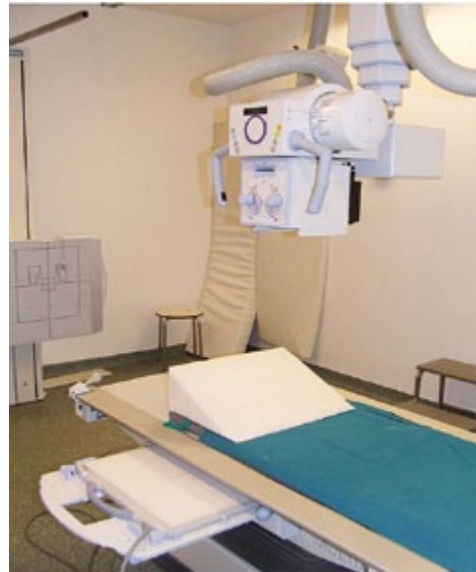

Figure 4.



Figure 3.



Figure 5.



Figure 6.

In analog radiography, an image is captured on a photographic film by the x-ray photons coming from the body. This method provides high resolution, although it has a narrower exposure latitude or dynamic range, compared with other imaging systems.

The film and cassettes are widely available in a variety of sizes (13 × 18, 18 × 24, 24 × 30, 30 × 40, 20 × 40, 35 × 35, 35 × 43 cm) and can be used with almost any piece of imaging equipment. Film development is automated and it is done by chemical means.

(Figure 6.)



Figure 7.

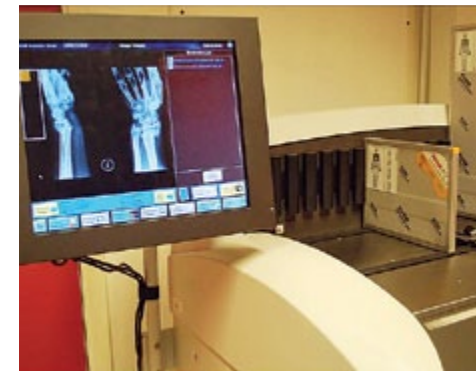

Figure 8.

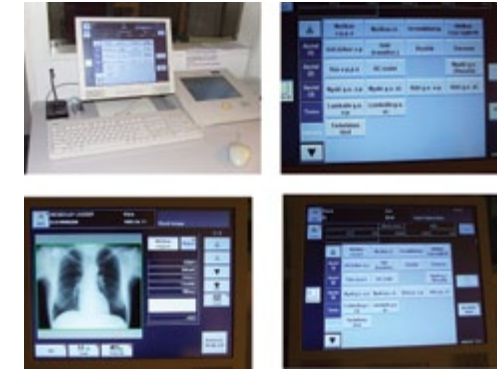

Figure 9.



Figure 10.

Film/screen imaging in radiography is gradually being replaced by digital imaging. There are many advantages to digital imaging: the workflow is faster, and it allows image processing to optimize the extraction of clinical information from an image.

In digital radiography, detection of X-rays and image processing occur in a digital manner. We can distinguish two forms of digital radiography:

- Partial digitalization of the phosphorous storage sheet system. In this case, there is a film in the cassette instead of a phosphorous sheet. After exposure, the cassette is placed in the automat to extract the information, which is then stored and converted into a digital image. (Figures 7., 8.)
- During full digitization, all operations occur electronically, such as in a flat panel detector. (Figures 9., 10., 11.)




Figure 11.

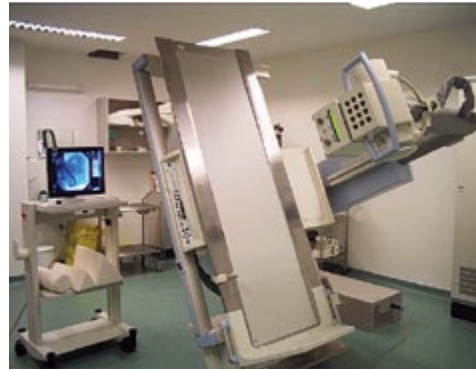

Figure 13.

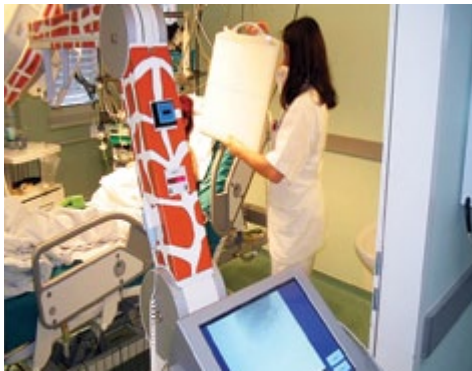

Figure 12.

If the patient can not be transported into the radiology department, it is possible to take mobile x-ray equipment into the ward.

(Figure 12.)

In the operating room, by using an image intensifier, we can assess each interventional step and result, for example: control of status after femoral nailing. In this case, it is possible to capture images, which may be archived.

This method of image acquisition employs an image intensifier to capture images, which are then displayed in real time or as static images on a monitor. Fluoroscopy is very useful for following the progress of contrast agent around the body, to control and to track angiographic

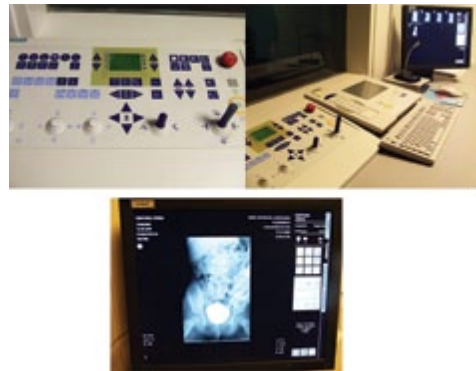

Figure 14.

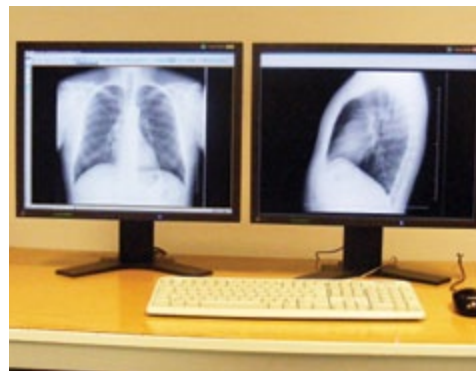

Figure 15.

devices, or to examine the gastrointestinal tract with contrast material. Fluoroscopy is used to capture complementary images, for motion and spatial assessment, and to guide invasive and noninvasive examinations.

(Figures 13.,14.)

In an analogue system, the images are developed by an automat. Evaluation is made on the viewing box. The films are then archived, where they can be looked up in the future.

Linking the digital X-ray into the Picture Archive and Communications Systems (PACS) system enables images to be reviewed at various reporting rooms, consultants' offices, wards, etc. This is where recording and archiving of images occur.

(Figure 15.)

III.2. X-ray photography

It is important to note that X-ray images are formed by projection, i.e. images of objects in the path of X-rays are projected on to a device for capturing the image, e.g. photographic material.

This differs from the way in which images are formed on the retina of the eye or on the photographic film in a camera where light travels from the object to the recording medium to produce an image that is a view of the object; a radiographic image is a projection of an object. The laws of central projection are magnification, distortion, summation and oblivescence.

Magnification: In a projected image, magnification will always be present, because the X-rays continue to diverge as they pass from the object to the image-acquisition device (henceforth referred to as the film for simplicity). The source of the X-rays is the X-ray tube focal spot. For a given focus-to-film distance (FFD), the greater the distance between the object and the film, the greater the magnification of the image will be. To minimize magnification, the object under examination should be positioned as close to the film as it is reasonable to do so. If the object-to-film distance has to be increased, e.g. in the case of a patient on a trolley, then the FFD can also be increased. Therefore, in daily practice, the goal is the ideal focus-film distance (100-150 cm), thus the object must be as close to the film as possible.

Distortion: A distorted image will be produced if not all parts of the image are magnified by the same amount. Distortion is due to diverging, obliquely incident rays on the edge of the cassette. Considering a thin, flat object, there will be constant magnification and thus no distortion when the film is parallel to the object. When possible, the part being radiographed should be placed parallel to the film to avoid distortion. If the object and film are not parallel to each other, then there is a difference in magnification of different parts of the object, leading to a distorted image. Distortion can be reduced if the FOD (focus-object distance) is increased and OFD (object-film distance) is reduced.

Summation: X-ray photons pass through each layer of the examined region, and each point of the body alters these photons. These X-ray modifications are summated, and these modifications make up the summated image. The advantage is that small, low density lesions become visible, for example: miliary tuberculosis. The disadvantage is the loss of information. This can be eliminated by capturing images from two different directions.

Oblivescence: If the object is relatively small compared to the radiation source and the OFD is relative large, then the shadow image of the object will not reach the film and the beam will for-

get the object. Consequently things remote from the film are lost, therefore the lesion of interest should always be as close to the film as possible.

The quality of the X-ray images are determined by three characteristic features:

- blackening – density
- contrast
- copper sharpness – resolution

Each time a radiograph is to be made, a set of exposure factors have to be chosen to give the type of image required. The choice of these factors will depend on the region being examined, including its thickness, density, pathology, etc. The exposure factors to be selected are:

- milliamperere seconds (mAs)
- kilovoltage (kV)

During the production of x-rays, the cathode receives a given amount of power; in practice this is called **mA**. The cathode spiral heats up, and electron emission occurs. The higher the mA, the more electrons are liberated. The number of liberated electrons are determined by the duration of heating (**secundum**). The amount of exposure, in practice, can be expressed by multiplying mA and s – called **mAs** – which determines the amount of radiation.

The electrons leaving the cathode are accelerated by the tube voltage, which is called **kV**. The greater the kV, the higher their velocity and energy will be. kV determines the intensity and hardness of the X-ray beam.

Density: Also known as the degree of film blackening. The optical density of the radiograph must be within a diagnostic range. If a radiograph is too light or too dark, an accurate diagnosis becomes difficult or impossible. If a change in technique is necessary, each of the following primary factors controlling density must be considered:

- Milliamperere (mA)
- Exposure time (second)
- Milliamperere-second (mAs)

It is important not to increase kV and mAs at the same time.

Contrast: Contrast is the difference in density between structures of interest within the image. The contrast must be sufficient to allow radiographic distinction of adjacent structures with different tissue densities. A wide range of contrast levels is produced among the variety of radiographic examinations performed. A low-contrast image will show little difference in density between structures of interest, whereas a high-contrast image will show a larger difference in density between structures. The primary controlling factor of radiographic contrast is kilovoltage

(kV). If the kV is low, attenuation effects and contrast are better. Above 100 kV, radiation penetration is greater, and the image has lower contrast, but it is more detailed.

Sharpness: In radiography, the aim is to produce an image that is as sharp as possible in order to resolve fine detail within the image. This is particularly important when looking for subtle fractures or changes in bone architecture. Unfortunately, there are several factors that may lead to image unsharpness, and these are:

- geometric unsharpness
- movement
- absorption (inherent factors)
- photographic unsharpness

Geometric unsharpness: If x-rays originated from a point source, then a perfectly sharp image would always be obtained. In an x-ray tube, however, x-rays are produced from the small area of the focal spot on the anode, and this leads to the formation of a penumbra or 'partial shadows' at the edge of the object. It is this that gives rise to geometric unsharpness. The degree of geometric unsharpness increases with a bigger focal spot size and a larger object-to-film distance. Geometric unsharpness can be a small, insignificant quantity, if the object is close to the film and a small focal spot is used.

Photographic unsharpness: Photographic unsharpness is the spread of light between the crystals and the photographic emulsion. The spread of light will be greater with larger crystals (regular or fast screens) and will also be greater with increasing distance between the crystal and the film (poor film/screen contact). In digital imaging, photographic unsharpness depends on the pixel size of the detector. It is affected by the central beam and the plane of the film as well. It is optimal if the film is parallel to the body part, and the central beam is perpendicular to the cassette plane.

Motion blur: It occurs when the patient, the tube or the cassette moves during the exposure. To avoid this problem, we can use certain fixing tools and a short exposure time. A short exposure time is also favored when imaging moving bodyparts.

III.3. Introduction to radiographic imaging techniques

Commonly used imaging techniques in conventional radiology are:

1. Static x-ray image

The x-ray image, irrespective of projection, is a 2-dimensional representation of a 3-dimensional structure. The image produced is therefore made up of multiple overlying structures.

Accurate localisation of an abnormality frequently requires at least two images obtained perpendicular to one another, e.g. anteroposterior and lateral projections.

Advantage: low radiation.

Disadvantage: it only provides information about status.

2. Fluoroscopy

This method of image acquisition employs an image intensifier to capture images, which are then displayed in real time or as static images on a monitor. Fluoroscopy is very useful for following the progress of a contrast agent around the body (in vessels or in bowels), for controlling tools during invasive procedures, but its resolution is poor compared with that of other image-acquisition methods. Fluorography employs photographic film to capture the image from the image intensifier.

Advantage: functional examination of organs is possible.

Disadvantage: relatively high radiation.

3. Hard beam technology:

A high tube voltage of 100-150 kV and a lower mAs value are used.

Advantage:

- improves the efficiency of beam usage – under the same tube loading, a higher energy radiation is created
- improves image quality – low exposure time reduces motion blur; the focus-film distance can be increased (150-200 cm) which results in the reduction of geometric blurring
- decreases the radiation absorbed by the body
- provides a more detailed picture
- improves contrast – the difference between minimum and maximum blackening decreases

We apply this technique almost exclusively when imaging the lungs and the chest. With this technique, the chest and the lungs are more detailed and the ribs do not interfere with the evaluation of the lungs.

4. Soft beam technology

It is suitable for emphasising the difference in contrast created by soft tissues; the essence is to harmonize contrast. A low tube voltage of 25-50 kV, and a high mAs value are used.

Technique: A special radiation source (molybdenum anode, small focus, beryllium window filter) is used, therefore geometric blurring is decreased, and sharpness is increased.

Advantage:

- increased radiation absorption difference between soft tissues
- the presence of a pathogenic processes may cause changes in contrast
- transparent areas (lipoma, fibrolipoma, subcutaneous emphysema, gas in abscess)
- intense shadows (vascular calcification, limescale tumor, lymph node, pancreas stone, kidney stone, gallbladder stone)

Application:

- extremity soft tissues, muscles
- mammograms

Anatomical terminology

- **Coronal plane:** it divides the body into an anterior and a posterior part. It is parallel to the longitudinal axis of the body.
- **Median sagittal plane:** it divides the body into right and left halves. Any plane that is parallel to this but divides the body into unequal right and left portions is simply known as **sagittal plane** or parasagittal plane.
- **Transverse or axial plane:** divides the body into a superior part and an inferior part. It is perpendicular to the longitudinal axis of the body.

Directions:

- anterior – frontal or ventral part of the body
- posterior – back or dorsal part of the body
- medial – closer to the center line
- lateral – farther from the center line
- distal – farther from the trunk
- proximal – closer to the trunk (extremities)
- cranial – towards the head
- caudal – towards the feet
- dexter – right
- sinister – left
- palmar
- plantar

Beam directions:

- antero-posterior AP – front to back
- postero-anterior PA – back to front
- dextro-sinister – lateral – right to left
- sinistro-dexter – lateral – left to right
- caudal-cranial – foot to head
- cranio-caudal – head to foot
- medio-lateral center-side
- latero-medial – center to lateral
- tangential
- axial - parallel to the axis

Beam directions at limbs:

- radio-ulnar
- volo-dorsal (from palm to back of hand)
- dorso-volar
- tibio-fibular
- dorso-plantar (from back of foot to sole of feet)
- planto-dorsal

Side markings:

- right – lateris dextri (l.d.)
- left – lateris sinistri (l.s.)
- both sides – lateris utriusque (l.u.)

Body postures:

- standing
- sitting
- half-sitting
- decubitus:
 - supine (dorsal decubitus) – lying on the back
 - prone (ventral decubitus) – lying face-down
 - lateral decubitus – lying on the side (right lateral decubitus – lying on the right side and left lateral decubitus – lying on the left side)

Required tools:

- different shapes and sizes of foam pads, which keep the patient in a comfortable posture
- sheets of paper for covering the exam table
- disinfectants for cleaning the table, the shooting stand, the cassettes, and the detector.

- side signals which are made of radiopaque material ("L" and "R")
 - radiation protection devices (gonad shields, lead aprons, thyroid protectors)
- (Figure 16.)



Figure 16.

Radiographer's tasks

The radiographer's task is complex. At the start of her shift she turns on the machine, checks its functioning, carries out the necessary checks and calibrations. She prepares the testing room for daily usage, and verifies that all the necessary tools are available. Before contrast-enhanced studies, she is responsible for the preparation of the contrast material and other equipments (needles, syringes, probes, kidney dish, etc.).

Patient preparation

Patient identification is always necessary. These data are the patient's name, date of birth, and identification number. The patient consent form should be given to the patient with a detailed explanation about content. It must be signed by the patient or legal guardians. Before any X-ray examination, ask all women in a fertile age whether they are pregnant or not! It is important to remove all items likely to cause artefacts on the final image. These may include: metal dentures, eye glasses, earrings, hair clips, hair bunches/buns and necklaces.

Preparation of taking an X-ray image

Surface disinfectants should be used on all work surfaces, including the table, the cassettes, the control panel, the X-ray tube head and the exposure switch after each patient. Put the table in the correct position, and choose the right cassette size. Choose an appropriate patient posture, and ensure that it is comfortable for the patient.

Centering

The part to be examined is usually placed at the center point of the cassette or to the position where the angulation of the central ray will project it to the center. Generally, the goal is to place the central ray at right angles only with the structure of interest. The beam of radiation must be

narrow enough to irradiate only the area under examination. Accurate positioning of the part and accurate centering of the central ray are of equal importance in obtaining a true structural projection.

Radiation protection

Protection of the patient from unnecessary radiation is the professional responsibility of the radiographer. The patient has to be protected from unnecessary radiation by using proper collimation and placing lead shielding between the gonads and the radiation source to restrict the radiation beam. Patients should never be seated against the examination table, as direct beams of X-rays will reach the gonads.

Exposure

The patient must be positioned and the exposure factors selected according to the region involved and the radiographic characteristics of the existent abnormality. Radiographers must understand the rationale behind the examination, otherwise, radiographs of diagnostic value cannot be produced. Having the information in advance prevents delay, inconvenience, and much more importantly, unnecessary radiation exposure to the patient. In an analog system, we choose the exposure values, while in a digital system we select the examination type. Exposure must occur in the appropriate respiratory phase (in chest examination). Instruct the patient how to achieve a proper breath hold, and instruct him or her to practice it before the exam.

General rules of taking an x-ray image

Always try to take X-ray images in standardized body positions.

For the limbs, the X-ray exams usually consist of two or more radiographs taken in orthogonal planes.

Create complementary images, if necessary.

Always take symmetric images for comparison views.

Various aids may be necessary for taking images in standardized body positions.

We can help the patient attain a comfortable position with pads and sponges, therefore we can eliminate motion artifacts.

After implantation of a prosthesis, the entire prosthesis has to be included in the image.

Body parts must always be identified by right or left side with a radiopaque material and placed on the cassette in the same manner, either facing or backing each other, according to established routines.

Machine settings should be selected prior to placing the patient on the table.
 Application of radiation safety objects, gonad shields, lead apron, etc..
 Application of the smallest beam target as possible.

General rules for taking an X-ray in case of injuries

The site of injury should be at the center of the film.
 For long bones, at least one joint has to be on the image.
 When imaging an articular joint, the joint cavity has to be at the center of the film.
 For children, image the contralateral side as well, for reference.

Errors and possible errors

A faulty cassette, wrong detector placement and improper choice of cassette size can all be a source of error, and a whole body part or a part of it may be missed.

Non-standardized body positions, improper centering, and wrong tube tilting may result in incorrect images.

If the patient moves during the exposure, motion artifacts are produced.

A small beam target may cause the examined body part to be missed. If the beam target is too big, that leads to bad image quality.

Side marker is missing or swapped.

Interfering objects are left on the patient.

When both sides are imaged for comparison, the images are not symmetric.

Radiation protection

X-rays penetrates tissues, and it also interacts with them. Therefore x-rays can be cytopathogenic in the living body and they may create biochemical and biological changes. This risk is increased as higher doses of radiation reach the body. Over the years, exposure accumulates.

The radiographs obtained for the initial examination of each body part are based on the anatomy or function of the part and the

type of abnormality, indicated by the clinical history. The radiographs obtained for the initial examination are usually the minimum required to detect any demonstrable abnormality in the region. Supplemental studies for further investigation are then made as needed. This method saves time, eliminates unnecessary radiographs, and reduces patient exposure to radiation. The beam of radiation must be narrow enough to irradiate only the area under examination. Gonad shielding should always be used to protect the patient. Contact, shadow, and large part area shields are used for radiographic examinations.

(Figure 17.)



Figure 17.

III.4. X-ray anatomy and imaging technique of the shoulder girdle and the humerus

The upper limb can be divided into two parts: shoulder girdle and upper extremity. The shoulder girdle is formed by two bones, the **clavicle** and **scapula**. Their function is to connect the upper limb to the trunk. The **clavicle**, classified as a long bone, has a body and two articular extremities. The clavicle lies in a horizontal oblique plane just above the first rib and forms the anterior part of the shoulder girdle. Its lateral aspect is termed the acromial extremity, and it articulates with the acromion process of the scapula (acromioclavicular joint). Its medial aspect, termed the sternal extremity, articulates with the manubrium of the sternum and the first costal cartilage (sternoclavicular joint).

The **scapula**, classified as a flat bone, forms the posterior part of the shoulder girdle. Triangular in shape, the scapula has two surfaces, three borders, and three angles. Lying on the superior posterior thorax between the second and seventh ribs, the scapula's medial border runs parallel to the vertebral column. The costal (anterior) surface of the scapula is slightly concave and contains the subscapular fossa. The dorsal (posterior) surface is divided into two portions by a prominent spinous process. The crest or spine arises at the superior third of the medial border from a smooth, triangular area and runs obliquely superior to end in a flattened, ovoid projection

called the acromion. The area above the spine is called the supraspinous fossa. The infraspinatus is the portion below the spine, which is called the infraspinous fossa. The superior border extends from the superior angle to the coracoid process and at its lateral end it has a deep depression, called the scapular notch. The medial border extends from the superior to the inferior angles. The lateral border extends from the glenoid cavity to the inferior angle. The superior angle is formed by the junction of the superior and medial borders. The lateral angle is the thickest part of the body of the scapula, and it ends in a shallow, oval depression called the glenoid cavity. The coracoid process arises from a thick base that extends from the scapular notch to the superior portion of the neck of the scapula. The proximal end of the humerus consists of a head, an anatomic neck, two prominent processes called the greater and lesser tubercles, and the surgical neck. The head is large, smooth, and rounded, and it lies in an oblique plane on the superomedial side of the humerus. Just below the head, lying in the same oblique plane, is the narrow, constricted anatomical neck. The constriction of the body just below the tubercles is called the surgical neck, which is the site of many fractures. The lesser tubercle is situated on the anterior surface of the bone, immediately below the anatomic neck.

Surface anatomy is the study of the superficial projection of anatomical structures that lie either deeper, or are protruding out through the skin. Surface anatomy plays an important role in the precise adjustment of x-ray images, in proper centering, and in landmarking.

Surface anatomy of the shoulder girdle: On the anterior surface of the shoulder girdle we can palpate the clavicle. Above it is the supraclavicular fossa, and below it we can find the infraclavicular fossa. Beyond the supraclavicular fossa the acromion is easily palpable; behind it lies the spina scapulae. The lower surface of the shoulder region is the axilla, or axillary fossa.

The most common indications:

- traumatic lesions
- degenerative changes
- inflammations

Shoulder – AP

Patient positioning: This examination can be carried out with the patient in the upright (standing, sitting) or supine positions. The patient stands, sits or lies with the affected shoulder against the cassette and he is rotated 15 degrees to bring the shoulder closer to the cassette and the plane of the acromioclavicular joint parallel to the central beam. Thus, the greater tubercle is profiled laterally. The arm is supine.

Exposure borders: The upper edge of the ray passes over the shoulder by approx. 2 cm. The lateral edge goes over the skin's surface by approx. 1 cm.

Film or image size: 18 × 24 cm

Focus-film distance: 100 cm

Centering: to the shoulder joint

Patient Instruction: breath hold

http://tamop.etk.pte.hu/tamop412A/Ke-palkotasi_gyakorlatok_tananyag/RTG/RTG_videok/01_vall_AP_en.avi

(Figure 18.)

Structures shown:

- the resulting image shows the bony and soft structures of the shoulder

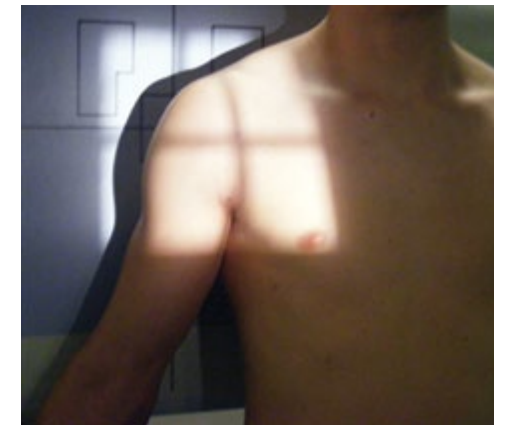


Figure 18.

Váll AP felvétele

- az expositió értéket úgy kell megválasztani, hogy a csont lágyrész is ábrázolódjon
- a caput humeri kissé rávetül a cavitas glenoidalisra
- tuberculum maius a caput humerire vetüljön

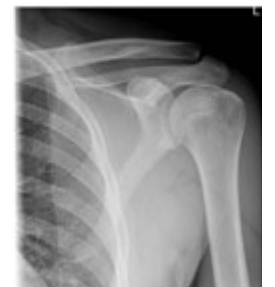

Figure 19.

- greater tubercle partially superimposing the humeral head
- slight overlap of the humeral head on the glenoid cavity
(Figures 19., 20.)

Shoulder – lateral/transthoracic

Its use is limited to the detection of fractures of the humerus, and luxation of the shoulder joint. It is good for the assessment of fractures of the surgical neck and / or luxation of the humeroscapular joint.

Patient positioning: This examination can be carried out with the patient in the upright (standing, sitting) or supine positions; the upright position is much easier for trauma patients. For upright positioning, seat or stand the patient in the lateral position before a vertical grid device. Have the patient raise the uninjured arm, rest the forearm on the head, and elevate the shoulder as much as possible. The injured arm should be placed against the cassette. The arm is supine, thus the greater tubercle is profiled laterally. If the patient cannot elevate the unaffected shoulder, angle the central ray 10 to 15 degrees cephalad to obtain a comparable radiograph.

Exposure borders: The upper edge of the ray passes over the shoulder by approx. 2 cm, and the lateral edge goes over the skin's surface by approx. 1 cm.

Film or image size: 18 × 24 cm

Focus-film distance: 100 cm

Centering: under the uninjured axilla by approx. 3 cm; the radiation passes through the chest directed to the contralateral humeral head

Patient Instructions: breath hold or shallow breathing

http://tamop.etk.pte.hu/tamop412A/Ke-palkotasi_gyakorlatok_tananyag/RTG/RTG_videok/02_vall_trasthoracalis_en.avi

(Figure 21.)

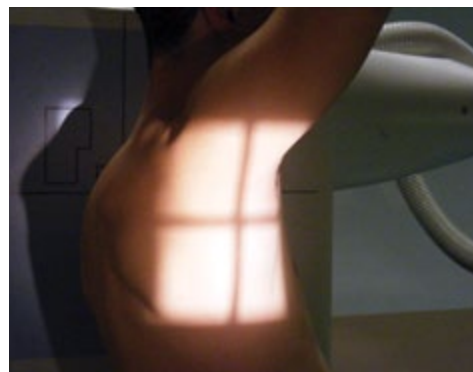


Figure 21.

Váll AP felvétele

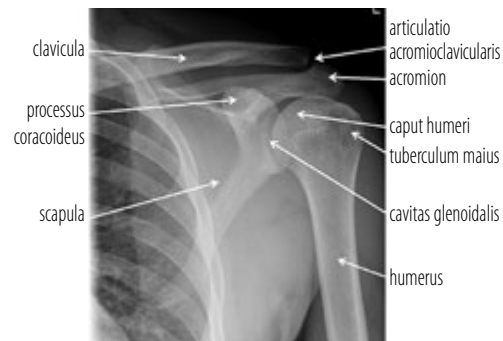


Figure 20.

A vállízület oldalirányú (transthoracalis) felvétele

- a vállízület oldalnézetben ábrázolódik az ellentétes váll, gerinc vagy sternum rávetülése nélkül
- a glenohumeralis ízület jól látható legyen

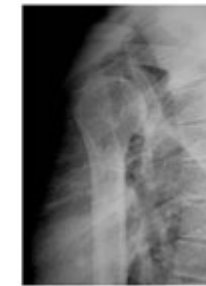

Figure 22.

Váll transthoracalis (oldalirányú) felvétele

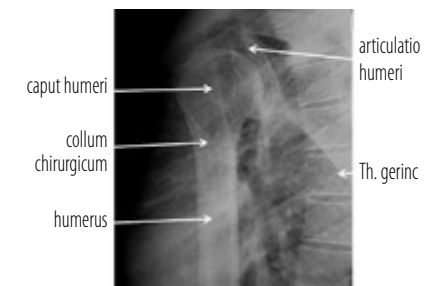


Figure 23.

Structures shown:

- lateral view of the shoulder joint, without superimposition of the contralateral shoulder, spine or sternum
- the glenohumeral joint must be clearly visible

(Figures 22., 23.)

Shoulder – axial

Patient positioning: This examination can be carried out with the patient in the upright (standing, sitting) or supine positions. The patient faces the vertical grid device and raises his arm up to vertical. The axilla is in the center of the grid. Or adjust the patient in the prone position with approximately a 7-6-cm thick pad under the shoulder being examined. Turn the patient's head away from the side being examined.

Exposure borders: The upper edge is the proximal third of the humerus, and the lower edge is the mid-scapula; on both sides the boundaries are the soft tissues.

Film or image size: 18 × 24 cm

Focus-film distance: 100 cm

Centering: to the shoulder joint

Patient Instruction: breath hold

(Figure 24.)

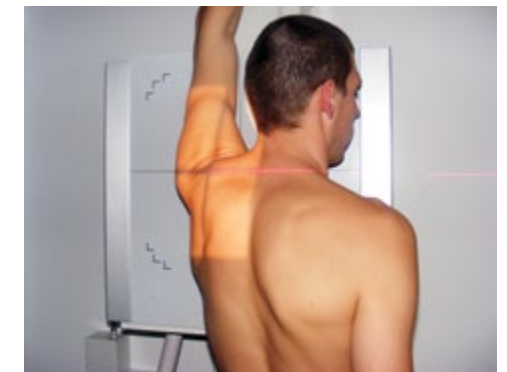

Figure 24.

A vállízület axiális felvétele

- a caput humeri és a scapula cavitas glenoidealis infero-superior vetületében ábrázolódnak
- az acromioclavicularis ízület a caput humerire vetül
- a caput és a collum humeri csaknem teljes oldalnézetben ábrázolódnak

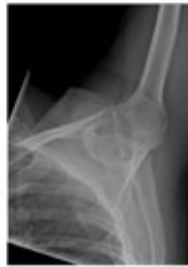

Figure 25.

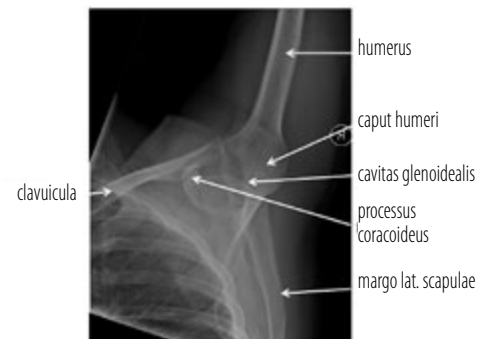
A vállízület axiális felvétele

Figure 26.

Structures shown:

- the image should demonstrate the head of the humerus, the acromion process, the coracoid process and the glenoid cavity of the scapula
- the head of the humerus and the glenoid cavity of the scapula are seen in infero-superior projection
- the acromioclavicular joint is superimposed on the humeral head
- the head and neck of the humerus should be seen in almost full lateral view

(Figures 25., 26.)

Clavicle – PA

Patient positioning: This examination can be carried out with the patient in the upright (standing, sitting) or supine positions. The patient sits or stands facing the vertical grid device.

The patient's position is adjusted so that the middle of the clavicle is in the centre of the cassette. The patient's head is turned away from the side being examined.

Exposure borders: The upper edge of the ray passes over the shoulder by approx. 2 cm, and the lateral edge goes over the skin's surface by approx. 1 cm.

Film or image size: 18 x 24 cm

Focus-film distance: 100 cm

Centering: to the center of the clavicle

Patient instruction: breath hold




Figure 27.

http://tamop.etk.pte.hu/tamop412A/Kepalkotasi_gyakorlatok_tananyag/RTG/RTG_vid-eok/03_clavicula_PA_en.avi

(Figure 27.)

Structures shown:

- the entire clavicle along with the acromioclavicular and sternoclavicular joints
- lateral part of the clavicle projected above the scapula with the medial end overlapping the first or second ribs

(Figures 28., 29.)

Clavicula PA felvétele

- a kulcsont egészében ábrázolódnak az acromioclavicularis és sternoclavicularis ízületekkel együtt
- a clavicula külső része a scapula fölé vetül, míg a mediális 1/3-ra bordák és a tüdő vetül

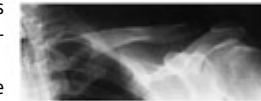

Figure 28.

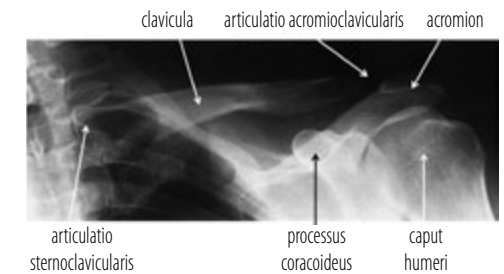
Váll transthoracalis (oldalirányú) felvétele

Figure 29.

Scapula – AP

Patient positioning: This examination can be carried out with the patient in the upright (standing, sitting) or supine positions. The patient stands with the affected shoulder against the cassette and rotated slightly inwards (10-15 degree) to bring the plane of the scapula parallel to the cassette. The arm is slightly abducted (90 degree) away from the body and medially rotated.

Exposure borders: The upper edge of the ray passes over the shoulder by approx. 2 cm, and the lower edge goes over the inferior angle of the scapula by approx. 1 cm. On both sides the boundaries are the soft tissues.

Film or image size: 24x30 cm

Focus-film distance: 100 cm

Centering: to the center of the scapula

Patient instructions: shallow breathing

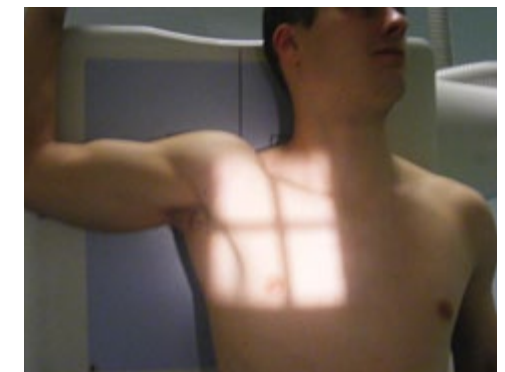


Figure 30.

http://tamop.etk.pte.hu/tamop412A/Kepalkotasi_gyakorlatok_tananyag/RTG/RTG_vid-eok/04_scapula_AP_en.avi
(Figure 30.)

Structures shown:

- lateral portion of the scapula free of superimposition from the ribs
 - the entire scapula should be demonstrated
- (Figures 31., 32.)

Scapula – lateral A scapula AP felvétele

- a scapula elfordulása nélkül ábrázolódjon
- lateralis szélé szabaddon ábrázolódjon

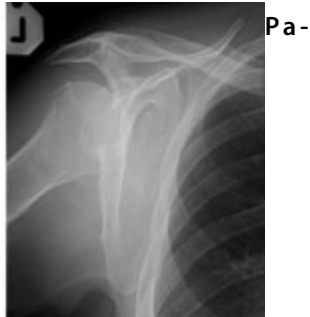

Figure 31.

patient positioning: This examination can be carried out with the patient in the upright (standing, sitting) or supine positions. Adjust the patient in an RAO or LAO position, with the affected scapula centered to the grid. The average patient requires a 60 degree rotation from the plane of the cassette. The arm is abducted with the elbow flexed to allow the back of the hand to the sacrum. In prone position, the patient is holding his other shoulder with the affected arm.

Exposure borders: The upper edge of the ray passes over the shoulder by approx. 2 cm, and the lower edge goes over the inferior angle of the scapula by approx. 1 cm. On both sides, the boundaries are the soft tissues.

Film or image size: 24 × 30 cm

Focus-film distance: 100 cm

Centering: to the center of the scapula

Patient Instructions: shallow breathing

(Figure 33.)

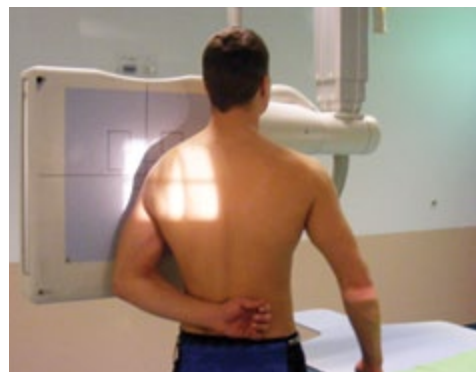

Figure 33.

Scapula AP felvétele

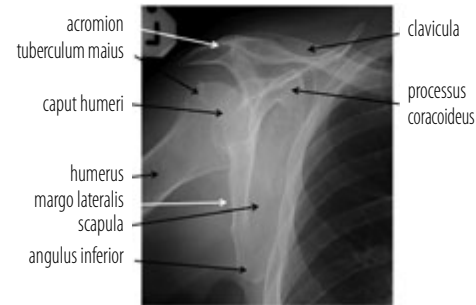


Figure 32.

Structures shown:

- the scapula should be demonstrated clear of the ribs
 - lateral portion of the scapula
- (Figures 34., 35.)

Scapula oldalirányú felvétele

- a scapula teljes oldalnézetben
- borda nem vetül rá

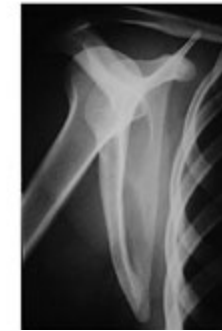


Figure 34.

Scapula oldalirányú felvétele

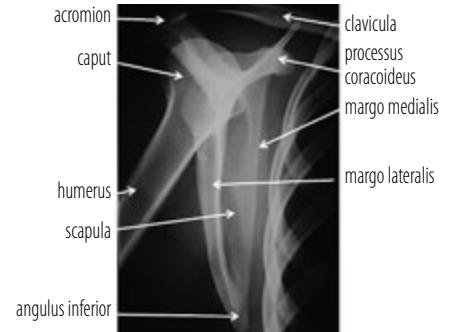


Figure 35.

Acromioclavicular joint – AP

Indications: luxation, subluxation

Patient positioning: This examination can be carried out with the patient in the upright (standing, sitting) or supine positions. The patient stands, facing the X-ray tube, with the arms relaxed to the side. The patient is rotated approximately 15 degrees towards the side being examined to bring the acromioclavicular joint space at right angles to the film. The patient is positioned so that the acromion process is in the centre of the film.

Exposure borders: The upper edge of the ray passes over the shoulder by approx. 2 cm, and the lower edge goes over the clavícula by approx. 1 cm. On both sides, the boundaries are the soft tissues.

Film or image size: 18 × 24 cm

Focus-film distance: 100 cm

Centering: to the AC joint

Patient Instructions: shallow breathing

(Figures 36., 37., 38.)

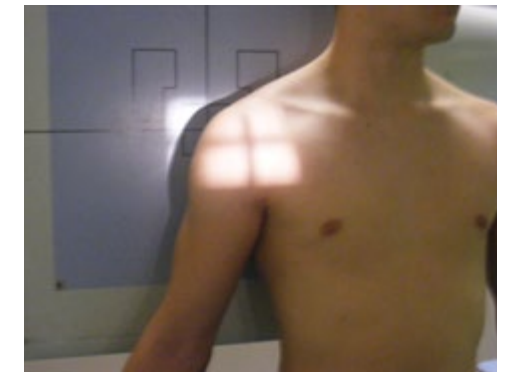


Figure 36.

A cromioclavicularis ízület AP felvétele

- AC ízület elfordulás nélkül ábrázolódik

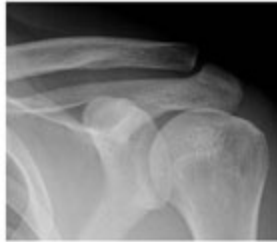

Figure 37.

Acromioclavicularis ízület AP felvétele

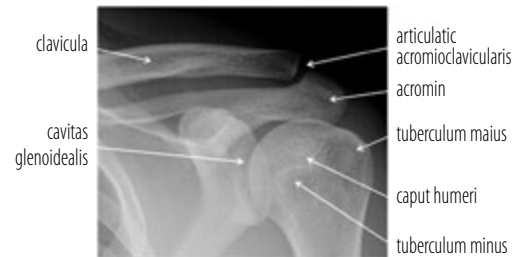

Figure 38.

Acromioclavicular joint – comparative AP

In case of AC trauma, images of the contralateral side should always be prepared. These images can be made separately or if the patient is thin, at the same time. If they are prepared separately, care should be taken so that images are symmetric .

Patient positioning: This position can be carried out with the patient in the upright (standing, sitting) or supine positions. The patient stands facing the X-ray tube, with the arms relaxed to the side. The patient is rotated approximately 15 degrees towards the side being examined to bring the acromioclavicular joint space at right angles to the film. The patient is positioned so that the acromion process is in the centre of the film.

Exposure borders: The upper edge of the ray passes over the shoulder by approx. 2 cm, and the lower edge goes over the clavicle by approx. 1 cm. On both sides the boundaries are the soft tissues.

Film or image size: 15 × 40 or 18 × 24 cm

Focus-film distance: 100 cm

Centering: to the jugulum

Patient Instructions: shallow breathing
(Figure 39.)

Structures shown:

- both AC joints should be demonstrated symmetrically without rotation
(Figure 40.)

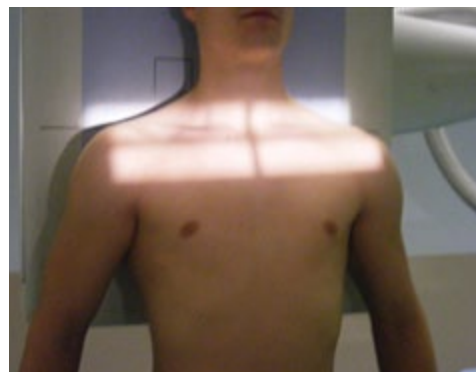


Figure 39.

It may be necessary to take stress images (weighted views). In this case, the patient holds a weight of approximately 5 kg in each hand for 5 minutes and then the images are taken with the weights still in his hand.

(Figure 41.)

Humerus – AP

Patient positioning: This position can be carried out with the patient in the upright (standing, sitting) or supine positions. The patient sits or stands with her back in contact with the cassette. The patient is rotated towards the affected side to bring the posterior aspect of the shoulder, upper arm and elbow into contact with the cassette. The patient's arm is in supine position and in the center of the cassette.

Exposure borders: The upper edge of the ray passes over the shoulder by approx. 2 cm, and the lower edge goes over the elbow joint by approx. 2 cm. On both sides the boundaries are the soft tissues.

Film or image size: 15 × 40 cm

Focus-film distance: 100 cm

Centering: to the humerus

http://tamop.etk.pte.hu/tamop412A/Ke-palkotasi_gyakorlatok_tananyag/RTG/RTG_videok/05_humerus_AP_en.avi

(Figure 42.)

Structures shown:

- the AP projection demonstrates the entire length of the humerus
- elbow and/or shoulder joint should be demonstrated

Acromioclavicularis ízület összehasonlító terheléses AP felvétele

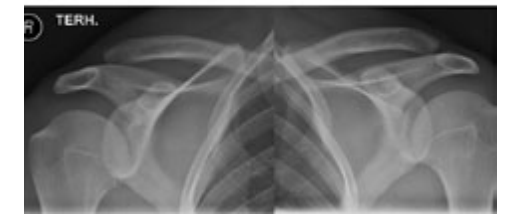


Figure 40.

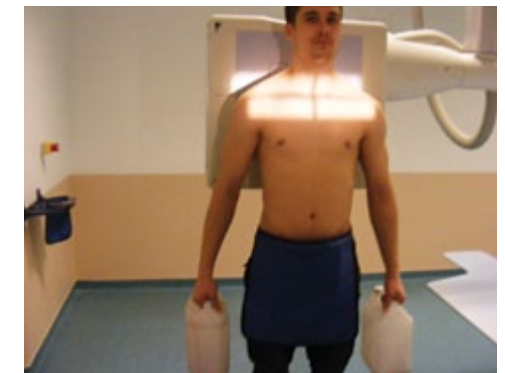

Figure 41.

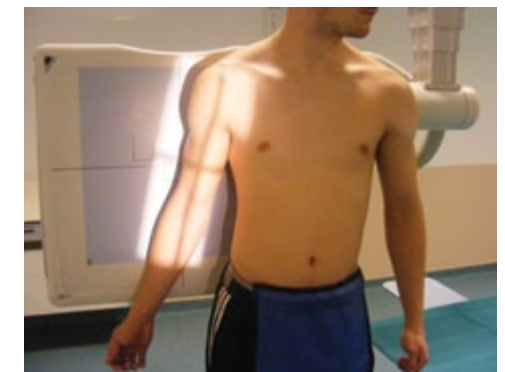

Figure 42.

- maximal visibility of epicondyles without rotation
- humeral head and greater tubercle in profile

(Figures 43., 44.)

Humerus – lateral

Patient positioning: This examination can be carried out with the patient in the upright (standing, sitting) or supine positions. Positioning is the same as that for the AP image, but the elbow is flexed, the palms are on the patient's abdomen, and the arm is abducted.

Humerus AP felvétele

- a humerus teljes egészében ábrázolódjon a váll és/ vagy a könyök ízülettel
- a humerus lateralis és medialis epicondylus ugyanabban a síkban, elfordulás nélkül ábrázolódjon
- a humerus AP helyzetben legyen (mind a caput humeri, mind pedig a tuberculum maius humeri)

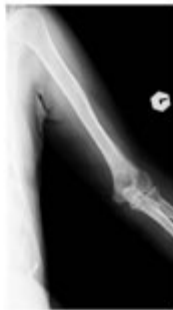

Figure 43.

Exposure borders: The upper edge of the ray passes over the shoulder by approx. 2 cm, and the lower edge includes the elbow joint. On both sides, the boundaries are the soft tissues.

Film or image size: 15 × 40 cm

Focus-film distance: 100 cm

Centering: to the humerus

http://tamop.etk.pte.hu/tamop412A/Ke-palkotasi_gyakorlatok_tananyag/RTG/RTG_videok/06_humerus_oldal_en.avi

(Figure 45.)

Structures shown:

- the AP projection demonstrates the entire length of the humerus
- elbow and/or shoulder joint should be demonstrated

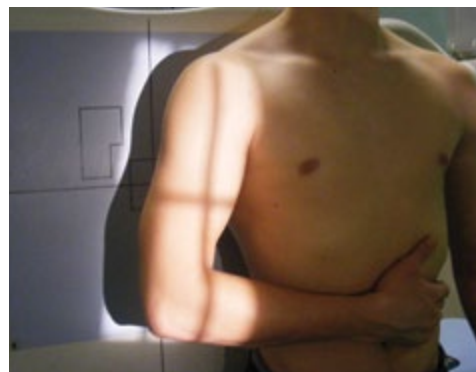


Figure 45.

Humerus AP felvétele

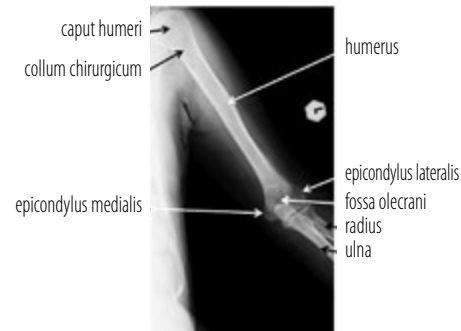


Figure 44.

Humerus oldalirányú felvételei

- a humerus teljes egészében ábrázolódjon a váll és a könyök ízülettel
- a tuberculum maius a caput humerire vetüljön
- a tuberculum minus oldalnézetben ábrázolódjon
- a lateralis és a medialis epicondylus egymásra vetüljön

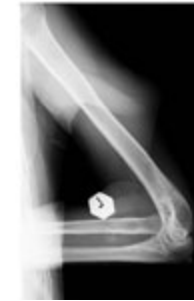

Figure 46.

Control image through the plaster cast

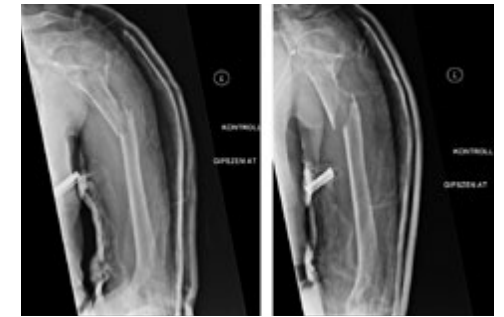


Figure 49.

Humerus oldalirányú felvétele

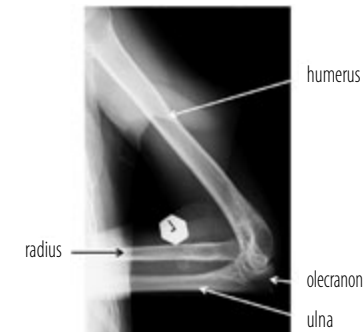

Figure 47.

Status after osteosynthesis

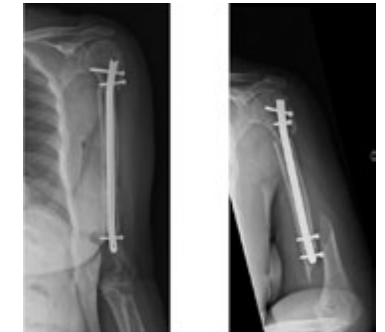

Figure 50.

Dislocated fracture with shortening on the proximal third of the humerus

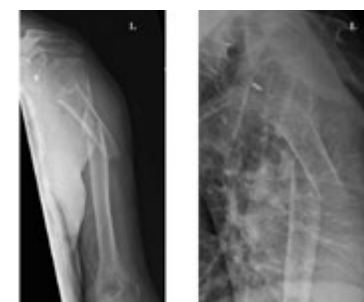

Figure 48.

Status after TEP implantation

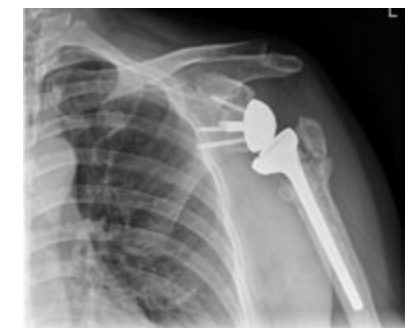

Figure 51.

- greater tubercle superimposed over the humeral head
- superimposed epicondyles
- the lesser tubercle is seen in a lateral position

(Figures 46., 47.)

(Figures 48–51. Pathologies)

III.5. X-ray anatomy and imaging technique of the upper limb

Elbow joint

The elbow is a hinge joint made up of the distal epiphysis of the humerus, and proximal epiphysis of the ulna and radius. The distal end of the humerus is called the humeral condyle and includes two smooth elevations for articulation with the bones of the forearm - the trochlea on the medial side and the capitulum on the lateral side. The medial and lateral epicondyles are superior to the condyle and easily palpated. On the anterior surface superior to the trochlea, a shallow depression called the coronoid fossa receives the coronoid process when the elbow is flexed. The relatively small radial fossa, which receives the radial head when the elbow is flexed, is located lateral to the coronoid fossa and proximal to the capitulum. The olecranon fossa is a deep depression found immediately behind the coronoid fossa on the posterior surface and accommodates the olecranon process when the elbow is extended.

The elbow joint is a complex joint, and consists of three joints:

- humeroradial joint
- humeroulnar joint
- radioulnar joint

The forearm consists of two bones that lie parallel to each other - the radius and ulna. The proximal end of the radius belongs to the elbow, while its distal end makes up the wrist. Like other long bones, they have a body and two articular extremities. The radius is located on the lateral side of the forearm, and the ulna is on the medial side. The body of the ulna is long and slender and tapers inferiorly. The proximal process, or olecranon process, concaves anteriorly and slightly inferiorly and forms the proximal portion of the trochlear notch. The more distal coronoid process projects anteriorly from the anterior surface of the body and curves slightly superiorly. The proximal end of the radius is small and presents a flat disklike head above a constricted area called the neck. Just inferior to the neck on the medial side of the body of the radius is a roughened process called the radial tuberosity. The distal end of the radius is broad and flattened and has a conic projection on its lateral surface called the radial styloid process. For the forearm, the most common types of injuries are fractures.

Wrist joint

The wrist has eight carpal bones, which are fitted closely together and arranged in two horizontal rows, and two forearm bones (radius and ulna). The proximal row of carpal bones, which is nearest to the forearm, contains the scaphoid, lunate, triquetrum, and pisiform. The distal row includes

the trapezium, trapezoid, capitate, and hamate bones. Between the two rows are the intercarpal joints. The joints between the metacarpals and the distal row are the carpo-metacarpal joints.

Hand

The hand consists of 27 bones, which are subdivided into the following groups – phalanges: bones of the digits (fingers and thumb); metacarpals: bones of the palm; carpals: bones of the wrist. The metacarpal bones have three parts: base, body and head. The head of the metacarpal and the base of the proximal phalange make up the metacarpophalangeal joint. The first digit has two phalanges: proximal and distal. The other digits have three phalanges: proximal, middle, and distal. The joints between the phalanges are called the interphalangeal joints.

Indications: trauma, articular disease, bone lesions.

Surface anatomy of the elbow:

The elbow joint has 3 palpable bony protrusions:

- medial epicondyle (bigger)
- lateral epicondyle (smaller)
- olecranon

Elbow – AP

Patient positioning: Extend the elbow, supinate the hand, and center the cassette to the elbow joint. Adjust the cassette to make it parallel with the long axis of the arm. Have the patient lean laterally until the humeral epicondyles and the anterior surface of the elbow are parallel with the plane of the cassette. Supinate the hand to prevent rotation of the bones of the forearm. The shoulder is lowered to the same level as the elbow joint.

Exposure borders: The upper edge is the distal third of the upper arm, and the lower edge is the proximal third of the forearm, while the lateral edges are the soft tissues.

Film or image size: 13 × 18 cm

Focus-film distance: 100 cm

Centering: to the center of the elbow joint

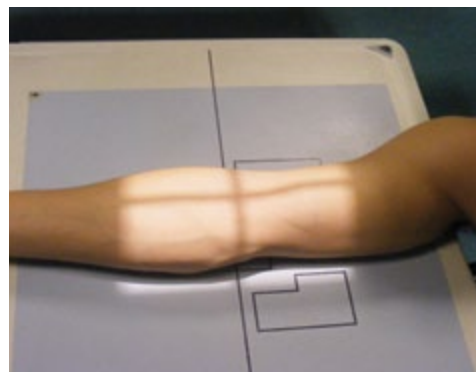


Figure 52.

http://tamop.etk.pte.hu/tamop412A/Kepalkotasi_gyakorlatok_tananyag/RTG/RTG_video/07_konyok_AP_en.avi

(Figure 52.)

Structures shown:

- elbow joint open and centered to the central ray
- no rotation of the humeral epicondyles

(Figures 53., 54.)

Könyök AP (volo-dorsalis) felvétele

- humerus epicondylusait összekötő egyenes párhuzamos legyen a film síkjával
- könyökízületi rész jól ábrázolódik

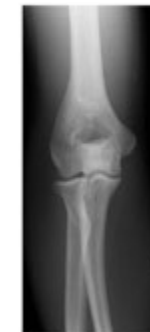

Figure 53.

Könyök AP felvétele

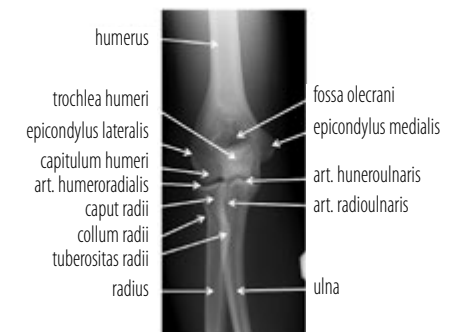


Figure 54.

Elbow – lateral

Patient positioning: The patient is seated alongside the table, with the affected side nearest to the table. The elbow is flexed 90 degrees and the palm of the hand is rotated so that it is at 90 degrees to the tabletop. The shoulder is lowered to the same level as the elbow joint.

Exposure borders: The upper edge is the distal third of the upper arm, and the lower edge is the proximal third of the forearm, while the lateral edges are the soft tissues.

Film or image size: 13 × 18 cm

Focus-film distance: 100 cm

Centering: to the center of the lateral epicondyle

http://tamop.etk.pte.hu/tamop412A/Kepalkotasi_gyakorlatok_tananyag/RTG/RTG_video/08_konyok_oldal_en.avi

(Figure 55.)

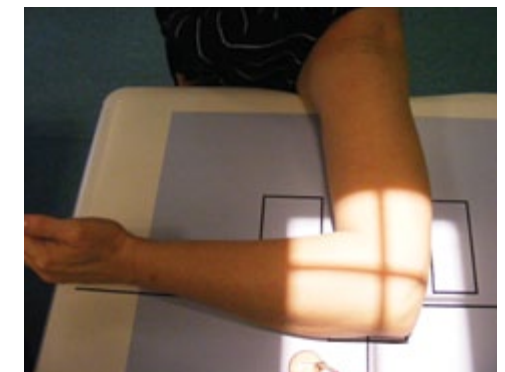

Figure 55.

Könyök oldalirányú felvétele

- könyök 90 fok-ban hajlított ízületirés nyitott
- epicondylusok egymásra vetülnek
- olecranon oldalnézetben ábrázolódnak

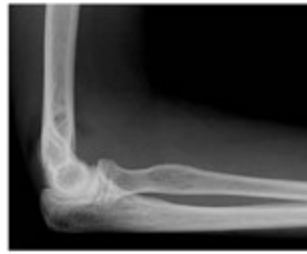

Figure 56.

Structures shown:

- open elbow joint centered to the central ray
- elbow flexed 90 degrees
- superimposed humeral epicondyles
- olecranon in lateral position

(Figures 56., 57.)

(Figures 58., 59. Pathologies.)

Fracture of the distal epiphysis of the humerus

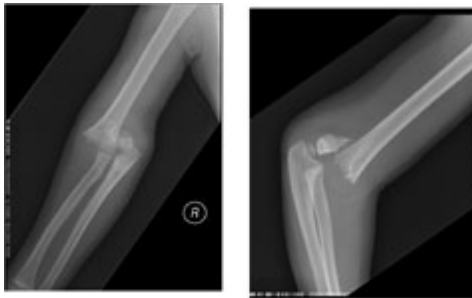

Figure 58.

Könyök oldalirányú felvétele

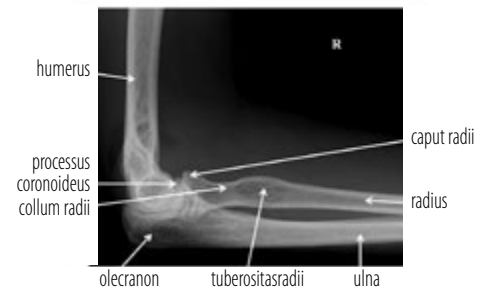

Figure 57.

X-ray images during and after the surgery humerus

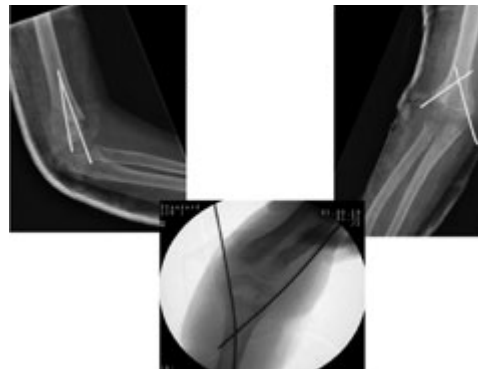

Figure 59.

Elbow – axial

Patient positioning: The patient is seated alongside the table, with the affected side nearest to the table. The elbow is fully flexed, and the palm of the hand is facing the shoulder. The posterior aspect of the upper arm is placed on the cassette, with the arm parallel to the long axis of the cassette.



Figure 60.

A könyökízület axiális felvétele

- olecranon szuperpozíció nélkül ábrázolódjon
- a radius és az ulna a humerusra vetül

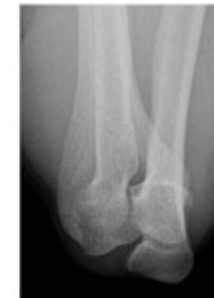

Figure 61.

Könyök axiális felvétele

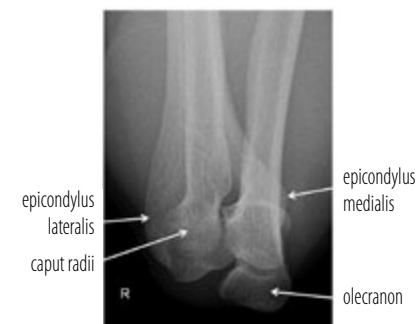


Figure 62.

Exposure borders: The upper edge is the distal third of the upper arm, while the lower and the lateral edges are the soft tissues.

Film or image size: 13 × 18 cm

Focus-film distance: 100 cm

Centering: to the olecranon

(Figure 60.)

Structures shown:

- forearm and humerus superimposed
- olecranon is seen without superposition (Figures 61., 62.)

Head of the radius and capitulum humeri

Patient positioning: The patient is seated alongside the table, with the affected side nearest to the table. The elbow is flexed 90 degrees and the palm of the hand is rotated so that it is at 90 degrees to the tabletop. The shoulder is lowered to the same level as the elbow joint.

Exposure borders: The upper edge is the distal third of the upper arm, while the lower and lateral edges are the soft tissues.

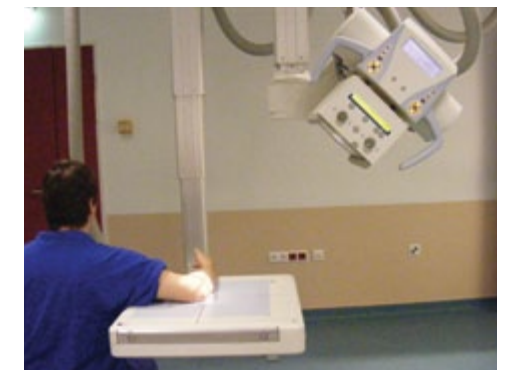


Figure 63.

Film or image size: 13 × 18 cm

Focus-film distance: 100 cm

Centering: in dorso-ventral direction, the ray passes through the radial head at a 45 degree angle.

(Figures 63., 64.)

Structures shown:

- the radial head is profiled ventrally without superposition
- the humeral capitulum and its articular surface are visualised slightly protracted

(Figures 65., 66.)

Radius fejecs és capitulum humeri felvétele

- a radius fejecs ventralian vetüljön és mentes legyen a szuperpozíciótól
- a capitulum humeri és a capitulum humeri ízfelszíne jól, bár enyhén elnyújtva ábrázolódik

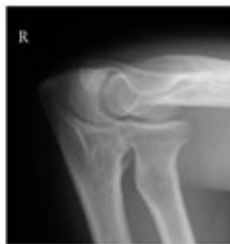

Figure 65.




Figure 64.

Radius fejecs és capitulum humeri felvétele

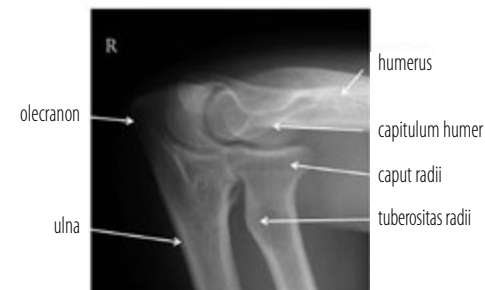

Figure 66.

Forearm – AP (volo-dorsal)

Patient positioning: The patient is seated alongside the table, with the affected side nearest to the table. The arm is abducted and the elbow joint is fully extended, with the supinated forearm resting on the table. The shoulder is lowered to the same level as the elbow joint. The cassette is placed under the forearm to include the wrist joint and the elbow joint.

Exposure borders: The upper edge is above the elbow by approx. 2 cm, and the lower edge is under the wrist by approx. 2 cm, while the lateral edges are the soft tissues.

Film or image size: 15 × 40 cm

Focus-film distance: 100 cm

Centering: to the center of the forearm



Figure 67.

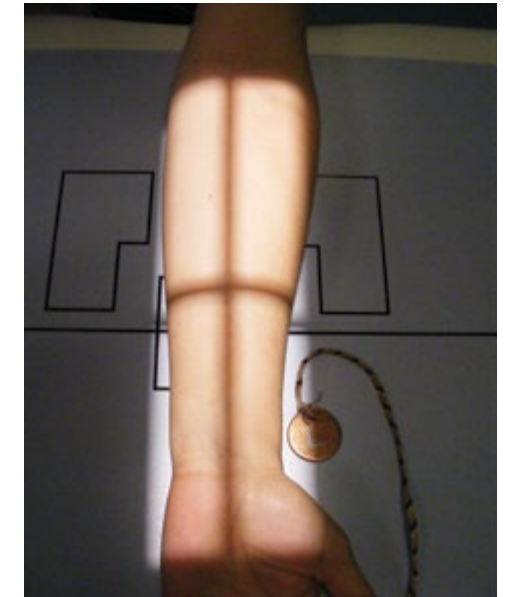

Figure 68.

Both the elbow and the wrist joints must be demonstrated on the cassette or at least one joint, which is nearest to the injury.

http://tamop.etk.pte.hu/tamop412A/Kepalkotasi_gyakorlatok_tananyag/RTG/RTG_video/09_alkar_AP_en.avi

(Figures 67., 68.)

Alkar AP/volo-dorsalis felvétele

- humerus condylusai elfordulás nélkül ábrázolódnak
- capitulum, collum, tuberositas enyhén pronációban vannak
- a felvételen látható a carpalis csontok proximalis sora és a humerus distalis vége

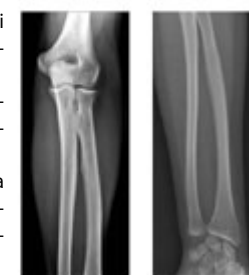

Figure 69.

Alkar + könyök felvétele

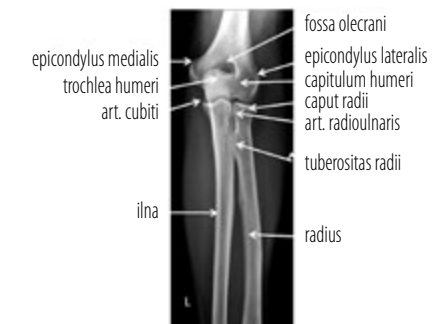


Figure 70.

Structures shown:

- no elongation or foreshortening of the humeral epicondyles
- humeral condyles project without rotation
- capitulum humeri, column and tuberositas radii are in prone position

(Figures 69–71.)

Forearm – lateral

Patient positioning: From the antero-posterior position, the elbow is flexed 90 degrees. The humerus is internally rotated 90 degrees to bring the medial aspect of the upper arm, elbow, forearm, wrist and hand into contact with the table. The cassette is placed under the forearm to include the wrist joint and the elbow joint. The shoulder is lowered to the same level as the elbow joint.

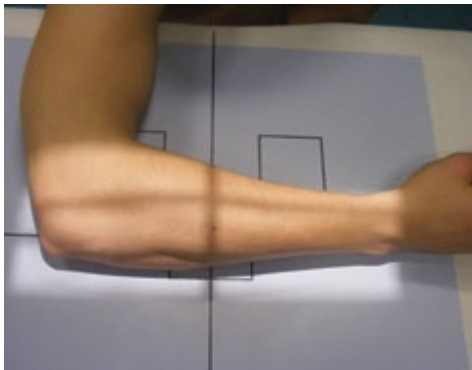


Figure 72.




Figure 73.

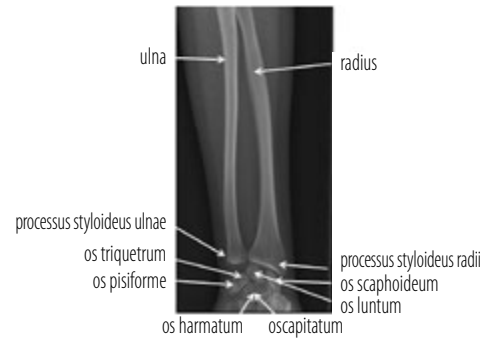
Alkar + csukló AP felvétele, bal

Figure 71.

Exposure borders: The upper edge is above the elbow by approx. 2 cm, and the lower edge is below the wrist by approx. 2 cm, while the lateral edges are the soft tissues.

Film or image size: 15 × 40 cm

Focus-film distance: 100 cm

Centering: to the center of the forearm

Both the elbow and the wrist joint must be demonstrated on the cassette or at least one joint, which is nearest to the injury.

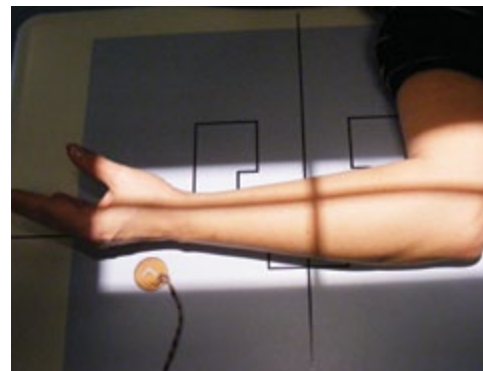


Figure 74.

http://tamop.etk.pte.hu/tamop412A/Kepalkotasi_gyakorlatok_tananyag/RTG/RTG_video/10_alkar_oldal_en.avi

(Figures 72., 73., 74.)

Structures shown:

- radial and ulnar styloid processes and the epicondyles of the humerus are superimposed
- elbow flexed 90 degrees

(Figure 75., 76., 77.)

Surface anatomy of the wrist: On the volar side there are 2-3 skin folds. The distal line of these coincides with the bones of the proximal carpal row. The ulnar styloid process is palpable near the V. digit, while the radial styloid process is palpable near the I. digit.

Alkar oldalirányú felvétele

- a könyökizület 90 fok-ban hajlított
- a radius és az ulna distalis vége egymásra vetül

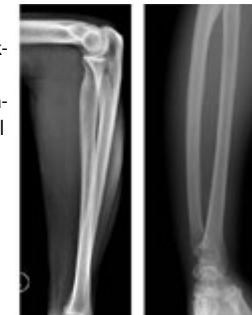

Figure 75.

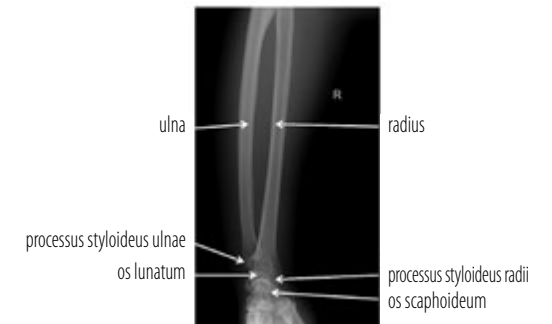
Alkar + csukló oldalirányú felvétele

Figure 77.

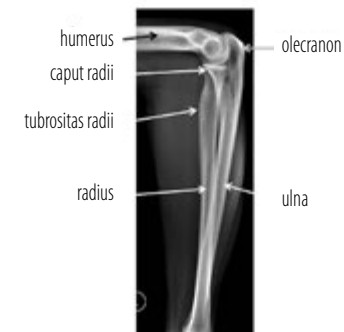Alkar + könyök oldalirányú felvétele

Figure 76.

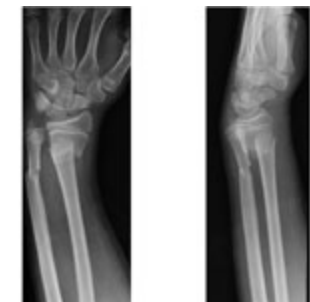Fracture on the distal thirds of the ulna and radius

Figure 78.

Wrist – AP (dorso-volar)

Patient positioning: The patient is seated alongside the table, with the affected side nearest to the table. The elbow joint is flexed 90 degrees and the arm is abducted, such that the anterior aspect of the forearm and the palm of the hand rest on the cassette. If the mobility of the patient permits, the shoulder joint should be at the same height as the forearm. The wrist joint is placed on one half of the cassette and adjusted to include the lower part of the radius and ulna and the proximal two-thirds of the metacarpals. The fingers are flexed slightly to bring the anterior aspect of the wrist into contact with the cassette.

Exposure borders: The upper edge is the distal third of the forearm, and the lower edge is the proximal two-thirds of the metacarpals, while the lateral edges are the soft tissues.

Film or image size: 13 × 18 cm

Focus-film distance: 100 cm

Centering: to the middle of the wrist

http://tamop.etk.pte.hu/tamop412A/Kepalkotasi_gyakorlatok_tananyag/RTG/RTG_video-ok/11_csuklo_dorso-volaris_en.avi
(Figure 79.)

Structures shown:

- the distal radius and proximal metacarpals without rotation
- the distal ulna is projected slightly oblique

(Figures 80., 81.)

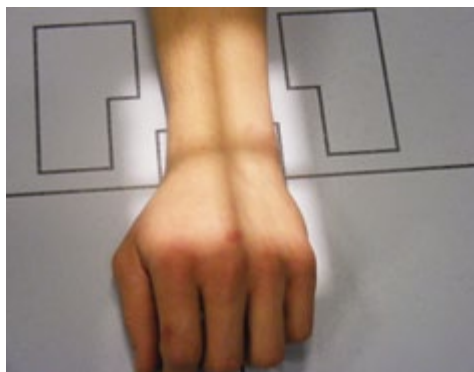


Figure 79.

Csukló AP/dorso-volaris irányú felvétele

- a radius distalis vége és a proximális metacarpusok elfordulás nélkül ábrázolódnak
- az ulna distalis vége kissé ferdén vetül

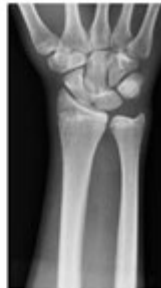

Figure 80.

CsuklóAP felvétele

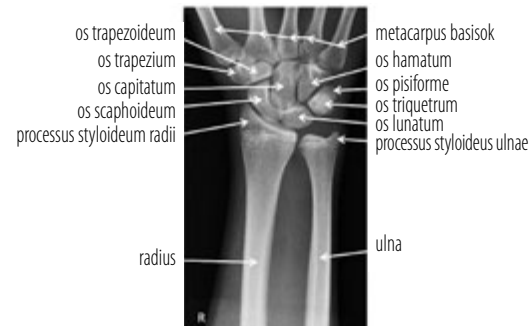


Figure 81.

Wrist – lateral

Patient positioning: The patient is seated alongside the table, with the affected side nearest to the table. The elbow joint is flexed 90 degrees and the arm is abducted. The arm is lying on the ulnar side (in lateral position). If the mobility of the patient permits, the shoulder joint should be at the same height as the forearm. The wrist joint is placed on one half of the cassette and adjusted to include the lower part of the radius and ulna and the proximal two-thirds of the metacarpals. The longitudinal axis of the hand-forearm is parallel to the longitudinal axis of the detector.

Exposure borders: The upper edge is the distal third of the forearm, and the lower edge is the proximal two-thirds of the metacarpals, while the lateral edges are the soft tissues.

Film or image size: 13 × 18 cm

Focus-film distance: 100 cm

Centering: to the middle of the wrist

http://tamop.etk.pte.hu/tamop412A/Kepalkotasi_gyakorlatok_tananyag/RTG/RTG_video-ok/12_csuklo_oldal_en.avi
(Figure 82.)

Structures shown:

- superimposed distal radius and ulna
- superimposed proximal metacarpals and carpals

(Figures 83., 84.)

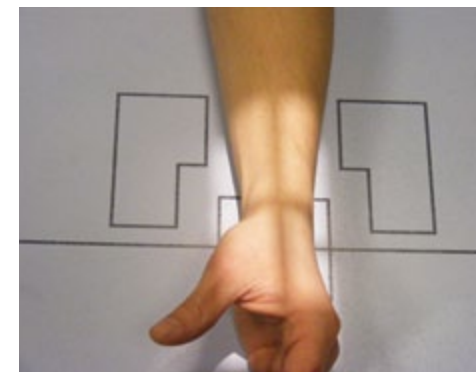


Figure 82.

Csukló oldalirányú felvétele

- a radius és az ulna distalis vége kissé egymásra vetül
- carpusok és a metacarpusok proximális vége egymásra vetül

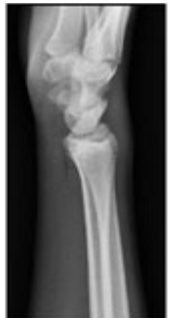

Figure 83.

Csukló oldalirányú felvétele

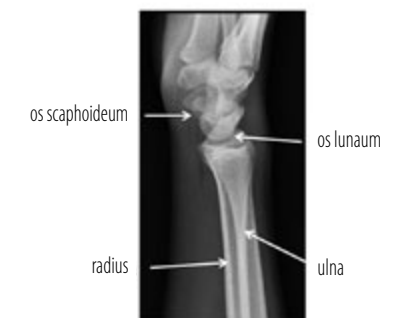

Figure 84.

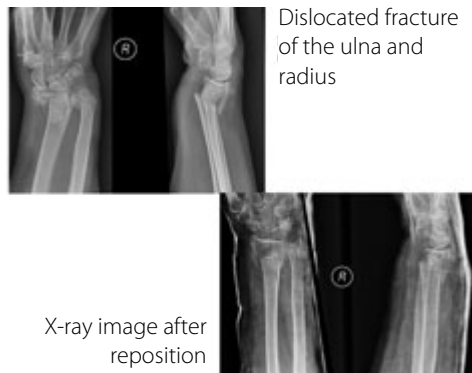


Figure 85.

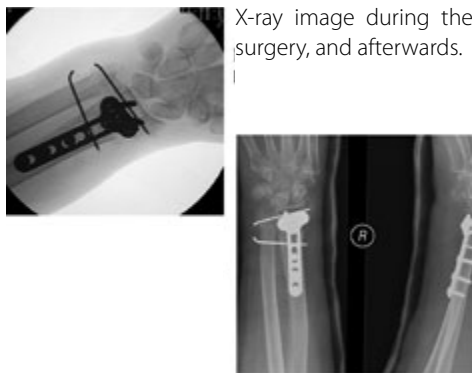


Figure 86.

Scaphoid – AP (dorso-volar)

Patient positioning: The patient is seated alongside the table, with the affected side nearest to the table. The elbow joint is flexed to 90 degrees and the arm is abducted, such that the anterior aspect of the forearm and the palm of the hand rest on the cassette. If the mobility of the patient permits, the shoulder joint should be at the same height as the forearm. The scaphoid is placed on one half of the cassette. The fingers are flexed slightly to bring the anterior aspect of the wrist into contact with the cassette. The longitudinal axis of the hand-forearm is parallel to the longitudinal axis of the detector.

Exposure borders: The upper edge is above the wrist by approx. 1 cm, and the lower edge is the bases of the metacarpals, while the lateral edges are the soft tissues.

Film or image size: 13 × 18 cm

Focus-film distance: 100 cm

Centering: to the scaphoid

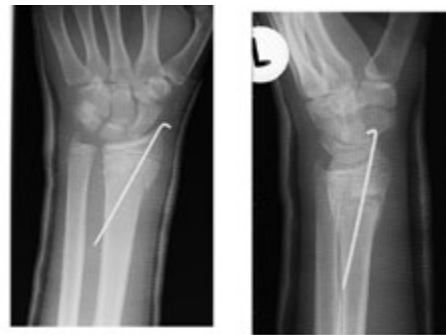

Figure 87.

Imaging technique of the scaphoid

Imaging of the carpal bones is most commonly undertaken to demonstrate the navicular. The projections may also be used to demonstrate other carpal bones, as indicated below. Four projections may be taken to demonstrate all the carpal bones.

http://tamop.etk.pte.hu/tamop412A/Ke-palkotasi_gyakorlatok_tananyag/RTG/RTG_videok/13_scaphoideum_AP_en.avi
(Figure 88.)

Scaphoid – lateral

Patient positioning: The patient is seated alongside the table, with the affected side nearest to the table. The elbow joint is flexed 90 degrees and the arm is abducted. If the mobility of the patient permits, the shoulder joint should be at the same height as the forearm. From the AP position, the hand and wrist are rotated 90 degrees internally, such that the medial (ulnar) aspect of the wrist is in contact with the cassette. The scaphoid is placed on one half of the cassette. The longitudinal axis of the hand-forearm is parallel to the longitudinal axis of the detector.

Exposure borders: The upper edge is above the wrist by approx. 1 cm, and the lower edge is the bases of the metacarpals, while the lateral edges are the soft tissues.

Film or image size: 13 × 18 cm

Focus-film distance: 100 cm

Centering: to the scaphoid

http://tamop.etk.pte.hu/tamop412A/Ke-palkotasi_gyakorlatok_tananyag/RTG/RTG_videok/14_scaphoideum_oldal_en.avi
(Figure 89.)

Scaphoid – ulnar deviation

Patient positioning: The patient is seated alongside the table, with the affected side nearest to the table. The elbow joint is flexed




Figure 88.




Figure 89.

90 degrees and the arm is abducted. The arm is extended across the table with the elbow flexed and the forearm pronated. If possible, the shoulder, elbow and wrist should be at the level of the tabletop. The hand is adducted (ulnar deviation). The longitudinal axis of the hand-forearm is parallel to the longitudinal axis of the detector.

Exposure borders: The upper edge is above the wrist by approx. 1 cm, and the lower edge is the bases of the metacarpals, while the lateral edges are the soft tissues.

Film or image size: 13 × 18 cm

Focus-film distance: 100 cm

Centering: to the scaphoid

http://tamop.etk.pte.hu/tamop412A/Ke-palkotasi_gyakorlatok_tananyag/RTG/RTG_videok/15_scaphoideum_flag_en.avi

(Figure 90.)




Figure 90.

Scaphoid – oblique (dorso-volar)

Patient positioning: The patient is seated alongside the table, with the affected side nearest to the table. The elbow joint is flexed 90 degrees and the arm is abducted. The arm is extended across the table with the elbow flexed and the forearm pronated. If possible, the shoulder, elbow and wrist should be at the level of the tabletop. The hand is rotated internally 45 degrees. The longitudinal axis of the hand-forearm is parallel to the longitudinal axis of the detector.

Exposure borders: The upper edge is above the wrist by approx. 1 cm, and the lower edge is the bases of the metacarpals, while the lateral edges are the soft tissues.




Figure 91.

Os scaphoideum négyirányú felvétele

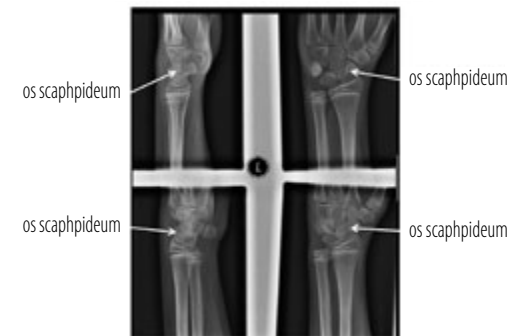

Figure 92.

Film or image size: 13 × 18 cm

Focus-film distance: 100 cm

Centering: to the scaphoid

(Figures 91., 92.)

(Figure 93.)

(Figure 94.)

(Figures 95–99. Pathologies)




Figure 93.




Figure 94.

Hand – AP

Patient positioning: Ideally, the patient is seated alongside the table. The forearm is pronated and placed on the table with the palmar surface of the hands in contact with the cassette. The fingers are separated and extended but relaxed to ensure that they remain in contact with the cassette. The longitudinal axis of the hand-forearm is parallel to the longitudinal axis of the detector.

Exposure borders: The upper edge is above the wrist by approx. 2 cm, and the lower and the lateral edges are the soft tissues.

Film or image size: 13 × 18 cm

Focus-film distance: 100 cm

Centering: to the head of the third metacarpus

<http://tamop.etk.pte.hu/tamop412A/Ke->

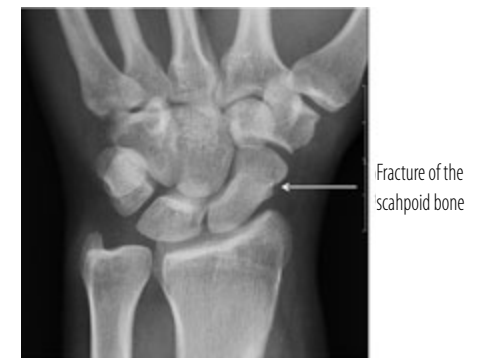

Figure 95.

Fracture of the proximal third of the scaphoid bone

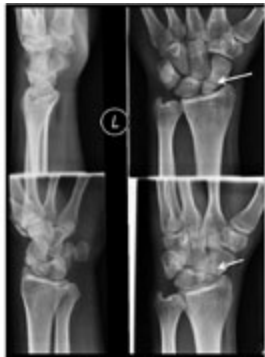

Figure 96.

Fracture of the proximal third of the scaphoid bone

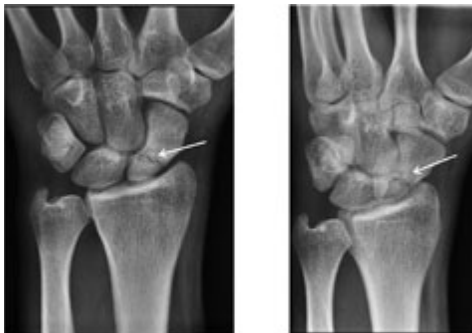

Figure 97.

palkotasi_gyakorlatok_tananyag/RTG/RTG_videok/16_scaphodeum_citera_en.avi

(Figure 100.)

Structures shown:

- no rotation of the hand
- open MCP and interphalangeal joints
- slightly separated digits with no soft tissue overlap
- all anatomy distal to the radius and ulna without rotation

(Figures 101–102.)

X-ray image of the scaphoid bone after surgery

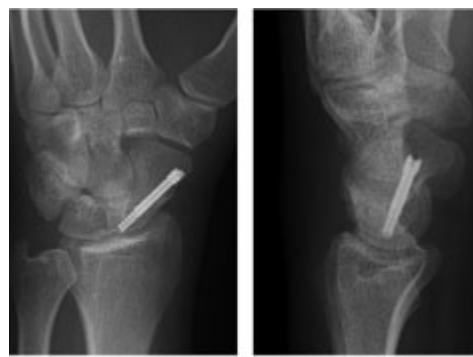

Figure 98.

X-ray image of the scaphoid bone after surgery

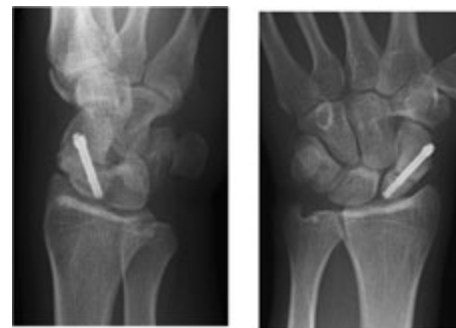

Figure 99.

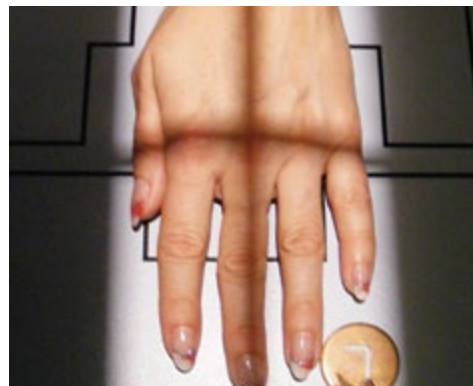

Figure 100.

Kéz AP felvétele

- az egész kéz elfordulás nélkül ábrázolódjon
- MCP és IP ízületek nyújtottak
- ujjak kissé eltávolítva
- radius és az ulna distalis vége elfordulás nélkül ábrázolódik

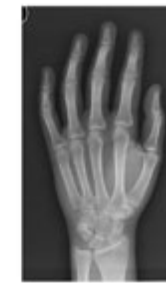

Figure 101.

Kéz PA/dorso-volaris felvétele

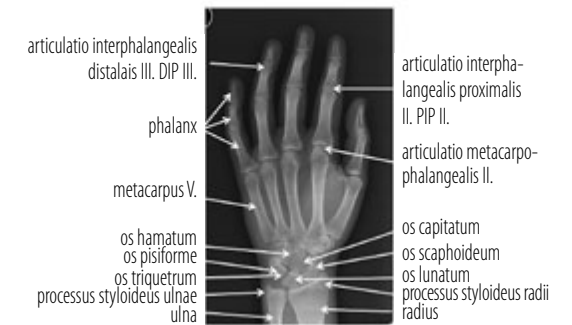


Figure 102.

Hand – oblique

Patient positioning: Ideally, the patient is seated alongside the table. From the basic AP position, the hand is externally rotated 45 degrees with the fingers extended. The fingers should be separated slightly. The longitudinal axis of the hand-forearm is parallel to the longitudinal axis of the detector.

Exposure borders: The upper edge is above the wrist by approx. 2 cm, and the lower and the lateral edges are the soft tissues.

Film or image size: 13 × 18 cm

Focus-film distance: 100 cm

Centering: to the head of the third metacarpus

http://tamop.etk.pte.hu/tamop412A/Ke-palkotasi_gyakorlatok_tananyag/RTG/RTG_videok/17_kez_AP_en.avi

(Figure 103.)

Structures shown:

- open interphalangeal and MCP joints
- digits separated slightly with no overlap of their soft tissues
- whole hand visible

(Figures 104–105.)

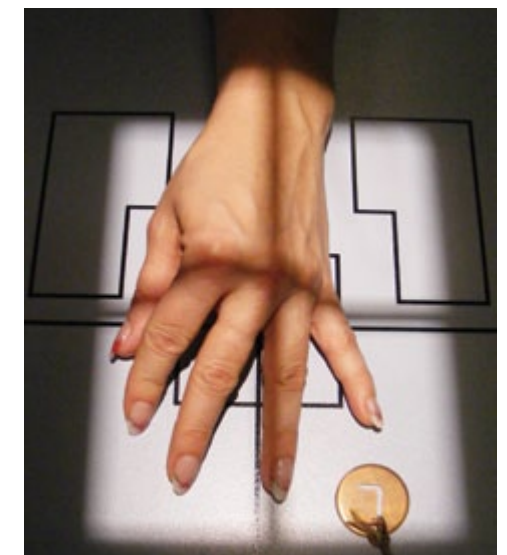


Figure 103.

Kézfelvétel citeratartásban

- egész kéz ábrázolódjon, ujjak eltávolítva
- kézcsonatok ne vetüljenek egymásra
- interphalangealis ízületi részek nyitottak

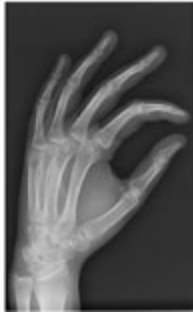

Figure 104.

For comparative technique both forearms are pronated and placed on the table with the palmar surface of the hands in contact with the cassette. The central ray is centred over a point midway between the inter-phalangeal joints of both thumbs.

(Figures 106–109.)

If you are looking for a foreign metal object in the soft tissues, you have to take the x-ray image in the lateral position, too.

(Figures 110–111.)

(Figures 112–113. Pathologies.)

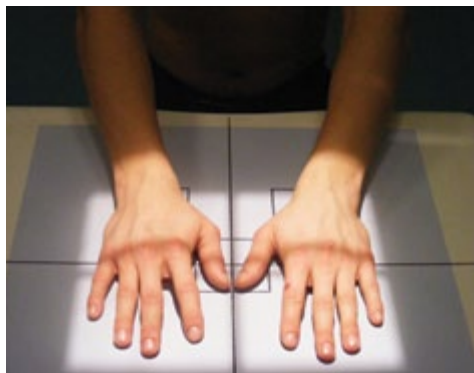

Figure 106.

Kéz felvétele citeratartásban

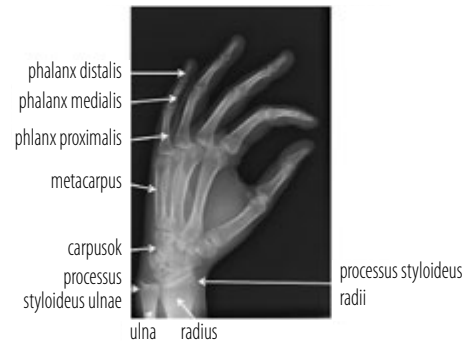

Figure 105.

Kéz AP összehasonlító felvétele

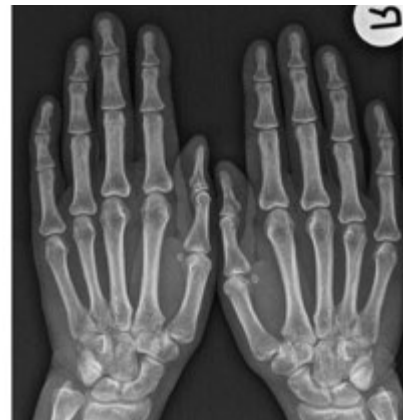

Figure 107.

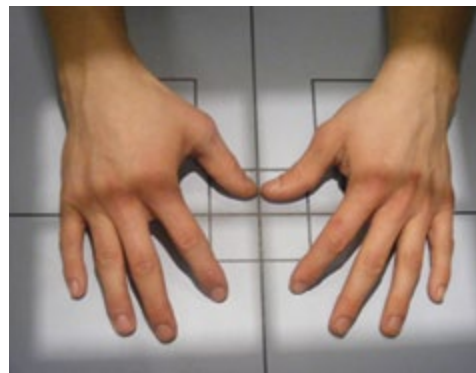

Figure 108.

Kéz összehasonlító felvétele citeratartásban

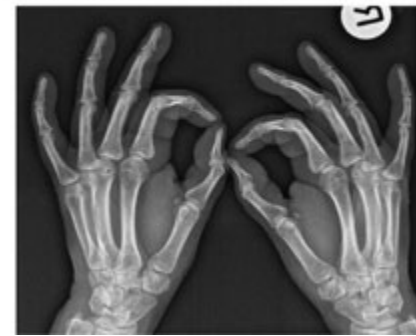

Figure 109.

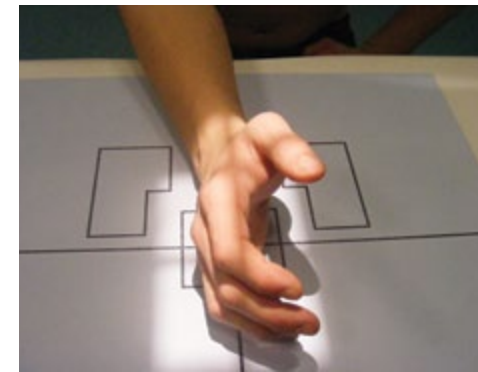


Figure 110.

Thumb – AP (volodorsal)

Patient positioning: The patient is seated alongside the table. Put the patient's hand in a position of extreme internal rotation. Have the patient hold the extended digits back with tape or the opposite hand. Rest the thumb on the cassette. If the patient is unable to pick up this position, adjust the patient's forearm in lateral position and the thumb should be supported by a pad. The longitudinal axis of the thumb is parallel to the longitudinal axis of the detector.

Kéz kétirányú felvétele teljes oldalhelyzetben, fémintenzitású idegentest keresés

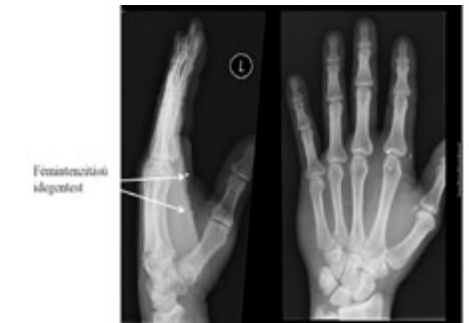

Figure 111.

Dislocated fracture of the distal end of the V. metacarpal bone

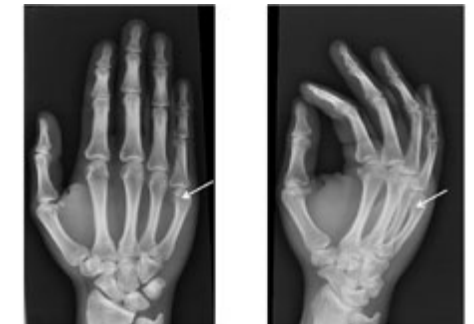

Figure 112.

Fracture of the proximal phalanx of the III. finger. The fracture line extends onto the proximal articular surface.

The dislocation is approximately 2 mm

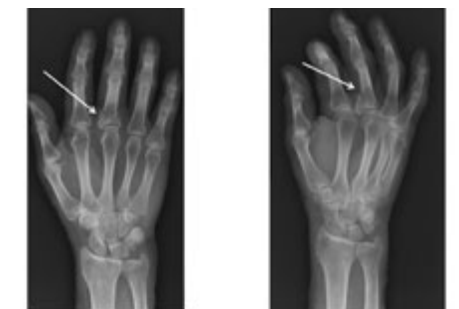

Figure 113.




Figure 114.

Exposure borders: The upper edge is below the I. metacarpal by approx. 1 cm, and the lower and the lateral edges are the soft tissues.

Film or image size: 13 × 18 cm

Focus-film distance: 100 cm

Centering: to the I. MCP joint

http://tamop.etk.pte.hu/tamop412A/Kepalkotasi_gyakorlatok_tananyag/RTG/RTG_videok/18_kez_citera_en.avi

http://tamop.etk.pte.hu/tamop412A/Kepalkotasi_gyakorlatok_tananyag/RTG/RTG_videok/19_lujj_DV_en.avi

(Figures 114–115.)

Thumb – lateral

Patient position: The patient is seated alongside the table with the arm abducted, the elbow flexed and the anterior aspect of the forearm resting on the table. The thumb is flexed slightly and the palm of the hand is placed on the cassette. The longitudinal axis of the thumb is parallel to the longitudinal axis of the detector.

Exposure borders: The upper edge is below the I. metacarpal by approx. 1 cm, and the lower and the lateral edges are the soft tissues.




Figure 115.




Figure 116.

Film or image size: 13 × 18 cm

Focus-film distance: 100 cm

Centering: to the I. MCP joint

http://tamop.etk.pte.hu/tamop412A/Kepalkotasi_gyakorlatok_tananyag/RTG/RTG_videok/20_lujj_VD_en.avi

(Figure 116.)

Structures shown:

- whole first digit in a true lateral projection
- open interphalangeal and MCP joint spaces

(Figures 117–118.)

I. ujj kétirányú felvétele

- az egész I-es ujj látszódn
- az interphalangealis és a metacarpophalangealis ízület nyújtva legyen

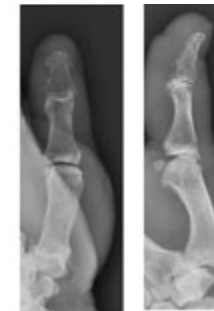

Figure 117.

I. ujj kétirányú felvétele

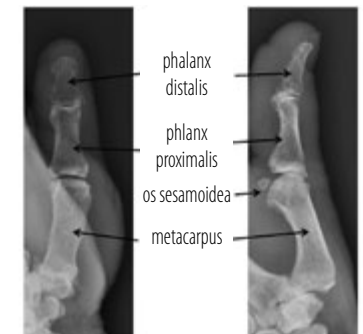

Figure 118.

Digits (II.–V.)

Patient positioning: The patient is seated alongside the table with the arm abducted, and the elbow flexed. Place the extended digit with the palmar surface down on the cassette – in case of an AP image – or in a lateral position. Separate the digits slightly, and center the digit under examination to the midline portion of the cassette.

Exposure borders: The upper edge is below the base of the I. metacarpal by approx. 1 cm, and the lower and the lateral edges are the soft tissues.

Film or image size: 13 × 18 cm

Focus-film distance: 100 cm

Centering: to the center of the digit

http://tamop.etk.pte.hu/tamop412A/Kepalkotasi_gyakorlatok_tananyag/RTG/RTG_videok/21_lujj_oldal_en.avi




Figure 119.




Figure 120.

http://tamop.etk.pte.hu/tamop412A/Ke-palkotasi_gyakorlatok_tananyag/RTG/RTG_videok/22_IIIujj_DV_en.avi

http://tamop.etk.pte.hu/tamop412A/Ke-palkotasi_gyakorlatok_tananyag/RTG/RTG_videok/23_IIIujj_oldal_en.avi

(Figure 119–121.)

(Figures 122–123. Pathologies.)

Kéz ujjak kétirányú felvétele

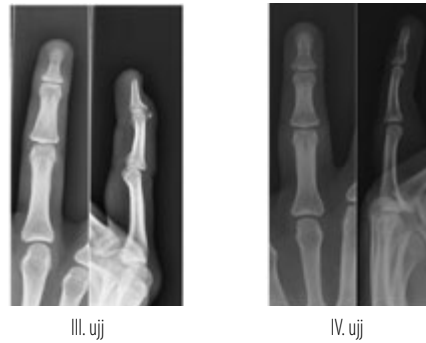


Figure 121.

Fracture of the proximal phalanx of the I. digit without any significant dislocation

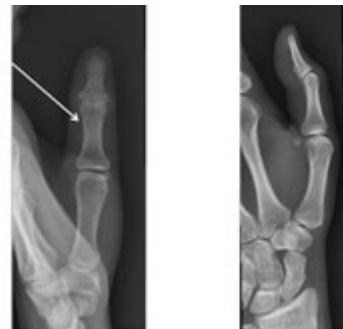

Figure 122.

Status after OS

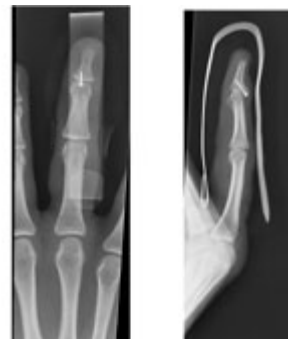

Figure 123.

III.6. X-ray anatomy and imaging technique of the pelvis and lower limb

The lower extremities consist of the pelvis and lower limbs. The pelvis serves as a base for the trunk and a girdle for the attachment of the lower limbs. The pelvis consists of four bones: two hip bones; the sacrum; and the coccyx. The pelvic girdle is composed of only the two hip bones, however. The hip bone consists of:

- the ilium (os ileum)
- the pubis (os pubis)
- the ischium (os ischii)

These three bones join together to form the acetabulum, the cup-shaped socket that receives the head of the femur. The ilium, pubis, and ischium are separated by cartilage in youth but become fused into one bone in adulthood.

The ilium consists of a body and a broad, curved portion called the ala. The body of the ilium forms approximately two fifths of the acetabulum superiorly. The ala has three borders: anterior, posterior, and superior. The anterior superior iliac spine (ASIS) is an important and frequently used radiographic positioning reference point. The superior margin extending from the ASIS to the posterior superior iliac spine is called the iliac crest. The inferior and posterior portion of the wing present a large, rough surface, the articular surface, for articulation with the sacrum.

The ischium consists of a body and the ischial ramus. The body of the ischium forms approximately two fifths of the acetabulum posteriorly. It projects posteriorly and inferiorly from the acetabulum to form an expanded portion called the ischial tuberosity. The ischial ramus projects anteriorly and medially from the tuberosity to its junction with the inferior ramus of the pubis. By this posterior union the rami of the pubis and ischium enclose the obturator foramen.

The pubis consists of a body, the superior ramus, and the inferior ramus. The body of the pubis forms approximately one fifth of the acetabulum anteriorly. The conjunction of the two pubis bones is called the symphysis.

The proximal end of the femur consists of a head, a neck, and two large processes: the greater and lesser trochanters. The smooth, rounded head is connected to the femoral body by a pyramid-shaped neck and is received into the acetabular cavity of the hip bone.

The femur is the longest, strongest, and heaviest bone in the body. The superior portion of the femur articulates with the acetabulum of the hip joint. The distal end of the femur is broadened and has two large eminences: the larger medial condyle and the smaller lateral condyle. Posteriorly the condyles are separated by a deep depression called the intercondylar fossa.

The tibia is the larger of the two bones of the leg and consists of one body and two expanded extremities. The proximal end of the tibia has two prominent processes – the medial and lateral condyles.

Between the two articular surfaces is a sharp projection, the intercondylar eminence. The superior surfaces of the condyles form smooth facets for articulation with the condyles of the femur. The lateral condyle has a facet at its distal posterior surface for articulation with the head of the fibula. On the anterior surface of the tibia, just below the condyles, is a prominent process called the tibial tuberosity.

The patella is a flat, triangular bone situated at the distal anterior surface of the femur. The apex, or tip, is directed inferiorly, lies above the joint space of the knee, and is attached to the tuberosity of the tibia by the patellar ligament. Interestingly, the superior border of the patella is called the base.

The leg has two bones: the tibia and fibula. The tibia, the second largest bone in the body, is situated on the medial side of the leg. Slightly posterior to the tibia on the lateral side of the leg is the fibula.

The distal end of the tibia is broad, and its medial surface is prolonged into a large process called the medial malleolus. Its anterolateral surface contains the anterior tubercle, which overlays the fibula. The enlarged distal end of the fibula is the lateral malleolus. The lateral malleolus is pyramidal and marked by several depressions at its inferior and posterior surfaces.

The region that is bordered by the dorsal contour of the fibula and the dorsal end of the tibia is called the Volkmann triangle.

For descriptive purposes the foot is sometimes divided into the forefoot, midfoot, and hindfoot. The forefoot includes the metatarsals and toes. The midfoot includes five tarsals – the cuneiforms, navicular, and cuboid bones. The hindfoot includes the talus and calcaneus. The bones of the foot are shaped and joined together to form a series of longitudinal and transverse arches. The longitudinal arch (tuber calcanei – condylar metatarsals) functions as a shock absorber to distribute the weight of the body in all directions, which permits smooth walking. The transverse arch (scaphoid – metatarsus basis) runs from side to side and assist in supporting the longitudinal arch.

The foot consists of phalanges (bones of the toes), metatarsals (bones of the instep) and tarsals (bone of the ankle).

The calcaneus is the largest and strongest tarsal bone. It projects posteriorly and medially at the distal part of the foot. It has two parts: tuberosity and body.

The proximal foot contains seven tarsal bones: calcaneus, talus, navicular, cuboid, medial cuneiform, intermediate cuneiform, lateral cuneiform.

The talus articulates with the navicular bone and the calcaneus articulates with the cuboid; together these form Chopart's joint.

The joints between the tarsal and metatarsal bones are the tarso-metatarsal joints; together they form the Lisfranc joint.

Both Chopart's and the Lisfranc joint have surgical significance.

Each foot has 14 phalanges - two in the great toe and three in each of the other toes. The phalanges of the great toe are termed the distal and proximal phalanges. Those of the other toes are termed the proximal, middle, and distal phalanges. Each phalanx is composed of a body and two expanded articular ends - the proximal base and the distal head.

Beneath the head of the first metatarsal are two small bones called sesamoid bones.

Surface anatomy of the hip: The hip joint can be located by palpating the ASIS and the superior margin of the pubic symphysis. The pubic symphysis can be palpated on the midsagittal plane and on the same horizontal plane as the greater trochanters. The greater trochanter is most prominent laterally and more easily palpated when the lower leg is medially rotated in slim patients.

Indications:

Trauma (fractures, luxation etc.), rheumatologic diseases, orthopedic diseases, before surgery for planning and after surgery, for control.

Pelvis – AP

Patient positioning: The patient lies supine and symmetrical on the X-ray table, with the median sagittal plane perpendicular to the tabletop. Unless contraindicated by trauma or any pathologic factors, rotate the feet and lower limbs about 15 degrees medially to place the femoral necks parallel to the plane of the cassette and to project it without shortening.

Exposure borders: The upper edge is above the iliac crest by approx. 2 cm, and the lower edge is below the symphysis by approx. 4 cm, while the lateral edges are the soft tissues.

Film or image size: 30 × 40 cm

Focus-film distance: 100 cm

Centering: to midway between the upper border of the symphysis pubis and anterior superior iliac spine

Patient Instructions: breath hold

http://tamop.etk.pte.hu/tamop412A/Kepalkotasi_gyakorlatok_tananyag/RTG/RTG_video/24_medence_en.avi

(Figures 124., 125.)

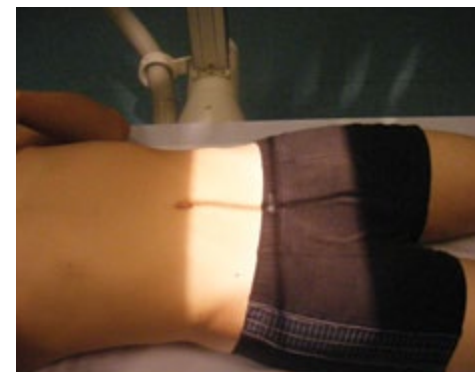

Figure 124.

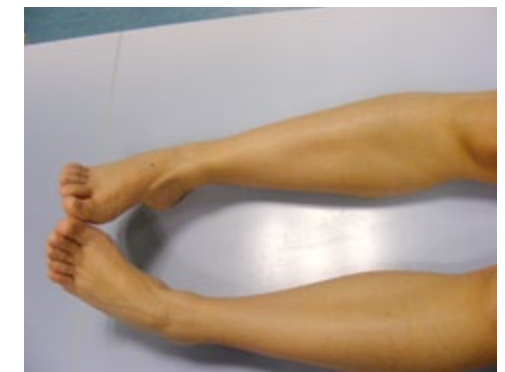

Figure 125.

If necessary, you can take an x-ray image in a standing position.

Figure 126.

Structures shown:

- entire pelvis without rotation
- apex of the lesser trochanters demonstrated on the medial border of the femurs
- femoral necks in their full extent without superimposition
- greater trochanters in profile
- symmetric obturator foramina
- L.V. spine fully demonstrated; L.IV. partially demonstrated

(Figures 127., 128.)

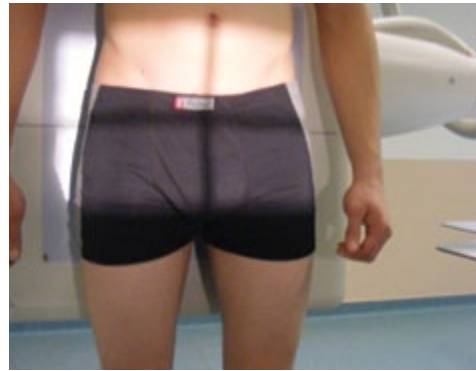

Figure 126.

Medence AP felvétele

- az egész medence és a femur proximális része is látható
- a medence nem fordult el
- a foramen obturatorumok szimmetrikusak
- a trochanter maior mindkét oldalon kivétel, azonos méretűnek ábrázolódnak
- mindkét combnyak rövidülés nélkül ábrázolódnak
- a trochanter minorak csak a csúcsa látható (ellenkező esetben elégtelen a végtag befördítése)
- L.V. csigolya egészében az L.IV. részben ábrázolódnak

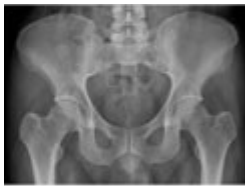

Figure 127.

Medence AP felvétele

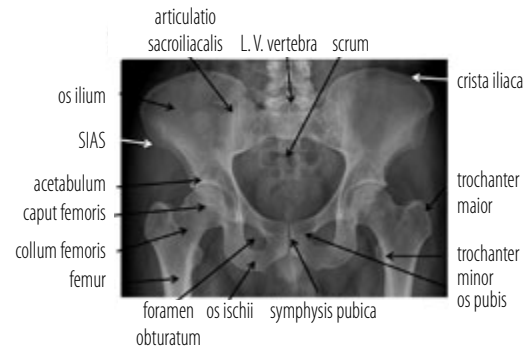


Figure 128.

Pelvis – inlet-outlet

In case of trauma, if the result of the clinical examination and the AP x-ray image indicate it, (posterior or anterior brim fracture with a large dislocation) inlet and outlet views can be made. These images are made by the patient positioned as in AP of pelvis with the x-ray tube angled 45 degrees cephalad.

(Figure 129.)

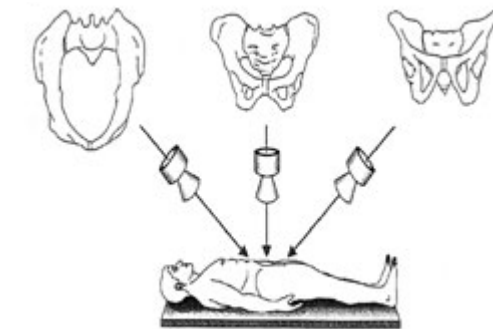


Figure 129.

Exposure borders: The upper edge is above the iliac crest by approx. 2 cm, and the lower edge is below the symphysis by approx. 4 cm, while the lateral edges are the soft tissues.

Film or image size: 30 × 40 cm

Focus-film distance: 100 cm

Centering: cranio-caudal ray angle of 45 degrees (inlet) and caudo-cranial ray angle of 45 degrees (outlet) to the midpoint between the upper border of the symphysis pubis and anterior superior iliac spine

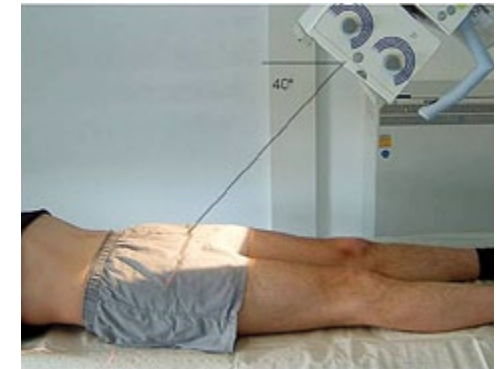


Figure 132.

Outlet felvétel

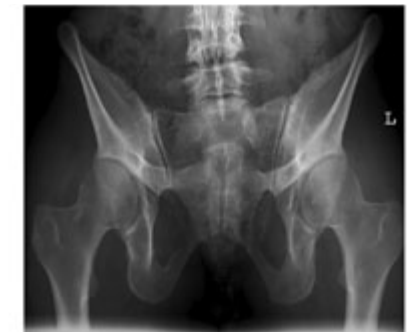

Figure 133.

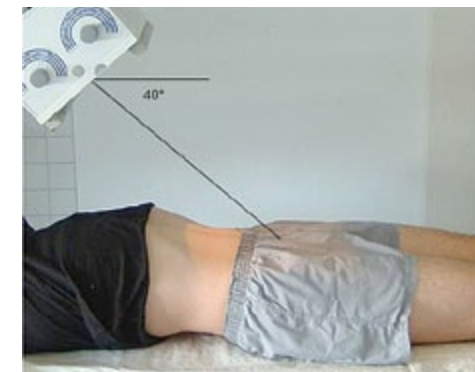


Figure 130.

Inlet felvétel

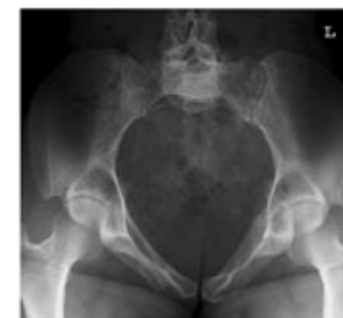

Figure 131.

Fracture of the right lateral mass of the sacrum and right pubis (inlet-outlet images)

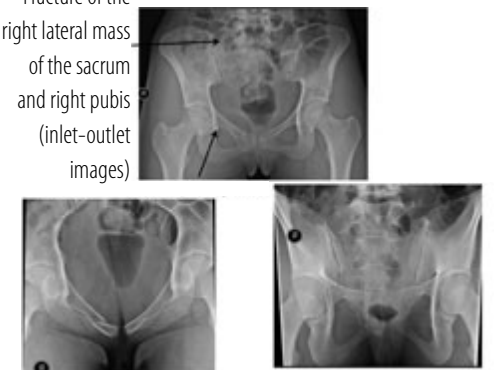


Figure 134.

Patient Instructions: breath hold
(Figures 130., 133.)
(Figures 134., 135. Pathologies)

Both hip – AP

Patient positioning: The patient lies supine and symmetrical on the X-ray table, with the median sagittal plane perpendicular to the tabletop. Unless contraindicated because of trauma or any pathologic factors, rotate the feet and lower limbs about 15 degrees medially to place the femoral necks parallel with the plane of the cassette and to project it without shortening.

Exposure borders: The upper edge is the ASIS, and the lower edge is below the symphysis by approx. 4 cm, while the lateral edges are the soft tissues.

Film or image size: 30 × 40 cm

Focus-film distance: 100 cm

Centering: above the symphysis by approx. 2 cm

Patient Instructions: breath hold
(Figure 136.)

Control
image
after
surgery.

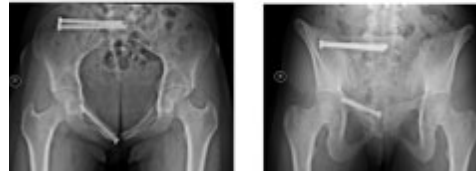
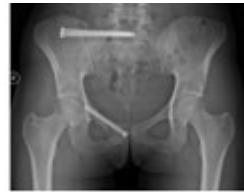
Figure 135.

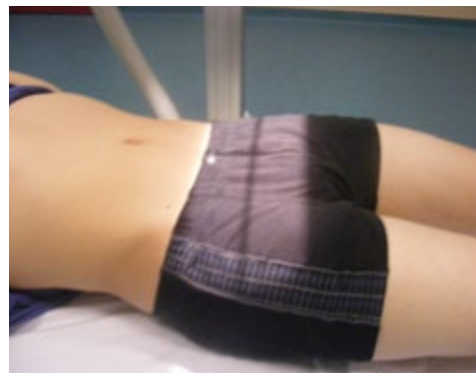

Figure 136.

Mindkét csípőízület AP felvétele

- a csípőízületek és a foramen obturatorumok szimmetrikusak
- a trochanter maior mindkét oldalon kivételül, azonos méretűnek ábrázolódnak
- mindkét combnyak rövidülés nélkül ábrázolódnak
- a trochanter minornak csak a csúcsa látható (ellenkező esetben elégtelen a végtag befördítése)

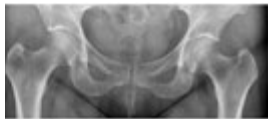


Figure 137.

Csípőízület összehasonlító felvétele

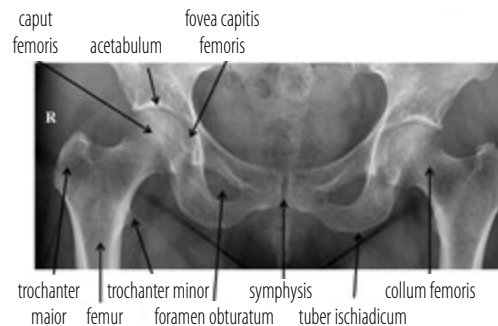


Figure 138.

Structures shown:

- apex of the lesser trochanters are visible on the medial border of the femurs
- femoral necks in their full extent without superimposition
- symmetric obturator foramina and hips
(Figures 137., 138.)

Hip – AP

Patient positioning: The patient lies supine and symmetrical on the X-ray table, with the median sagittal plane perpendicular to the tabletop. Unless contraindicated because of trauma or any other pathologic factor, rotate the feet and lower limbs about 15 degrees medially to place the femoral necks parallel with the plane of the cassette and to project it without shortening.

Exposure borders: The upper edge is the ASIS, and the lower edge is below the symphysis by approx. 4 cm, while the lateral edges are the soft tissue.

Film or image size: 24 × 30 cm

Focus-film distance: 110 cm

Centering: to the midpoint between the symphysis pubis and ASIS

http://tamop.etk.pte.hu/tamop412A/Ke-palkotasi_gyakorlatok_tananyag/RTG/RTG_videok/25_csipo_AP_en.avi

(Figure 139.)

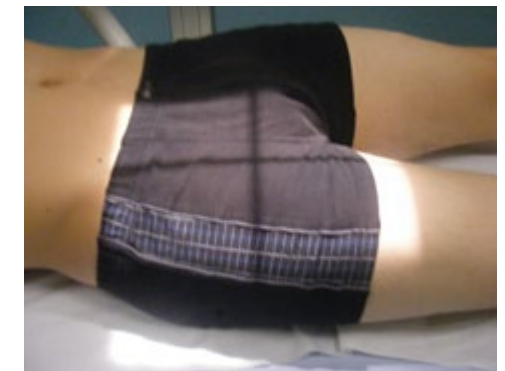

Figure 139.

Csípőízület AP felvétele

- csípőízület teljes egészében ábrázolódnak
- combnyak rövidülés nélkül ábrázolódnak
- trochanter minor ne látszódjon

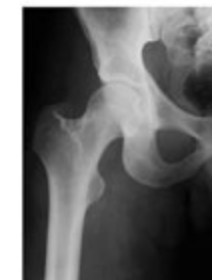

Figure 140.

Csípőízület AP felvétele

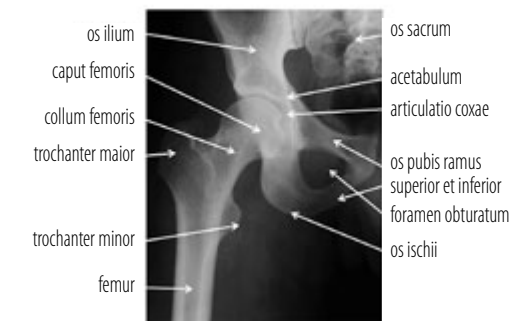


Figure 141.

Structures shown:

- lesser trochanter is usually not projected
 - entire long axis of the femoral neck not foreshortened
- (Figures 140., 141.)

If the patient has a prosthesis, it should be entirely visible on the picture.

(Figure 142.)

(Figures 143–146. Pathologies)

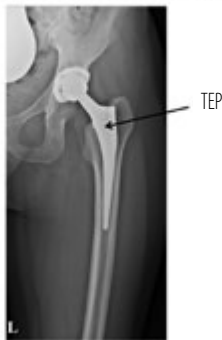Csípőízület AP felvétele TEP beültetése után

Figure 142.

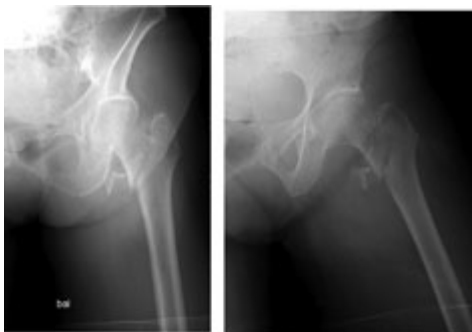Pretrochanter fracture of the femur

Figure 143.

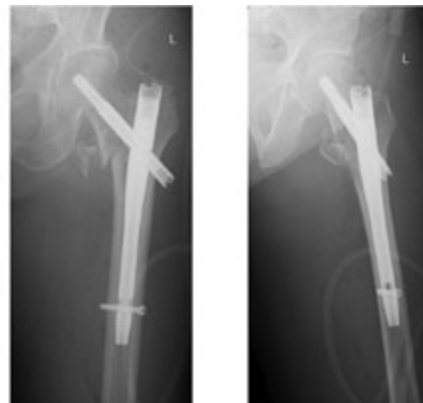Pretrochanter fracture of the femur after surgery

Figure 144.

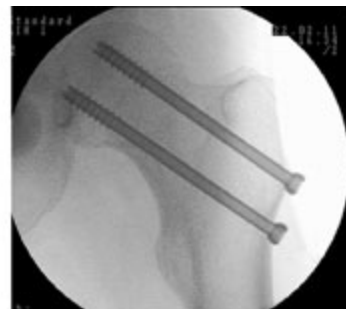X-ray image of the femur neck during operation

Figure 145.

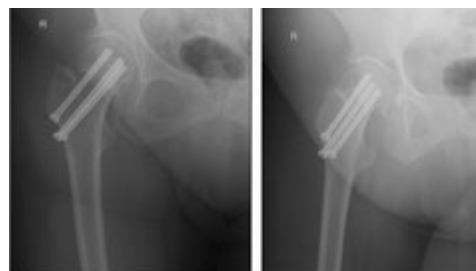X-ray image of the femur neck after surgery

Figure 146.

Hip – lateral (lauenstein)

Patient positioning: The patient lies supine on the X-ray table, with the legs extended. The median sagittal plane coincides with the long axis of the table. The patient rotates 45 degrees on to the affected side, with the hip abducted 45 degrees and flexed 45 degrees. The knee is flexed to bring the lateral aspect of the thigh into contact with the tabletop. The knee falls into a lateral position. The opposite limb is raised and supported behind the limb being examined.

Exposure borders: The upper edge is the ASIS, and the lower edge is below the symphysis by approx. 4 cm, while the lateral edges are the soft tissues.

Film or image size: 24 × 30 cm

Focus-film distance: 110 cm

Centering: to the midpoint between the symphysis pubis and ASIS

http://tamop.etk.pte.hu/tamop412A/Kepalkotasi_gyakorlatok_tananyag/RTG/RTG_video/26_csipo_axialis_en.avi

(Figure 147.)

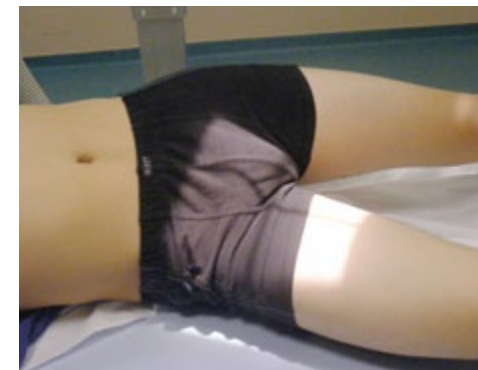

Figure 147.

Csípőízület oldalirányú felvétele Lauenstein szerintaa

- a collum femoris a kép közepén legyen
- a femur proximális harmada is megítélhető legyen
- a csípőízület teljes egészében látható

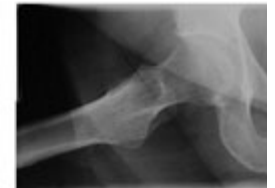

Figure 148.

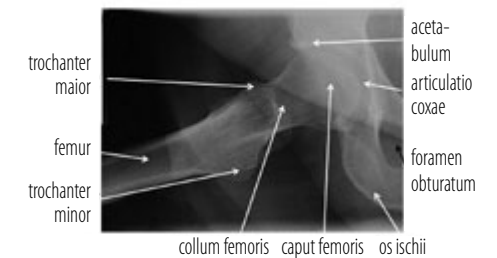
Csípőízület oldalirányú felvétele

Figure 149.

Structures shown:

- hip joint and the proximal third of the femur are fully demonstrated
- femoral neck centered to the cassette

If the patient has a prosthesis, it should be entirely visible on the picture.

(Figures 148., 149.)

Both hip – lateral (Lauenstein)

Patient positioning: The patient lies supine on the X-ray table, with the anterior superior iliac spines equidistant from the tabletop to avoid rotation of the pelvis. The median sagittal plane is perpendicular to the table. The hips and knees are flexed and the limbs rotated laterally approximately 60 degrees. This movement separates the knees and brings the plantar aspect of the feet in contact with each other.

Exposure borders: The upper edge is the ASIS, and the lower edge is below the symphysis by approx. 4 cm, while the lateral edges are the soft tissues.

Film or image size: 30 × 40 cm

Focus-film distance: 100 cm

Centering: above the symphysis by approx. 2 cm

http://tamop.etk.pte.hu/tamop412A/Kepalkotasi_gyakorlatok_tananyag/RTG/RTG_video/27_OHlauenstein_en.avi

(Figure 150.)

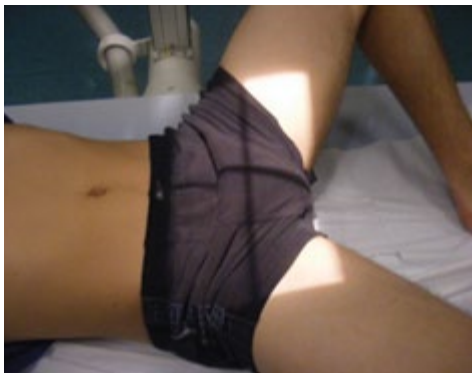

Figure 150.

Structures shown:

- the two femoral necks are in the middle of the picture and they are symmetrical.

(Figures 151., 152.)

Hip – axial

Patient positioning: The patient lies supine on the stretcher or X-ray table. The

Mindkét csípőizület oldalirányú, összehasonlító felvétele Lauenstein szerint

- a két collum femoris a kép közepén legyen szimmetrikusan

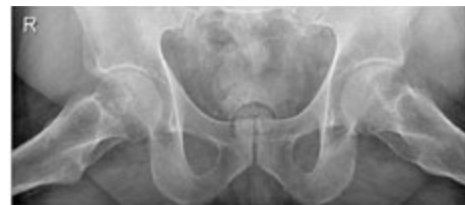

Figure 151.

Mindkét csípőizület oldalirányú felvétele Lauenstein

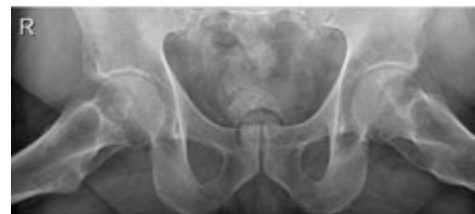

Figure 152.

legs are extended and the pelvis adjusted to make the median sagittal plane perpendicular to the tabletop. The grid cassette is positioned vertically, with the shorter edge pressed firmly against the waist, just above the iliac crest. The longitudinal axis of the cassette should be parallel to the neck of femur. This can be approximated by placing a 45-degree foam pad between the front of the cassette and the lateral aspect of the pelvis. The cassette is supported in this position by sandbags or a special cassette holder attached to the table. The unaffected limb is then raised until the thigh is vertical, with the knee flexed. This position is maintained by supporting the lower leg on a stool or specialized equipment.

Adjust the pelvis so that it is not rotated.

Exposure borders: The upper edge is the ASIS, and the lower edge is the proximal third of the femur, while the lateral edges are the soft tissues.

Film or image size: 30 × 40 cm

Focus-film distance: 100 cm

Centering: to the femoral neck

(Figure 153.)

Structures shown:

- small amount of the lesser trochanter on the posterior surface of the femur (with the proximal femur)
- hip joint with the acetabulum fully demonstrated

(Figures 154., 155.)

Csípőizület axialis felvétele Sven-Johanson szerint

- a teljes csípőizület ábrázolódjon (a femur proximális régiója is)
- a combnyak a felvétel közepén legyen és a trochanter maior csak kissé vetüljön rá

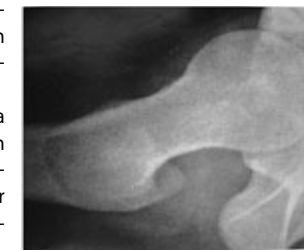


Figure 154.

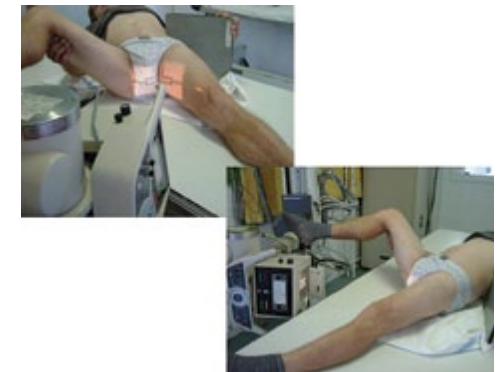


Figure 153.

Csípőizület axialis felvétele Sven-Johanson szerint

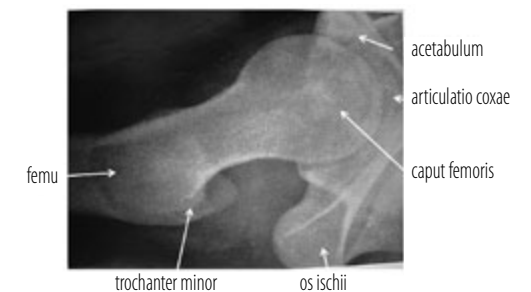

Figure 155.

Foramen obturatum

Patient positioning: The patient lies supine on the X-ray table, with the legs extended. The median sagittal plane coincides with the long axis of the table. The patient rotates 45 degrees on to the affected side. The knee is slightly flexed.

Exposure borders: The upper edge is the ASIS, and the lower edge is below the symphysis by approx. 4 cm, while the lateral edges are the soft tissues.

Film or image size: 24 × 30 cm

Focus-film distance: 110 cm

Centering: to the midpoint between the symphysis pubis and ASIS
(Figure 156.)

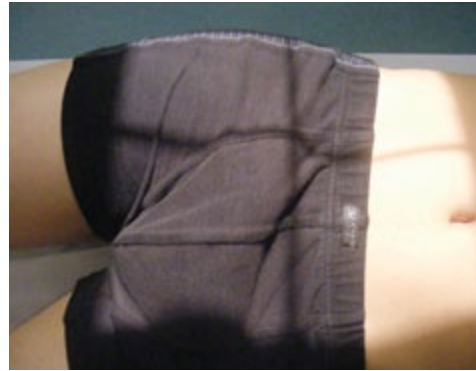

Figure 156.

Structures shown:

- front rim of the acetabulum demonstrated
- femoral head and femoral neck well visualized

(Figures 157–158.)

Foramen obturatum felvétél

- az acetabulum elülső pereme ábrázolódik
- femurfej, combnyak is jól ábrázolódik

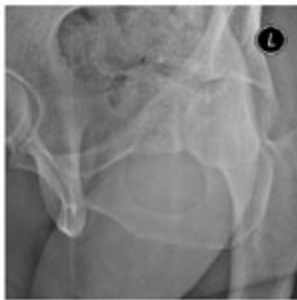

Figure 157.

Foramen obturatum felvétél

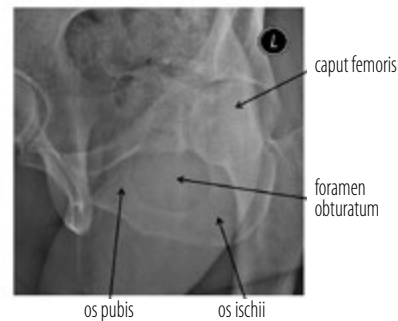


Figure 158.

ALA (iliac)

Patient positioning: The patient lies supine on the X-ray table and is positioned for a basic AP pelvic projection. From this position, the patient is rotated approximately 45 degrees on to the affected side; the unaffected side is raised and supported. Both hips and knees are flexed and the raised limb is supported on a pad. The ASISs are parallel to the cassette.

Exposure borders: The upper edge is the ASIS, and the lower edge is below the symphysis by approx. 4 cm, while the lateral edges are the soft tissues.

Film or image size: 24 × 30 cm

Focus-film distance: 110 cm

Centering: to the center of the iliac bone
(Figure 159.)

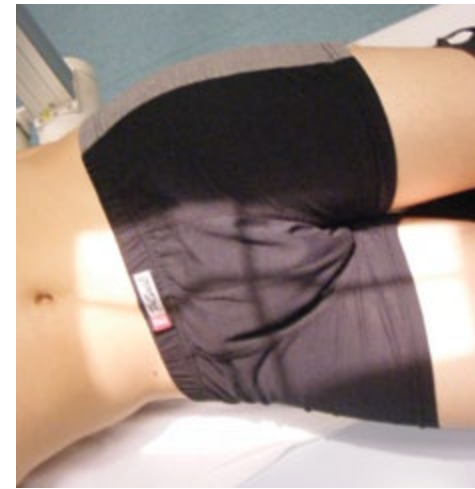


Figure 159.

Structures shown:

- the iliac bone fully demonstrated
(Figures 160–161.)

Femur – AP

Patient positioning: The patient lies supine on the X-ray table, with both legs extended. The cassette is positioned in the Bucky tray immediately under the limb. Center the affected thigh to the midline of the cassette. When the patient is too tall to include the entire femur, include the joint closest to the area of interest on one image.

Exposure borders: With the hip included: The upper edge is the ASIS, and the lower edge is the proximal two-thirds of the femur, while the lateral edges are the soft tissues. With the knee included: the upper edge is the proximal two-thirds of the femur, and the lower edge is the proximal third of the tibia, while the lateral edges are the soft tissues.

Ala felvétél

- a csípőlapát egészében ábrázolódjon

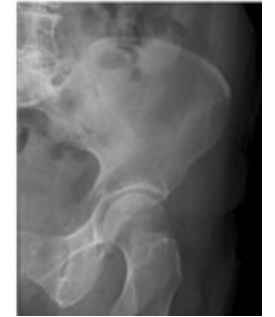

Figure 160.

Ala felvétél

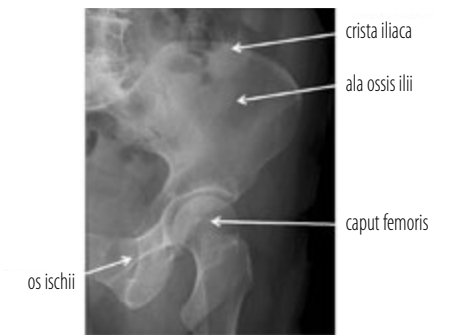


Figure 161.

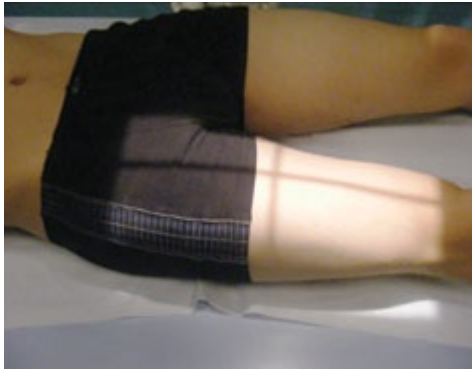


Figure 162.

Film or image size: 15 × 40 cm

Focus-film distance: 100 cm

Centering: to the center of the detector
(Figures 162., 163.)

Structures shown:

- majority of the femur and the joint nearest to the pathologic condition or site of injury
- femoral neck not foreshortened on the proximal femur
- patella completely superimposed on the femur, no rotation of the femur and tibia
(Figures 164–166.)

Combcson AP felvétele

- a teljes femur ábrázolódjon a vizsgálandó terület-hoz közelebbi ízülettel
- aha a csípőizület van a felvételen: csípőizület teljes egészében, combnyak rövidülés nélkül ábrázolódik, trochanter minor ne látszódjon
- térdizület esetén a patella a femorra vetül, tibia proximalis fele részben a fibulafejcsre

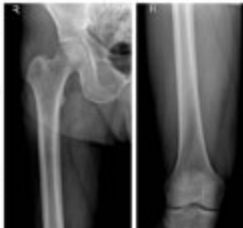

Figure 164.

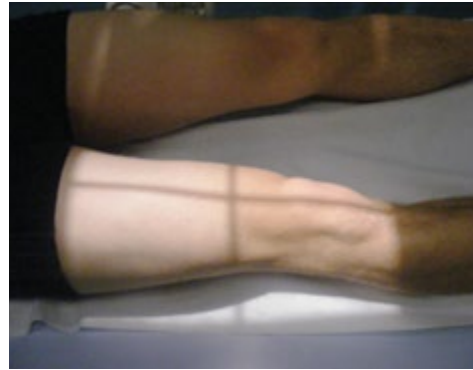

Figure 163.

Femur AP felvétele a csípőizülettel

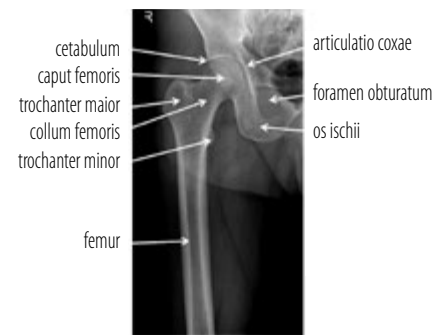


Figure 165.

Femur AP felvétele a térdizülettel

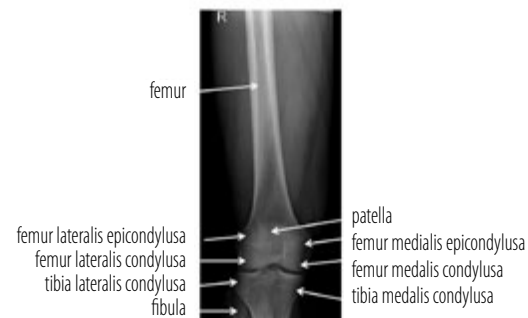

Figure 166.

Femur – lateral

Patient positioning (with the hip included): From the antero-posterior supine position, the patient's hip rotated on to the affected side, and the knee is slightly flexed. The pelvis is rotated backwards to separate the thighs. The position of the limb is then adjusted to vertically superimpose the femoral condyles.

Exposure borders: The upper edge is the ASIS, and the lower edge is the distal third of the femur, while the lateral edges are the soft tissues.

Film or image size: 15 × 40 cm

Focus-film distance: 100 cm

Centering: to the center of the detector
(Figure 167.)

Patient positioning (with the knee included): From the antero-posterior supine position, the patient rotates on to the affected side, and the knee is flexed 45 degrees. The femur's longitudinal axis is in the center of the cassette.

Exposure borders: The upper edge is the proximal third of the femur, and the lower edge is the proximal third of the tibia, while the lateral edges are the soft tissues.

Film or image size: 15 × 40 cm

Focus-film distance: 100 cm

Centering: to the center of the detector
(Figure 168.)

Structures shown:

- contralateral limb superimposed on the femur

With hip joint included:

- the hip joint and the femoral neck fully demonstrated

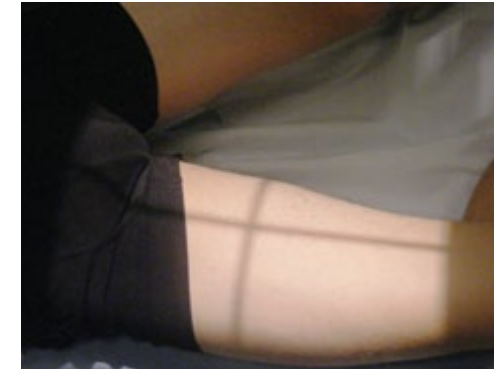

Figure 167.

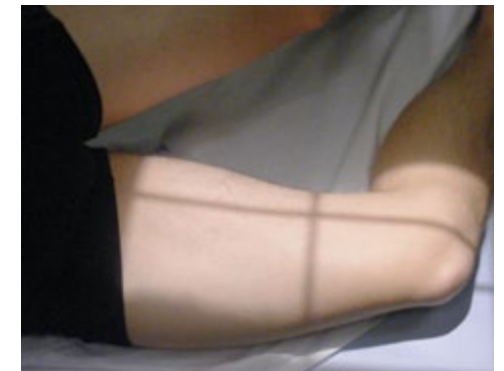

Figure 168.

Combcson oldalirányú felvétele

- ellenoldali végtag nem vetül a combsontra
- Csípőizület ábrázolása esetén: a csípőizület és a collum femoris teljes egészében látható

Térdizület ábrázolása esetén

- a femur condylusai egymásra vetülnek, a patella oldalirányban látható, a femoropatellaris ízületi rész szabad

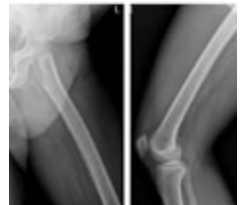

Figure 169.

Femur oldalirányú felvétele a csípőízülettel

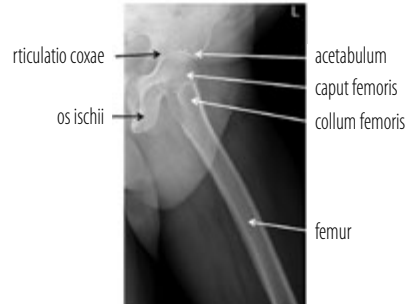


Figure 170.

Femur AP felvétele a térdízülettel

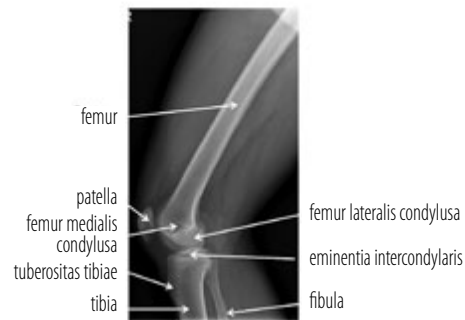


Figure 171.

With knee joint included:

- superimposed anterior surface of the femoral condyles
- patella in profile
- open patellofemoral space

(Figures 169–171.)

Knee – AP

Patient positioning: The patient is either supine or is standing (weight-bearing), with both legs extended. The affected limb is rotated to centralize the patella between the femoral condyles. The longitudinal axis of the limb is in the center of the detector.

Exposure borders: The upper edge is the distal third of the femur, and the lower edge is the proximal third of the tibia, while the lateral edges are the soft tissues.

Film or image size: 18 × 24 cm

Focus-film distance: 100 cm

Centering: inferior to the patellar apex

http://tamop.etk.pte.hu/tamop412A/Kepalkotasi_gyakorlatok_tananyag/RTG/RTG_videoek/28_terd_AP_en.avi

(Figure 172.)

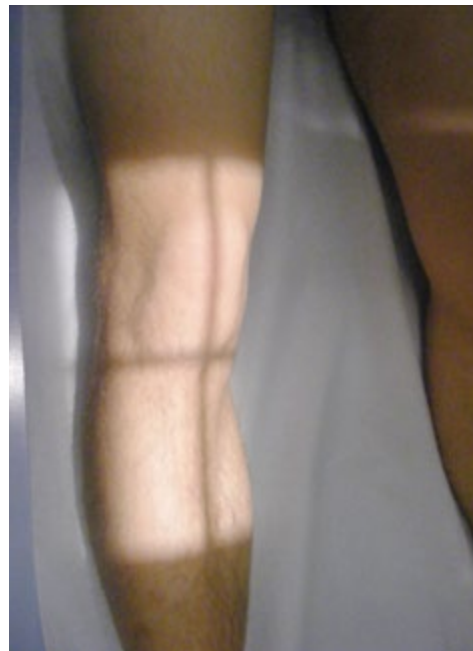

Figure 172.

Térdízület AP felvétele

- térdízület elfordulása nélkül ábrázolódik
- patella a femorra vetül
- tibia proximalis vége részben a fibula fejecsre vetül

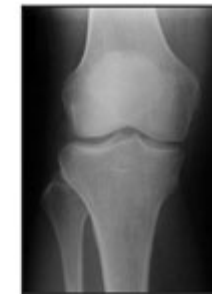

Figure 173.

AP térd felvétel

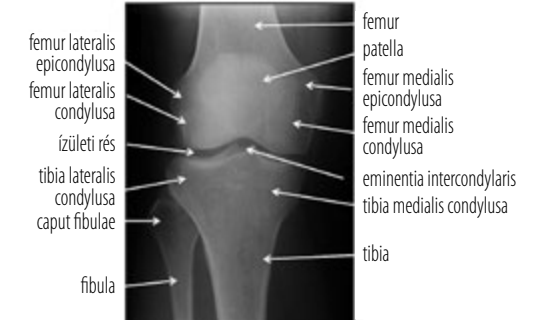


Figure 174.

Structures shown:

- patella completely superimposed on the femur
- knee joint without rotation
- the proximal end of the tibia slightly superimposed on the fibular head

(Figures 173–174.)

Knee – lateral

Patient positioning: The patient lies on the side to be examined, with the knee flexed at 45 degrees, while he extends the other limb behind it. The other limb may also be placed in front of the affected knee on a support block. The longitudinal axis of the femur is in the center of the detector.

Exposure borders: The upper edge is the distal third of the femur, and the lower edge is the proximal third of the tibia, while the lateral edges are the soft tissues.

Film or image size: 18x24 cm

Focus-film distance: 100 cm

Centering: inferior to the patellar apex

http://tamop.etk.pte.hu/tamop412A/Kepalkotasi_gyakorlatok_tananyag/RTG/RTG_videoek/29_terd_oldal_en.avi

(Figure 175.)

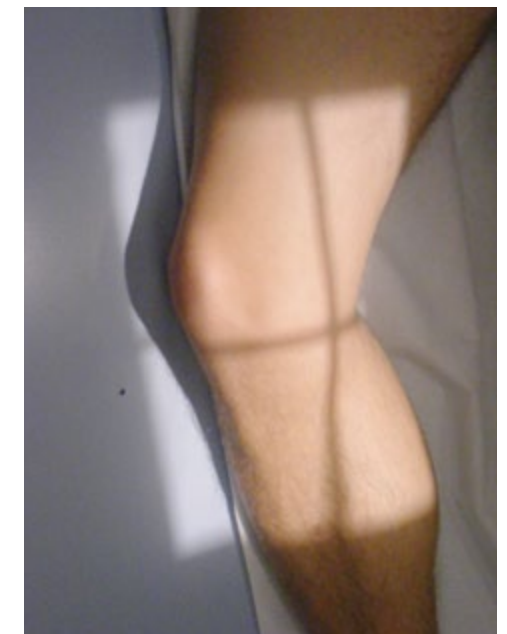

Figure 175.

Térdízület oldalirányú felvétele

- térdízület oldalnézetben ábrázolódik, femur condylusok egymásra vetülnek
- patella oldalirányban látható
- femoropatellaris ízületi rész jól ábrázolódik
- tibia proximalis része kissé rávetül s fibulafejecse

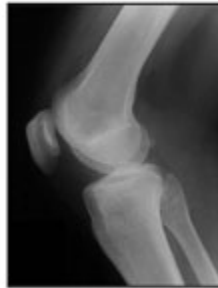

Figure 176.

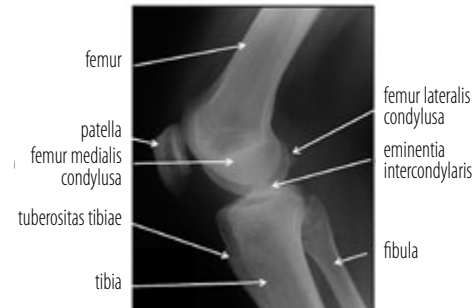
Oldalirányú térd felvétel

Figure 177.

Structures shown:

- femoral condyles superimposed
- open joint space between femoral condyles and tibia
- patella in a lateral profile
- fibular head and tibia slightly superimposed

(Figures 176–177.)

(Figures 178–181. Pathologies)

For comparison images, the two knees have to be symmetrically placed on the detector. Centering is at the height of the knee joint at the center of the detector. It is important to use an xray marker.

(Figures 182–184.)

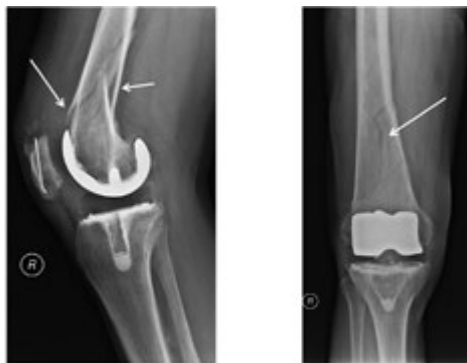Status after prosthesis implantation. Fracture of the distal metaphysis of the femur. Patellar fracture stabilized by a nail

Figure 178.

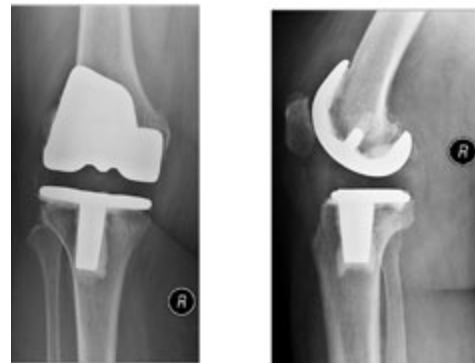X-ray image of the knee in two direction, after surgery

Figure 179.

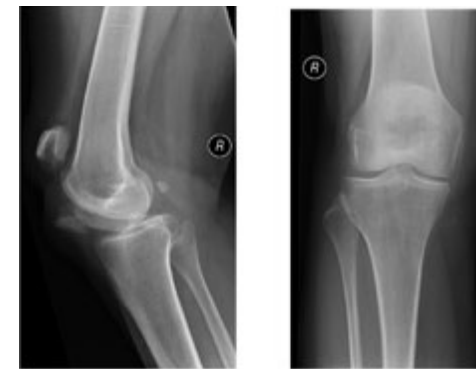Dislocated fracture of the middle third of the patella

Figure 180.

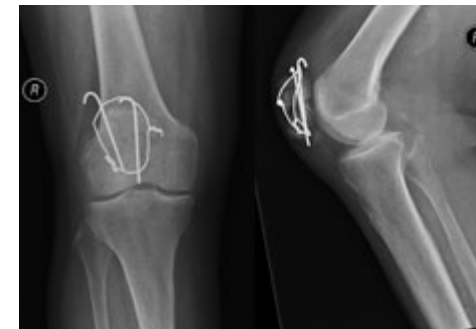X-ray image of the knee after patellar surgery

Figure 181.

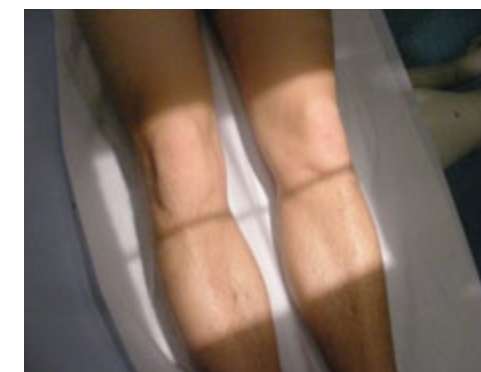

Figure 182.

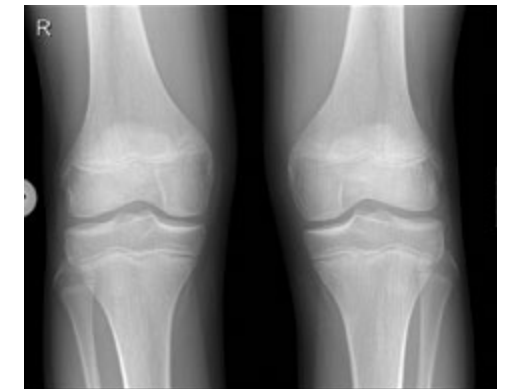
Összehasonlító AP térd felvétel

Figure 183.

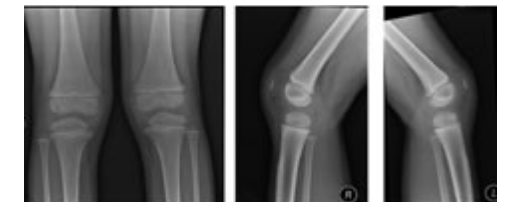Gyermek összehasonlító térd felvétel

Figure 184.

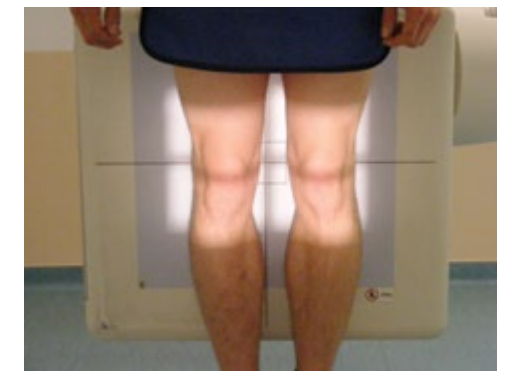

Figure 185.

At the clinician's request, we can take images of one or both knees in a weight-bearing (stress-loading) position.

(Figures 185–187.)

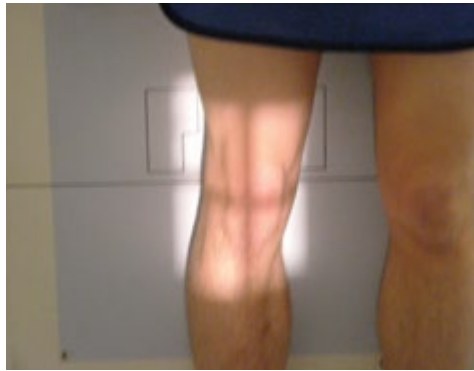

Figure 186.

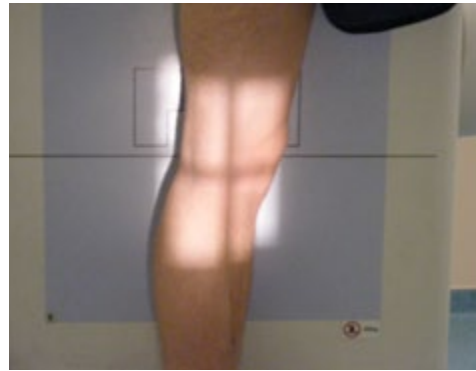

Figure 187.

Patella – axial (delfine)

Patient positioning: The patient lies prone on the X-ray table, with the cassette placed under the knee joint and the knee flexed 90 degrees. The patella axis is perpendicular to the cassette.

Exposure borders: The upper edge is the proximal third of the tibia, and the lower and lateral edges are the soft tissues.

Film or image size: 18 × 24 cm

Focus-film distance: 100 cm

Centering: to the center of the patella
(Figure 188.)

Structure shown:

- patella in tangential position

Patella axiális felvétele Delfine

- patella tangenciálisan látszódik
- femoropatellaris ízületi rész egésze áttekinthető
- condylusok jól látszódnak

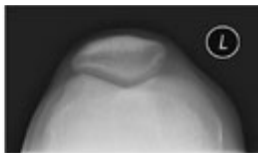


Figure 189.

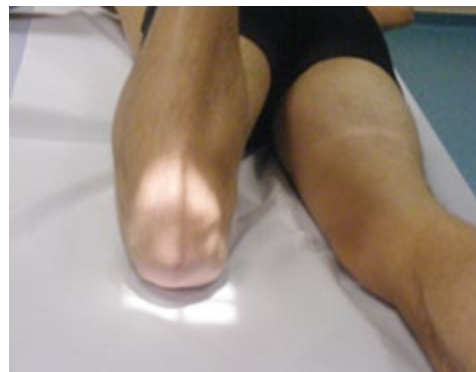

Figure 188.

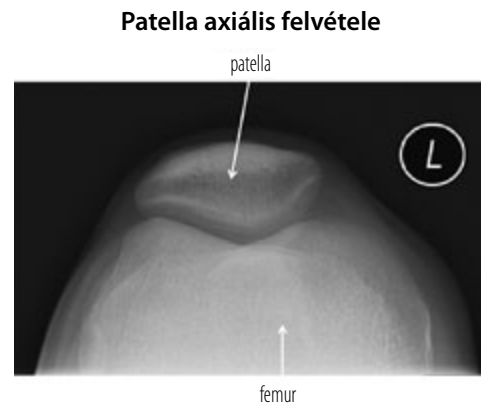


Figure 190.

- open patellofemoral joint
- surfaces of the femoral condyle well demonstrated

Figures 189–190.

For comparison images, the knees have to be symmetrically placed on the detector. Centering is at the midpoint between the two patellas and the center of the detector. It is important to use an xray marker.

(Figures 191–192.)

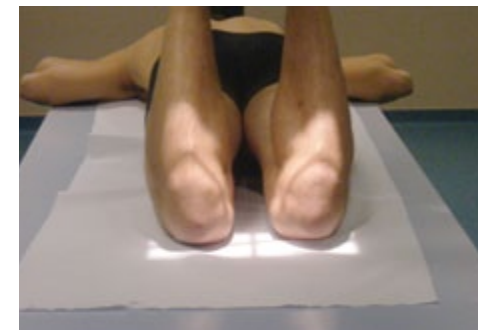

Figure 191.

Patella axiális felvétele

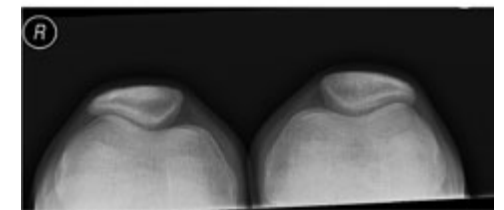


Figure 192.

LEG – A

In case of a leg examination, either the ankle or the knee should also be visible on the image.

Patient positioning: the patient is supine on the X-ray table, with both legs extended. The ankle is supported in dorsiflexion by a firm 90-degree. Adjust the leg so that the femoral condyles are parallel to the cassette. With knee included: rotate the leg 10 degrees medially; with ankle included: rotate the leg 30 degrees medially.

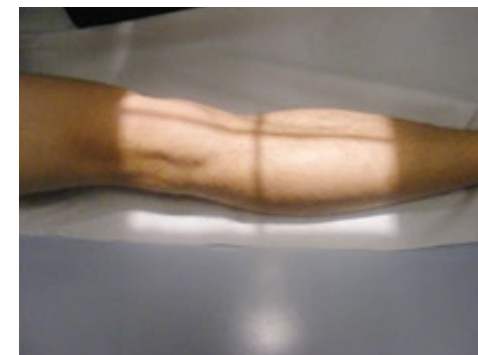

Figure 193.

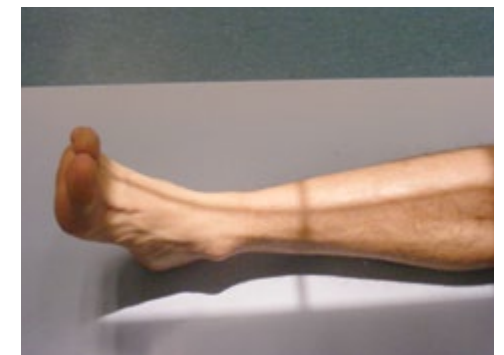

Figure 194.

Exposure borders: with the knee included: the upper edge is the distal third of the femur, and the lower edge is the distal third of the leg, while the lateral edges are the soft tissues. With the ankle included: the upper edge is the proximal third of the leg, and the lower and the lateral edges are the soft tissue.

Film or image size: 15 × 40 cm

Focus-film distance: 100 cm

Centering: to the center of the detector
(Figures 193–194.)

Structures shown:

- ankle and/or knee joints on AP projections
- leg, ankle and knee joints without rotation

(Figure 195.)

Lábszár AP felvétele

- egész lábszár ábrázolódjon az egyik ízülettel
- lábszár-, boka-, illetve térdízület elfordulás nélkül ábrázolódjon

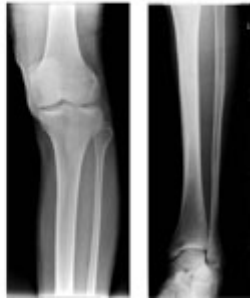

Figure 195.

LEG – lateral

Patient positioning: From the supine position, the patient rotates to the affected side. The leg is rotated further until the malleoli are superimposed vertically. The tibia should be parallel to the cassette and the foot should be perpendicular to the leg.

Exposure borders: With the knee included: the upper edge is the distal third of the femur, and the lower edge is the distal third of the leg, while the lateral edges are the soft tissues. With the ankle included: the upper edge is the proximal third of the leg, and the lower and the lateral edges are the soft tissues.

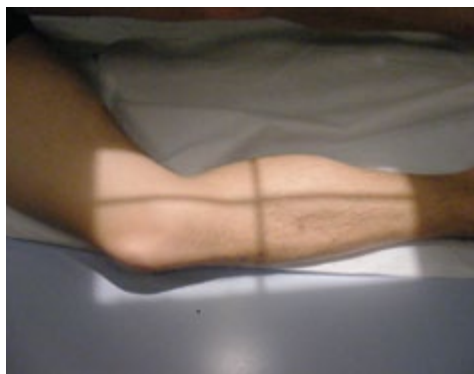

Figure 196.

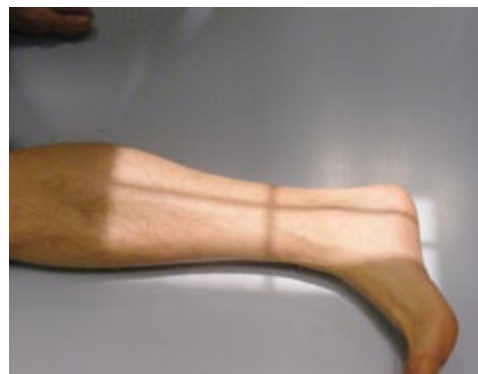

Figure 197.

Film or image size: 15 × 40 cm

Focus-film distance: 100 cm

Centering: to the center of the detector
(Figures 196–197.)

Structures shown:

- ankle and/or knee joints on one image
- distal fibula lying over the posterior half of the tibia

(Figures 198–200.)

(Figures 201–202. Pathologies)

Lábszár oldalirányú felvétele

- az egész lábszár ábrázolódjon a térd- vagy bokaízülettel teljesen oldalirányból
- (a tibia részben rávetül a fibula proximális végére és teljesen rávetül a fibula distális végén a külbokára)

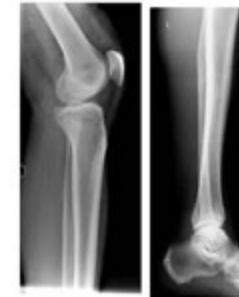

Figure 198.

Lábszár kétirányú felvétele bokaízülettel

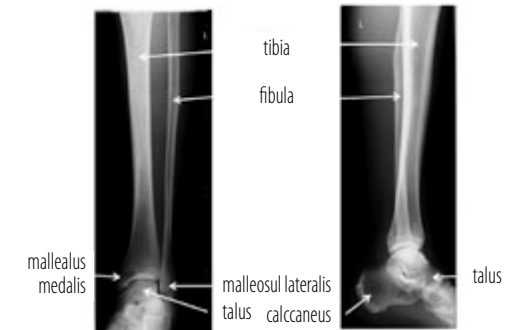

Figure 200.

Dislocated fractures of the fibula and tibia

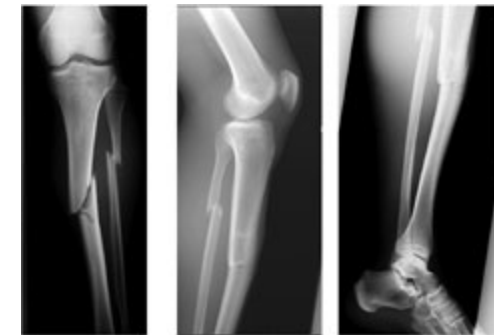

Figure 201.

Lábszár kétirányú felvétele térdízülettel

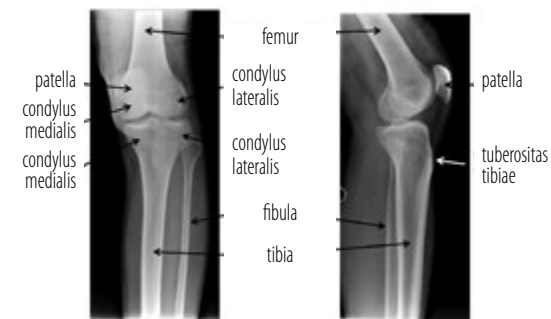

Figure 199.

Status after surgery

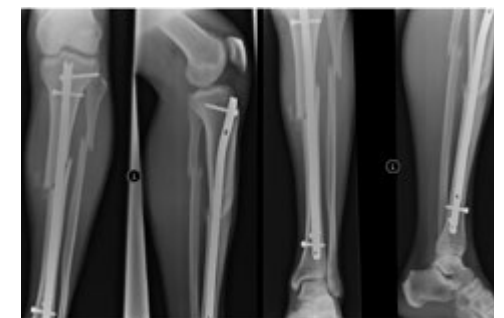

Figure 202.

Surface anatomy of the foot and ankle

The medial and lateral ankles are palpable; the bump made by the medial malleolus is greater. The lateral malleolus is approx. 1-2 cm lower than the medial malleolus. Under the lateral malleolus, there is the calcaneus, distal from the calcaneus there is the cuboid.

Ankle – AP

Patient positioning: The patient is either supine on the X-ray table with both legs extended. The affected ankle is supported in dorsiflexion by a firm 90-degree pad placed against the plantar aspect of the foot. The limb is rotated medially (approximately 30 degrees) until the medial and lateral malleoli are equidistant from the cassette.

Exposure borders: The upper edge is the distal third of the leg, and the lower and the lateral edges are the soft tissues.

Film or image size: 13 × 18 cm

Focus-film distance: 100 cm

Centering: to the ankle joint, at the midpoint between the malleoli.

http://tamop.etk.pte.hu/tamop412A/Kepalkotasi_gyakorlatok_tananyag/RTG/RTG_video-ok/30_boka_AP_en.avi

(Figure 203.)

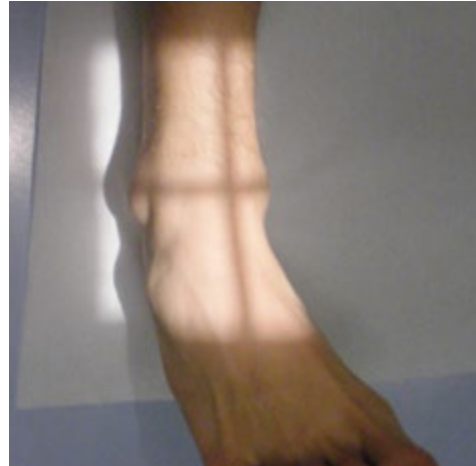

Figure 203.

Bokaízület AP felvétel

- bokaízület a felvétel közepén van
- tibia és a fibula distalis vége a tibiofibularis ízületnél kissé egymásra vetül
- malleolus medialis jól ki-vetül
- malleolus lateralis kissé rávetül a talusra

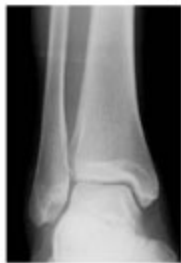

Figure 204.

Bokaízület AP felvétel

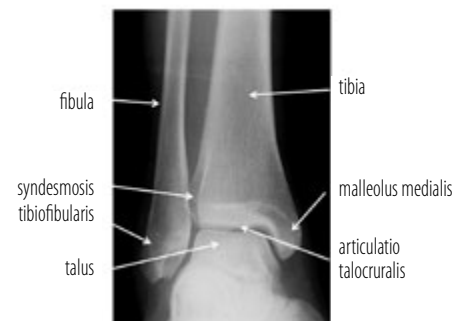


Figure 205.

Structures shown:

- ankle joint centered to exposure area
- normal overlapping of the tibiofibular articulation with the anterior tubercle slightly superimposed over the fibula
- lateral malleolus slightly overlapping talus
- no overlapping of the medial talomalleolar articulation
- medial malleolus well demonstrated

(Figures 204–205.)

Ankle – lateral

Patient positioning: With the ankle dorsiflexed, the patient turns to the affected side until the malleoli are superimposed vertically and the tibia and the foot is parallel to the cassette.

Exposure borders: The upper edge is the distal third of the leg, and the lower and the lateral edges are the soft tissues.

Film or image size: 13 × 18 cm

Focus-film distance: 100 cm

Centering: to the lateral malleolus

http://tamop.etk.pte.hu/tamop412A/Kepalkotasi_gyakorlatok_tananyag/RTG/RTG_video-ok/31_boka_oldal_en.avi

(Figure 206.)

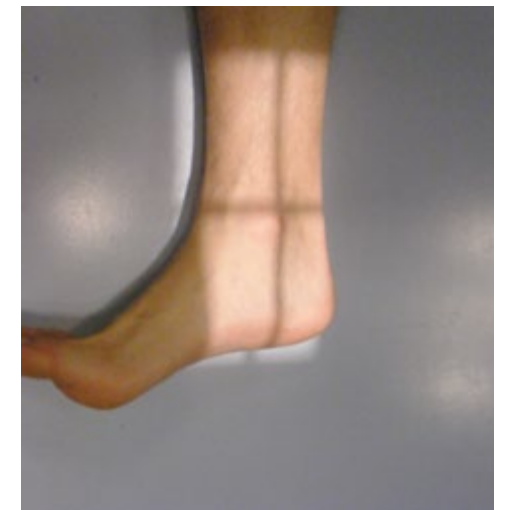

Figure 206.

Bokaízület oldalirányú felvétele

- a tibia distalis hátsó része a fibulavégére vetüljön
- bokaízület közepén legyen, az ízületi rész jól ábrázolódik, medialisan lateralis és caudalisan egyforma széles
- a tibiotalaris ízület és a boka nyúlványok vetüljenek egymásra
- a talus, os naviculare, os cuboideum és a calcaneus ábrázolódjon

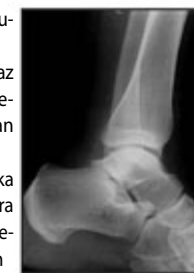

Figure 207.

Bokaízület oldalirányú felvétele

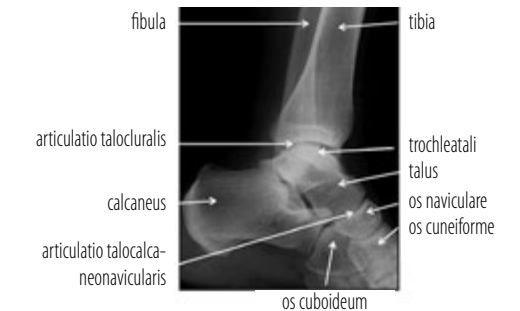
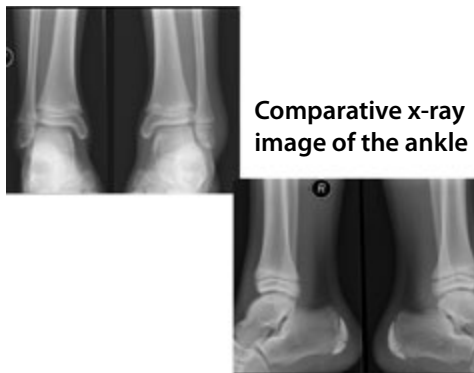


Figure 208.



Comparative x-ray image of the ankle

Figure 209.

Fractures of the both malleoli

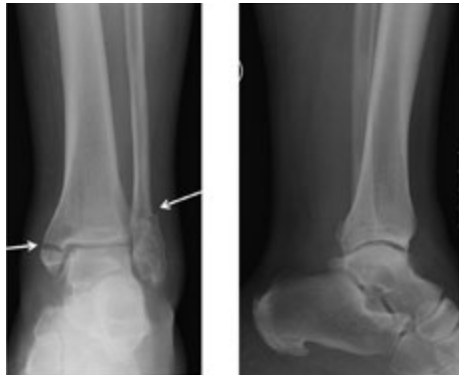

Figure 210

Fractures of both malleoli and the posterior part of the tibia

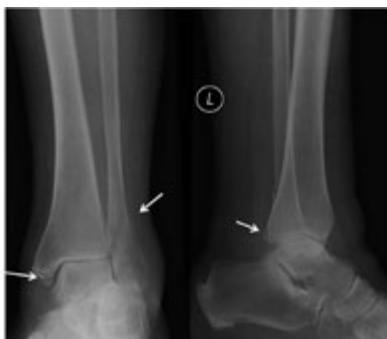

Figure 211.

Structures shown:

- ankle joint centered to exposure area
- tibiotalar joint well visualized, with the medial and lateral talar domes superimposed
- fibula over the posterior half of the tibia
- distal tibia and fibula, talus, and adjacent tarsals demonstrated

(Figures 207–208.)

(Figures 209–213. Pathologies)

Control x-ray image of the ankle, and during surgery

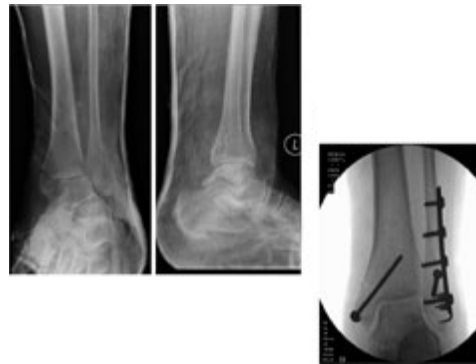

Figure 212.

Non-ossifying fibroma in the distal tibial metaphysis

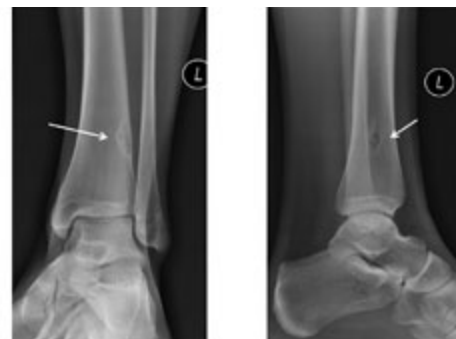

Figure 213.

Foot – AP (dorso-plantar)

Patient positioning: The patient is seated on the X-ray table, supported if necessary, with the affected hip and knee flexed. The plantar aspect of the affected foot is placed on the cassette and the lower leg is supported in the vertical position by the other knee. The longitudinal axis of the detector is the same as the longitudinal axis of the foot.

Exposure borders: The upper edge is the distal third of the leg, and the lower and the lateral edges are the soft tissues.

Film or image size: 24 × 30 cm

Focus-film distance: 100 cm

Centering: 10 degrees toward the heel to the base of the third metatarsal or perpendicular to the cassette and toward the base of the third metatarsal.

(Figure 214.)

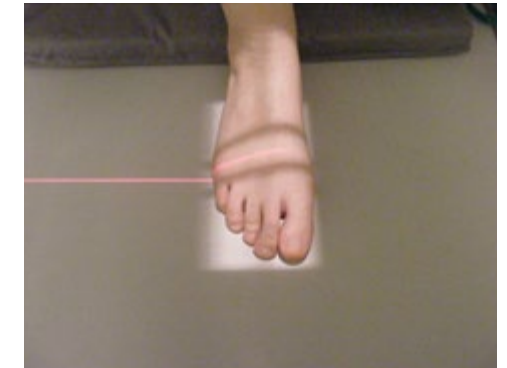


Figure 214.

Structures shown:

- visualization of the phalanges and tarsals distal to the talus, as well as the metatarsals
- no rotation of the foot

(Figures 215–216.)

Láb AP/dorso-plantaris felvétele

- láb teljes egészében (lábujjak distális phalanxaitól a lábtő-csontokig) elfordulás nélkül ábrázolódjon
- os cuneiforme, os cuboideum és az os naviculare jól látszódnak

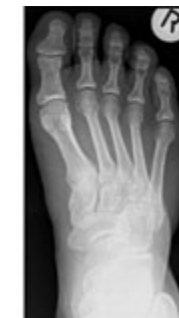

Figure 215.

Láb PA/dorso-volaris felvétele

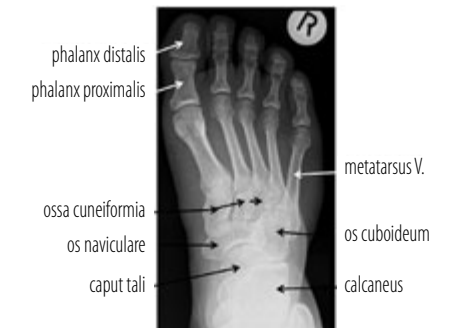

Figure 216.

Foot – medial oblique

Medial oblique images of the foot are taken so that the tarsals do not project onto each other, and only in some cases (eg.: foreign body) are total lateral images taken.

Patient positioning: The patient is seated on the X-ray table. From the basic position, the affected limb is allowed to lean medially to bring the plantar surface of the foot approximately 30–45 degrees to the cassette.

Exposure borders: The upper edge is the distal third of the leg, and the lower and the lateral edges are the soft tissues.

Film or image size: 24 × 30 cm

Focus-film distance: 100 cm

Centering: to the base of the third metatarsal

(Figure 217.)

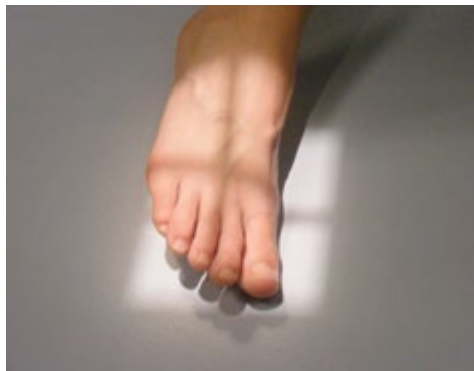


Figure 217.

Láb medialis félferde felvétele

- a láb teljes egészében ábrázolódik
- az ujjak, lábközépcsontok, láb-tőcsontok nem vetülnek egymásra

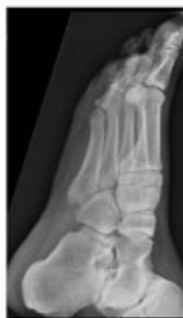

Figure 218.

Láb felvétele

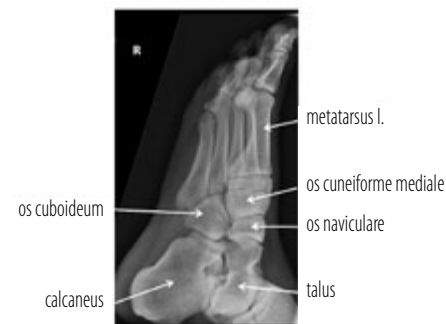

Figure 219.

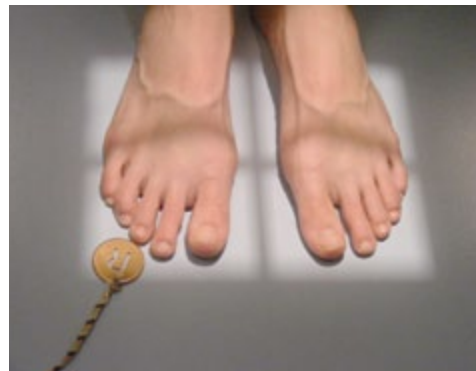

Figure 220.

Láb összehasonlító AP felvétele

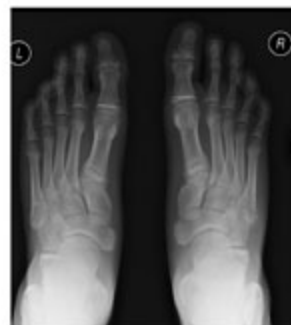

Figure 221.

Structures shown:

- toes, tarsals and metatarsals free of superimposition
- the foot entirely demonstrated (Figures 218–219.)

For comparison images the two feet have to be symmetrically placed on the cassette. Centering between the two feet at the height of the third metatarsal, to the center of the detector. It is important to use an X-ray marker.

(Figures 220–221.)

(Figure 222. Pathology)

Fracture of the fifth metatarsal bone

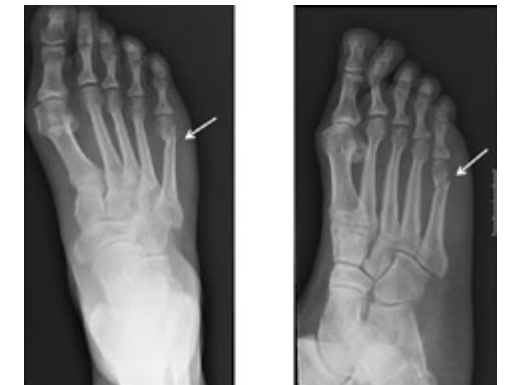

Figure 222.

First toe – AP

Patient positioning: The patient is seated on the X-ray table, supported if necessary, with hips and knees flexed. The plantar aspect of the affected foot is placed on the cassette. The first toe is in the center of the cassette.

Exposure borders: The upper edge is the head of the metatarsus, and the lower and the lateral edges are the soft tissues.

Film or image size: 13x18 cm

Focus-film distance: 100 cm

Centering: to the center of the first toe

(Figure 223.)

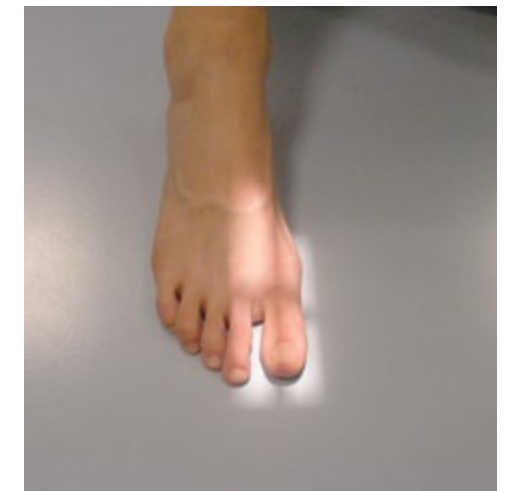

Figure 223.

First toe – lateral

Patient positioning: The patient is seated on the X-ray table. From the dorso-plantar position, the foot is rotated medially until the medial aspect of the hallux is in contact with the cassette. A bandage is placed around the remaining toes (provided that no injury is suspected) and they are gently pulled forwards by the patient to clear the hallux. The first toe is in the center of the cassette.

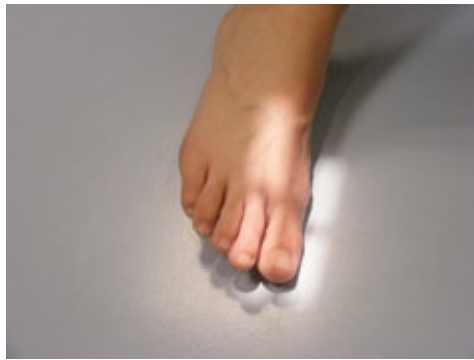

Figure 224.

Exposure borders: The upper edge is the head of the metatarsal, and the lower and the lateral edges are the soft tissues.

Film or image size: 13 × 18 cm

Focus-film distance: 100 cm

Centering: to the center of the first toe

(Figures 224–225.)

(Figures 226–227. Pathologies)

Fracture of the proximal phalanx of the first toe

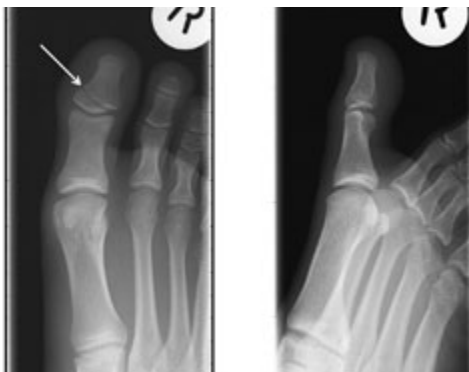

Figure 226.

Toes ii.–V. – AP

Patient positioning: The patient is seated on the X-ray table, supported if necessary, with hips and knees flexed. The plantar aspect of the affected foot is placed on the cassette. The toes are in the center of the cassette.

Láb I. ujj kétirányú felvétele

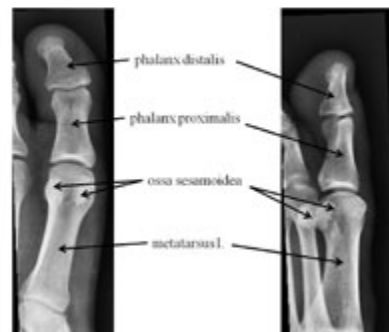

Figure 225.

Status after surgery

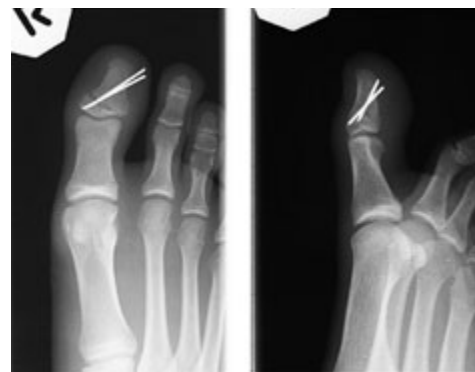

Figure 227.

Exposure borders: The upper edge is the head of the metatarsal, and the lower and the lateral edges are the soft tissues.

Film or image size: 13 × 18 cm

Focus-film distance: 100 cm

Centering: to the center of the third toe

(Figure 228.)

Structures shown:

- no rotation of phalanges or metatarsals

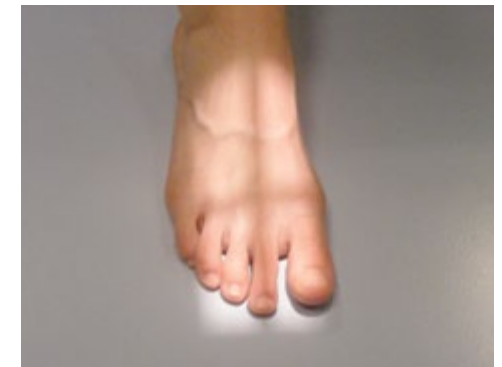

Figure 228.

Toes ii.–V. – Oblique

Patient positioning: From the basic dorso-plantar position, the affected limb is allowed to lean medially to bring the plantar surface of the foot approximately 30 degrees to the cassette.

Exposure borders: The upper edge is the head of the metatarsal, and the lower and the lateral edges are the soft tissues.

Film or image size: 13 × 18 cm

Focus-film distance: 100 cm

Centering: to the center of the third toe

(Figures 229–231.)

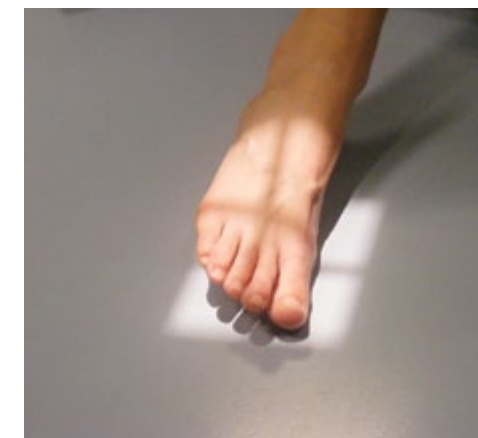
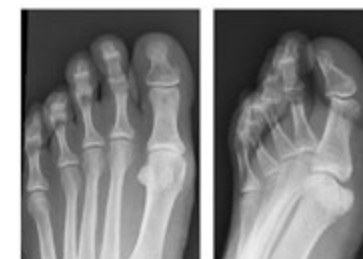
Figure 229.

Lábujjak felvétele



- a lábujjak distális phalanxaitól a lábtőcsontokig elfordulás nélkül ábrázolódjön

Figure 230.

Lábujjak kétirányú felvétele

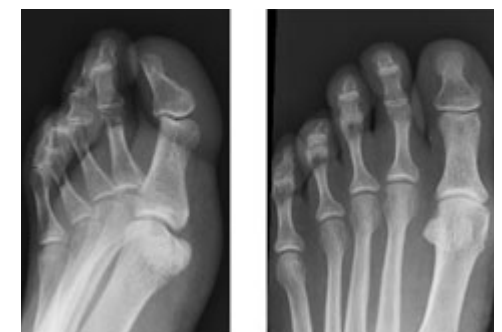

Figure 231.

Calcaneus – lateral

Patient positioning: From the supine position, the patient rotates on to the affected side. The leg is rotated until the medial and lateral malleoli are superimposed vertically. The plantar surface is parallel to the cassette.

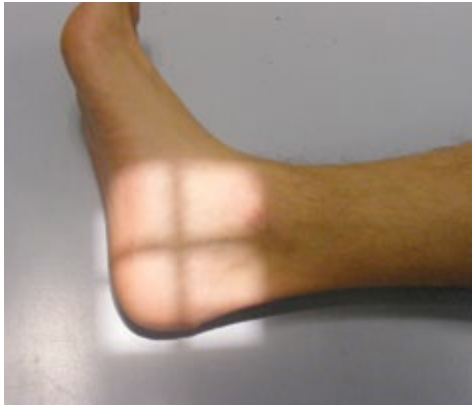


Figure 232.

Sarokcsont oldalirányú felvétele

- a calcaneus elfordulás nélkül ábrázolódjon
- a talus, os naviculare és az os cuboideum közti ízületi részek látszanak

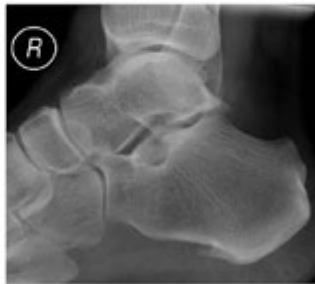

Figure 233.

Exposure borders: The upper edge is above the ankle, the lower and the lateral edges are the soft tissues.

Film or image size: 13 × 18 cm

Focus-film distance: 100 cm

Centering: to the center of the calcaneus (Figure 232.)

Structures shown:

- no rotation of the calcaneus
- Joints between the calcaneus the talus, navicular and cuboid are well demonstrated. (Figures 233–234.)

Sarokcsont oldalirányú felvétele

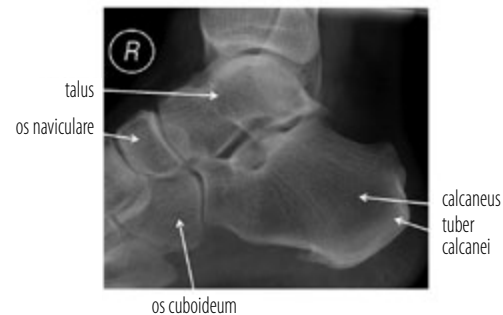


Figure 234.

Calcaneus – axial

Patient positioning: The patient sits or lies supine on the X-ray table with both limbs extended. The affected leg is rotated medially until both malleoli are equidistant from the film. The ankle is dorsiflexed. The position is maintained by using a bandage strapped around the forefoot and held in position by the patient. The plantar surface is perpendicular to the cassette.

Exposure borders: The upper edge is the mid-third of the foot and the lateral edges are the soft tissues.

Film or image size: 13 × 18 cm

Focus-film distance: 100 cm

Centering: to the midpoint of the center of the calcaneus at a caudal angle of 40 degrees to the long axis of the foot

http://tamop.etk.pte.hu/tamop412A/Kepalkotasi_gyakorlatok_tananyag/RTG/RTG_video/32_sarok_axialis_en.avi

(Figures 235–236.)

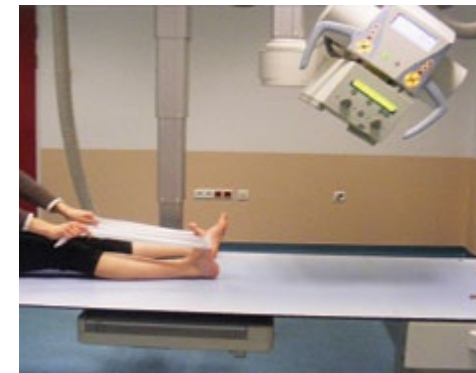

Figure 235.

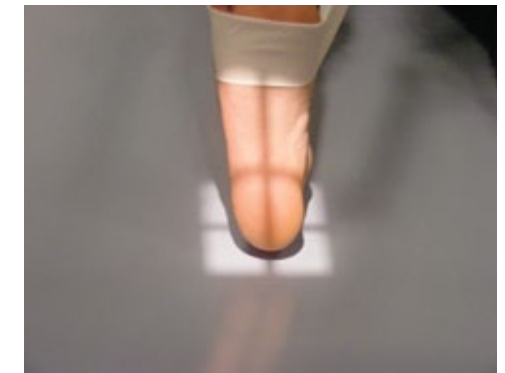

Figure 236.

Structures shown:

- no rotation of the calcaneus (Figures 237–238.) (Figure 239. Pathology)

Sarokcsont axialis felvétel

- a sarokcsont elfordulás nélkül, egészében ábrázolódik

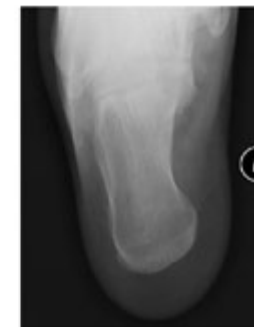

Figure 237.

Sarokcsont axialis felvétel

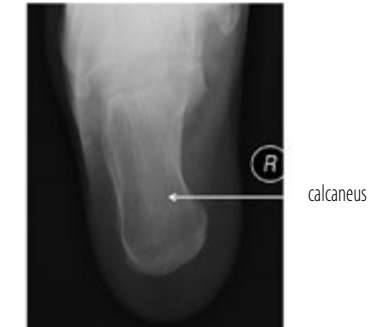

Figure 238.

Calcaneus – axial oblique (zadrawecz-borden)

Patient positioning: the patient lies supine on the X-ray table, with the affected limb extended. The ankle joint is dorsiflexed and the malleoli are equidistant from the film. The leg is internally rotated through 45 degrees. Centring is 1 cm distal to the lateral malleolus on the talocalcaneal joint with the following angulations:

- 10 degrees cranio-caudal (Figure 240.)
- 0 degree (Figure 241.)
- 30 degrees caudo-cranial (Figure 242.)
- 40-45 degrees caudo-cranial (Figure 243.)

Exposure borders: The upper edge is above the lateral malleolus by approx. 3 cm, and the lower and lateral edges are the soft tissues.

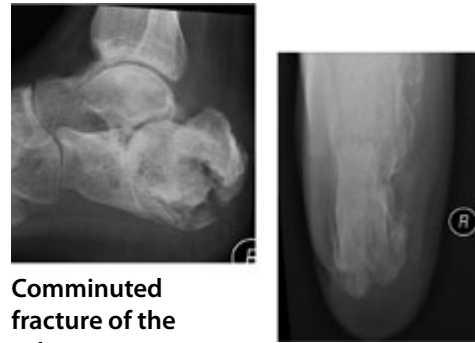Film or image size: 13 × 18 cm

Focus-film distance: 100 cm

Centering: 1 cm distal to the lateral malleolus

With this technique the subtalar joint is well demonstrated. Articular step-off, thalamic fragment dislocation, the relative position and the diastasis between the fragments, moreover lateralisation of the tuber are easily assessed.

(Figure 244.)



Comminuted fracture of the calcaneus

Figure 239.

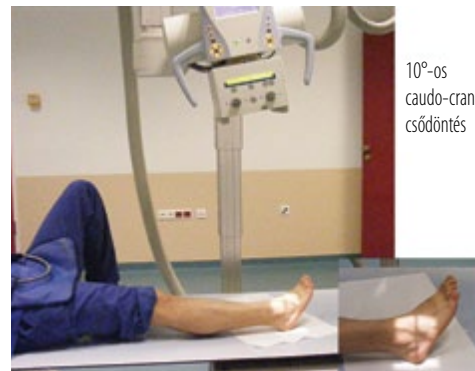

Figure 240.

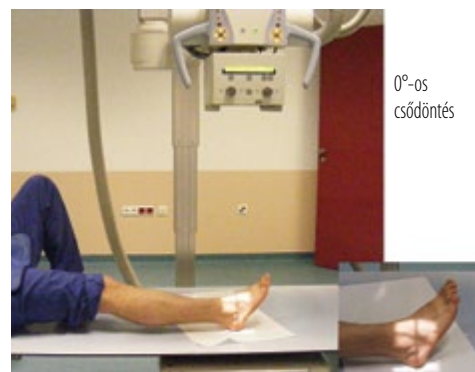


Figure 241.

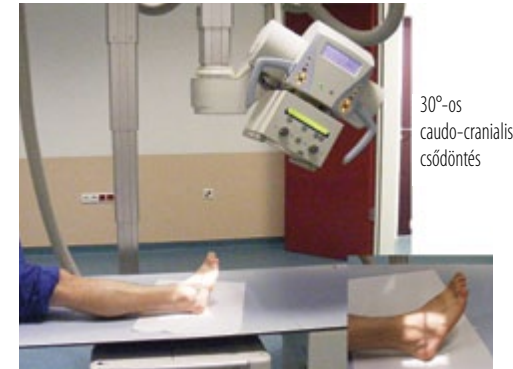

Figure 242.

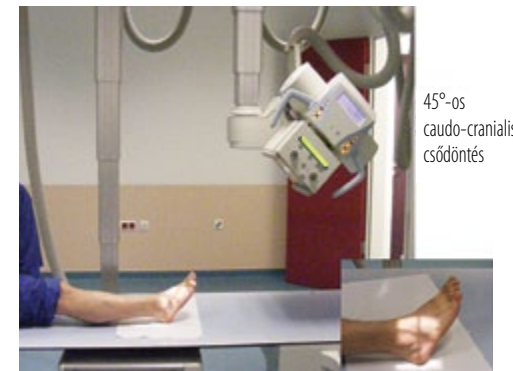


Figure 243.

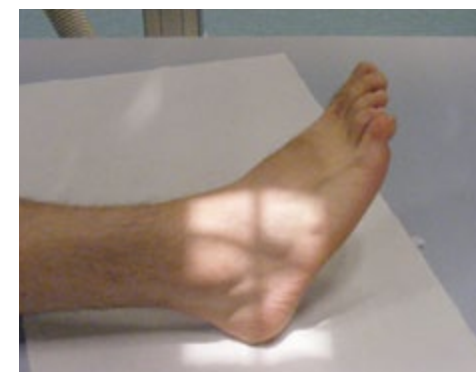

Figure 244.

Borden sor I. felvétel 10°-os eranio-caudalis irányú csődöntés

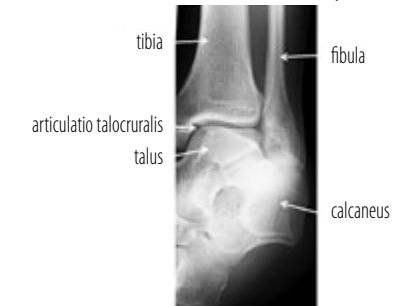

Figure 245.

Borden sor II. felvétel 0°-os csődöntés

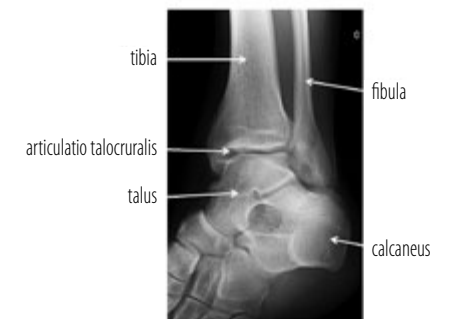

Figure 246.

Borden sor III. felvétel 30°-os caudo-cranialis irányú csődöntés

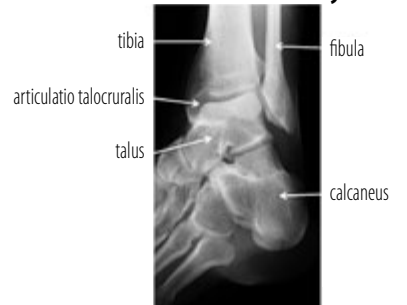

Figure 247.

Boden sor 4. felvétel 45°-os caudo-cranális irányú döntés

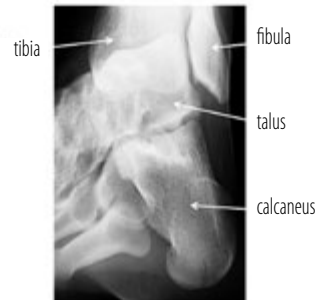

Figure 248.

Structures shown:

- calcaneus and the posterior talocalcaneal joint fully demonstrated (Figures 245–248.) (Figure 249. Pathology)

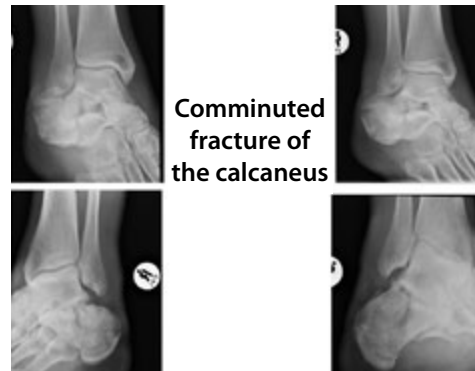


Figure 249.

III.7. X-ray anatomy and imaging technique of the vertebral column and sacroiliac joint

The vertebral column forms the central axis of the skeleton and is centered in the midsagittal plane of the posterior part of the trunk. The vertebral column is composed of small segments of bone called vertebrae. Disks of fibrocartilage are interposed between the vertebrae and act as cushions. The vertebral column usually consists of 32-35 small, irregularly shaped bones.

These are:

- 7 cervical vertebrae
- 12 thoracic vertebrae
- 5 lumbar vertebrae
- 5 sacral vertebrae
- 3-5 coccygeal vertebrae

Viewed from the side, the vertebral column has four curves that arch anteriorly and posteriorly from the midcoronal plane of the body.

These are:

- cervical lordosis
- thoracic kyphosis
- lumbar lordosis
- sacral/pelvic kyphosis

A typical vertebra is composed of two main parts; an anterior mass of bone called the body and a posterior ringlike portion called the vertebral arch. The vertebral body and arch enclose a place called the vertebral foramen. In the articulated column the vertebral foramina form the vertebral canal. The body of the vertebra is approximately cylindrical in shape and is composed largely of cancellous bony tissue covered by a layer of compact tissue. In the articulated spine the vertebral bodies are separated by intervertebral disks. The vertebral arch is formed by two pedicles and two laminae that support four articular processes, two transverse processes, and one spinous process. By articulation with the vertebrae above and below, the notches form intervertebral foramina for the transmission of spinal nerves and blood vessels. The transverse processes project laterally and slightly posteriorly from the junction of the pedicles and laminae. The spinous process project posteriorly and inferiorly from the junction of the laminae in the posterior midline. The articulating surface of the four articular processes are covered with fibrocartilage and are called facets. In a typical vertebra, each superior articular process has an articular facet on its posterior surface, and each inferior articular process has an articular facet on the anterior surface.

The first two **cervical vertebrae** are atypical in that they are structurally modified to join the skull.

The typical cervical vertebrae (C III.-C VI.) have a small, transversely located, oblong body with slightly elongated anteroinferior border. The transverse processes of the typical cervical vertebra arise partly from the side of the body and partly from the vertebral arch. These processes are short and wide, and they are perforated by the transverse foramina for the transmission of the vertebral artery and vein. The atlas (C I.), the first cervical vertebra, is a ring like structure with no body and a very short spinous process. The atlas consists of an anterior arch, a posterior arch, two lateral masses, and two transverse processes. The axis (C II.), the second cervical vertebra, has a strong conical process arising from the upper surface of its body. This process, called the dens or odontoid process, is received into the anterior portion of the atlantal ring to act as the pivot or body for the atlas.

The bodies of the **thoracic vertebrae** increase in size from the first to the twelfth vertebrae. The bodies of the typical (third through ninth) thoracic vertebrae are approximately triangular in form.

The posterolateral margins of each thoracic body have costal facets for articulation with the heads of the ribs.

The **lumbar vertebrae** have large, beanshaped bodies that increase in size from the first to the fifth vertebra in this region. The transverse processes of the lumbar vertebrae are smaller than those of the thoracic vertebrae.

The **sacrum** is formed by the fusion of the three-five sacral vertebral segments into a curved, triangular bone. The sacrum is wedged between the iliac bones of the pelvis, with its broad base directed obliquely, superiorly, and anteriorly and its apex directed posteriorly and inferiorly. The superior surface of the base of the sacrum corresponds in size and shape to the inferior surface of the last lumbar segment, with which it articulates to form the lumbosacral junction. At its superior anterior margin the base of the sacrum has a prominent ridge termed the sacral promontory. Directly behind the bodies of the sacral segment is the sacral canal, which is the continuation of the vertebral canal. The anterior and posterior walls of the sacral canal are each perforated by four pairs of pelvic sacral foramina for the passage of the sacral nerves and blood vessels.

Indications:

Trauma (fracture, luxation), degenerative disorders, developmental disorders, rheumatic disorders, cerebral circulatory disorders (cervical spine), osteoporosis.

On the x-ray images the following can be judged:

- physiological curvatures and possible deformations
- direction and severity of abnormal curvatures
- disability on functional images
- vertebral shape, size, calcium content, metastasis, fracture, compression
- quantity changes (lumbarisation, sacralization)
- vertebral end plates ("bone spurs")
- discs (indirectly)

- processes' shape, direction, small joints
- width of intervertebral foramina

Surface anatomy of the cervical spine:

- C. I. vertebra is 1 cm below/in front of the mastoid process
- C. IV. vertebral is at the height of the thyroid cartilage
- the spinous process of the seventh vertebra is longer, heavier, palpable (vertebra prominens)

C-spine – AP

Patient positioning: The patient lies supine on the table or, if erect positioning is preferred, sits or stands with the posterior aspect of the head and shoulders against the vertical grid device. The neck is extended (if the patient's condition will allow) so that the mandible is cleared from the upper cervical vertebra.

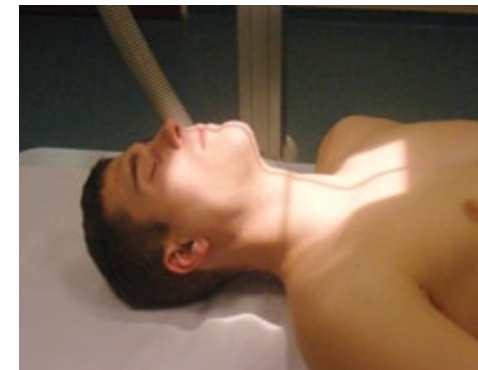

Figure 250.

Exposure borders: The upper edge is at the level of the ear; the lower edge is the jugulum, and the lateral edges are inside the soft tissues by approx. 1 cm.

Film or image size: 18 × 24 cm

Focus-film distance: 100 cm

Centering: through C IV. with a ray angle of 10 degrees to the thyroid cartilage.

http://tamop.etk.pte.hu/tamop412A/Kepalkotasi_gyakorlatok_tananyag/RTG/RTG_video/33_nyak_AP_en.avi
(Figures 250–252.)

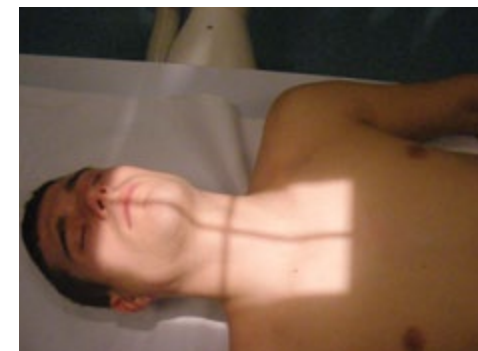

Figure 251.

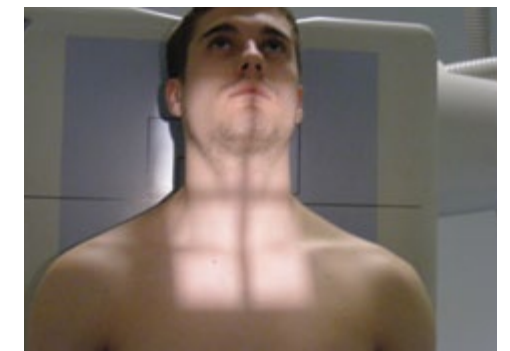


Figure 252.

Nyaki gerinc AP felvétele

- koponya basisától a Th. I. csigolyáig érő szakasz ábrázolódik
- intervertebrálisrések és az ívek közti rések ábrázolódnak
- gerinc a felvétel közepén, síkja párhuzamos a detektorral

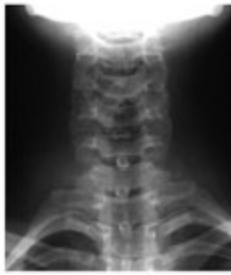

Figure 253.

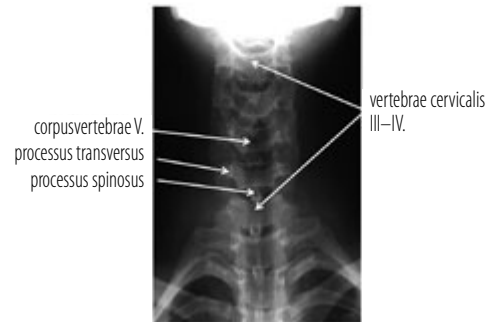
Nyaki gerinc felvétele

Figure 254.

Structures shown:

- from the skull base to the first thoracic vertebra.
- the mandible and occiput are superimposed over the atlas and most of the axis - open intervertebral disk spaces
- the vertebrae are in the center of the cassette

(Figures 253–254.)

On these images, usually, only the section between C. III–VII. is well visualized. For C.I–II. vertebrae, we take targeted images or examine the entire cervical spine with Ottonello images.

C I–II. Spine – AP (transoral)

Patient positioning: The patient lies supine on the table or, if erect positioning is preferred, sits or stands with the posterior aspect of the head and shoulders against the vertical grid device. The neck is extended. Have the patient open the mouth as wide as possible, and then adjust the head so that a line from the lower edge of the upper incisors to the tip of the mastoid process is perpendicular to the cassette.

Exposure borders: The upper edge is at the level of the ear, and the lower edge is the jugulum; the lateral edges are inside the soft tissues by approx. 2 cm.

Film or image size: 13 × 18 cm

Focus-film distance: 100 cm

Centering: through the mouth to C I–II.

(Figures 255–256.)

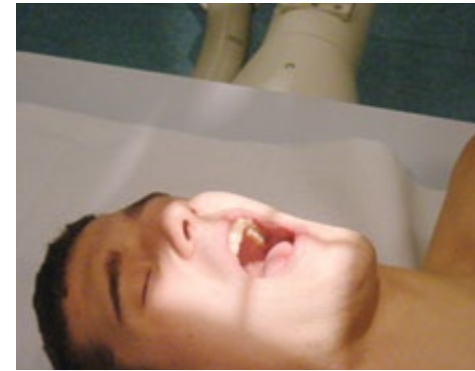

Figure 255.

C. I–II. csigolya AP transoralis felvétele

- atlas és az axis nyitott szájba vetül
- dens csúcs és a C. I–II. ízesülése jól látszódjon

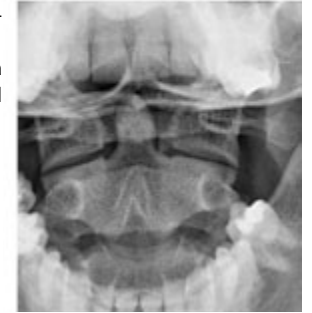

Figure 257.

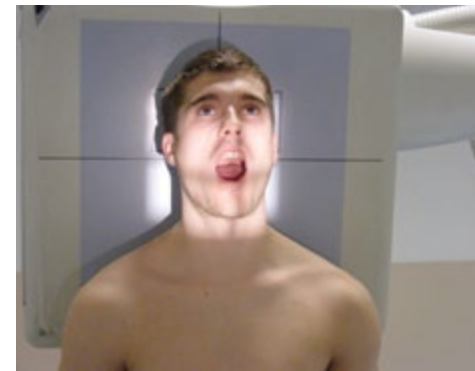


Figure 256.

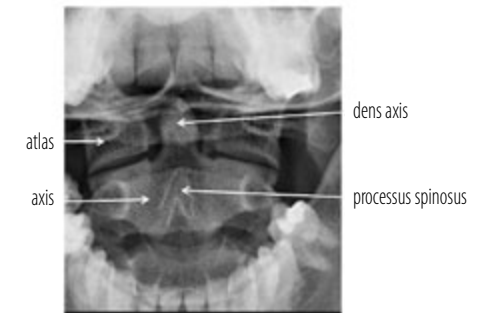
C. I–II. csigolya AP transoralis felvétele

Figure 258.

Structures shown:

- dens, atlas, axis, and articulations between the first and second cervical vertebrae are well demonstrated
- atlas and the axis are projected into the open mouth

(Figures 257–258.)

C-spine – AP (ottonello)

Patient positioning: The patient lies supine on the table or, if erect positioning is preferred, sits or stands with the posterior aspect of the head and shoulders against the vertical grid device. The neck is extended (if the patient's condition will allow) so that the mandible is cleared from the upper cervical vertebra.

Exposure borders: The upper edge is at the level of the ear; the lower edge is the jugulum, and the lateral edges are inside the soft tissues by approx. 2 cm.

Film or image size: 18 × 24 cm

Focus-film distance: 100 cm

Centering: to the mandible

An extended exposure time is used (more than 1.5-2 sec), and the patient moves his mandible continuously during the exposure so it will become blurred and the C.I-II. vertebrae can be judged.

It may be helpful to have the patient practice the mandible movement prior to exposure.

1st. movie

Structures shown:

- area from skull base to Th I.
- shadows of the mandible and occiput are superimposed over the atlas and most of the axis
- open intervertebral disk spaces
- the vertebrae are in the center of the cassette

(Figures 259–260.)

Nyaki gerinc AP felvétele Ottonello szerint

- koponya basisától a Th. I. csigolyáig érő szakasz ábrázolódjon
- intervertebrális rések és az ívek közti rések ábrázolódjanak
- gerinc síkja párhuzamos a kazettával

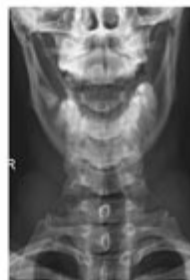

Figure 259.

Nyaki gerinc AP felvétele Ottonello szerint

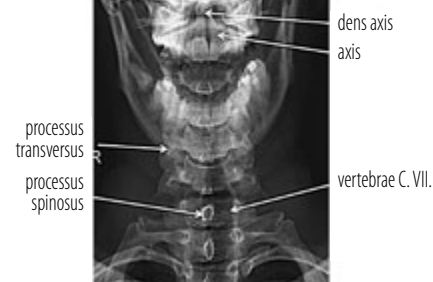


Figure 260.

C spine – lateral

Patient positioning: The patient stands or sits with either shoulder against the cassette. The median sagittal plane should be adjusted such that it is parallel with the cassette. In order to demonstrate the lower cervical vertebra, the shoulders should be depressed. This can be achieved by asking the patient to relax his shoulders downwards.

Exposure borders: The upper edge is at the level of the ear, and the lower edge is the jugulum; the lateral edges are inside the soft tissues by approx. 1 cm.

Film or image size: 18 × 24 cm

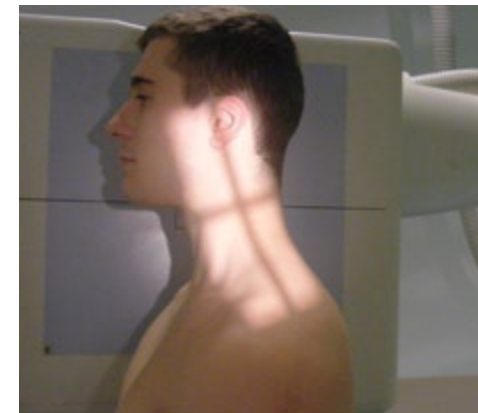

Figure 261.

Focus-film distance: 150 cm

Centering: to the level of the thyroid cartilage; to the center of the neck.

http://tamop.etk.pte.hu/tamop412A/Kepalkotasi_gyakorlatok_tananyag/RTG/RTG_videok/34_nyak_oldal_en.avi
(Figure 261.)

Structures shown:

- all seven cervical vertebrae and at least one third of the first thoracic vertebra.
- superimposed or nearly superimposed rami of the mandible

- no rotation or tilt of the cervical spine indicated by superimposed open zygomatic joints (Figures 262–263.)

Nyaki gerinc oldalirányú felvétele

- nyaki csigolyák I–VII-ig oldalheányzetben, elfordulás nélkül ábrázolódnak
- mandibula szárak fedik egymást, nem vetülnek a nyaki csigolyákra

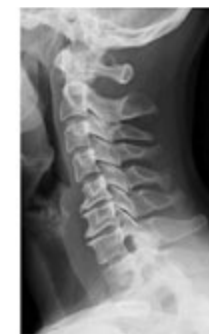

Figure 262.

Nyaki gerinc oldalirányú felvétele

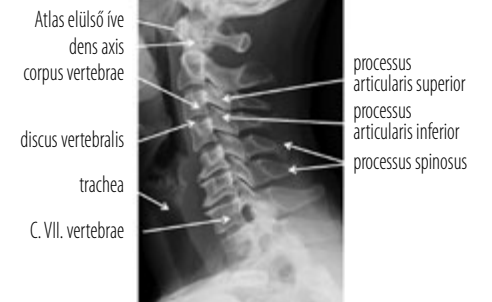


Figure 263.

C spine – lateral (flexion-extension)

Patient positioning: These projections may be required to supplement the basic projections (if a fracture can be safely excluded) in cases of trauma, e.g. subluxation, or pathology, e.g. rheumatoid arthritis (and often before surgery to assess movement in the neck for insertion of an endotracheal tube). The degree of movement and any change in the relationship of the cervical vertebrae can also be assessed.

Patient positioning: The patient stands or sits with either shoulder against the cassette. The median sagittal plane should be adjusted such that it is parallel with the cassette. In order to demonstrate the lower cervical vertebra, the shoulders should be depressed. This can be achieved by

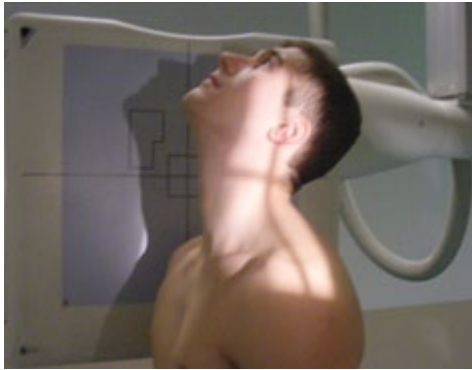

Figure 264.

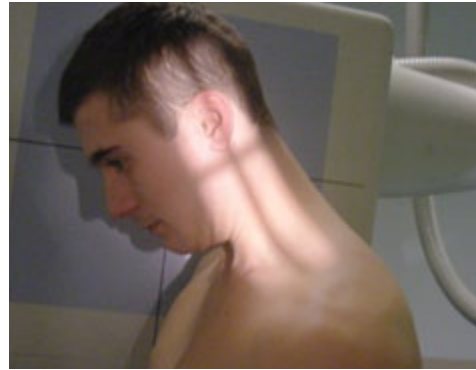

Figure 265.

asking the patient to relax their shoulders downwards. The patient is asked to flex the neck and to tuck the chin in towards the chest as far as it is possible. For the second projection, the patient is asked to extend the neck by raising the chin as far as possible.

Exposure borders: The upper edge is at the level of the ear, and the lower edge is the jugulum, while the lateral edges are inside the soft tissues by approx. 1 cm.

Film or image size: 18 × 24 cm

Focus-film distance: 150 cm

Centering: to the level of the thyroid cartilage; to the center of the neck

(Figures 264–265.)

Structures shown:

- Flexion: the spinosus processes are separated; the mandibular body is almost perpendicular to the bottom edge of the cassette
- Extension: the spinosus processes are close to each other

(Figures 266–267.)

Nyaki gerinc funkcionális felvételei

- anteflexióban: a processus spinosusok elkülönülnek, mandibula test közel merőleges a felvétel alsó szélére
- retroflexióban: a processus spinosusok közel vannak egymáshoz

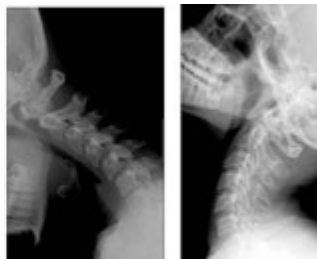

Figure 266.

Nyaki gerinc funkcionális felvétele

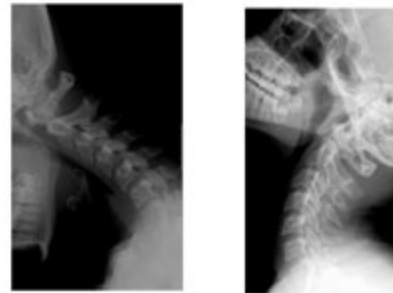

Figure 267.

Cervicothoracic junction – AP

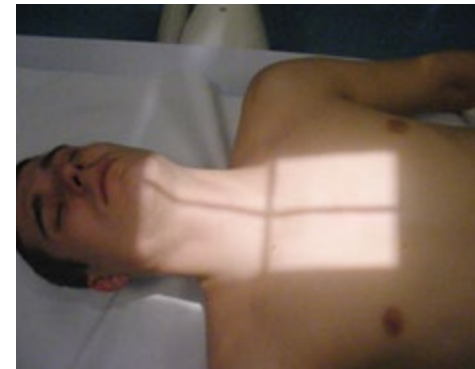

Figure 268.

Exposure borders: The upper edge is the lip, and the lower edge is the sternum; the lateral edges are inside the soft tissues by approx. 1 cm.

Film or image size: 24 × 30 cm

Focus-film distance: 100 cm

Centering: to the jugulum

(Figure 268.)

Structures shown:

- area from C.V. to Th.IV.
- no rotation of the vertebrae

(Figures 269–270.)

Nyaki-háti átmenet AP felvétele

- ábrázolódnak a C.V–Th.VI. csigolya
- csigolyák elfordulás nélkül ábrázolódnak

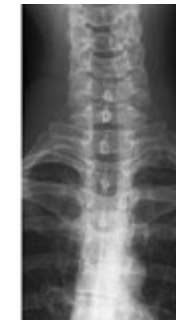

Figure 269.

Nyaki-háti átmenet AP felvétele

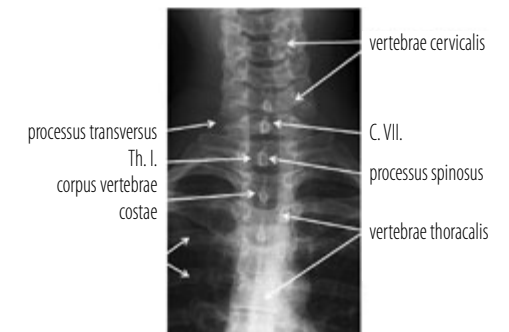


Figure 270.

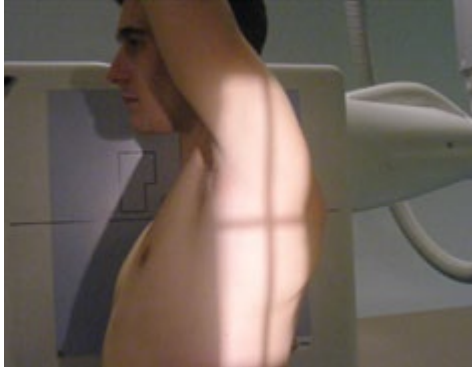Cervicothoracic junction – lateral (twining)

Figure 271.

Film or image size: 18 × 24 cm

Focus-film distance: 100 cm

Centering: to the level of the jugulum; to the spine.

(Figure 271.)

Structures shown:

- vertebrae are not rotated
- shoulders are separated from each other
- area approximately between C.5 to Th.4

(Figures 272–273.)

Nyaki-háti gerinc átmenet oldalirányú felvétele gyorsúszó-tartásban Twining szerint

- a C. V.–Th. VI. csigolyatestek, intervertebrális rések jól láthatók oldalnézetben a humerus rávetülése nélkül

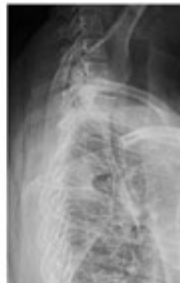

Figure 272.

Patient positioning: The patient stands or sits with either shoulder against the cassette. The median sagittal plane should be adjusted such that it is parallel with the cassette. The arm nearest the cassette is folded over the head, with the humerus as close to the trolley top as the patient can manage. The arm and shoulder nearest the X-ray tube are depressed as far as possible. The shoulders are now separated vertically.

Exposure borders: The upper edge is the lip, and the lower edge is the sternum; the lateral edges are inside the soft tissues by approx. 2 cm.

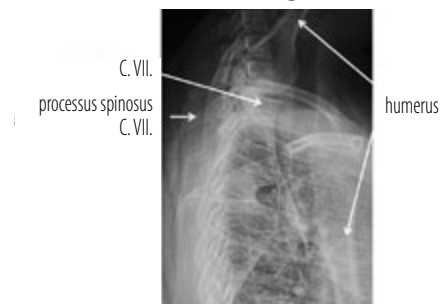
Nyaki-háti gerinc átmenet oldalirányú felvétel Twining szerint

Figure 273.

Thoracic spine – AP

Patient positioning: The patient is positioned supine on the X-ray table, with the median sagittal plane perpendicular to the tabletop.

Exposure borders: The upper edge is above the shoulder; the lower edge is at the level of the last rib, and the lateral edges are approximately 3 centimeters lateral from the vertebrae

Film or image size: 20 × 40 cm

Focus-film distance: 100 cm

Centering: to the center of the sternum

http://tamop.etk.pte.hu/tamop412A/Kepalkotasi_gyakorlatok_tananyag/RTG/RTG_video-ok/35_hat_AP_en.avi

(Figure 274.)

For the assessment of the physiological curvatures, we can image the patient in a standing position, too.

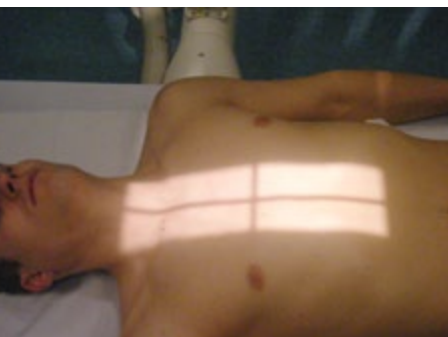

Figure 274.

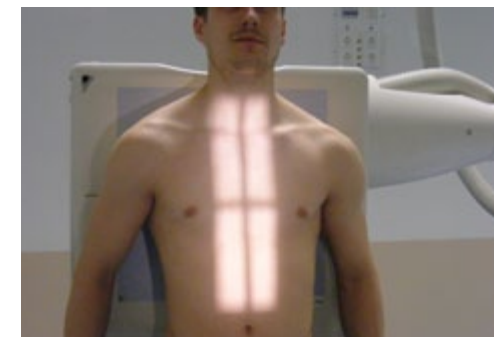

Figure 275.

Háti gerinc AP felvétele

- ábrázolódik a C. VII–L. I. csigolya
- minden csigolya azonos denzitású (kazetta esetén kiegyenlítő fóliát alkalmazunk)
- háti csigolyák a felvétel közepén, elfordulás nélkül ábrázolódnak
- oldaljelzés

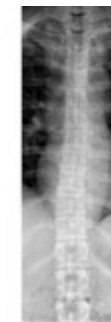

Figure 276.

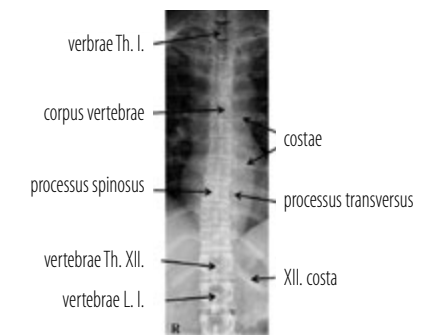
Háti gerinc AP felvétele

Figure 277.

Structure shown:

- vertebrae from C VII.–L I.
- vertebral column aligned to the middle of the radiograph, without rotation
- each vertebra has the same density

Figures 276–277.

Thoracic spine – lateral

Patient positioning: Usually undertaken with the patient in the lateral decubitus position on the X-ray table, although this projection can also be performed erect. The median sagittal plane should be parallel to the cassette. The arms should be raised well above the head. The head can be supported with a pillow, and pads may be placed between the knees for the patient's comfort.

Exposure borders: The upper edge is above the shoulder, and the lower edge is at the level of the last rib; the lateral edges are approximately 3 centimeters lateral from the vertebrae

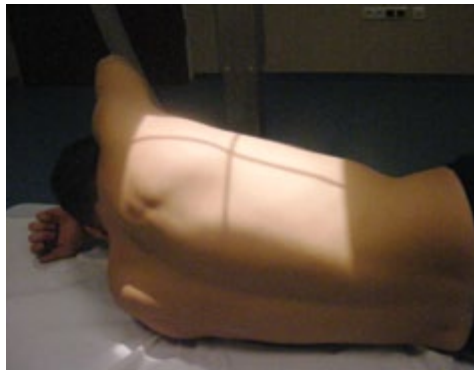

Figure 278.

Háti gerinc oldalirányú felvétel

- Th. I.–L. I. csigolyatestek, intervertebrális rések oldalnézetben elfordulás nélkül ábrázolódnak
- az intervertebrális foramenek nyitottan, egymásra vetülve ábrázolódnak
- L. I. csigolya látszódik a Th. XII-es csigolya biztosan nem naradt

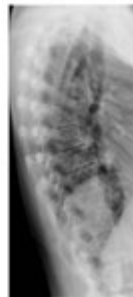


Figure 280.

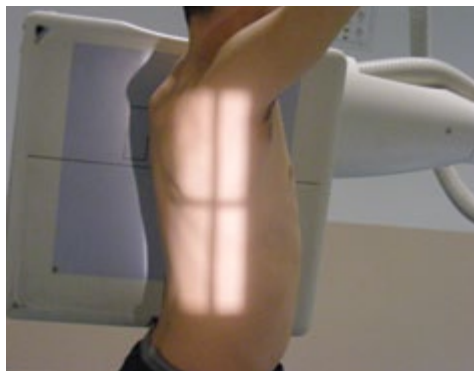

Figure 279.

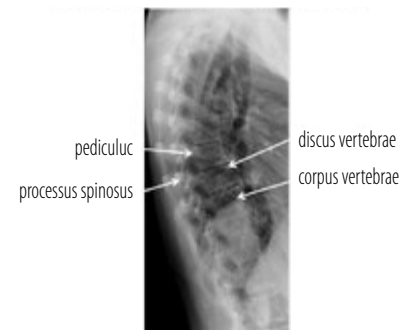
Háti gerinc oldalirányú felvétel

Figure 281.

Film or image size: 20 × 40 cm

Focus-film distance: 100 cm

Centering: to the center of the sternum, to the Th IV.

http://tamop.etk.pte.hu/tamop412A/Ke-palkotasi_gyakorlatok_tananyag/RTG/RTG_videok/36_hat_oldal_en.avi

(Figure 278.)

For the assessment of the physiological curvatures, we can image the patient in a standing position, too.

(Figure 279.)

Structure shown:

- vertebrae from Th. I–L I. without rotation
- superimposed, open intervertebral foramina
- Th. XII. is not left out
- vertebrae clearly seen through rib and lung shadows

(Figures 280–281.)

Thoracolumbar junction – AP

Patient positioning: The patient is positioned supine on the X-ray table, with the median sagittal plane perpendicular to the tabletop.

Exposure borders: The upper edge is above the xiphoid process by approx. 2 cm, and the lower edge is the iliac crest; the lateral edges are approximately 3 centimeters lateral from the vertebrae

Film or image size: 20 × 40 cm

Focus-film distance: 100 cm

Centering: below the xiphoid process by approx 2 cm

(Figure 282.)

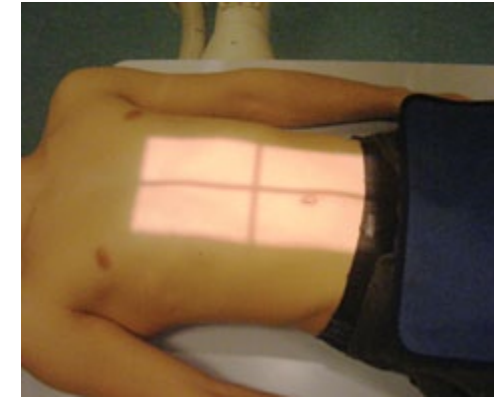


Figure 282.

Dorso-lumbalis átmenet AP felvétele

- Th. X–L. III. csigolyák közepén elfordulás nélkül ábrázolódnak

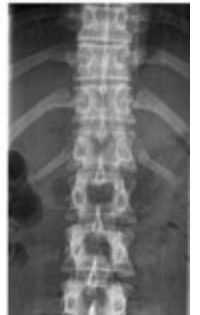

Figure 283.

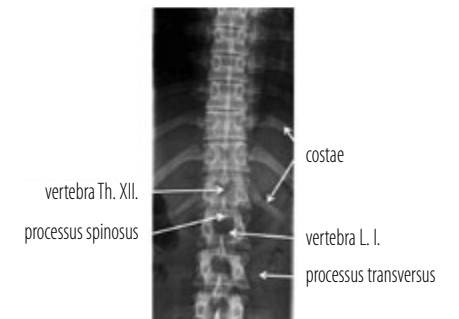Háti-ágyéki gerinc átmenet AP felvétele

Figure 284.

Structure shown:

- vertebrae from Th X.–L. III.
(Figures 283–284.)

Thoracolumbar junction – lateral

Patient positioning: Usually undertaken with the patient in the lateral decubitus position on the X-ray table, although this projection can also be performed erect. The median sagittal plane should be parallel to the cassette. The arms should be raised well above the head. The head can be supported with a pillow, and pads may be placed between the knees for the patient's comfort.

Exposure borders: The upper edge is above the xiphoid process by approx. 2 cm; the lower edge is the iliac crest, and the lateral edges are approximately 3 centimeters lateral from the the vertebrae

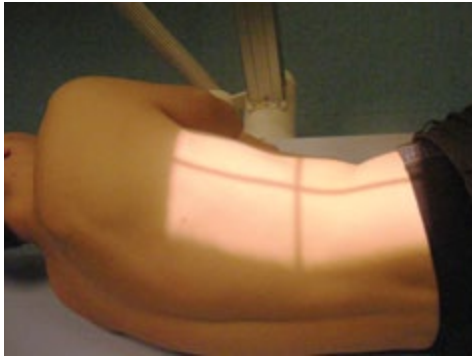


Figure 285.

Film or image size: 20 × 40 cm
Focus-film distance: 100 cm
Centering: below the xiphoid process by approx 2 cm, to the spine
(Figure 285.)

Structure shown:

- vertebrae from Th X.–L. III. without rotation
- superimposed, open intervertebral foramina
(Figures 286–87.)

Dorso-lumbalis átmenet oldalirányú felvétel

- a Th. X.–L. III. csigolyatestek, intervertebrális rések oldalnézetben elfordulás nélkül ábrázolódnak
- az intervertebrális forame-nek nyitottan, egymásra vetülve ábrázolódnak

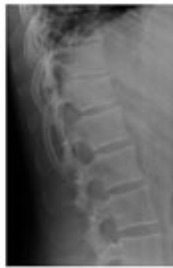

Figure 286.

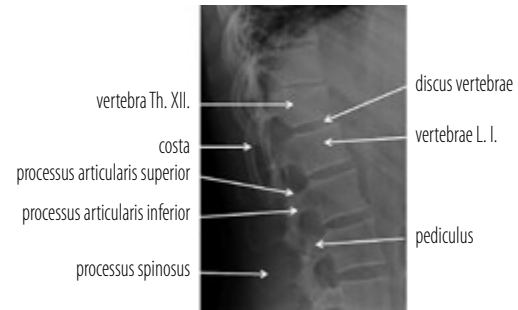
Háti-ágyéki gerinc átmenet oldalirányú felvétel

Figure 287.

L spine – AP

Patient positioning: The patient lies supine on the Bucky table, with the median sagittal plane coincident with, and at right-angles to, the midline of the table. The anterior superior iliac spines should be equidistant from the tabletop. The hips and knees are flexed and the feet are placed with their plantar aspect on the tabletop to reduce the lumbar arch and bring the lumbar region of the vertebral column parallel to the cassette.

Exposure borders: The upper edge is the xiphoid process; the lower edge is the iliac crest, and the lateral edges are approximately 3 centimeters lateral from the vertebrae

Film or image size: 20 × 40 cm

Focus-film distance: 100 cm

Centering: to the level of the iliac crest; to the L–IV spine

http://tamop.etk.pte.hu/tamop412A/Kepalkotasi_gyakorlatok_tananyag/RTG/RTG_videok/37_Lumb_AP_en.avi
(Figure 288.)

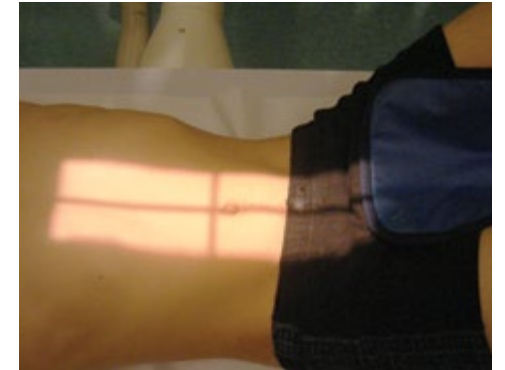

Figure 288.

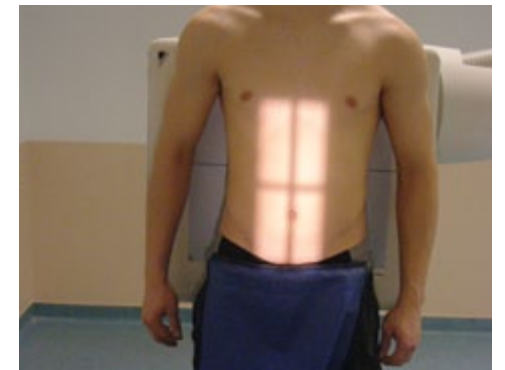

Figure 289.

For the assessment of the physiological curvatures, we can image the patient in a standing position, too.

(Figure 289.)

Structure shown:

- vertebrae from T XII.–S I. without rotation
- area from the lower thoracic vertebrae to the sacrum
- open intervertebral joints
- sacroiliac joints equidistant from the vertebral column

Ágyéki gerinc AP felvétele

- ábrázolódnak Th. XII.–S. I. csigolya
- a lumbalis csigolyák elfordulás nélkül a középvonalban ábrázolódnak (processus spinosusok a csigolyatestek középvonalába vetülnek, a processus transversusok egyforma hosszúak)
- oldaljelzés

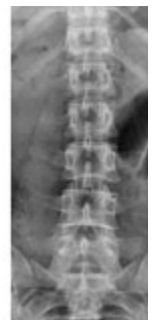

Figure 290.

- symmetric vertebrae, with spinous processes centered to the bodies
 - side mark
- (Figures 290–291.)

L spine – lateral

Patient positioning: The patient lies on either side on the table. The arms should be raised and resting on the pillow in front of the patient's head. The knees and hips are flexed for stability. The coronal plane running through the centre of the spine should coincide with, and be perpendicular to, the midline of the cassette.

Exposure borders: The upper edge is the xiphoid process, and the lower edge is the iliac crest; the lateral edges are the regions next to the vertebrae

Film or image size: 20 × 40 cm

Focus-film distance: 100 cm

Centering: to the level of the iliac crest

http://tamop.etk.pte.hu/tamop412A/Kepalkotasi_gyakorlatok_tananyag/RTG/RTG_video/38_lumb_oldal_en.avi
(Figure 292.)

For the assessment of the physiological curvatures, we can image the patient in a standing position, too.

(Figure 293.)

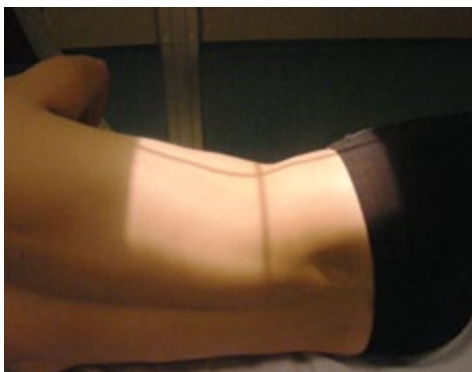

Figure 292.

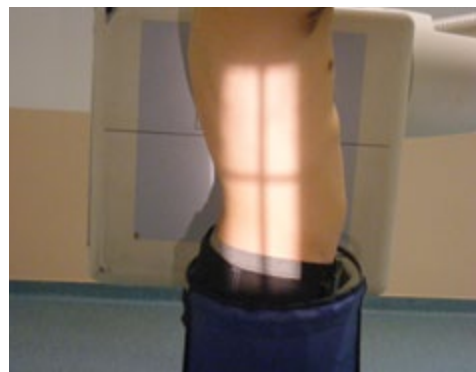

Figure 293.

Ágyéki gerenc AP felvétele

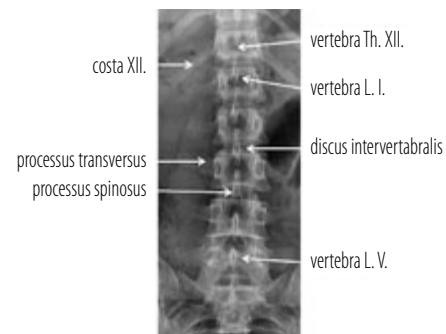


Figure 291.

Ágyéki gerinc oldalirányú felvétele

- a csigolyatestek processus spinosusok oldalnézetben elfordulás nélkül ábrázolódnak
- csigolya közti rések jól látszódnak
- felső négy intervertebralis foramen nyitott és egymást fedi

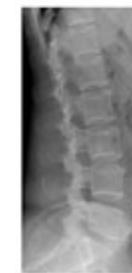

Figure 294.

Ágyéki gerinc oldalirányú felvétele

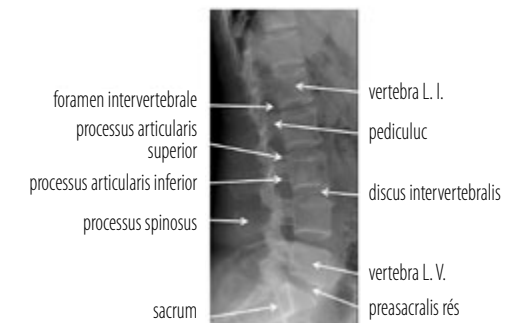

Figure 295.

Structure shown:

- vertebrae, and spinous processes without rotation
- open intervertebral disk spaces
- the top four intervertebral foramina are open and superimposed

(Figure 294–295.)

(Figure 296. Pathology)

Thoracic and lumbar scoliosis

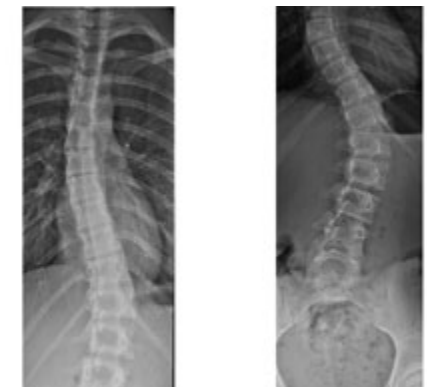

Figure 296.

L spine – oblique (dittmar)

With this technique we can assess the intervertebral joints. If the patient is positioned correctly, the small joints resemble a "Scottie dog" shape. The following can cause error: rotation is not accurate, and the angle of the pelvis and the back is not the same.

Patient positioning: The patient is positioned supine on the Bucky table and is then rotated 45 degrees to the right and left sides in turn. The patient's arms are raised, with the hands resting on the pillow. The hips and knees are flexed and the patient is supported with a 45-degree foam pad placed under the trunk on the raised side.

Exposure borders: The upper edge is the xiphoid process; the lower edge is the iliac crest, and the lateral edges are approximately 3 centimeters lateral from the vertebrae

Film or image size: 20 × 40 cm

Focus-film distance: 100 cm

Centering: to the level of the iliac crest

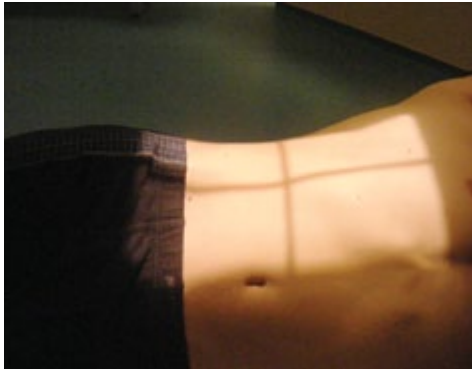


Figure 297.

Ágyéki gerinc ferde síkú Dittmár felvétele

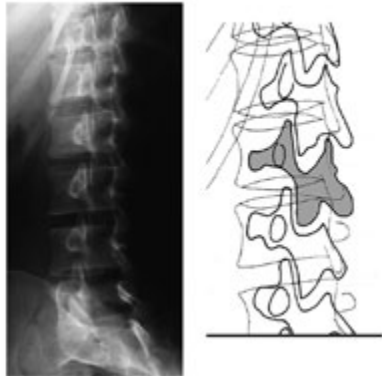
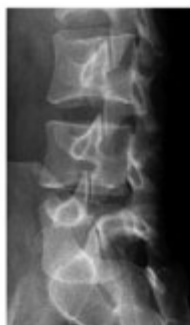
Figure 299.

Ágyéki gerinc ferde síkú Dittmár felvétele



„kutya” orra: proc. transversus
szeme: arcus gyöke
füle: proc. articularis sup.
mellső lába: proc. articularis inf.
teste: arcus vertebrae
farka: proc. spinosus
hátsó lába: proc. art. Inf.
(filmtől távolabb)

Figure 300.

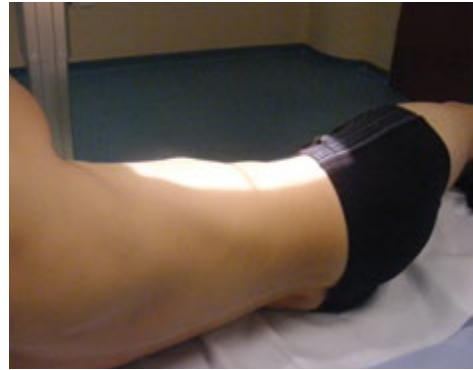

Figure 298.

Small joints closest to the cassette side are visualized.

Side mark.

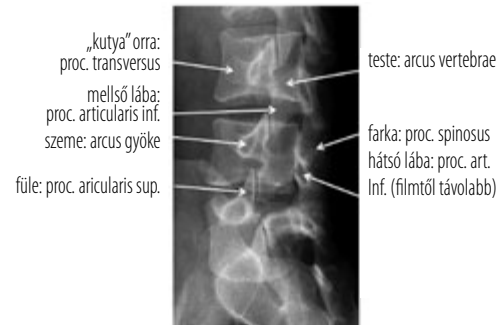
(Figures 297–298.)

Structure shown:

- dogs' nose: transverse process
- eye: pedicle
- ear: superior articular process
- forelegs: inferior articular process
- body: arcus vertebrae
- tails: spinous process
- hind legs: inferior articular process

(Figures 299–301.)

Ágyéki gerinc ferde síkú Dittmár felvétele



„kutya” orra: proc. transversus
szeme: arcus gyöke
füle: proc. articularis sup.
mellső lába: proc. articularis inf.
teste: arcus vertebrae
farka: proc. spinosus
hátsó lába: proc. art. Inf.
(filmtől távolabb)

Figure 301.

Lumbosacral junction – lateral

Patient positioning: The patient lies on either side on the Bucky table, with the arms raised and the hands resting on the pillow. The knees and hips are flexed slightly for stability. The dorsal aspect of the trunk should be at right-angles with the cassette.

Exposure borders: The upper edge is the iliac crest; the lower and the lateral edges are approximately 3 centimeters lateral from the vertebrae

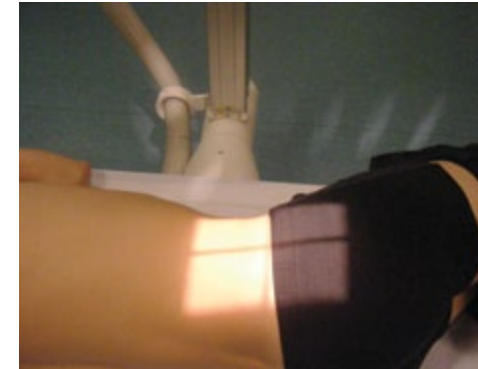

Figure 302.

Film or image size: 20 × 30 cm
Focus-film distance: 100 cm
Centering: below the iliac crest by approx. 3 cm
(Figure 302.)

Structure shown:

- LV.–S I. junction in lateral and open position
- the upper part of the sacrum and L V. visualized
(Figures 303–304.)

Lumbosacralis átmenet oldalirányú felvétele

- az L. V.–S. I. átmenet elfordulás nélkül, nyitottan ábrázolódik
- az L. V. és sacrum felső része ábrázolódik

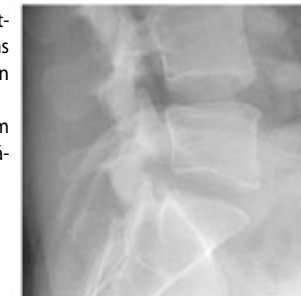

Figure 303.

Lumbosacralis átmenet oldalirányú felvétele

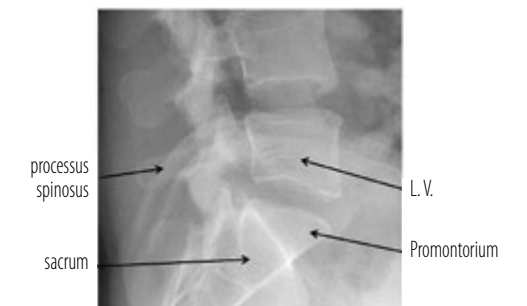


Figure 304.

Sacrum-coccygum – AP

Patient positioning: The patient lies supine on the Bucky table, with the median sagittal plane coincident with, and at right-angles to, the midline of the cassette.

Exposure borders: The upper edge is the iliac crest; the lower edge is below the symphysis, and the lateral edges are approximately 3 centimeters lateral from the vertebrae

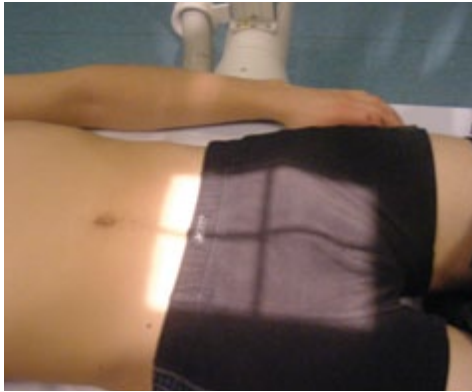

Figure 305.

Film or image size: 20 × 30 cm

Focus-film distance: 100 cm

Centering: through the lumbosacral joint at an average angle of 15 degrees; the central ray enters above the symphysis
(Figures 305–306.)

Sacrum-coccygeum – lateral

Patient positioning: The patient lies on either side of the Bucky table, with the

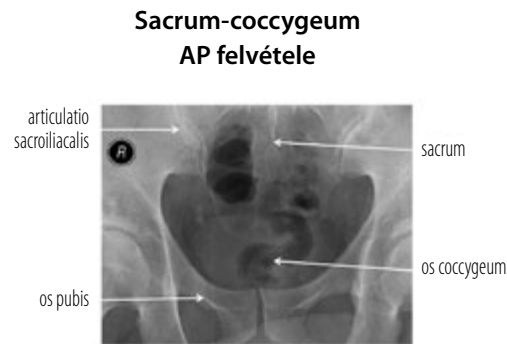


Figure 306.

Sacrum-coccygeum oldalirányú felvétele

- a sacrum és a farokcsont elfordulás nélkül oldalhelyzetben ábrázolódnak

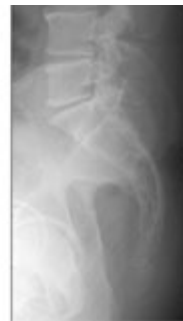

Figure 308.

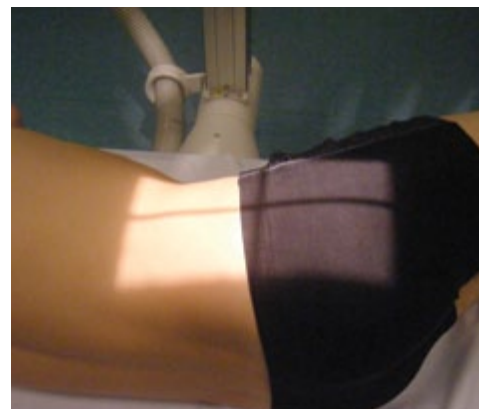

Figure 307.

Sacrum-coccygeum oldalirányú felvétele

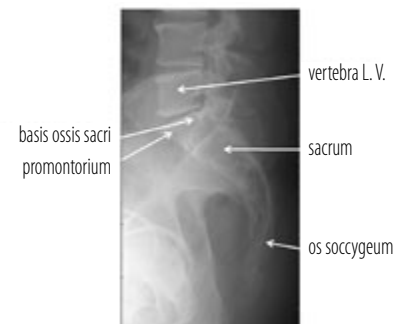

Figure 309.

arms raised and the hands resting on the pillow. The knees and hips are flexed slightly for stability. The dorsal aspect of the trunk should be at right-angles with the cassette.

Exposure borders: The upper edge is the iliac crest; the lower edge is below the symphysis, and the lateral edges are approximately 3 centimeters lateral from the vertebrae

Film or image size: 20 × 30 cm

Focus-film distance: 100 cm

Centering: to the center of the detector
(Figure 307.)

Structure shown:

- sacrum and coccygeum in lateral position without rotation
(Figures 308–309.)

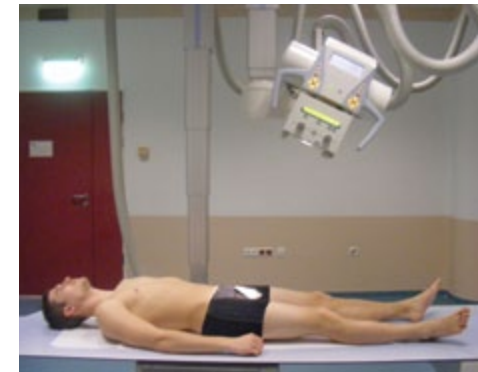

Figure 310.

Sacroiliacalis ízület felvétele

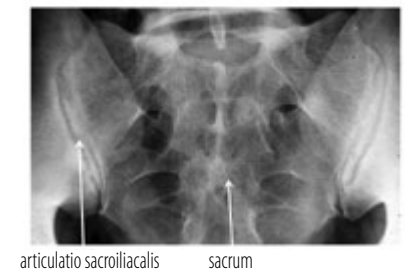

Figure 312.

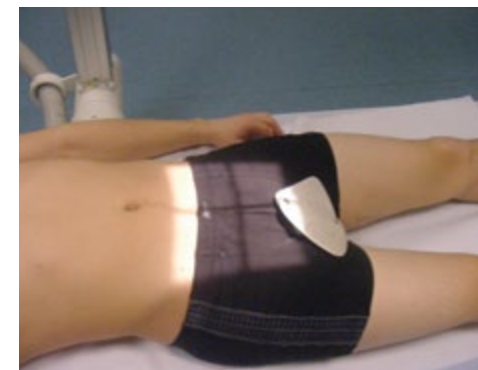

Figure 311.

Sacroiliacalis ízület betekintő AP felvétele

- L. V.–S. I. ízület jól ábrázolódnak

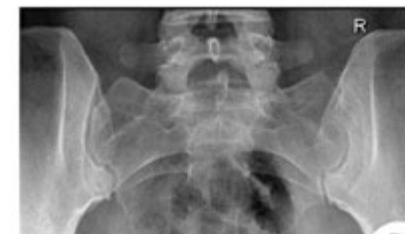

Figure 313.

Sacroiliac joint – oblique

Patient positioning: The patient lies supine on the Bucky table, with the median sagittal plane coincident with, and at right-angles to, the midline of the table. The anterior superior iliac spines should be equidistant from the tabletop.

Exposure borders: The upper edge is below the iliac crest; the lower edge is the symphysis, and the lateral edges are the anterior superior iliac spines

Film or image size: 20 × 40 cm

Focus-film distance: 100 cm

Centering: through the lumbosacral joint at an average angle of 25-35 degrees; the central ray enters above the symphysis

(Figures 310–311.)

Structure shown:

- L V.–S I. joint well visualized

(Figures 312–313.)

III.8. X-ray anatomy and imaging technique of the bony chest and respiratory system

Bony chest

The bony thorax is formed by the sternum, 12 pairs of ribs, and 12 thoracic vertebrae.

The 12 pairs of **ribs** are numbered consecutively from superior to inferior. The rib number corresponds to the thoracic vertebra to which it attaches.

- 7 pairs of ribs are attached directly to the sternum – true ribs
- 5 pairs of ribs are attached indirectly to the sternum – false ribs
- 2 pairs of ribs are not attached to the sternum – floating ribs

Each rib is a long, narrow, curved bone with an anteriorly attached piece of hyaline cartilage, the costal cartilage. A typical rib consists of

- a head, which is attached to the vertebra (capitulum costae)
- a flattened neck (collum)
- a tubercle, which is attached to the transverse process (tuberculum costae)
- a body (corpus costae)

The **sternum**, or breastbone, is directed anteriorly and inferiorly and is centered over the midline of the anterior thorax. A narrow, flat bone, the sternum consists of three parts: manubrium, body, and xiphoid process. The sternum supports the clavicles at the superior manubrial angle and provide attachment to the costal cartilages of the first seven pairs of ribs at the lateral borders. The manubrium, the superior portion of the sternum, is quadrilateral in shape and is the widest portion of the sternum. At its center the superior border of the manubrium has an easily palpable concavity termed the jugular notch. The manubrium slant laterally and posteriorly on each side of the jugular notch, and an oval articular facet called the clavicular notch articulates with the sternal extremity of the clavicle. The body is the longest part of the sternum and is joined to the manubrium at the sternal angle. The xiphoid process is the distal and smallest part of the sternum.

Surface anatomy of the bony chest:

The ribs and the parts of the sternum are easily palpated.

Ribs

Lower and upper ribs should be imaged separately due to X-ray attenuating differences. Depending on the indication, we can image the ventral or posterior arch of the ribs in either AP or PA positions.

Ribs – whole right/left

Patient positioning: The patient's position depends on which arch of the ribs needs to be visualized. For imaging the ventral arches, the patient stands in front the vertical grid device or lies in a prone position on the table; for imaging the posterior arches, the patient puts his back against the stand or he lies supine on the table. The patient rotates slightly on to the affected side. The imaginary line between the median sagittal line and the lateral side of the patient is in the center of the table.

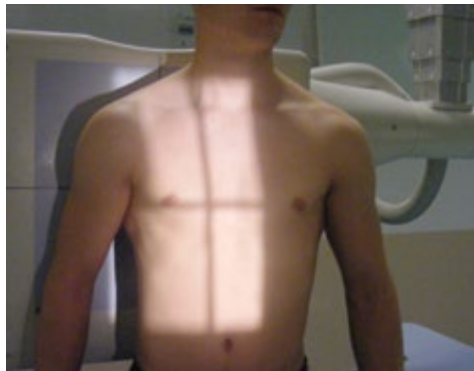

Figure 314.

Teljes jobb vagy baloldali bordák

- a 12 pár borda azonos denzitással ábrázolódnak

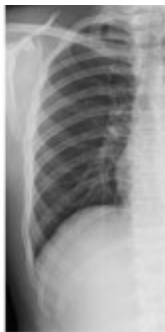

Figure 315.

Exposure borders: The upper edge is above the shoulder by approx. 1 cm; the lower edge is the iliac crest, and the lateral edges are the soft tissues.

Film or image size: 30 × 40 cm

Focus-film distance: 100 cm

Centering: the center of the detector

Patient Instructions: breath hold

http://tamop.etk.pte.hu/tamop412A/Kepalkotasi_gyakorlatok_tananyag/RTG/RTG_videok/39_borda_PA_en.avi

(Figure 314.)

Teljes jobb és bal borda felvétele

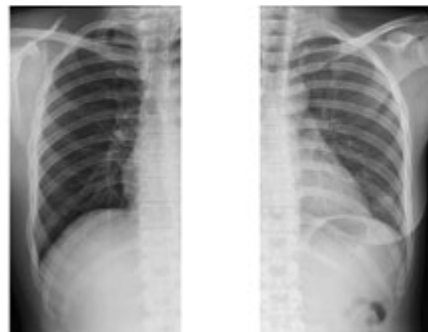


Figure 316.

Structure shown:

- 12 pairs of ribs of the same density
(Figures 315., 316.)

Upper ribs

Patient positioning: The patient's position depends on which rib arch has to be visualized. If the front arches need to be imaged, the patient stands in front of the vertical grid device or lies prone on the table; for imaging the posterior arches, the patient stands with his back against the stand or lies supine on the table. The patient rotates slightly on to the affected side. The center line between the median sagittal line and the patient's lateral side is in the center of the table.

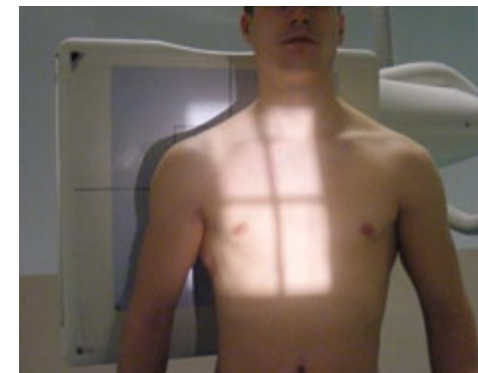

Figure 317.

Exposure borders: The upper edge is above the shoulder by approx. 1 cm; the lower edge is the xiphoid process, and the lateral edges are the soft tissues and the median sagittal plane.

Film or image size: 24 × 30 cm

Focus-film distance: 100 cm

Centering: the center of the detector

Patient Instructions: full inspiration

http://tamop.etk.pte.hu/tamop412A/Kepalkotasi_gyakorlatok_tananyag/RTG/RTG_videok/40_felsoborda_AP_en.avi

(Figures 317–319.)

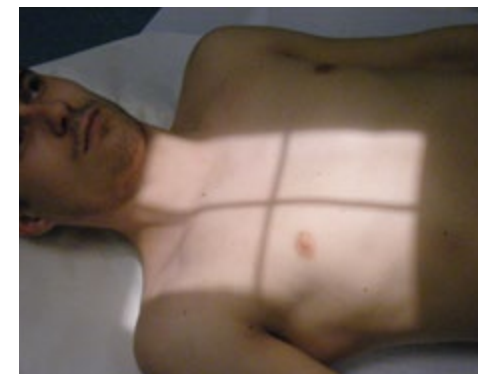

Figure 318.

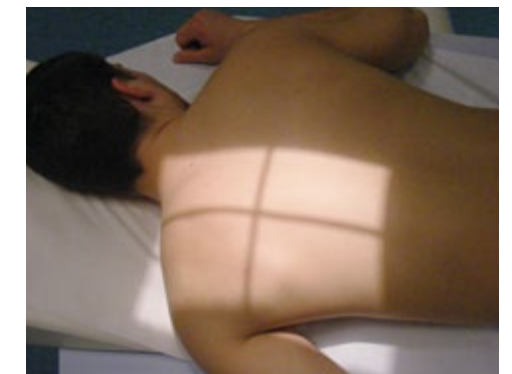

Figure 319.

Felső bordák felvétele

- a mellkas régióban ábrázolódjon az első nyolc pár borda
- bordák a tüdőtől jól elkülönüljenek

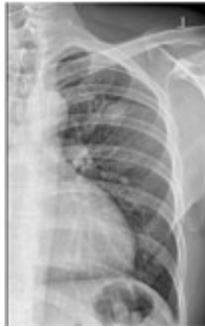

Figure 320.

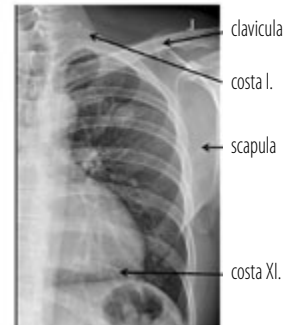Bal felső borda felvétel

Figure 321.

Structures shown:

- first through eighth ribs in their entirety, with the posterior portions lying above the diaphragm
- the ribs are separated from the lung (Figures 320., 321.)

Lower ribs

Patient positioning: The patient's position depends on which rib arch has to be visualized. If the front arches are imaged, the patient stands erect in front of the vertical grid device or lies prone on the table; for imaging the posterior arches, the patient stands with his back against the stand or lies supine on the table. The patient rotates slightly on to the affected side. The center line between the median sagittal and the patient's lateral side is in the center of the table.

Exposure borders: The upper edge is the middle of the sternum, and the lower edge is below the lower ribs; the lateral edges are the soft tissues and the median sagittal plane.

Film or image size: 24 × 30 cm

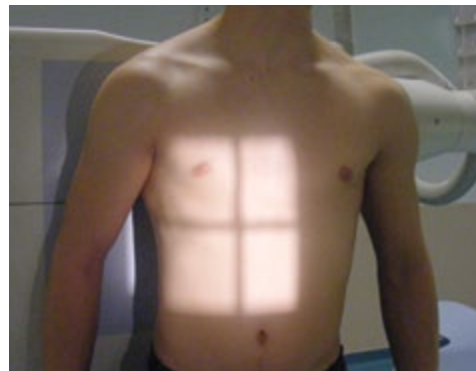


Figure 322.

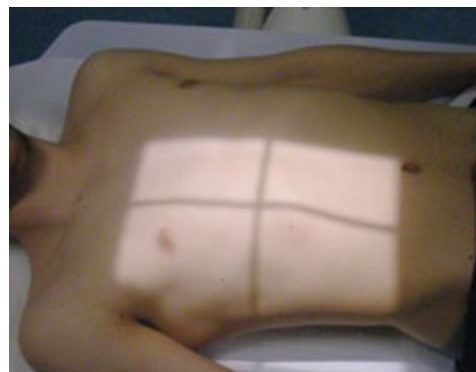

Figure 323.

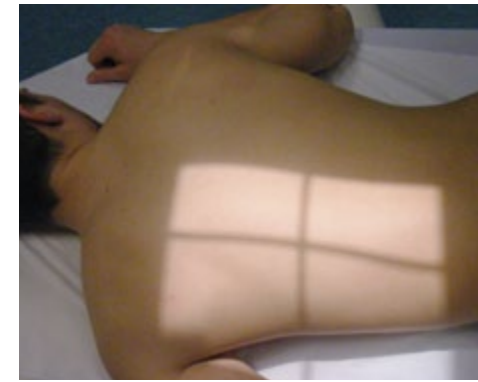

Figure 324.

Focus-film distance: 100 cm

Centering: the center of the detector

Patient Instructions: full expiration
http://tamop.etk.pte.hu/tamop412A/Kepalkotasi_gyakorlatok_tananyag/RTG/RTGvideok/41_alsoborda_AP_en.avi
 (Figures 322–324.)

Structures shown:

- for ribs below the diaphragm, seventh through twelfth posterior ribs
- ribs visible through the lungs or abdomen (Figures 325., 326.)

Alsó bordákfelvétele

- a mellkas alsó és a has-felső régiójában VIII–XII. bordapár ábrázolódjon
- a bordák a mellkas alsó, illetve a has felső részében lévő struktúráktól jól elkülönüljenek

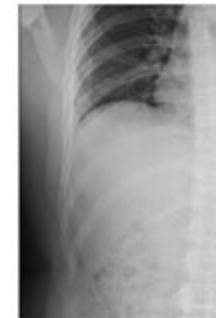

Figure 325.

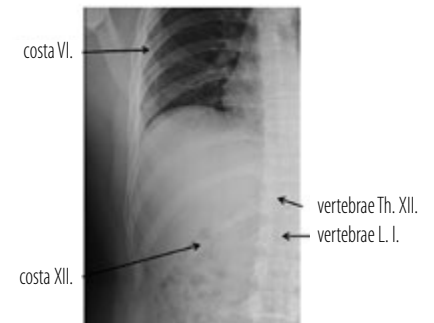
Jobb alsó AP borda felvétel

Figure 326.

Ribs – PA oblique (right and left)

Patient positioning: The patient sits or stands erect facing the vertical grid device. Alternatively, the patient lies prone on the table. The mid-clavicular line of the side under examination should coincide with the central line of the table. The trunk is rotated 45 degrees towards the side being examined. The affected arm is lifted up.

Exposure borders: For upper ribs (I.–VII.): The upper edge is above the shoulder by approx. 1 cm, and the lower edge is the xiphoid process, while the lateral edges are the soft tissues and the median sagittal plane. For lower ribs (VIII.–XII.): The upper edge is the middle of the sternum, and the lower edge is below the lower ribs, while the lateral edges are the soft tissues and the median sagittal plane.

Film or image size: 30 × 40 cm

Focus-film distance: 100 cm

Centering: For upper ribs: to the VI. vertebra; For lower ribs: to the X. vertebra

Patient Instructions: full inspiration (upper ribs); full expiration (lower ribs)

(Figure 327.)

Structures shown:

- For upper ribs:
 - first through eighth rib in their entirety, with the posterior portions lying above the diaphragm
- the ribs separated from the lung
- For lower ribs:
 - for ribs below the diaphragm, seventh through twelfth posterior ribs
- ribs visible through the lungs or abdomen

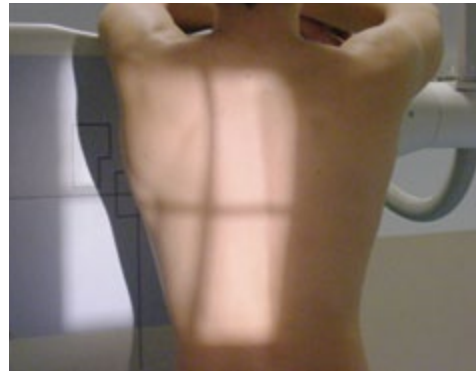

Figure 327.

Ribs – AP oblique (right and left)

Patient positioning: The patient sits or stands with his back against the vertical grid device. Alternatively, the patient lies supine on the table. The mid-clavicular line of the side under examination should coincide with the central line of the table. The trunk is rotated 45 degrees towards the side being examined. The affected arm is lifted up.

Exposure borders: For upper ribs (I.–VII.): The upper edge is above the shoulder by approx. 1 cm, and the lower edge is the xiphoid process, while the lateral edges are the soft tissues and the

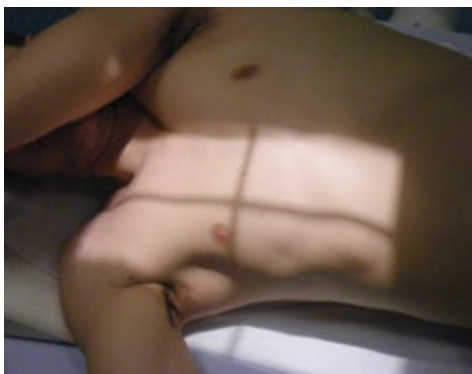


Figure 328.

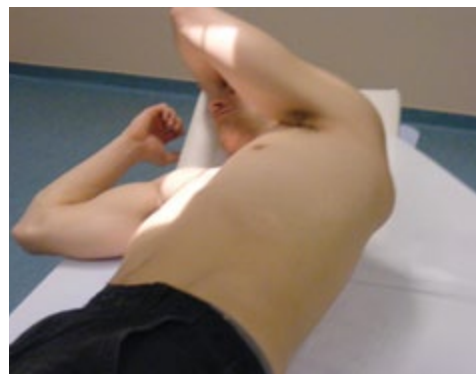

Figure 329.

median sagittal plane. For lower ribs (VIII.–XII.): The upper edge is the middle of the sternum, and the lower edge is below the lower ribs, while the lateral edges are the soft tissues and the median sagittal plane.

Film or image size: 30 × 40 cm

Focus-film distance: 100 cm

Centering: For upper ribs: to the VI. vertebra; For lower rib: to the X. vertebra

Patient Instructions: full inspiration (upper ribs); full expiration (lower ribs)

(Figure 327.)

Structures shown:

- For upper ribs:
 - first through eighth rib in their entirety, with the posterior portions lying above the diaphragm
- the ribs are separated from the lung
- For lower ribs:
 - for ribs below the diaphragm, seventh through twelfth posterior ribs
- ribs visible through the lungs or abdomen

Sternum – lateral

Patient positioning: The patient sits or stands, with either shoulder against a vertical grid device. The median sagittal plane of the trunk is adjusted parallel to the cassette. The sternum is centred to the cassette or Bucky table. The patient's hands are clasped behind the back and the shoulders are pulled well back.

Exposure borders: The upper edge is above the jugulum by approx. 1 cm, and the lower edge is below the xiphoid process by approx 2 cm, while the lateral edges are the soft tissues.

Film or image size: 24 × 30 cm

Focus-film distance: 100 cm

Centering: to the center of the sternum

http://tamop.etk.pte.hu/tamop412A/Kepalkotasi_gyakorlatok_tananyag/RTG/RTG_video/42_sternum_oldal_en.avi

(Figure 330.)

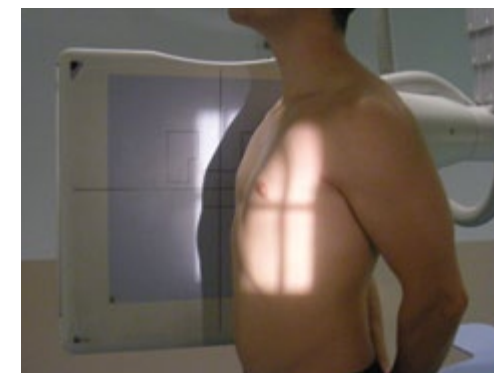

Figure 330.

Szegycsont oldalirányú felvétele

- a sternum jól látható legyen teljes egészében a manubriumtól a processus xyphoideusig
- a bordák nem vetülnek rá
- a manubriumra nem vetül rá a váll




Figure 331.

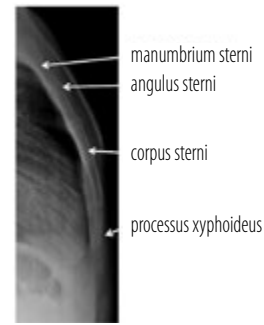
Szegycsont oldalirányú felvétele

Figure 332.

Structures shown:

- lateral image of the sternum in its entirety
- sternum free of superimposition by the shoulders or arms
- sternum free of superimposition by the ribs

(Figures 331., 332.)

Fracture of the sternum

(Figure 333. Pathology)

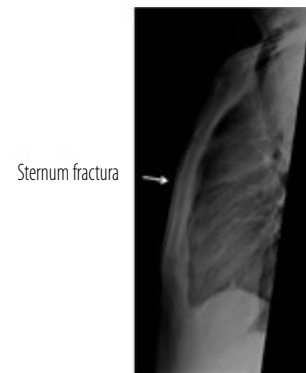

Figure 333.

Respiratory system

The thoracic cavity is bounded by the walls of the thorax and extends from the superior thoracic aperture, where structures enter the thorax, to the inferior thoracic aperture.

The **lungs** are composed of a light, spongy, highly elastic substance, the parenchyma, and they are covered by a layer of serous membrane. The lung is divided into two parts. The right side is composed of 3 lobes; the left side is composed of 2 lobes. The anatomical units of the lobes are the segments. Each part of the lung is made up of 10-10 segments. Both lungs present a rounded apex that reaches above the level of the clavicles into the root of the neck and a broad base that, resting on the obliquely placed diaphragm, reaches lower in back and at the side than in front. The lateral surface of each lung conform with the shape of the chest wall. The inferior surface of the lung is concave, fitting over the diaphragm, and the lateral margins are thin. During respira-

tion the lungs move inferiorly for inspiration and superiorly for expiration. During inspiration the lateral margins descend into the deep recesses of the parietal pleura. In radiology this recess is called the costophrenic angle (this is the region where pleural fluid first appears). Each lung is enclosed in a double walled, serous membrane sac called the pleura. The inner layer of the pleural sac, called the visceral pleura, closely adheres to the surface of the lung, extends into the interlobar fissures (not visible on x-ray images, only in case of pleural fluid), and is continuous with the outer layer at the hilum. The outer layer, called the parietal pleura, lines the wall of the thoracic cavity occupied by the lung and closely adheres to the upper surface of the diaphragm. The two layers are moistened by serous fluid so that they move easily on each other. Thus the serous fluid prevents friction between the lungs and chest wall during respiration. The space between the two pleural walls is called the pleural cavity and in the pleural cavity there is vacuum. If air gets into the cavity, the vacuum ceases and a pneumothorax (PTX) develops while the lung collapses.

The **trachea** lies in the midline of the body, anterior to the esophagus in the neck.

At the carina the trachea divides, or bifurcates, into two lesser tubes, the primary bronchi. One of these bronchi enters the right lung, and the other enters the left lung. The left primary bronchi forms a 100 degree angle with the horizontal, while the right bronchi runs down continuously. This is why most foreign bodies get jammed frequently in the right bronchus. The bronchi continue dividing into tertiary bronchi, then to smaller bronchioles, and end in minute tubes called the terminal bronchioles. The terminal bronchiole communicate with alveolar ducts.

The mediastinum is the area of the thorax bounded by the sternum anteriorly, the spine posteriorly, and the lung laterally. The mediastinum is divided into anterior and posterior part by trachea.

The heart, thymus, superior and inferior vena cava, aortic arch are in the anterior mediastinum.

The esophagus, lymphatic vessels, vagus nerve and descend aorta are in the posterior mediastinum.

The mediastinal shadow is formed by the respiratory tract, the heart and the major blood vessels.

The structures of the lung hila are the pulmonary arteries and veins, the bronchial arteries and veins, the main bronchus, lymph nodes and lymph vessels, and nerves.

X-ray examination of the lungs is the basic test method for chest diseases.

Indications: inflammation of the lungs, cancer, pneumothorax, thoracic fluid, pulmonary vascular lesions, heart diseases.

The images are always taken in full inspiration except when there is a pneumothorax, because in this case, the images are taken in full expiration. Hard beam technique (100-125 KV, low mAs) is applied, so that the ribs become transparent and thus do not interfere with the assessment of the lungs.

Chest – PA (standing position)

Patient positioning: The patient is positioned facing the vertical grid device, with the chin extended and centred to the middle of the top of the cassette. The feet are placed slightly apart so that the patient is able to remain steady. The median sagittal plane is adjusted at right-angles to the middle of the cassette. The shoulders are rotated forward and pressed downward in contact with the cassette. This is achieved by placing the dorsal aspect of the hands behind and below the hips, with the elbows brought forward, or by allowing the arms to encircle the cassette.

Exposure borders: The upper edge is above the shoulder by approx. 1 cm, and the lower edge is the iliac crest, while the lateral edges are the soft tissues.

Film or image size: 35 × 43 cm

Focus-film distance: 150-200 cm

Centering: level of the inferior angle of the scapula, to the center of the detector

Patient Instructions: full inspiration

http://tamop.etk.pte.hu/tamop412A/Ke-palkotasi_gyakorlatok_tananyag/RTG/RTG_videok/43_mellkas_PA_en.avi

(Figure 334.)

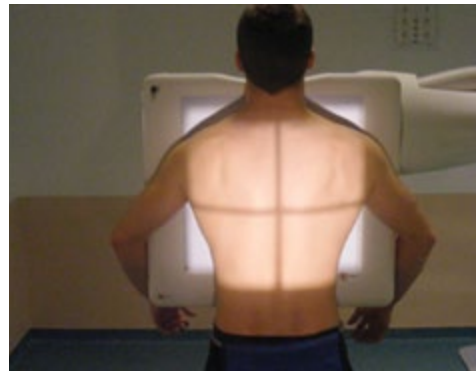

Figure 334.

Structures shown:

- sharp outline of the heart and diaphragm, without moving artefacts
- no rotation of the heart and lungs
- ten posterior ribs visible above the diaphragm

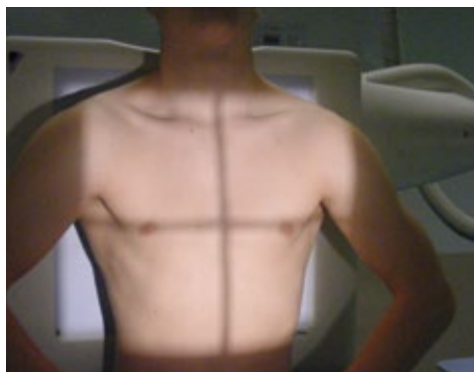


Figure 335.

Mellkas PA/AP felvétel

- a teljes tüdő mozgási műtermékektől mentesen ábrázolódik
- a tüdő és a szív elfordulás nélkül ábrázolódik
- a tíz pár borda hátsó íve a rekesz fölé vetül
- a scapulák nem vetülnek a tüdőre
- a tüdő optimális kontraszttal és megfelelő expozíciós értékkel ábrázolódik
- a trachea légsáv általában a gerincoszlop középvonalára vetül

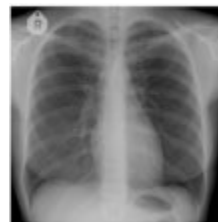

Figure 336.

- scapulae projected outside the lung fields
- optimal contrast and exposure value
- trachea visible in the midline

(Figures 335., 336.)

Chest – AP

Patient positioning: For sick patients we have to take the x-ray image in a lying or a sitting position with the patient's back against the cassette. The median sagittal plane is at the middle of the cassette. The shoulders are brought downward. The arms are rotated laterally and supported by the side of the trunk.

Exposure borders: The upper edge is above the shoulder by approx. 1 cm, and the lower edge is the iliac crest, while the lateral edges are the soft tissues.

Film or image size: 35 × 43 cm

Focus-film distance: 150-200 cm

Centering: to the center of the sternum

Patient Instructions: full inspiration

(Figure 337.)

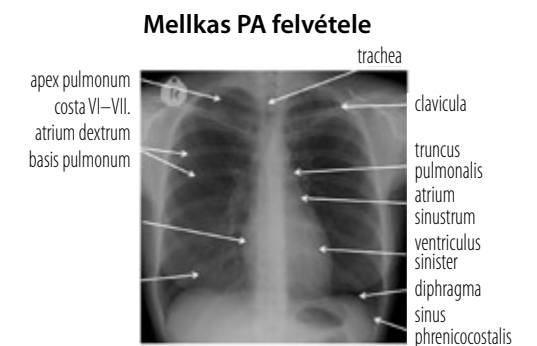


Figure 337.

Healthy AP-PA chest x-ray images: The diaphragm is sharply bounded, on the right hand side it is higher by approx. 1cm. During full inspiration the lateral margins of the lung descend into the phrenicocostal angle, thus the sinuses open up. When the lungs fill with air, they become transparent, and blood vessels are recognizable.

Chest – lateral

Patient positioning: The patient is turned to bring the side under investigation in contact with the cassette. The median sagittal plane is adjusted parallel to the cassette. The arms are folded over the head or raised above the head to rest on a horizontal bar. The mid-axillary line is coincident with the middle of the film.

Exposure borders: The upper edge is above the shoulder by approx. 1 cm, and the lower edge is the iliac crest, while the lateral edges are the soft tissues.

Film or image size: 35 × 43 cm

Focus-film distance: 150-200 cm

Centering: to the mid-axillary line at the level of the sternum

Patient Instructions: full inspiration
http://tamop.etk.pte.hu/tamop412A/Ke-palkotasi_gyakorlatok_tananyag/RTG/RTG_videok/44_mellkas_frontal_en.avi
 (Figure 338.)

Structures shown:

- superimposition of the ribs posterior to the vertebral column
- long axis of the lung fields demonstrated in vertical position, without rotation
- visible costophrenic angles and the lower apices of the lungs

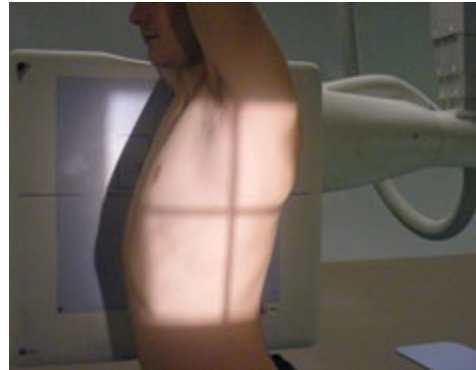

Figure 338.

Mellkas oldalirányú felvétele

- a sternum oldalnézetben ábrázolódik
- a csúcsi és felső tüdőrészek, a costophrenicus szögletek jól láthatók
- a tüdő, szív, rekesz éles határokkal ábrázolódik
- a hátsó bordarészek a gerincoszlopra vetülnek
- oldaljelzés (film közelit!)

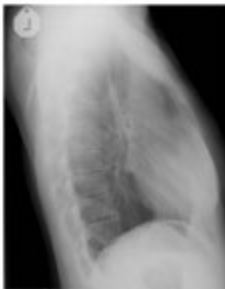


Figure 339.

Mellkas oldalirányú felvétele

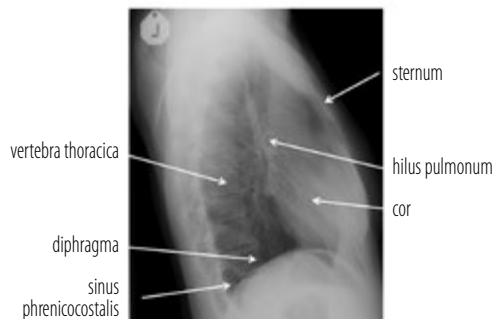


Figure 340.

Jobb oldali tüdő consolidatio

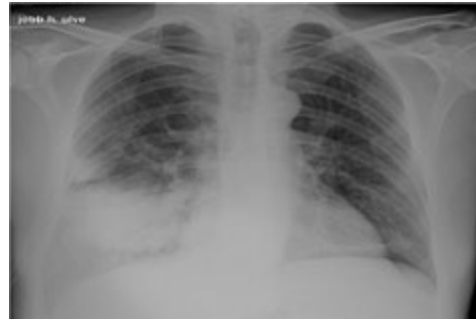

Figure 341.

Bullosus emphysema: tönkrement alveolusok helyén képződő, vékony falú üregek

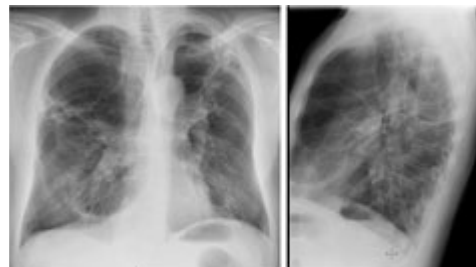


Figure 342.

A jobb középső alsó lebenyben masszív, foltos, köteges tüdőconsolidatio

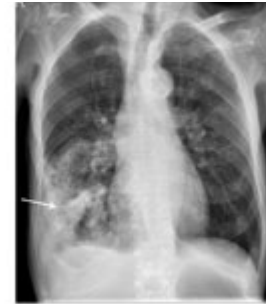
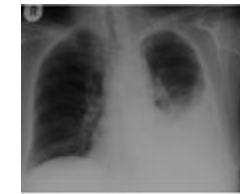
Figure 343.



Folyadék bal oldalon

Mellkas csapolás után kontroll felvétel

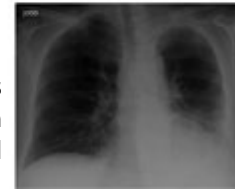

Figure 344.

- sharp outlines of the heart and diaphragm
 - side mark (closest to the cassette)
- (Figures 339–344.)

Apices

Patient positioning: The patient sits or stands with his back against the vertical grid device and in front of it by approx. 30 cm. Have the patient lean backward in a position of extreme lordosis and rest the shoulders against the vertical grid device.

Exposure borders: The upper edge is above the shoulder by approx. 1 cm, and the lower edge is the sternal angle, while the lateral edges are the soft tissues.

Film or image size: 24 × 30 cm

Focus-film distance: 150 cm

Centering: to the center of the sternum

Patient Instructions: If the patient is unable to lean backward, the tube is angled 30 degrees in caudo-cranial position. Centering is to the jugulum.
 (Figure 345.)

Structures shown:

- clavicle lying superior to the apices

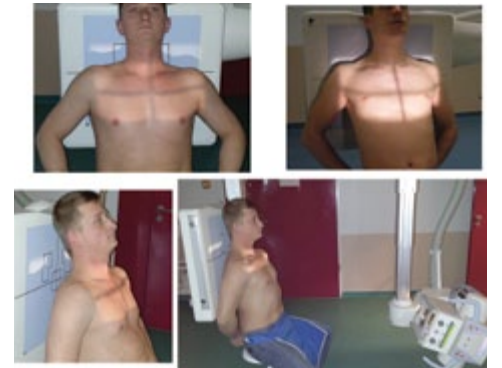

Figure 345.

Kivetített tüdőcsúcs felvétel

- a tüdőcsúcsok jól ábrázolódnak a clavikulák rávetülése nélkül
- a bordák torzultan ábrázolódnak, elülső és hátsó ívük kissé egymásra vetül
- a gerincoszlop a felvétel középvonalában van

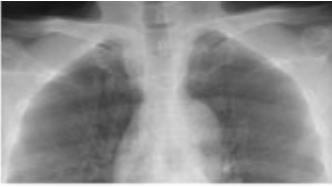


Figure 346.

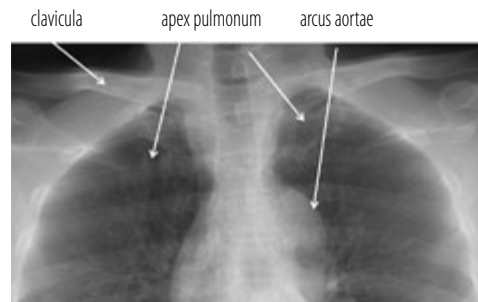Kivetített tüdőcsúcs felvétel

Figure 347.

- ribs distorted with their anterior and posterior portion somewhat superimposed
 - spine at center of the image
- (Figures 346., 347.)

Wards, on-site x-ray images: For sick patients, in bad general conditions, who can not be transported to the radiology department. In the ward we have to make an effort to set the highest focus-film distance as possible, because in most cases we cannot achieve the optimal 150-200 cm. When imaging pleural fluid, if possible, the patient should be in a sitting position. If he is supine, pleural fluid spreads out, and its volume can not be assessed.

(Figure 348.)

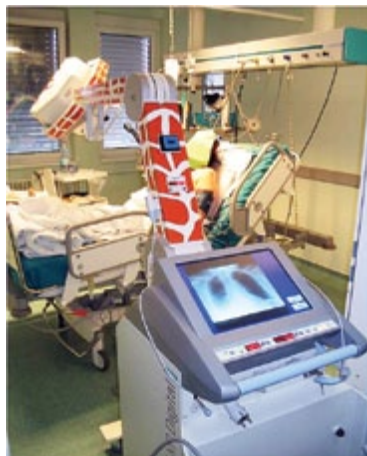

Figure 348.



Figure 348 a



Figure 348 b

Chest fluoroscopy can be performed in addition to conventional x-ray images. We can visualize motion and locate lesions in space. Scarce amounts of pleural fluid can be detected, too.

When imaging neonates and infants, the hanging position is the best, by using the necessary tools. Gonadal protection is very important.

(Figures 348 a., b.)

III.9. X-ray anatomy and imaging technique of the skull

The **skull** rests on the superior aspect of the vertebral column. It is made up of 22 separate bones divided into two distinct groups: 7 cranial bones and 14 facial bones. The two parts are separated by the line connecting the upper edge of the orbit and the external ear. The cranial bones are further divided into the calvaria and floor. The dividing line here is between the upper edge of the orbit and the occipital tuber.

Frontal bone – os frontale: The frontal bone has a vertical portion and horizontal portions. The vertical portion, called the frontal squama, forms the forehead and the anterior part of the vault. The horizontal portions form the orbital plates (roofs of the orbit), part of the roof of the nasal cavity, and the greater part of the anterior cranial fossa. The frontal sinuses are situated between the two tables of the squama on each side of the midsagittal plane.

Sphenoid bone – os sphenoidale: The sphenoid bone is an irregularly wedge shaped bone that somewhat resembles a bat with its wings extended. It is situated in the base of the cranium anterior to the temporal bones. The body of the sphenoid bone contains the two sphenoidal sinuses, which are incompletely separated by a median septum.

The anterior surface of the body forms the posterior bony wall of the nasal cavity. The superior surface presents a deep depression called the sella turcica and contains a gland called the pituitary gland.

Temporal bone – os temporale: The temporal bones are irregular in shape and are situated on each side of the base of the cranium between the greater wings of the sphenoid bone and the occipital bone. Each temporal bone consists of a squamous portion, a tympanic portion, a styloid process, a zygomatic process, and a petromastoid portion (the mastoid and petrous portions) that contains the organs of hearing and balance.

Occipital bone - os occipitale: The occipital bone is situated at the posteroinferior part of the cranium. It forms the posterior half of the base of the cranium and the greater part of the posterior cranial fossa. The occipital bone has four parts: the squama, which is saucer-shaped, being convex externally; two occipital condyles, which extend anteriorly, one on each side of the foramen magnum; and the basilar portion. The occipital bone also has a large aperture, the foramen magnum, through which the inferior portion of the medulla oblongata passes as it exits the cranial cavity and joins the spinal cord. The occipital condyles project anteriorly, one from each side of the squama for articulation with the atlas of the cervical spine.

Parietal bone – os parietale: The two parietal bones are somewhat square and have a convex external surface and a concave internal surface. The parietal bones form a large portion of the sides of the cranium.

The bones of the cranium are joined by fibrous joints called **sutures**. These are:

- coronal – sutura coronalis: between the frontal and parietal bones

- sagittal – sutura sagittalis: located on the top of the head between the two parietal bones and just behind the coronal suture line
- lambdoidal – sutura lambdoidea: between the occipital bone and the parietal bones
- squamosal – sutura squamosa: between the temporal bones and the parietal bones

Orientation planes and lines:

Median sagittal plane: divides the skull into right and left halves. Landmarks on this plane are the nasion anteriorly and the external occipital protuberance (inion) posteriorly.

(Figure 349.)

Infra orbito-meatal plane: The line connecting the upper edge of the orbit and the external ear. It is perpendicular to the median sagittal plane.

(Figure 350.)

Orbito-meatal baseline (radiographic baseline): extends from the outer canthus of the eye to the centre of the external auditory meatus.

(Figure 351.)

Auricular plane: perpendicular to the axial plane. Passes through the centre of the two external auditory meatuses. It is an example of a coronal plane. It divides the skull into anterior and posterior halves.

(Figure 352.)

Nucha-occiput, frons-front, occiput-occipital bone, nasion-noseroor, tempora-temporal bone, skull roof-vertex.

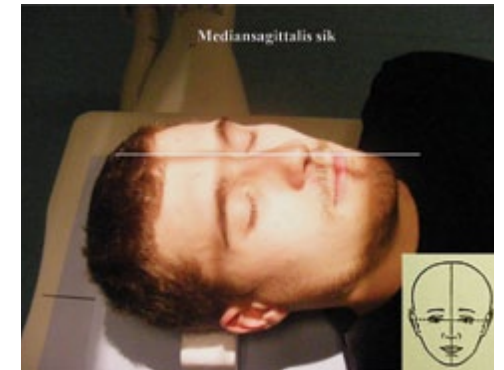

Figure 349.

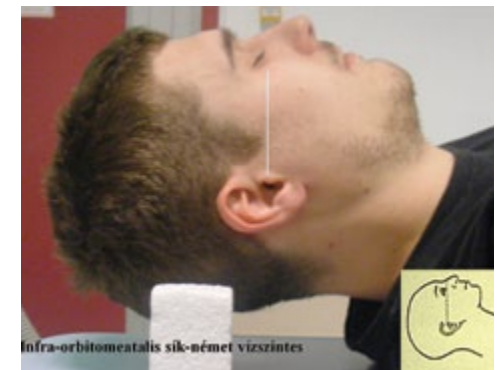

Figure 350.

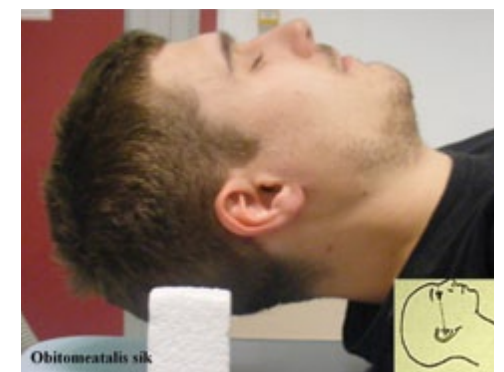

Figure 351.

Margo supraorbitalis – upper edge of the orbit

Margo infraorbitalis – bottom edge of orbit

Indications: trauma, cerebral neurologic symptoms (headache), palpable masses, nodular bone lesions, detection of developmental disorders

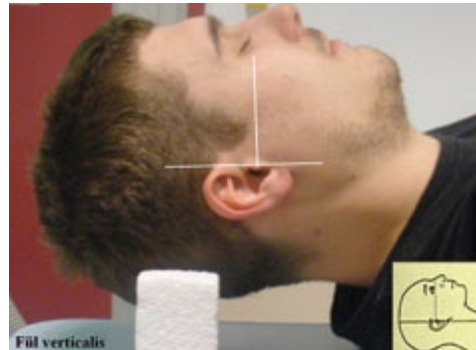


Figure 352.

Skull – AP

Patient positioning: The patient lies supine on the table. The head is adjusted to bring the median sagittal plane at right angles to the film and coincident with its midline and the chin is brought in. In this position, the external auditory meatuses are equidistant from the cassette. The orbito-meatal baseline should be perpendicular to the cassette.

Exposure borders: The upper and the lateral edges are the soft tissues, and the lower edge is below the mandible by approx. 1 cm.

Film or image size: 24 × 30 cm

Focus-film distance: 100 cm

Centering: to the glabella

http://tamop.etk.pte.hu/tamop412A/Kepalkotasi_gyakorlatok_tananyag/RTG/RTG_video/45_koponya_AP_en.avi

(Figures 353., 354.)



Figure 353.




Figure 354.

Koponya AP felvétele

- a koponya szimmetrikus és teljes egészében ábrázolódik
- a sziklacsont az orbita alsó harmadába vetül

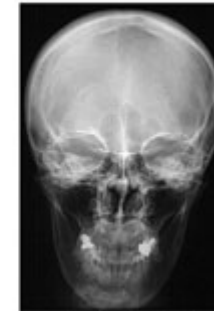

Figure 355.

Koponya AP felvétele

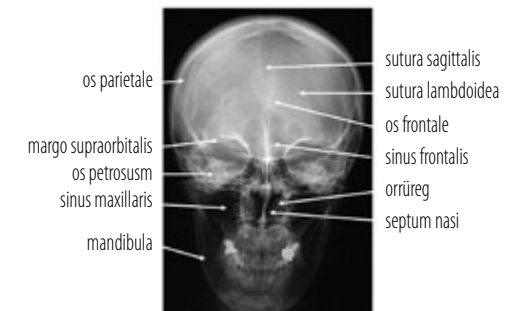


Figure 356.

Structures shown:

- the entire skull demonstrated
- symmetric skull
- petrous pyramids lying in the lower third of orbit
(Figures 355., 356.)

Skull – PA

Patient positioning: This projection is usually undertaken with the patient erect and facing the vertical grid device, although it may be performed prone. Initially, the patient is asked to place their nose and forehead on the Bucky table. The head is adjusted to bring the median sagittal plane at right-angles to the cassette and so it is coincident with its midline. The orbito-meatal baseline should be perpendicular to the cassette.

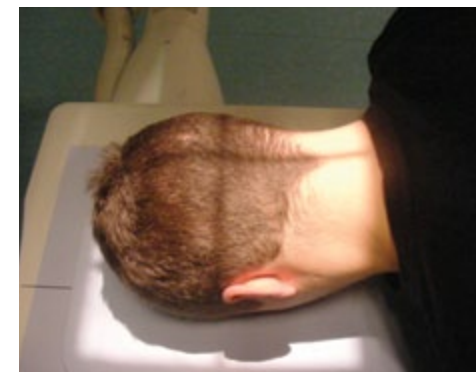


Figure 357.

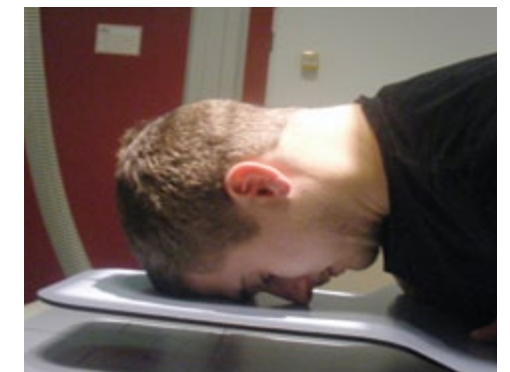

Figure 358.

Exposure borders: The upper and the lateral edges are the soft tissues, and the lower edge is the mandible.

Film or image size: 24 × 30 cm

Focus-film distance: 100 cm

Centering: to the protuberantia occipitalis externa

(Figures 357., 358.)

Structure shown:

- the entire skull demonstrated
- symmetric skull
- petrous pyramids lying in the lower third of orbit

(Figures 359–362.)

Koponya PA felvétele

- a koponya szimmetrikus és teljes egészében ábrázolódik
- az os petrosum az orbitába vetül

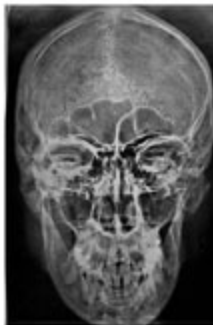


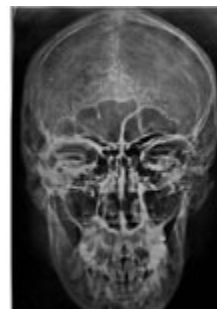
Figure 359.

AP filmközelben az os occiput

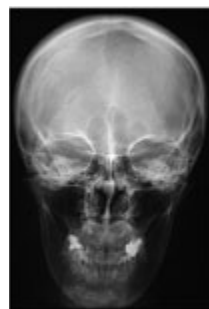

Figure 361.

PA filmközelben az os frontale



Koponya PA felvétele

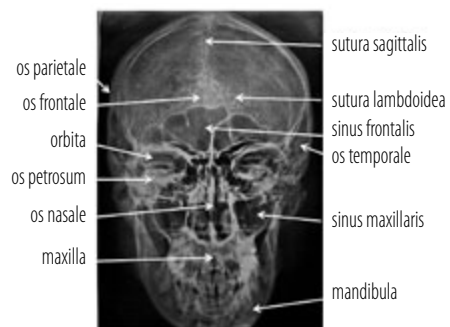


Figure 360.

Gyermek kétirányú koponya felvétele

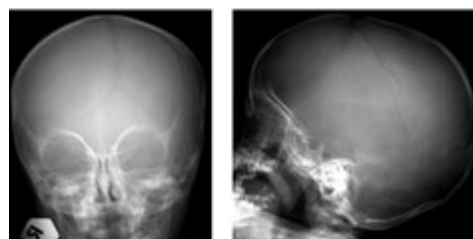


Figure 362.

Skull–lateral (prone)

Patient positioning: The patient lies prone, and rotates his head into a lateral position. The chin is raised up with a skull pad, or the patient can put his fists under his chin to prevent unnecessary motion. The head is adjusted so that the infra-orbito-meatal plane is parallel to the cassette.

Exposure borders: The upper and the lateral edges are the soft tissues, and the lower edge is the mandible.

Film or image size: 24 × 30 cm

Focus-film distance: 100 cm

Centering: to the center of the infra-orbito-meatal plane

http://tamop.etk.pte.hu/tamop412A/Kepalkotasi_gyakorlatok_tananyag/RTG/RTG_video-ok/46_koponya_oldal_fugg_en.avi

(Figures 363–364.)

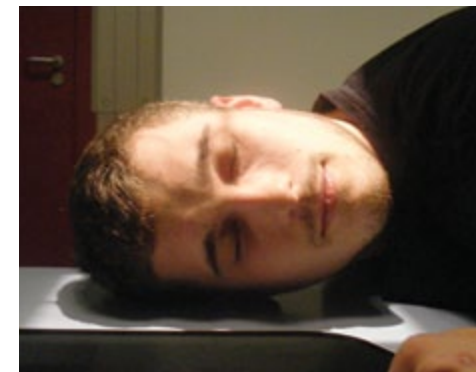

Figure 363.

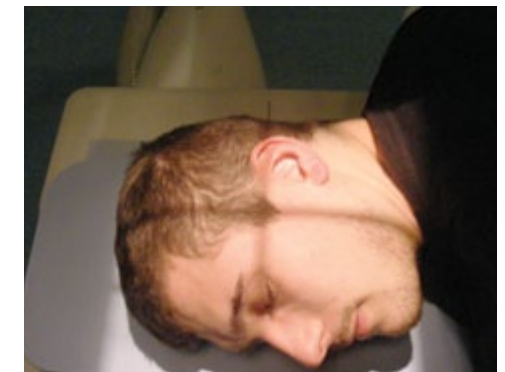

Figure 364.

Skull – lateral (supine)

If the patient's condition does not allow the prone position, due to trauma for example, or suspected c-spine fracture, the following setting should be applied.

Patient positioning: The patient lies supine, with the head raised and immobilized on a non-opaque skull pad. This will ensure that the occipital region is included on the final image. The head is adjusted, such that the median sagittal plane is perpendicular to the table and the infra-orbitomeatal line is perpendicular to the cassette.

Exposure borders: The upper and the lateral edges are the soft tissues, and the lower edge is the mandible.

Film or image size: 24 × 30 cm

Focus-film distance: 100 cm

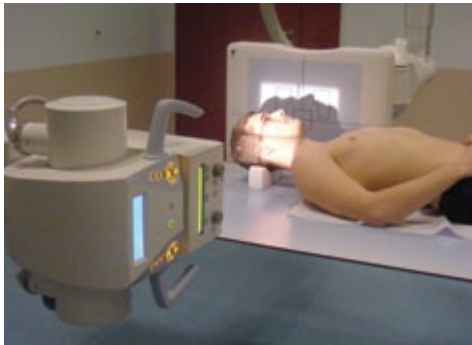

Figure 365.

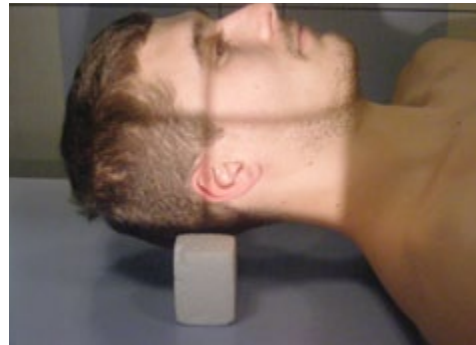

Figure 366.

Centering: transversal, below the center of the infra orbito-meatal plane by approx. 1 cm
http://tamop.etk.pte.hu/tamop412A/Kepalkotasi_gyakorlatok_tananyag/RTG/RTG_video-ok/47_koponya_oldal_viz_en.avi
 (Figures 365–366.)

Structures shown:

- entire cranium without rotation
- superimposed mastoid regions, orbital roofs, EAMs, TMJs and greater wings of sphenoid
 (Figures 367–368.)

Koponya oldalirányú felvétele

- a koponyaboltozat teljes egészében ábrázolódik
- az orbitatető, a meatus acusticus externa, a mandibulaszár, a temporomandibularis ízület és a sella turcica szélei egymásra vetülnek

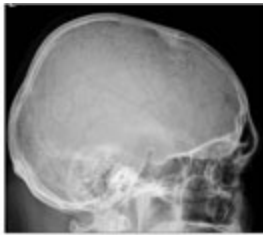

Figure 367.

Koponya oldalirányú felvétele

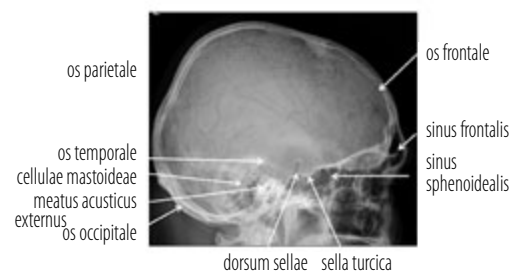


Figure 368.

Sella – lateral

Patient positioning: The patient lies prone, and rotates his head into a lateral position. The chin is raised up with a non-opaque skull pad. The head is adjusted so that the infra orbito-meatal plane is parallel to the cassette.

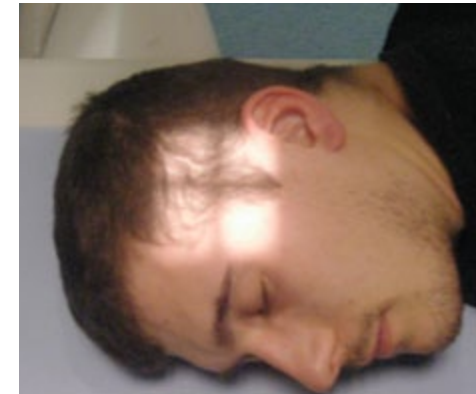


Figure 369.

Exposure borders: In all directions, approx. 2 cm from the center ray.

Film or image size: 13 × 18 cm

Focus-film distance: 100 cm

Centering: next to and above the external ear by approx. 2 cm
 (Figure 369.)

Structures shown:

- no rotation or distortion of sella turcica
- superimposed anterior clinoid processes, posterior clinoid processes, sella turcica and dorsum sellae
 (Figures 370–371.)

Sella felvétel oldalirányból

- a sella turcica, processus clinoidae anterior et posterior és a dorsum sellae egymásra vetül

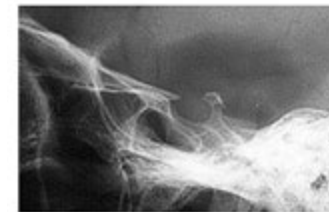

Figure 370.

Sella felvétel

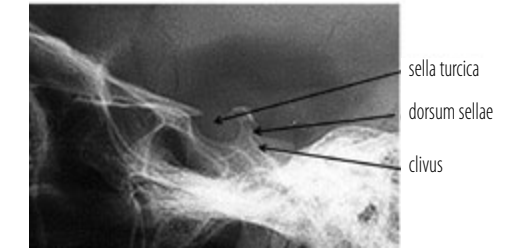


Figure 371.

III.10. X-ray anatomy and imaging technique of the facial bones

The facial bones (cranium viscerale) are separated from the skull by the line connecting the top of the eye sockets and the external ear. On the frontal surface of the facial bones, there are the orbits, between them, there is the nasal cavity and below it is the oral cavity. The facial bones are made up of six even and three odd bones.

Maxillary bones (2): The two maxillary bones are the largest of the immovable bones of the face. The maxillary bones form part of the lateral walls and most of the floor of the nasal cavity, part of the floor of the orbital cavities, and three fourths of the roof of the mouth. The body of each maxilla contains a large, pyramidal cavity called the maxillary sinus, which empties into the nasal cavity. Inside the maxillary sinus there is a mucous membrane.

Zygomatic bones (2): The zygomatic bones form the prominence of the cheeks and a part of the side wall and floor of the orbital cavities. A posteriorly extending temporal process unites with the zygomatic process of the temporal bone to form the zygomatic arch.

Ethmoid bone: The ethmoid bone is a small, cube-shaped bone that consists of a horizontal plate, a vertical plate, and two light, spongy lateral masses called labyrinths. Situated between the orbits, the ethmoid bone forms part of the anterior cranial fossa, the nasal cavity and orbital walls, and the bony nasal septum. The horizontal portion of the ethmoid bone, called the cribriform plate, is received into the ethmoidal notch of the frontal bone. The cribriform plate is perforated by many foramina for the transmission of olfactory nerves. The labyrinths contain the ethmoidal sinuses, or air cells. Projecting inferiorly from each medial wall of the labyrinths are two thin, scroll-shaped processes called the superior and middle nasal conchae.

Nasal bone: The nasal bone is an odd bone. It forms the back of the nose.

Mandible: The mandible, the largest and densest bone of the face, consists of a curved horizontal portion, called the body, and two vertical portions, called the rami, which unite with the body at the angle of the mandible. Each ramus presents two processes. The condylar process consists of a constricted area, the neck, above which is a broad, thick, almost transversely placed condyle that articulates with the mandibular fossa of the temporal bone. This articulation is the TMJ.

Vomer: The vomer is a thin plate of bone situated in the midsagittal plane of the floor of the nasal cavity, where it forms the inferior part of the nasal septum.

Lacrimal bones (2): The two lacrimal bones, which are the smallest bones in the skull, are very thin and are situated at the anterior part of the medial wall of the orbits between the labyrinth of the ethmoid bone and the maxilla.

Palatine bones (2): The two palatine bones are L-shaped bones composed of vertical and horizontal plates. The horizontal plates articulate with the maxillae to complete the posterior fourth of the bony palate, or roof of the mouth. The vertical portions of the palatine bones extend

upward between the maxillae and the pterygoid processes of the sphenoid bone in the posterior nasal cavity.

Sinuses: The nasal cavity has three major pairs of sinuses. These are:

- frontal sinus
- maxillary sinus
- sphenoid sinus
- ethmoid cells

The frontal sinus is located in the frontal bone, and it has a mostly asymmetric septum.

The maxillary sinus almost completely fills out the maxillary bone.

The sphenoid sinus completely fills out the anterior part of the body of the sphenoid bone.

The ethmoid cells are a complex system of cavities that are bordered by thin plates of mucous membrane covered bones.

Indications: trauma, and inflammation of the sinuses (sinusitis)

Facial bones – PA

Patient positioning: The patient lies prone on the table. The patient's nose and chin are placed in contact with the midline of the cassette. The median sagittal plane is perpendicular to the cassette. The projection is also performed with the patient seated facing the vertical grid device.




Figure 372.

Arckoponya PA felvétel

- arckoponya elfordulás nélkül ábrázolódott a járomívekkel

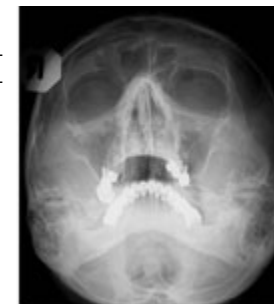

Figure 373.

Arckoponya PA felvétel

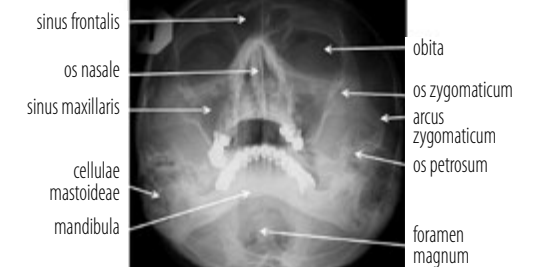

Figure 374.

Exposure borders: The upper and the lateral edges are the soft tissues, and the lower edge is the occiput.

Film or image size: 24 × 30 cm

Focus-film distance: 100 cm

Centering: to the center of the detector

(Figure 372.)

Structures shown:

- facial bones without rotation
- zygomatic bones demonstrated

(Figures 373., 374.)

Sinuses – waters

Patient positioning: The patient is seated facing the skull vertical grid device. The patient's chin is placed in contact with the midline of the cassette holder with the mouth open. The patient's nose is located 1 cm from the cassette. The head is then adjusted to bring the orbito-meatal baseline to a 37-degree angle with respect to the cassette holder. The median sagittal plane is perpendicular to the cassette.

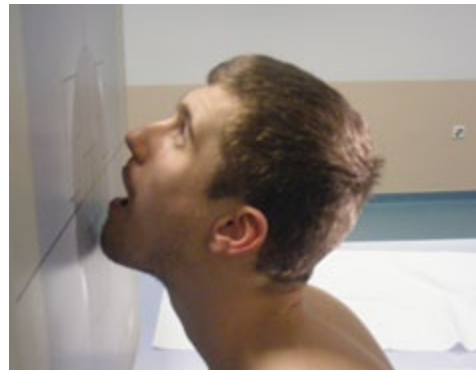

Figure 375.

Exposure borders: The upper, lower and the lateral edges are the soft tissues.

Film or image size: 24 × 30 cm

Focus-film distance: 100 cm

Centering: to the upper incisor, and to the center of the detector

http://tamop.etk.pte.hu/tamop412A/Kepalkotasi_gyakorlatok_tananyag/RTG/RTG_video/48_OMU_en.avi

(Figure 375.)

Structures shown:

- petrous bones projected immediately below maxillary sinuses
- maxillary sinuses, orbit without rotation

(Figures 376., 377.)

Orrmelléküreg felvétel Waters szerint

- a sziklacsont a sinus maxillaris alá vetüljön
- a sinus maxillarisok és az orbita elfordulás nélkül ábrázolódnak

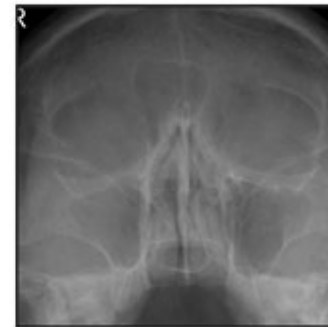

Figure 376.

Orrmelléküreg Waters-féle felvétel

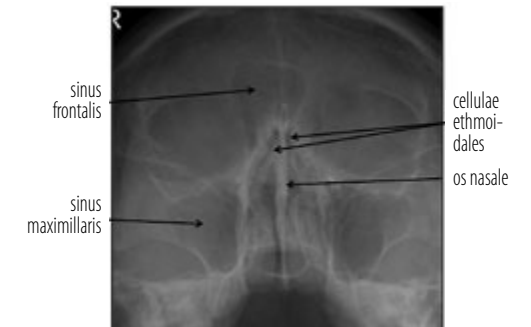


Figure 377.

On the left side there is a decrease in transparency, and on the right side there is circular mucosal thickening with a small air-fluid level.

(Figure 378. Pathology)

If the patient's head is retroflexed adequately, the petrous bone is well visualized below the maxillary sinus, otherwise the bone is projected into the maxillary.

In a standing position, fluid is visualized as a horizontal level of the fluid below gas.

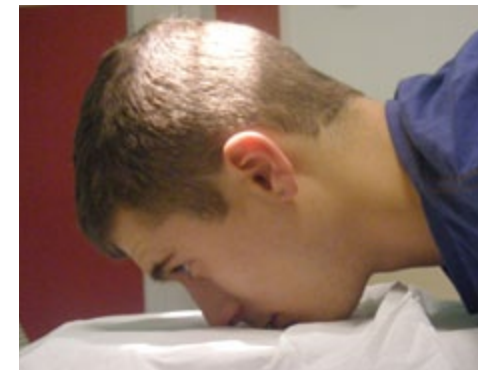

Figure 378.

Orbit – PA

Patient positioning: The patient lies prone on the table or he is seated facing the vertical grid device. The patient's nose and chin are placed in contact with the midline of the cassette. The median sagittal plane is perpendicular to the cassette.

Exposure borders: The upper edge is above the supraorbital margin by approx. 2 cm and the lateral edges are the soft tissues, while the lower edge is below the infraorbital margin by approx. 2 cm.

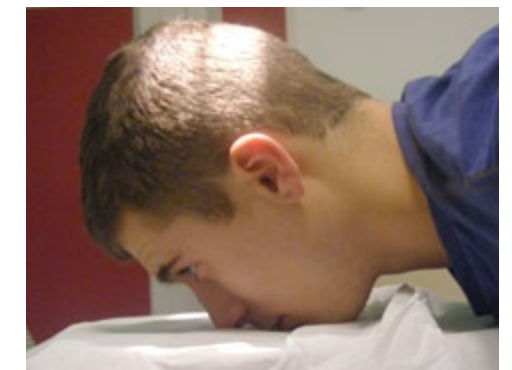

Figure 379.

Film or image size: 18 × 24 cm

Focus-film distance: 100 cm

Centering: to the glabella

(Figure 379.)

Structures shown:

- petrous pyramids lying well below the supraorbital margin
- symmetric and sharp visualization of the upper and lateral margins of the orbits

(Figures 380., 381.)

Orbita PA felvétel

- a fissura orbitalis superior jól ábrázolódva a sziklacsont felső pereme fölé vetül
- a margo orbitalis superior és lateralis élesen ábrázolódjon

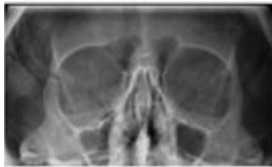

Figure 380.

Nasal bone – lateral

Patient positioning: The patient lies prone on the table. The head is turned so that the median sagittal plane is parallel with the cassette.

Exposure borders: The upper and the lower edges are soft tissues.

Film or image size: 13 × 18 cm

Focus-film distance: 100 cm

Centering: to the glabella

http://tamop.etk.pte.hu/tamop412A/Ke-palkotasi_gyakorlatok_tananyag/RTG/RTG_video/49_orrcsont_en.avi

(Figure 382.)

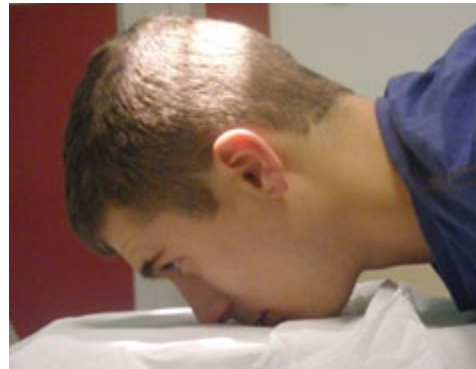

Figure 379.

Orbita PA felvétel

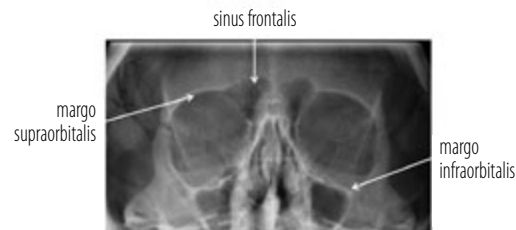

Figure 381.

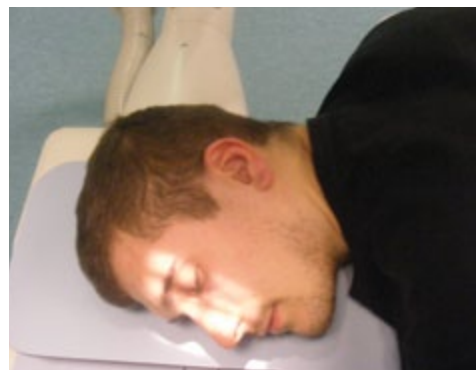

Figure 382.

Orrcsont oldalirányú felvétele

- orrcsontok egymásra vetülnek
- orr lágyrészei is ábrázolódnak
- látható a blendézés

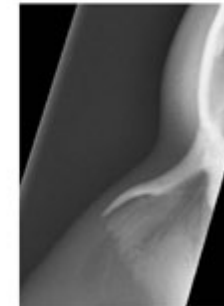


Figure 383.

Orrcsont oldalirányú felvétele

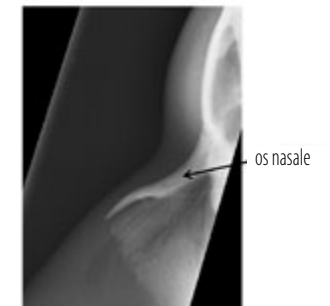

Figure 384.

Structures shown:

- no rotation of nasal bone and soft tissues
- nasal bones superimposed
- exposure borders demonstrated

(Figures 383., 384.)

Mandible – PA

Patient positioning: The patient lies prone on the table. The patient's median sagittal plane should be perpendicular to the cassette holder. The head is then adjusted to bring the orbito-meatal baseline perpendicular to the cassette. The patient's nose and forehead are placed in contact with the midline of the cassette. The patient has to bring the chin in.

Exposure borders: The upper edge is the middle of the orbit, while the lower and lateral edges are soft tissues.

Film or image size: 18 × 24 cm

Focus-film distance: 100 cm

Centering: below the occiput

(Figure 385.)

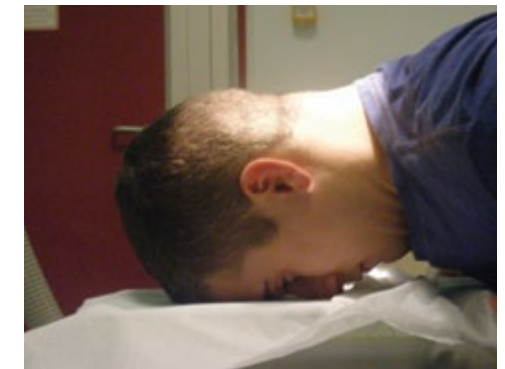

Figure 385.

Mandibula PA felvétele

- teljes mandibula ábrázolódik a mandibulaszár és -test elfordulás nélkül

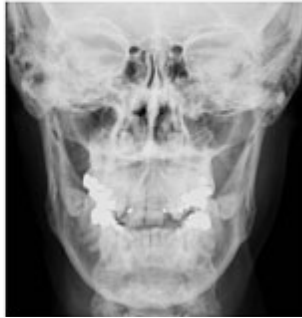

Figure 386.

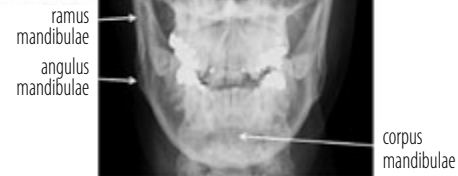Mandibula PA felvétele

Figure 387.

Structures shown:

- mandibular body and rami are symmetric on each side and they are visible without rotation. (Figures 386., 387.)

Otological x-ray imaging

The following techniques involve taking images of the petrous bones from different directions and orientations. These methods are named after their discoverers (Schüller, Stenvers and Mayer). Today, except for the Schüller method, their use is limited. Nowadays, the complex petrous structure and the inner ear are imaged by either CT or MRI.

Schüller

Patient positioning: The patient lies prone on the table. The head is turned so that the median sagittal plane is parallel to the cassette. The auricle of the ear adjacent to the table is folded forward, and the external acoustic meatus is approximately 1 cm in front of the midline of the cassette, so that the mastoid process is projected better.

Exposure borders: From the central ray by approx 2 cm, in all directions.

Film or image size: 13 × 18 cm

Focus-film distance: 60 cm

Centering: approx. 2 cm above the external ear closest to the detector, with a 25-degree cranio-caudal angulation.

http://tamop.etk.pte.hu/tamop412A/Kepalkotasi_gyakorlatok_tananyag/RTG/RTG_video-ok/50_schuller_en.avi

(Figures 388., 389.)

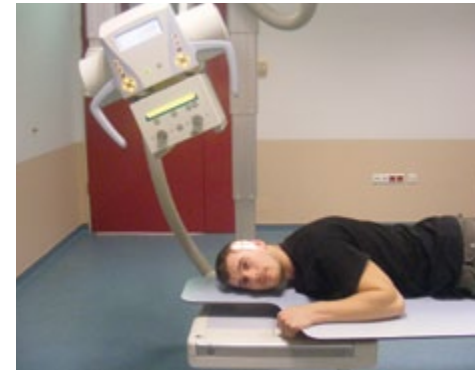

Figure 388.

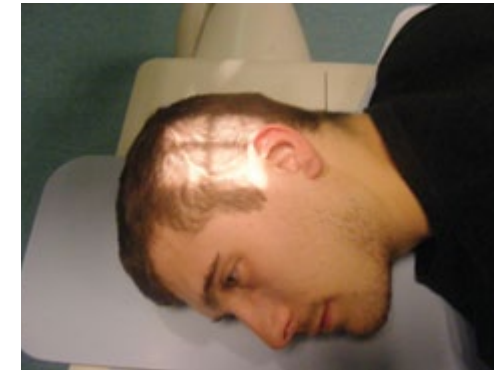

Figure 389.

Structures shown:

- the mastoid cells and the mastoid antrum are well visualized
- TMJ in front of the external acoustic meatus
- ear not superimposed on the mastoid cells
- exposure borders demonstrated (Figures 390., 391.)

Schüller felvétel

- a mastoidalis sejtek, és az antrum jól ábrázolódik a felvétel közepén
- a temporo mandibularis ízület a meatus acusticus extamús előtt ábrázolódik
- a fülkagyló nem vetül a mastoid sejtekre
- jól látszik a blendézés

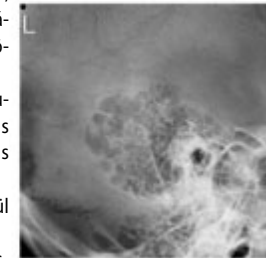


Figure 390.

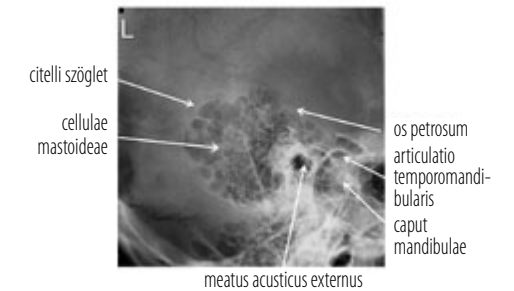
Schüller felvétel

Figure 391.

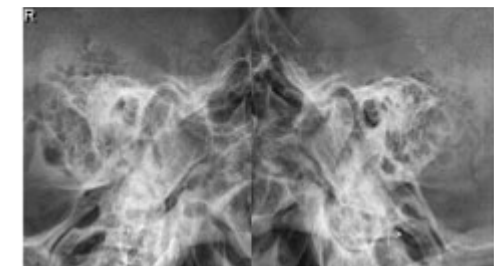Összehasonlító Schüller felvétel

Figure 392.

Always prepare comparative images; symmetrical positioning is important. Use side marks.

(Figure 392.)

Petrous bone, schüller comparative

Patient positioning: The patient lies supine on the table. The patient's median sagittal plane should be perpendicular to the cassette holder. The head is then adjusted to bring the orbito-meatal baseline perpendicular to the cassette, therefore the patient has to bring the chin in.

Exposure borders: The upper edge is above the supraorbital margin by approx. 2 cm and the lateral edges are the soft tissues, while the lower edge is below the infraorbital margin by approx. 2 cm.

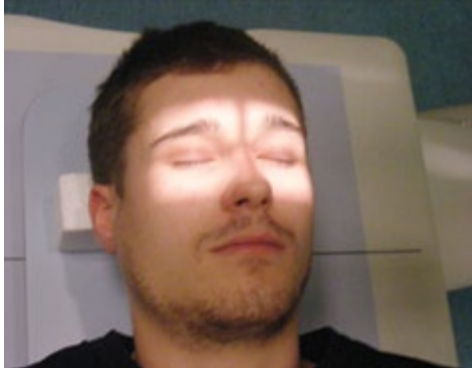


Figure 393.

Film or image size: 12 × 18 cm

Focus-film distance: 100 cm

Centering: to the glabella

(Figure 393.)

Structures shown:

- petrous bone symmetrical and superimposed on the lower third of the orbita (Figures 394., 395.)

Összehasonlító sziklacsont, orbitalis Schüller felvétel

- a sziklacsont szimmetrikusan az orbita alsó harmadába vetül

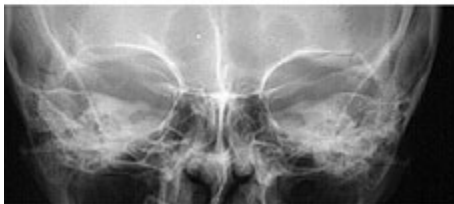

Figure 394.

Orbitalis Schüller felvétel

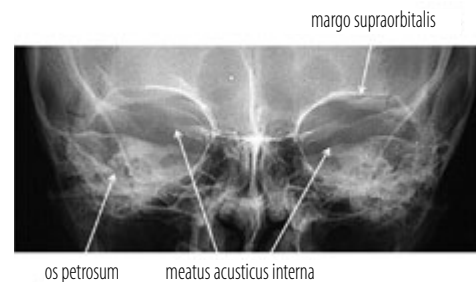


Figure 395.

III.11. X-ray contrast agents

Definition of x-ray contrast agents: When administered into the body, x-ray contrast agents alter the radiation-absorbing capability of organs, and tissues. Thus, a contrast difference develops between tissues that appear the same density on a native image, therefore it becomes easier to separate structures of interest from their surroundings.

The history of contrast agents: In 1896, for the first time, contrast agents were used in cadaver and animal studies.

In 1904, Rieder was the first who used contrast material (bismuth) for medical diagnostics.

In 1906, barium sulfate was used as a contrast material for the first time.

In the early 1920s, iodine-containing contrast media began to appear. By experience, it became apparent that the main cause of the observed side effects were due to the osmotic effect and the presence of electrically charged particles.

In the mid-1960s non-ionic, low osmolar iodinated contrast agents became popular.

In the mid-1980s ultrasound contrast agents appeared.

In the mid-1990s MR contrast agents appeared.

Contrast agents can be divided into three main categories:

- 1 **X-ray** contrast agents (also known as, radiocontrast agents) alter the radiation-absorbing capability of organs and tissues.
- 2 **Ultrasound** contrast agents enhance the reflection of sound waves, thereby enhancing ultrasound backscatter (tiny gas bubbles are conjugated to different carrier molecules, such as galactose or albumin).
- 3 **MRI** contrast agents are paramagnetic or superparamagnetic materials (gadolinium, manganese, iron), which, under an external magnetic field, behave like magnets. They shorten the relaxation time, and increase or decrease the intensity of the magnetic resonance signal.

An ideal contrast agent:

- clearly demonstrates the required anatomical structure
- is non-toxic
- does not cause acute complications or permanent damage
- is rapidly cleared from the body
- does not cause adverse side effects

Types of X-ray contrast agents:*Illustration 1.***Negative contrast agents**

- negative contrast agents absorb less x-ray photons than their surroundings, thus they decrease attenuation
- air and carbon-dioxide are most frequently used, and they are:
- absorbed by tissues, they leave the body via the lungs
- basically harmless, but they can cause air embolism if they get into blood vessels
- nowadays not used independently, but they were used to examine body cavities (eg.: ventricles, retroperitoneum)
- liquids (methyl cellulose) for small intestine examinations
- nowadays they are used in double contrast studies in combination with a positive contrast agent to enhance the contrast effect
- the examined body cavity / lesion's wall is coated with a positive contrast agent, and then the lumen is filled with gas / liquid
- gastrointestinal track
- bladder
- examination of cyst
- do not use them, if there is a risk of air embolism (eg.: bleeding, ulcer, disintegrating tumour)

Positive contrast agents

- positive contrast agents absorb more x-ray than the surrounding tissue
- they contain elements with a high atomic number
- they are highly radio-opaque; they increase attenuation
- give intense shadows and very good contrast
- barium containing compounds
- iodine containing compounds

Barium sulfate

Barium is toxic as a chemical element, and therefore as a contrast agent can be used only in the form of compounds which are not soluble in either water or gastric fluids and are not absorbed in tissues. This form is the barium sulfate.

Application:

Barium sulfate is mainly used in the imaging of the digestive system. The substance exists as a water insoluble white powder that is made into a slurry with water and administered directly into

the gastrointestinal tract, orally, rectally or via a tube. Barium sulfate, an insoluble white powder is typically used for enhancing contrast in the GI tract. Depending on how it is to be administered, the compound is mixed with water, thickeners, de-clumping agents, and flavourings to make the contrast agent.

Expectations for barium sulfate:

- it should give an intense shadow
- it should clearly demonstrate the gastrointestinal mucosal lining
- it should not precipitate
- it should not settle during the investigation
- given orally, it should pass through the gastrointestinal tract easily
- it should fully leave the body
- given rectally, it should not cause spastic or painful defecation
- it should be easy to use

The risks of using barium sulfate:

In case of a high grade stenosis complete, blockage may occur. In constipating, elderly, or debilitated patients bowel movements and clearance is slow, and the contrast agent may thicken and cause intestinal obstruction, thus ileus may occur. Immobile contrast agent may cause inflammation in the diverticuli. If aspirated, the contrast agent may cause inflammation in the airways. In ulcerative colitis, wall abscess formation may occur. If there is an unknown perforation, the contrast agent can get out of the intestines and into the abdominal cavity. This can lead to a foreign body granuloma formation and fibrosis.

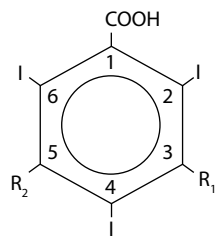
We do not use barium sulfate:

- in suspected perforation
- in dysphagia or if the patient is unable to swallow
- in the presence of varices, ulcers and suspected tumours
- in the postoperative period, in case there is suture insufficiency
- if the patient swallowed a foreign body
- when examining newborns and infants for congenital absence of body cavities, strictures, internal fistulas

In all these cases, an iodine-containing, water-soluble contrast agent must be used.

Applications of barium sulfate:

- imaging of the esophagus, stomach, duodenum, small intestines (enterography), and the large intestines (colonography).

Iodinated contrast agents

All intravascular iodinated contrast agents are based on a tri-iodinated benzene ring that consists of 6 carbon and 6 hydrogen atoms.

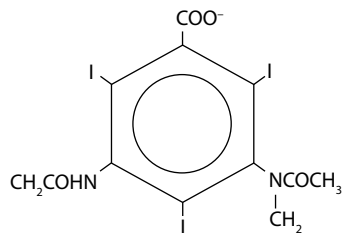
Advantages of the structure:

- high radiation absorbing capacity
- creates an ideal contrast
- iodine strongly binds to the benzene ring, thus it has low toxicity
- the side chains may be linked to the molecule with which the physical and chemical properties of the molecule can be changed (ionic-, non-ionic character, solubility, toxicity)

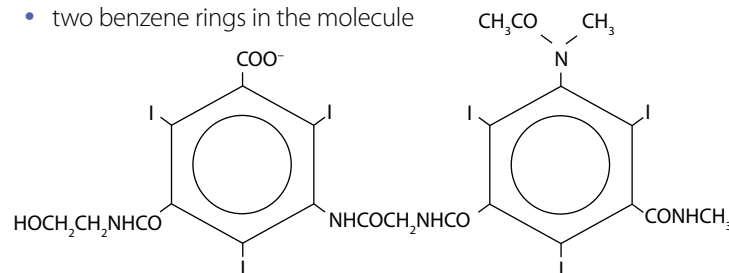
Depending on the number of benzene rings there are:

Monomer structure:

- one benzene ring in the molecule

**Dimeric structure:**

- two benzene rings in the molecule



This latter structure is preferable, because it has six iodine atoms, therefore its radiation-absorbing capacity and its contrast enhancing ability are both greater. Its disadvantage is that it has a greater viscosity, compared to the monomer structure, which is a direct consequence of the larger molecule.

These molecules may be also grouped based on whether they are

- ionic or
- non-ionic contrast agents.

This is determined by the nature of the side chain at the first position of the benzene ring.

Ionic contrast agents:

In the first position of the benzene ring, there is a carboxyl group (-COOH) which has two parts: a large negatively-charged iodinated ion (the anion), and a much smaller positively-charged sodium ion (the cation), so that when it is dissolved in water it gives rise to two particles for each molecule of contrast medium. Therefore it is an ionic contrast medium, and it has a high osmolality. That's why complications are much frequent, which can be:

- vessel pain, vasospasm, because the contrast agent irritates the endothelium
- thrombosis due to endothelial injury, damage
- hemodynamic signs (blood pressure, poor circulation)
- arrhythmia
- blood pressure disorders
- disorders of the central nervous system

Therefore, the goal is to develop contrast agents which cause fewer complications, and have an osmolarity that is as close as possible to the osmolarity of blood and body fluids.

Non-ionic contrast agents:

The group on the first position of the benzene ring does not dissociate in water, therefore the osmolarity of the molecule is low, almost identical to blood and bodily fluids; it is isotonic, and it will not be electrically charged. On the third and fifth positions of the benzene ring, there are strong hydrophilic chains.

Expectations for iodinated contrast agents:

- low osmolarity
- lack of an electric charge
- strong hydrophilic nature
- binding to plasma proteins should be minimal

- minimal toxicity
- adequate viscosity
- proper concentration at the injection site
- makes even small structures visible
- leaves the body quickly

Iodinated contrast media are divided into 3 groups:

- high osmolarity
- low osmolarity
- iso-osmolar

Based on secretion, there are three groups of contrast agents:

Nephrotop contrast agents:

Most ionic and non-ionic contrast agents belong here. They hardly bind to plasma proteins, and they leave the veins quickly spreading in the intercellular space. Secretion occurs through the glomeruli of the kidneys. If there is poor kidney function, secretion is delayed and occurs partially through the liver

Hepatotrop contrast agents:

They are primarily used for imaging the gallbladder and the biliary system. The orally administered contrast agent is absorbed in the small intestine and goes directly to the liver via the portal vein; secretion is biliary, and it is excreted into the duodenum. Since these agents have a high tendency to bind to plasma protein, when administered intravenously, in case of hepatic impairment, their renal excretion is increased. These type of contrast agents have one serious disadvantage; since they have a high tendency to bind to plasma proteins there are frequent complications associated with them.

Oil-based contrast agents:

This is a special group. In iodinated oils the iodine is linked to an open carbon chain. These are lipophilic organic compounds from which the iodine is easily liberated. They give good contrast, they do not dissolve in water and tissue-fluids, they are not absorbed by the body, and they remain at the injection site for an extended period of time. They may cause local complications (such as pneumonia), and if their administration is too rapid, pulmonary microembolization may occur. If they get into the venous system, they can cause oil embolism. They are used for myelography or lymphography. Today, their use is gradually diminishing. Nowadays, oil drops are used for therapeutic purposes. They can clog capillaries, therefore they may be good for selective cytostatic chemoembolization of focal hepatic space-occupying lesions.

Administration of contrast agents, and the determining factors:

- osmolarity of the contrast agent, and the injection rate
- examined organ
- patient history
- patient's general status (circulation, kidney function), age, body weight (2-5 ml/kg body weight)
- iodine content of the contrast agent

Conditions for the use of contrast material:

- suck the contrast agent up out of the ampulla only prior to use, and do not store the remainder - do not mix it with infusion and drugs
- during the injection the patient is in a supine position
- observe the patient for 15-30 minutes after administration
- prepare a peripheral venous catheter
- instruct the patient to drink plenty of fluids after the examination

Preparations before administering the contrast agent :

- check the patient's fluid and electrolyte homeostasis, and ensure an adequate hydration
- the patient should not eat 4-6 hours before the examination
- ask the patient about his/her existing diseases (thyroid disease, bronchial asthma, diabetes)
- check the patient's medical history (metformin, contrast sensitivity) and inform the patient about the examination procedure, the expected results and the possible complications
- Metformin containing medications (diabetes) should be stopped 48 hours prior to the test; a serum creatinine under 60 ml/min/1,73 m² is considered an increased risk, and under 30 ml/min/1,73 m² GFR (glomerular filtration rate) a very high risk
- to resolve complications, medical and technical conditions, plus prepared personell have to be available

Side effects caused by iodinated contrast agents

The possibility of complications should be weighed against the potential benefits. During contrast-enhanced studies, approx. 50 % of patients have an adverse action, but most of them are mild, negligible, vasomotor reactions. The occurrence of moderate reactions is 2%. Out of 1000 patients, 1 will experience a serious side effect and the probability of a fatal complication is 0.0025%.

Contraindications:

Absolute contraindications:

- hyperthyroidism
- contrast allergy

Relative contraindications:

- shock
- renal function impairment

Risk factors:

- renal function impairment (GFR < 30)
- diabetic nephropathy
- congestive cardiomyopathy
- age above 70 years
- simultaneous use of nephrotoxic medication (eg: nonsteroidal anti-inflammatory drug, metformin, aminoglycoside, vancomycin, amphotericin, cisplatin)
- asthma
- multiple myeloma
- allergic reaction

Tasks to prevent the reactions:

- hydration (before and after the examination)
- use of a low or an iso-osmolar contrast agent
- stop nephrotoxic medication (metformin)
- apply an adequate dose (up to 2 ml/kg)
- do not use another iodinated contrast agent on the patient within 5-7 days of the examination

Side effects caused by iodinated contrast agents*Accompanying symptoms:*

- dizziness
- warmth
- dry mouth, bad taste in mouth
- urge to urinate
- nausea

Features:

- occurs at the time of injection
- short-lasting
- disappears spontaneously without intervention

It is important to be aware of these!

Complications are grouped into:

- local complications
- general complications:
 - acute reactions (within 1 hour)
 - late reactions (after 1 hour, within 1 week)
 - kidney function impairment
 - thyrotoxicity
 - late allergic symptoms

Local complications:*Generating factors:*

- osmolarity, viscosity, concentration and the amount of the administered contrast agent
- endothelial injury, thrombosis
- changes in the permeability of capillaries - edema
- local circulatory disorder
- in angiography, the catheter may block the lumen of the vessel, and at the time of injection only contrast agent enters the cells - tissue hypoxia
- pain at the injection site
- paravasation, inflammation, necrosis
- in the intestines, the large amount of concentrated iodinated contrast material absorbs water from the bowel's wall – liquid and electrolyte homeostasis is disturbed, hypovolemia, shock
- increases peristalsis, and it may cause bowel gripes and diarrhea

General complications:

Complications are not related to the amount of injected contrast material. They are grouped according to the constellation of symptoms that dominate the clinical picture.

- cardiorespiratory complications
- renal complications
- neurological complications
- allergic reactions

Cardiovascular complications:

- vasodilation
- decrease of blood pressure
- bradycardia
- seizure
- angina symptoms
- in the absence of therapy: shock (rapid pulse, cold sweats, cyanosis), arrhythmias, and finally circulatory and respiratory failure may develop

Renal complications:

They may occur for days after the administration of the contrast agent.

- hematuria and albuminuria
- in severe cases anuria
- nephrotoxicity, renal impairment (serum creatinine is increased more than 25%)

Neurological complications:

- mild: headache, dizziness, blurred vision, tinnitus
- severe: epileptic seizures, rare permanent neurological impairment (paraesthesia, paraplegia, quadriplegia, speech disorder)

Allergic reactions (hypersensitivity):

Contrast agents can induce allergic complications such as anaphylaxis / anaphylactoid reaction, angioedema, and urticaria.

Pathogenesis: Anaphylaxis develops in sensitive individuals after repeated allergen exposure. Immunoglobulin E (IgE) binds to the antigen (the foreign material that provokes the allergic reaction). Antigen-bound IgE then activates the receptors on mast cells and basophils. This leads to the release of inflammatory mediators. These mediators are responsible for the clinical symptoms. For an anaphylactoid reaction (frequent in the case of contrast agents) there is no need for a first time allergen exposure; allergens bind directly to basophil granulocytes and mast cells. The causes of angioneurotic edema and urticaria are the same that were described in anaphylaxis and anaphylactoid reactions. For a portion of the symptoms narrowing or obstruction of the upper airways, narrowing of the lower airways, and respiratory failure may be responsible. The other symptoms are caused by the following vasodilatation, increased vascular permeability (edema), subsequent intravascular dehydration, low blood pressure or even shock.

The discussion of symptoms and treatment is based on the recommendation of the UK Resuscitation Council (2008) titled "The emergency care of the anaphylactic reactions". (www.resus.org.uk)

Symptoms of hypersensitivity:*Symptoms of severe airway obstruction:*

- huskiness due to vocal cord edema
- inspiratory stridor due to upper airway obstruction
- difficulty in swallowing due to tongue and throat swelling

Symptoms of difficult breathing:

- hampered respiration, wheezing, increased respiratory work
- fatigue, cyanosis
- hypoxia caused confusion
- respiratory arrest

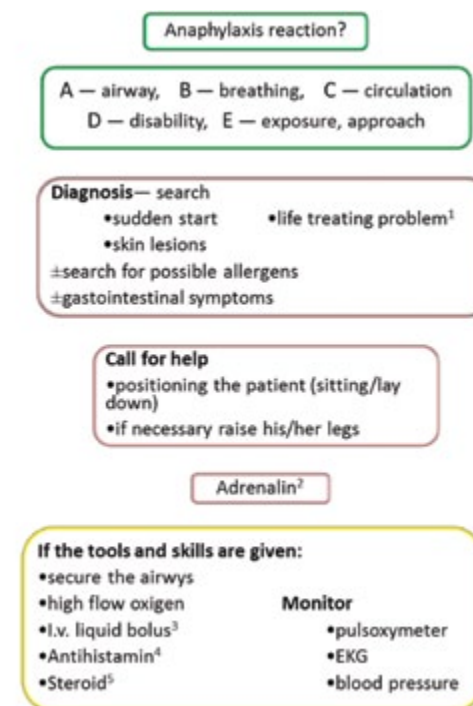
Signs of circulatory disorders (shock):

- pale, cold sweaty skin
- tachycardia
- hypotension, collapse
- impaired consciousness
- loss of consciousness
- symptoms and ECG signs of myocardial ischemia.
- cardiac arrest

Differential diagnosis:

- collapse
- panic attack (especially if the patient has had an allergic reaction)
- children's respiratory spasm.
- idiopathic (non-allergic) urticaria or angioedema

Treatment: Life-threatening symptoms must be treated at the time of recognition. For proper care, you should use the ABCDE protocol. The following algorithm is based on this, too.



¹Life-treating symptoms (shock/angioedema)

- A – airways:** swelling (tongue, pharyngeal), huskiness, inspiratory stridor
B – breathing: tachypnoe, bronchospasm, fatigue, cyanosis, SpO₂ < 92%, mental confusion
C – circulation: pale, damp, hypotension, weakness, impaired consciousness / coma

²Adrenalin:

- IM; 1:1000 diluted (1 mg / 1 ml) Adult, children > 12 years: 500 µgIM (0.5 ml)
 Children 6–12 years: 300 µgIM (0.3 ml)
 Children < 6 years: 150 µgIM (0.15 ml)
 IV adrenalin should only be used by a skilled person, as a 1:10 000 diluted solution (1 ml of 1:1000 adrenaline diluted to 10 ml), and administered slowly.
 Adult: –50-100 µg/kg, children: –1 µg /kg.

³IV liquid bolus:

- Adult: –500-1000 ml/kg crystalloid
 Children: –20 ml/kg crystalloid
 Stop the administration of the IV colloid if there is a suspicion that it is an allergen.

	⁴ Chloropyramine (Suprastin®) (IM, or slowly IV)	⁵ Methylprednisolon (IM, or IV)
Adult or children > 12 years:	20-40 mg	40-125 mg
Children:	0.2-0.4 mg/kg	1-2 mg/kg

(Figure 1 Algorithm of anaphylaxis)

We must do everything that is necessary to try to prevent complications before they occur. This can be achieved by selecting the most appropriate contrast agent, which is nonionic and low osmolarity. After contrast agent injection, adequate hydration and observation of the patient is necessary. Considering the risks associated with contrast examinations, these type of examinations should only be performed in a radiology department, where the appropriate medications, resuscitation tools and sufficient expertise for the prevention of complications is available!

III.12. X-ray anatomy and non-contrast imaging of abdominal, and acute abdominal disorders

Anatomy of the abdominal cavity

The abdominopelvic cavity consists of two parts: a large superior portion, called the abdominal cavity, and a smaller inferior part, the pelvic cavity. The abdominal cavity extends from the diaphragm to the superior aspect of the bony pelvis.

The abdominal cavity (cavitas abdominis) is bounded by

- from the top: diaphragm
- from below: terminal line and the pelvic cavity (diaphragma pelvis et urogenitale)
- in the front: several layers of abdominal muscles
- in the back: lower thoracic spine, the lumbar section and the paravertebral muscles
- on both sides: ribs, muscles, pelvic bones

The abdominopelvic cavity is enclosed in a double-walled seromembranous sac called the peritoneum. The outer portion of this sac, termed the parietal peritoneum, is in close contact with the abdominal wall, the greater (false) pelvic wall, and most of the undersurface of the diaphragm. The inner portion of the sac, known as the visceral peritoneum, is positioned over or around the contained organs and forms folds called the mesentery and omenta, which serve to support the viscera in position.

The space between the two layers of the peritoneum is called the peritoneal cavity and it contains serous fluid. The retroperitoneum is the cavity behind the peritoneum. The abdominal organs are categorized based on their position in relation to the peritoneum.

Intraperitoneal organs – within the peritoneum:

- digestive organs
- liver, spleen

Outside the peritoneum – (spatium extraperitoneum):

- pancreas (retroperitoneal)
- part of duodenum (retroperitoneal)
- major blood vessels, lymph vessels, lymph nodes, nerves (retroperitoneal)
- urinary system (retro-, and infraperitoneal)

Non-contrast x-ray imaging of the abdomen

Indications:

- clinical suspicion of acute abdominal disorders (for example: digestive tract obstruction (ileus) or perforation)
- abdominal or other life-threatening illness that requires urgent surgical solution
- radiopaque foreign bodies in the digestive tract
- lime deposition in the abdominal organs (liver, spleen, abdominal vessels, lymph nodes, pancreas – for example, in chronic pancreatitis)

Chest images should always be taken additionally to the plain abdominal images, because certain signs on the chest x-ray (elevated diaphragm, restricted breathing, dystelectasia) may be signs of an abdominal process. Some symptoms of chest diseases (pneumonia, pleurisy) may mimic abdominal diseases, so the chest x-ray is also justified for the exclusion of these processes.

Patient positioning: If possible, the patient is examined standing against a vertical grid device. The patient stands with their abdomen against the vertical Bucky. The patient's legs are placed well apart so that a comfortable and steady position is adopted.

Exposure borders: the upper edge is the xiphoid process, and the lower edge is approx. 2 cm below the symphysis, while the lateral edges are soft tissues.

Film or image size: 30 × 40 cm

Focus-film distance: 100 cm

Centering: to the center of the line connecting the xiphoid process and the symphysis pubis.

http://tamop.etk.pte.hu/tamop412A/Ke-palkotasi_gyakorlatok_tananyag/RTG/RTG_videok/51_has_en.avi

(Figure 396.)

Structure shown:

- area from the pubic symphysis to the diaphragm- the vertebral column is in the center
- no rotation of the patient
- side mark

(Figures 397., 398.)

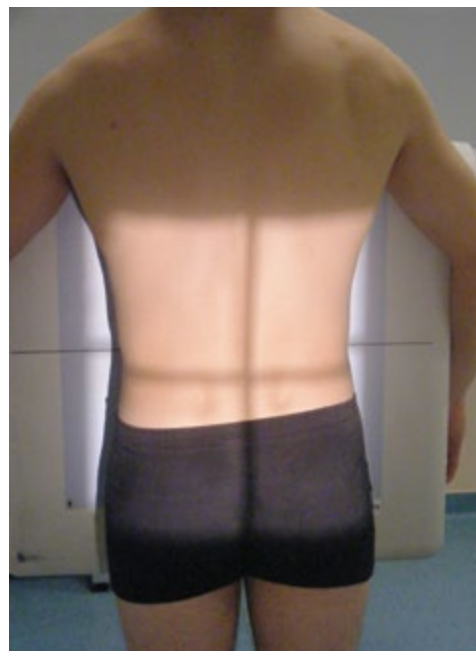

Figure 396.

Has natív felvétele

- elfordulás nélkül látszódnak az anatómiai képletek
- a rekesz jól ábrázolódik
- a gerinc a felvétel közepén legyen
- oldaljelzés szükségés

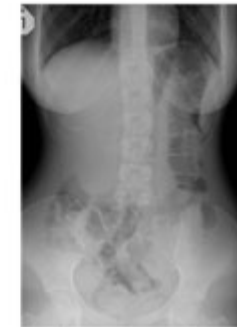

Figure 397.

Natív has felvétel állva

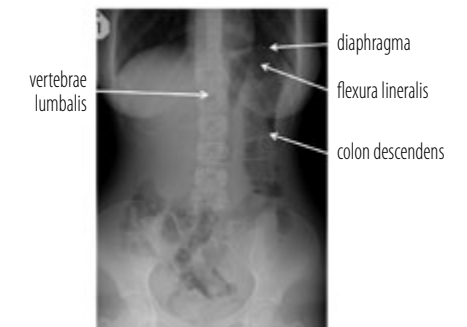


Figure 398.

If the patient is sick and he cannot be positioned erect or sitting, then we image the patient lying in a supine position to confirm the presence of a subdiaphragmatic gas collection. This technique is also used for confirming obstruction. With the patient lying on the left side (left decubitus position), free gas will rise, and it will be located between the lateral margin of the liver and the right lateral abdominal wall. To allow time for the gas to collect there, the patient should remain lying on the left side for 5 minutes before the exposure is made. With the patient lying on the right side, free fluid will rise, to be located between the liver and the right kidney, in the Morrison's sac. In this latter case, and ultrasound exam will be more informative.

(Figures 399., 400.)



Figure 399.

Natív has felvétel, baloldal fekvés, vízszintes sugárirány

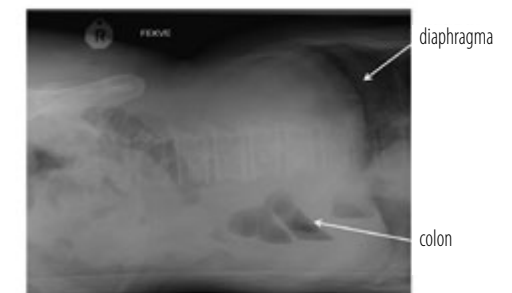


Figure 400.

Acute abdominal disorders

Ileus

Also called bowel obstruction; it is the failure of normal bowel function for any reason (mechanic, paralytic or combined). Due to failure of bowel transit, nutrients are deposited in the bowel and

together with the intraluminal gas, they form an air-fluid level or horizontal niveau. The typical x-ray image of small bowel ileus develops after 3-6 hours, while colonic ileus appears later.

X-ray signs of small bowel ileus (80%):

- above the obstruction there is liquid and gas accumulation
- abnormally distended bowel loops (4-7 cm), inverted U-shaped small-bowels
- valves of Kerckring (jejunum) are clearly visible due to air
- niveau (air-fluid level) formation in the middle of the abdomen

X-ray signs of large bowel ileus (20%):

- the loops of bowel above the obstruction are distended (10-15 cm) and they are filled with gas (large horizontal air-fluid levels are visible)
- the distended bowels are located laterally

(Figure 401.)

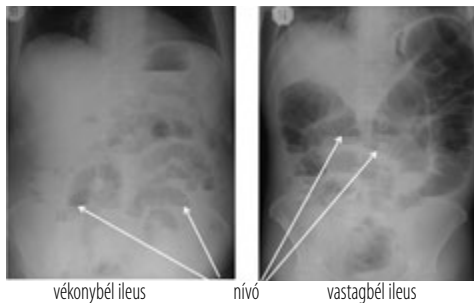


Figure 401.

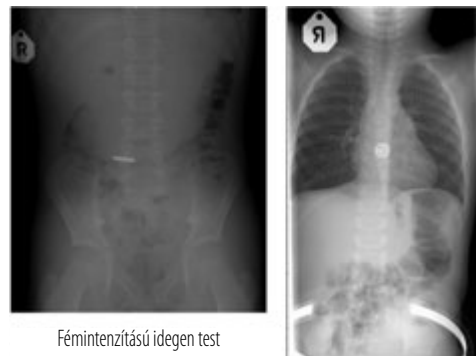

Figure 403.

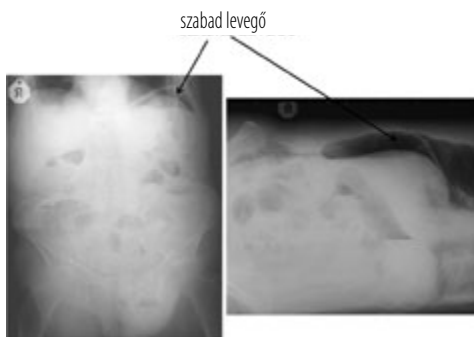

Figure 402.

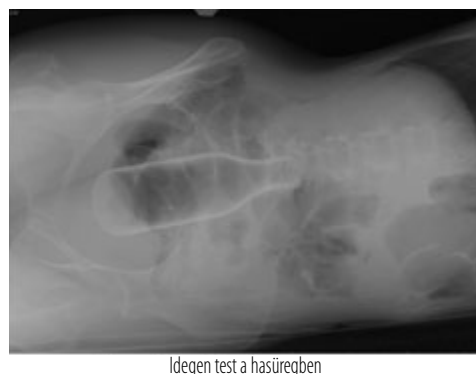

Figure 404.

Abdominal perforation

Symptoms: a sudden severe abdominal pain, after which, for a short time, the patient feels better, and then the pain increases again. Other symptoms are defense musculaire and bowel dysfunction. After perforation, free air rises and collects under one hemi-diaphragm. It is easier to detect it on the right, above the liver, because on the left it may easily superimpose on normal gastric air. In sigmoid perforation, air does not always reach the diaphragm. It may be located below the heart or between the intestines. In the latter case the loops of bowel are bordered by a double line of gas. In addition to air, liquid can also be visible, when large amounts of gastric or intestinal contents get into the abdominal cavity.

(Figure 402.)

False positive results (abdominal free air) may be detected 5-7 days after laparotomy and laparoscopy.

Foreign body

It is most frequent in children, but it can also occur in adults, who swallow or put various objects into their rectum.

(Figures 403., 404.)

III.13. X-ray anatomy and imaging technique of the urinary system

The excretory system is responsible for excreting, collecting and emptying urine.

The urinary system includes:

- two kidneys
- two ureters
- one urinary bladder
- one urethra

The **kidneys** are bean-shaped bodies. The lateral border of each organ is convex, and the medial border is concave. The left kidney is usually slightly longer and narrower than the right kidney. The kidneys are situated behind the peritoneum (retroperitoneal) and are in contact with the posterior wall of the abdominal cavity. The kidneys normally extend from the level of the superior border of T 12 to the level of the transverse processes of L3. The outer covering of the kidney is called the renal capsule. The capsule is a semi-transparent membrane that is continuous with the outer coat of the ureter. Each kidney is embedded in a mass of fatty tissue called the adipose capsule. The capsule and kidney are enveloped in a sheath of superficial fascia, the renal fascia, which is attached to the diaphragm, lumbar vertebrae, peritoneum, and other adjacent structures. The concave medial border of each kidney has a longitudinal slit, or hilum, for transmission of the blood and lymphatic vessels, nerves, and ureter. The hilum expands into the body of the kidney to form a central cavity called the renal sinus. The renal sinus is a fat-filled space surrounding the renal pelvis and vessels. Each kidney has an outer renal cortex and an inner renal medulla. The renal medulla, composed mainly of the collecting tubules that give it a striated appearance, consists of 8 to 15 cone-shaped segments called the renal pyramids. The apices of the segments converge toward the renal sinus to drain into the pelvicalyceal system. The more compact renal cortex lies between the periphery of the organ and the bases of the medullary segments and extends medially between the pyramids to the renal sinus. These extensions of the cortex are called renal columns. The essential microscopic components of the parenchyma of the kidney are called nephrons.

The **ureter** is the continuation of the renal pelvis. It has three parts:

- in the abdomen – pars abdominalis
- in the pelvic area – pars pelvina
- in the bladder (passes through the wall of the bladder) – pars-intramuralis

Each ureter descends behind the peritoneum and in front of the psoas muscle and the transverse processes of the lumbar vertebrae. The ureters enter the posterior wall of the bladder at the lateral margins of the superior part of its base and pass obliquely through the wall to their respective internal orifices.

The **urinary bladder** is a musculo-membranous sac that serves as a reservoir for urine. The bladder is situated immediately posterior and superior to the pubic symphysis and is directly anterior to the rectum in males and anterior to the vaginal canal in females.

The **urethra**, which conveys the urine out of the body, is a narrow, musculo-membranous tube with a sphincter type of muscle at the neck of the bladder. The urethra arises at the internal urethral orifice in the urinary bladder.

Indications:

Assessment of the kidneys, ureters, bladder, urethral lesions:

- developmental disorders
- stone
- inflammation
- neoplasms
- stenoses
- reversed flow (reflux)
- outcome of ESWL therapy

The X-ray examination, in all cases, must be preceded by an ultrasound examination.

Imaging methods

Plain ren and urinary bladder

The preliminary examination may consist of no more than an AP projection of the abdomen. When indicated, oblique and/or lateral projections are taken to localize calcium and tumor masses, and an upright position may be used to demonstrate the mobility of the kidneys. Preliminary radiography can usually demonstrate the position and mobility of the kidneys and usually their size and shape. This is possible because of the contrast furnished by the radiolucent fatty capsule surrounding the kidney. Around the kidneys and along the edges of the psoas muscles there is fatty tissue. If the fat lines are blurry, that may indicate inflammation. Intestinal gases, and superimposing organs can interfere judgment.

Patient positioning: The patient lies supine on the X-ray table, with the median sagittal plane of the body at right-angles to and in the midline of the table. The knees are flexed and the legs are pulled up, thus the kidneys move closer to the cassette.

Exposure borders: the upper edge is the xiphoid process, and the lower edge is 2 cm. below the symphysis pubis, while the lateral edges are soft tissues.

Film or image size: 30 × 40 cm

Focus-film distance: 100 cm

Centering: to the center of the line connecting the xiphoid process and the symphysis pubis.

Patient instruction: breath-hold

http://tamop.etk.pte.hu/tamop412A/Ke-palkotasi_gyakorlatok_tananyag/RTG/RTG_videok/52_vese_en.avi

(Figure 405.)

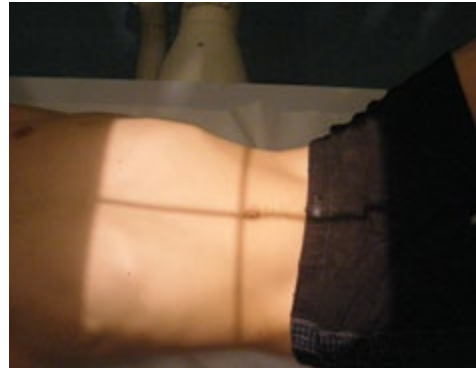

Figure 405.

Structures shown:

- abdomen without rotation
- the vertebral column in the center
- kidneys and bladder without motion bluntness
- side mark

(Figures 406, 407.)

Natív vese és hólyag felvétel

- a vesék és a húgyhólyag mozgási életlenség nélkül ábrázolódjon
- a has elfordulás nélkül (processus spinosusok a csigolyatestek közepén)
- gerinc a felvétel közepén

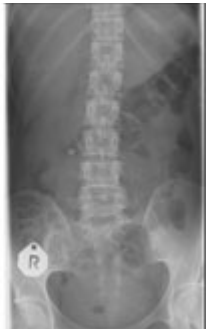

Figure 406.

Natív vese felvétel

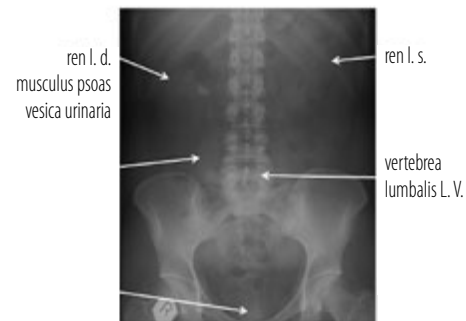

Figure 407.

Left or right plain kidney

Patient positioning: The patient lies supine on the X-ray table, with the affected side in the midline of the table. The knees are flexed and the legs are pulled up, thus the kidneys move closer to the cassette

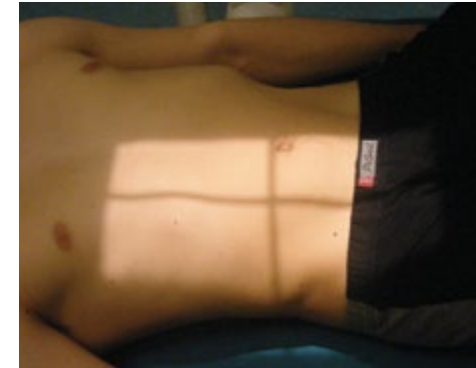

Figure 408.

Bal oldali natív vese felvétel

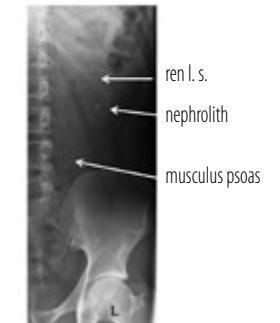


Figure 409.

Exposure borders: the upper edge is the xiphoid process, and the lower edge is 2 cm. below the symphysis, while the lateral edges are soft tissues.

Film or image size: 20 × 40 cm

Focus-film distance: 100 cm

Centering: to the center the line connecting the xiphoid process and the symphysis pubis.

Patient instruction: breath-hold

(Figures 408, 409.)

Pelvis plain

Patient positioning: The patient lies supine on the X-ray table.

Exposure borders: the upper edge is the iliac crest, and the lower edge is 2 cm. below the symphysis, while the lateral edges are the ASIS.

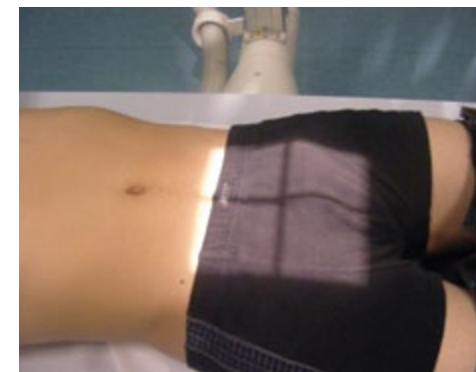

Figure 410.

Kismedence felvétel

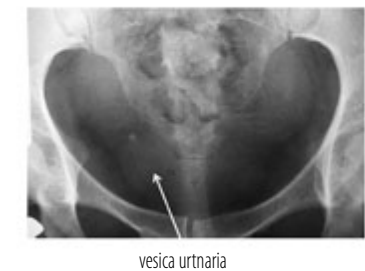

Figure 411.

Film or image size: 20 × 40 cm

Focus-film distance: 100 cm

Centering: with a 15 degree ray angle to the center of the line connecting the xiphoid process and the symphysis pubis.

Patient instruction: breath-hold

(Figures 410., 411.)

Excretory or intravenous urography (IVU)

The excretory technique is used for examining the upper urinary tracts. Since the contrast medium is administered intravenously and all parts of the urinary system are normally demonstrated, the excretory technique is correctly referred to as intravenous urography. This method may be used only if the kidneys are functioning.

Examination procedure:

The patient should empty the bladder before the examination.

Ask the patient about medication (metformin), thyroid disease, contrast allergies, etc.), then he or she should sign the consent form.

- take a plain kidney x-ray image
- intravenous administration of 40-60 ml iodinated contrast agent
- after intravenous iodinated contrast agent administration, images are taken at 7-15-30 minutes
- if necessary, late images are taken at 4-6-24 hours
- if necessary, images are taken with an empty bladder

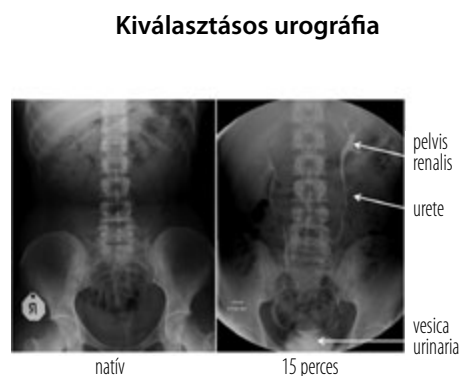

Figure 412.

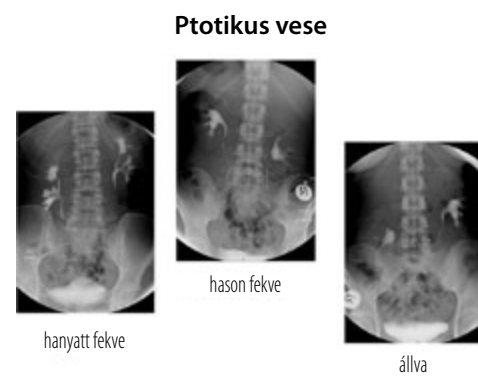


Figure 413.

Preparation:

- 3 × 20 ml syringes with contrast agent
- 1 × 10 ml syringe with saline
- tourniquet, skin disinfectant, plaster

A few minutes after contrast administration, the contrast material accumulates in the renal parenchyma, this is called a nephrogram. In case of a blockage, depending on its severity, excretion can be delayed up to 24 hours. On the nephrogram, a filling defect indicates a lack of functioning parenchyma. 5-10 minutes after contrast administration, the contrast medium outlines the cavity system, the ureters and the bladder. At the end of the investigation, the bladder is completely filled. Dynamics of urinary excretion and emptying, location of blockage, and its severity, can also be assessed with this method, however, the contrast medium may hide positive stones.

(Figures 412., 413.)

Retrograde urography

In some procedures involving the urinary system, the contrast material is introduced against the normal flow. This is called retrograde urography. The contrast medium is injected (10-20 ml) directly into the canals by means of ureteral catheterization for contrast filling of the upper urinary tract and by means of urethral catheterization for contrast filling of the lower part of the urinary tract. After this, targeted images are taken.

(Figure 414.)

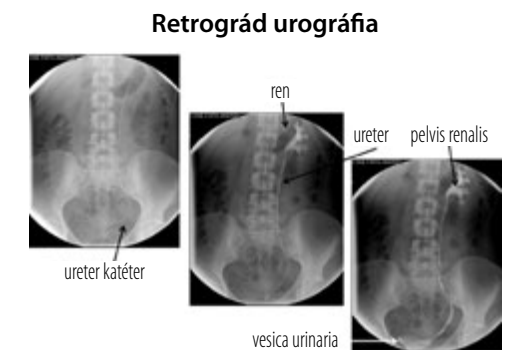


Figure 414.

Antegrade urography

Antegrade filling techniques allow the contrast medium to enter the kidney in the normal direction of blood flow. In selective patients this is done by introducing the contrast material (10-20) directly into the kidney through a percutaneous puncture of the re-

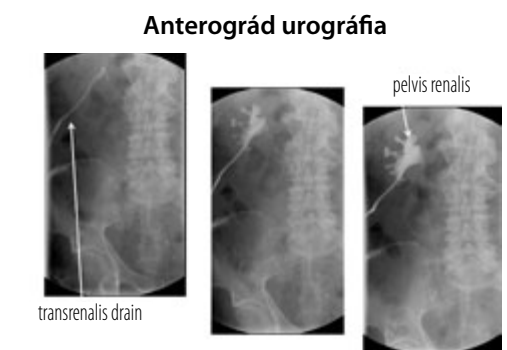


Figure 415.

nal pelvis; this technique is called percutaneous antegrade urography. After this, targeted images are taken.

(Figure 415.)

Cystography

For retrograde cystography, the contrast material is introduced into the bladder by injection or infusion through a catheter passed into position by way of the urethral canal. After this targeted images are taken. With this method, bladder lesions (tumour, diverticulum) and injuries can be assessed.

(Figure 416.)

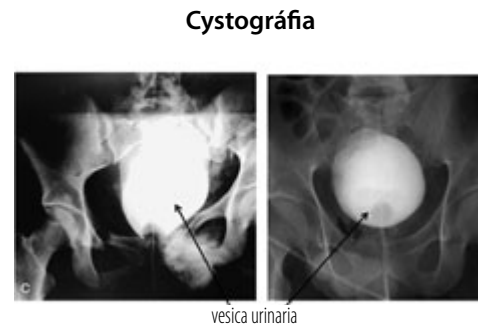


Figure 416.

Mictios urethro-cystografía

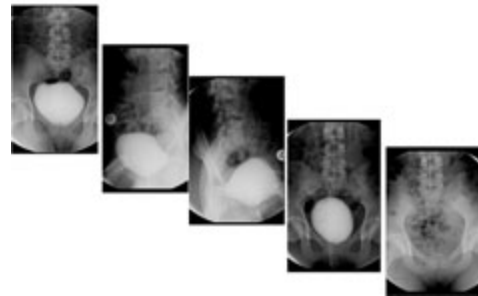


Figure 417.

Urination-urethro-cystography

It is used in babies and young children to detect vesicoureteral reflux. For urethro-cystography, the diluted contrast material is introduced into the bladder through a catheter (suprapubic percutaneous puncture) and images are generally taken in four projections: AP, right half-oblique, left half-oblique and during urination.

(Figure 417.)

Vesicoureteral reflux (VUR) is an abnormal movement of urine from the bladder into ureters or kidneys. Urine normally travels from the kidneys via the ureters to the bladder. In vesicoureteral reflux the direction of urine flow is reversed (retrograde).

Urethrografía

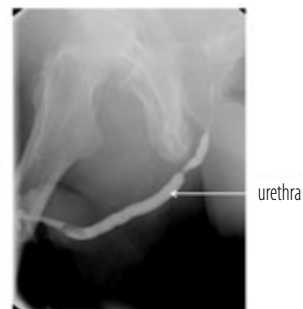

Figure 418.

Urethrography

In males, the contrast material is introduced into the urethra through a catheter. After this, targeted images are taken. It is used in case of stenosis and injury. In females, the only way to assess the urethra is by urination-urethro-cystography.

(Figure 418.)

III.14. X-ray anatomy and imaging technique of the gastrointestinal tract – part I.

According to x-ray morphology, the gastrointestinal tract is divided into:

- gastrointestinal tract (from mouth to the rectum)
- parenchymal organs, which form a functional unit with the gastrointestinal tract during digestion (liver, biliary tract, pancreas)

The main sections of the gastrointestinal tract:

- Oral cavity
- Esophagus
- Stomach
- Duodenum
- Small intestine: jejunum, ileum
- Large intestine: colon

The main diagnostic method of the GI tract is endoscopy, in which biopsy of the found lesion may be performed, and a histological diagnosis is available. Imaging is carried out for the assessment of the function (peristaltic, excretory), or when endoscopy can not be performed. For example, if the patient refuses to undergo endoscopy.

Esophagus

The esophagus is a long, muscular tube that carries food and saliva from the laryngopharynx to the stomach. The esophagus lies in the midsagittal plane. It originates at the level of the sixth cervical vertebra. The esophagus enters the thorax from the superior portion of the neck. In the thorax the esophagus passes through the mediastinum, anterior to the vertebral bodies and posterior to the trachea and heart. In the lower thorax the esophagus passes through the diaphragm at T 10.

It has 3 physiologic stenoses:

1. at the level of the laryngeal cartilages
2. at the level of the aortic arch and the main bronchus bifurcation
3. at the diaphragm

In the assessment of the most common diseases of esophagus (reflux, peptic ulcer, diverticulum, varices, scarring stenosis, tumour) endoscopy has a decisive role. X-ray imaging is done when the function needs to be assessed, or if endoscopy can not be performed (for instance when the patient refuses to undergo endoscopy).

Indications:

- congenital abnormalities (stricture, fistula)
- swallowing complaints (painful swallowing, inability to swallow)
- tumours
- foreign body swallowing

Esophagus examination

The esophagus may be examined by performing a full-column, single-contrast study in which only barium or another radiopaque contrast agent (positive contrast agent) is used to fill the esophageal lumen. Abnormal stenoses, dilatations, intraluminal filling defects, surpluses, and swallowing can be also judged. A double-contrast procedure may also be used. For this study, barium and carbon dioxide crystals (which liberate carbon dioxide gas) are the two contrast agents. Buscopan is necessary for the better assessment of the mucous membrane.

A positive contrast agent (barium preparation) is used unless there is:

- difficulty swallowing, aspiration, swallowing inability
- foreign body aspiration
- when perforation is suspected
- bleeding varices, bleeding tumor
- close postoperative period

For these cases, a water-soluble contrast medium is used.

Patient preparation:

No preliminary preparation of the patient is necessary.

Contrast material preparation:

- Barium or water-soluble contrast media
- Gas generating material

Tools preparation:

- plastic cups, spoons, straws
- kidney dish

- paper wadding
- gonad shield

Examination:

It is necessary to inform the patient about the details of the investigation. Remove all interfering objects from the examined body part (bras, necklaces, etc.). Start the fluoroscopic and spot-film examinations with the patient in a standing position whenever possible. Shield the gonads!

After the plain fluoroscopic examination, instruct the patient to take the cup containing the barium suspension in the left hand and to drink it on request. The radiologist asks the patient to swallow several mouthfuls of the barium so that the act of deglutition can be observed to determine whether any abnormality is present. Use the horizontal and Trendelenburg positions

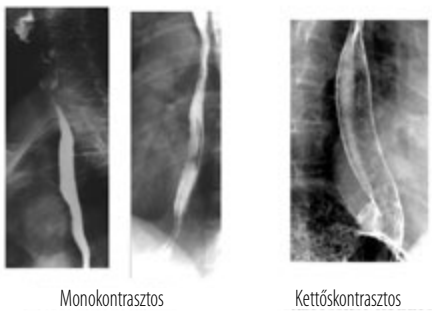Nyelőcső vizsgálat

Figure 419.

At the level of the Th. II.–III. vertebrae the esophagus is dislocated to the left. The lumen is a little bit thinner than usual, and there is a concave depression on its lateral contour– retrosternal struma.

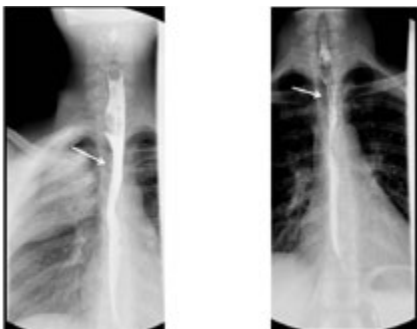


Figure 421.

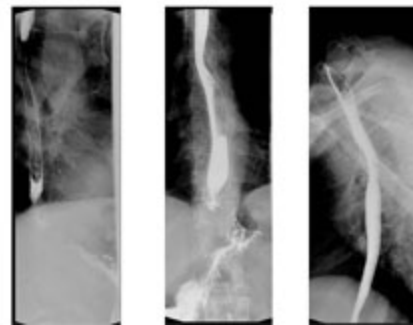aaa

Figure 420.

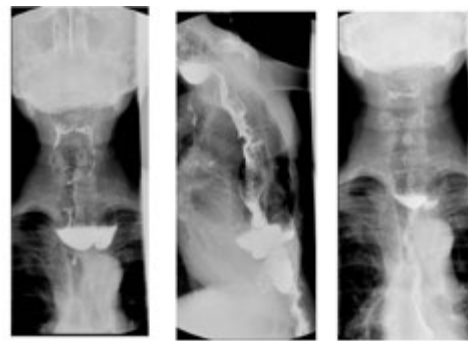
Esophagus removal with large intestine replacement

Figure 422.

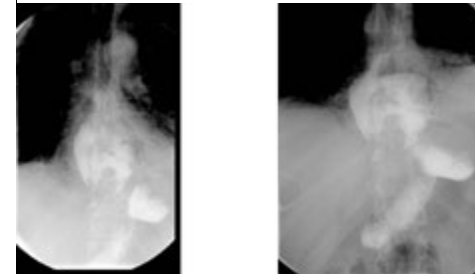
Ruptured esophagus: water-salable contrast agent appears in the mediastinum at level of the Th VII. vertebra

Figure 423.

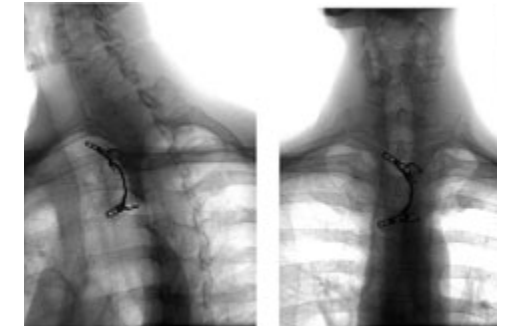Foregin body (denture) in the esophagus

Figure 425.

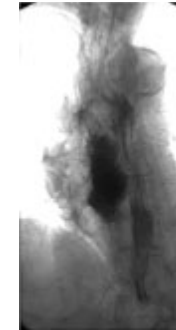
Perforated esophagus

Figure 424.

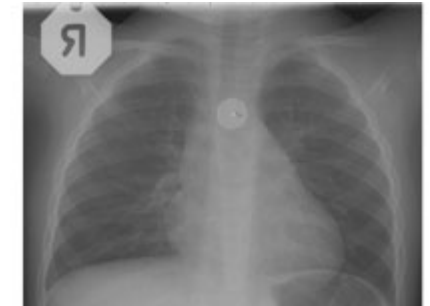Kisgyermek mellkas felvétel, idegentest (rajzszeg) a nyelőcsőben

Figure 426.

(Figures 419 a., b.) – to assess cardiac function, and to detect reflux – as indicated. The radiologist instructs the patient to perform various breathing maneuvers under fluoroscopic observation so that spot radiographs of areas or lesions not otherwise demonstrated can be obtained.

(Figures 419., 420.)

(Figures 421–426. Pathologies)

Stomach

The stomach is the dilated, saclike portion of the digestive tract extending between the esophagus and the small intestine. Its shape shows a high degree of individual variation. The stomach is divided into five parts:

- cardia
- fundus

- body
- antrum
- pyloric portion

The stomach has an anterior and a posterior surface. The right border of the stomach is marked by the lesser curvature. The left and inferior borders of the stomach are marked by the greater curvature.

Indications:

For common diseases of the gastro-duodenal tract (gastritis, peptic ulceration, scarring, cancer, pyloric stenosis) endoscopic examination has a decisive role. Conventional X-ray examination of this region should be performed when endoscopic examination can not be performed (functional), the lesion cannot be reached by endoscopy (below stenosis), detection of hiatal hernia, and after gastric surgery.

Gastric examination

The stomach may be examined by performing a full-column, single-contrast study in which only barium or another radiopaque contrast agent (positive contrast agent) is used to fill the stomach's lumen. Abnormal stenoses, dilatations and intraluminal filling defects can also be judged.

A double-contrast procedure also may be used. For this study, barium and carbon dioxide crystals (which liberate carbon dioxide gas) are the two contrast agents. Buscopan is necessary for the better assessment of the mucous membrane. The duodenum also should be examined during gastric examination.

Patient preparation:

The stomach must be empty for an examination of the upper gastrointestinal tract (the patient did not eat, drink, or smoke the night before the examination). Due to secretion, it is recommended to perform the examination in the morning.

Contrast material preparation:

- Barium or water-soluble contrast media
- Gas generating material
- Smooth muscle relaxants (Buscopan or Glucagon). If the patient has glaucoma, Buscopan can not be used; in this case, use Glucagon. The principal advantage of the relaxant is that small lesions are less easily obscured, and the mucosal lining of the stomach can be more clearly visualized.

Tools of preparation:

- plastic cups, spoons, straws
- kidney dish
- paper wadding
- skin disinfectant, tourniquet, needles, syringes, bap, plaster

Examination:

Inform the patient about the the examination. Remove all interfering objects from the examined body part. To begin the examination, place the patient on the fluoroscopic table in a standing or a supine position. Take a plain chest or abdominal x-ray image of the patient, then give the patient a gas-producing substance. Give the patient a small amount of commercially available high-density barium suspension. Place the patient in a recumbent position, and instruct him or her to turn from side to side or to roll over a few times. This movement serves to coat the mucosal lining of the stomach as the carbon dioxide continues to expand. Just before the examination the patient may be given glucagon. Conventional images obtained after the fluoroscopic examination may be the same as those obtained before the contrast examination. Use the horizontal and Trendelenburg positions – to assess cardiac function, and to detect reflux – as indicated.

During gastric examination, the stomach's shape, wall, contour and size, its lower pole's relationship to the iliac crest, peristalsis, pyloric function, and gastric emptying can all be assessed.

(Figures 427., 428.)

Indications for imaging after gastric surgery:

In the early postoperative period (about 6 weeks), a water-soluble contrast agent is used to assess emptying of the gastric stump, and to detect any postoperative complication (anastomotic leakage, fistula, abscess). Detection of delayed postoperative complications such as ulcer recurrence, tumour recurrence, and dumping syndrome (after Billroth II. resection).

Gyomor vizsgálat

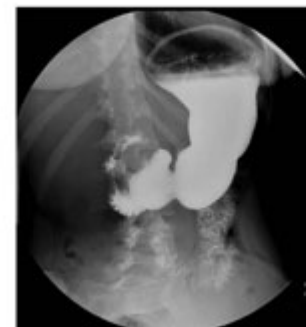


Figure 427.

Gyomor vizsgálat

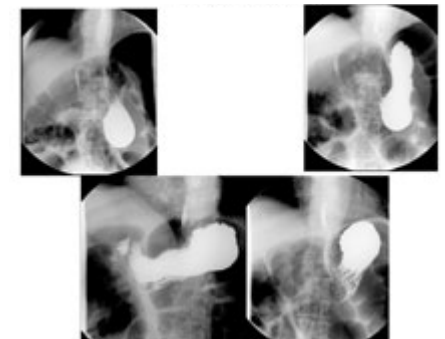


Figure 428.

Gastrointestinal passage

Patient preparation and the examination procedure is the same as in the case of plain gastric imaging, except that the patient drinks more contrast material. 2-4-6-24 hours after the patient swallowed the contrast material, the radiologist takes x-ray images in accordance with the rate of excretion.

(Figure 429.)

Gyomor–bél passage vizsgálát

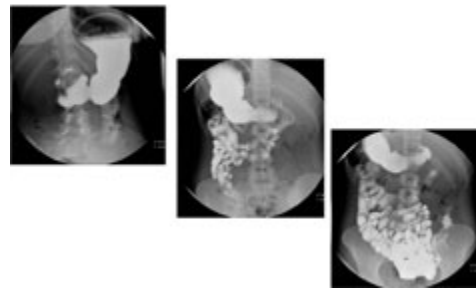


Figure 429.

III.15. X-ray anatomy and imaging technique of the gastrointestinal tract – part II.

Small intestine: The small intestine extends from the pyloric sphincter of the stomach to the ileocecal valve, where it joins the large intestine at a right angle. The length of the adult small intestine averages about 4-6 meters. The mucosa of the small intestine contains a series of finger-like projections called villi, which help facilitate the process of digestion and absorption. The small intestine is divided into four parts:

- duodenum
- duodenojejunal flexure
- jejunum
- ileum

Beyond the duodenum, the small intestine is arbitrarily divided into two parts, with the upper two fifths referred to as the jejunum and the lower three fifths as the ileum. The jejunum and ileum are gathered into freely movable loops, or gyri, and are attached to the posterior wall of the abdomen by the mesentery.

Indications:

- congenital anomalies (jejunal atresia, meconium ileus, malrotation, Meckel's diverticulum)
- inflammatory lesions (Morbus Crohn)
- tumours

This region is not available for endoscopy, so the importance of the radiological examination is stressed. Plain testing comes into play in emergency cases, where gas contents, fluid levels, the possible presence of free air can be judged.

During a so called "High Passage" test, we can follow the passage of the contrast agent, and we may also assess rough lesions. This method is not suitable for the detection of subtle lesions. The basic conventional radiographic procedure is selective enterography, because most lesions can be safely detected with it (Crohn's disease and other enteritis, diverticulitis, tumours).

"High-passage"

Patient preparation and the examination procedure is the same as in the case of plain gastric imaging, except that the patient drinks more contrast material. 2-4-6-24 hours after the patient

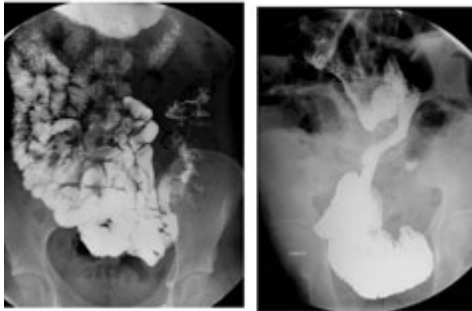Gyomor–bélpasszázs vizsgálat I.

Figure 430.

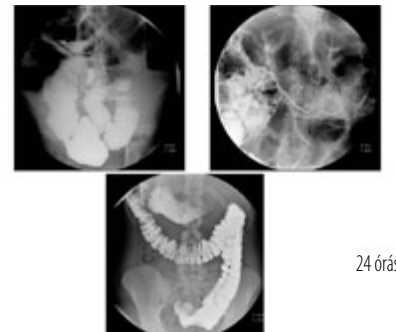
Gyomor–bélpasszázs vizsgálat II.

Figure 431.

24 órá

swallowed the contrast material, the radiologist takes x-ray images in accordance with the rate of excretion

(Figures 430., 431.)

Selective enteroclysis

Enteroclysis (the injection of nutrient or medicinal liquid into the bowel) is a radiographic procedure in which contrast medium is injected into the duodenum under fluoroscopic control for examination of the small intestine. The contrast medium is injected through a tube which is inserted through the nose or mouth and passed into the duodenum. It is a double contrast examination in which the positive contrast agent is barium sulfate, and the negative contrast agent is methylcellulose.

Patient preparation:

The day before the examination fiber-free meals, lots of liquid, and 1 liter of laxative liquid consumption is allowed, but the patient should not have dinner the night before. The patient does not eat nor smoke on the day of the examination. In the morning, the patient can drink a little, but he can only take that medication which he was told by his doctor.

Contrast material preparation:

1 day before the examination one bag of methylcellulose is mixed with 200 ml of warm water. After dissolution, it is diluted in 1800 ml water and stored in a refrigerator. It is removed from the refrigerator in the morning of the examination and stored at room temperature. Mix 300 ml of Micropaque with 600 ml of water.

Tools preparation:

- 2 ml of Buscopan or Glucagon
- skin disinfectant, tourniquet, sterile bun, plaster
- disposable oral trans (Bilbao-Dotter) v. transnasal tube
- injector, or 3-5 pieces of 50 or 100 ml syringes (for the injection of contrast material)
- 3-5 plastic cups
- lidocaine anesthetic throat spray
- disposable gloves
- paper wadding, kidney dish

Examination:

Inform the patient about the the examination. Remove all interfering objects from the examined body part. The radiologist applies the Lidocaine spray on the patient's throat. Under fluoroscopic control, a tube with a stiff guidewire is advanced to the end of the duodenum at the duodenojejunal flexure, near the ligament of Treitz. 300 ml of barium is then installed through the tube at a rate of approximately 75 ml/minute. Spot radiographs are taken. Then, 600-800 ml of barium is installed through the tube. After this, 1.2-1.8 l methylcellulose is injected into the small intestine. The patient gets the relaxant. After fluoroscopic examination of the patient's small intestine, radiographs of the small intestine may be requested.

(Figure 432.)

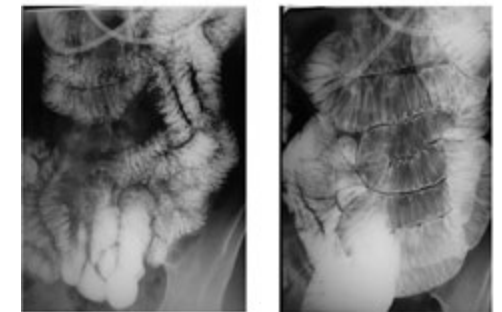
Szelektív enterográfia

Figure 432.

Large intestine: The large intestine begins in the right iliac region, where it joins the ileum of the small intestine, forms an arch surrounding the loops of the small intestine, and ends at the anus.

The large intestine has eight parts:

- cecum (vermiform appendix, ileocecal valve)
- ascending colon
- right colic-flexure
- transverse colon
- left colic-flexure
- descending colon
- sigmoid colon
- rectum

Indications:

- congenital anomalies (anorectal atresia, microcolon, Hirschsprung's disease)
- diverticulum
- inflammation (ulcerative colitis, Crohn's disease)
- tumour

Examination methods:

The primary examination method of the colon is colonoscopy, during which biopsy is also available. The double contrast test is used to assess subtle mucosal differences.

Due to risk of perforation, in the acute phase of an inflammatory process this method is avoided.

Patient preparation:

It is the same as described for imaging the small intestines.

Contrast material preparation:

The positive contrast agent is a barium containing material, and the negative agent is air (water soluble contrast agent, if necessary)

Tools preparation:

- 2 ml of Buscopan or Glucagon in a syringe (in glaucoma only Glucagon is used)
- skin disinfectant, tourniquet, sterile bun, plaster
- disposable gloves
- paper wadding, kidney dish

Examination:

The patient is undress completely, and he is covered with a sheet. The patient lies on his side on the examining table. The filler pipe with jelly is introduced into the anus, then plastered securely. The doctor administers the muscle relaxant intravenously. The patient turns onto his left side holding on to the handle. The radiologist puts the patient in a Trendelenburg position, and, according to the doctor's instructions, the assistant intermittently gives the contrast agent, finishes the enema, and starts the air intake. The air intake also occurs intermittently. When the contrast material reaches the coecum, the patient is returned to a supine position. Spot radiographs are taken in various position. At the end of the examination the patient may leave and empty his bowels.

(Figures 433, 434.)

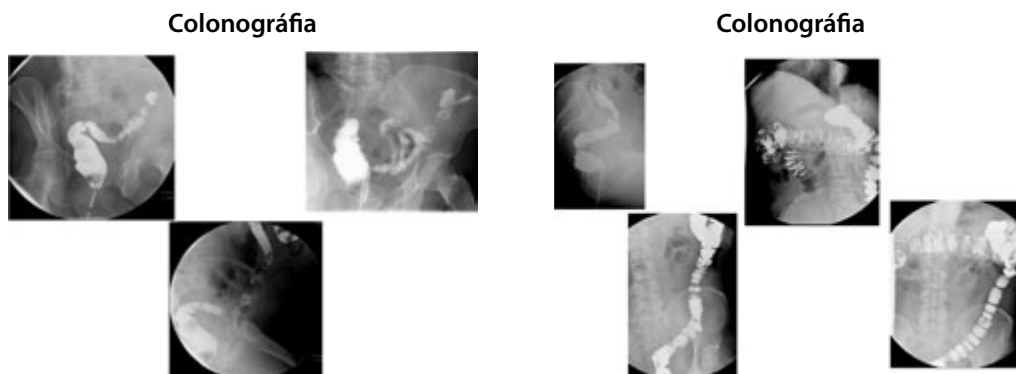


Figure 433.

Figure 434.

III.16. X-ray anatomy, imaging technique and interventional procedures of the breast

Mammography is the radiographic examination of the breast tissue (soft tissue radiography). To visualize normal structures and pathology within the breast, it is essential that sharpness, contrast and resolution are maximized. This optimizes, in the image, the relatively small differences in the absorption characteristics of the structures comprising the breast. A low kVp value, typically 25-35 kVp, is used. Radiation dose must be minimized due to the radio-sensitivity of breast tissue. A small focus and a fine-grain x-ray film provide good resolution.

The mammography system comprises:

- a high-voltage generator (22-35 kV range)
- X-ray tube with molybdenum rotating anode
- two foci: 0.4 mm at base mode; 0.1 mm at magnification
- automatic exposure control (AEC) system
- reciprocating anti-scatter grid
- cassette holder (adjustable, depending on the breast size 18 × 24 and 24x30) and detector
- moving Bucky with fine grid
- plexi compression device (hand and foot controlled)

(Figures 435–437.)

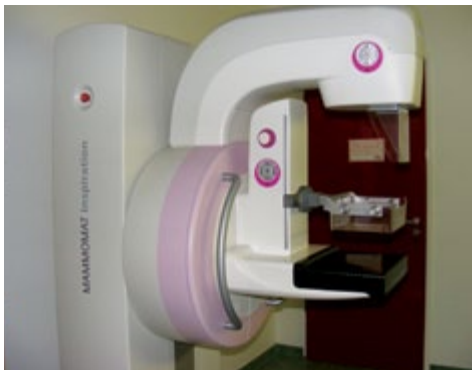

Figure 435.



Figure 436.

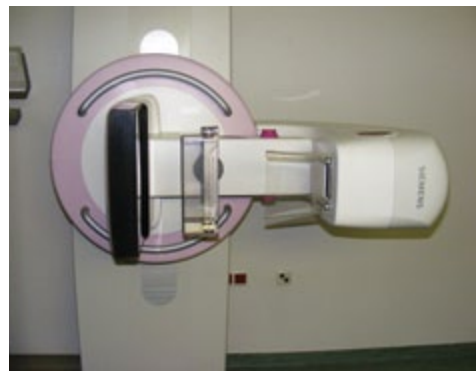

Figure 437.

The mammography equipment also has targeted and direct magnification options; vector plate, perforated plate for pin biopsy and 2D preoperative localizations; interventional covers for stereotaxic (3D localization).

(Figure 438.)



Figure 438.

Basic terms:

Screening mammography: Women between the ages of 45 and 65 should undergo bilateral mammography every two years.

Diagnostic mammography: All patients with clinical evidence of significant or potentially significant breast disease should undergo a diagnostic mammogram.

Anatomy of the breast

The breast is composed of glandular, fibrous and fatty tissue. Its size, shape and consistency vary significantly, depending on the patient's size, shape and age. Each breast consists of 15–20 lobes, each of which is divided into several lobules. The lobules comprise large numbers of secretory alveoli, which drain into a single lactiferous duct for each lobe, before converging towards the nipple into the ampullae before opening onto the surface. The blood supply is derived from branches of the axillary, intercostal and internal mammary arteries. With increasing age, and especially after the menopause, the glandular elements of the breast become less prominent and tend to be replaced by adipose tissue (fat).

Cranio-caudal

Patient positioning: The woman faces the machine, with her arms by her sides. She is standing and is rotated 15–20 degrees to bring the side under examination close to the horizontal breast-support table. The nipple should be in the midline of the breast and in profile.

Structures shown:

- the shadow of the pectoralis muscle is convex, we can follow it to the line of the mamilla
- the inframammary skin fold visualized
- the whole glandular structure is visible
- nipple is in profile

Emlő cranio-caudalis felvétele

- teljes mirigyállomány ábrázolódjon
- a pectoralis izomszél látszódjon
- emlőbimbó profilban van
- a bőr nem gyűrődik meg

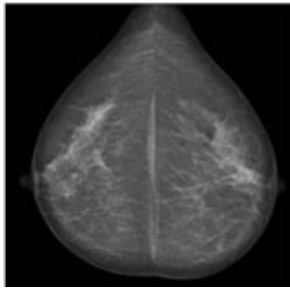


Figure 439.

- skin does not crinkle
- breast does not hang

(Figures 439., 440.)

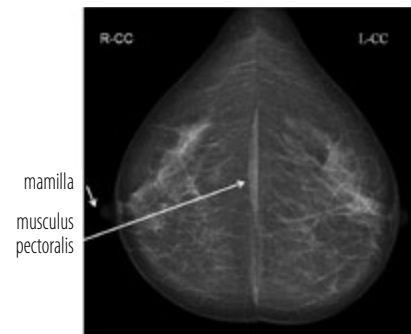
Emlő cranio-caudalis felvétele

Figure 440.

Medio-lateral oblique

Patient positioning: The woman faces the equipment, with the breast about to be examined closer to the breast-support table. The woman's arm is placed on the top of the table, with the elbow flexed and dropped behind it. The table height is adjusted so that the lower border of the breast is 2–3 cm above the edge of the film. The nipple must be in profile and about a third of the way up the film. To ensure that the entire breast back to the chest wall margin is included, the infra-mammary skin fold should be included if possible.

Emlő medio-lateralis félferde felvétele

- a pectoralis izom árnyéka konvex, a mailla vonaláig követhető
- alsó áthajlási redő ábrázolódik
- bimbó profilban van
- a bőr nem gyűrődik
- emlő nem lóg

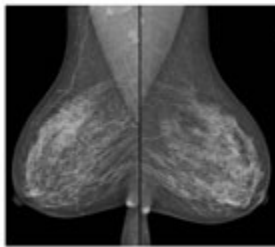


Figure 441.

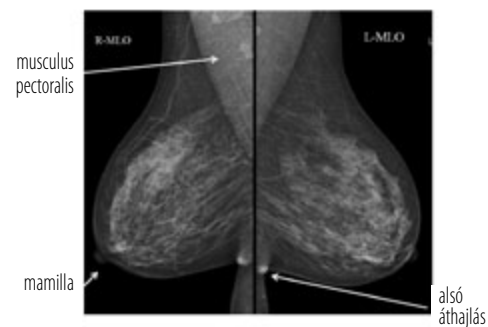
Emlő medio-lateralis félferde felvétele

Figure 442.

Structures shown:

- the shadow of the pectoralis muscle is convex, we can follow it to the line of the mamilla
- the infra-mammary skin fold visualized
- nipple is in profile
- skin does not crinkle
- breast does not hang

(Figures 441., 442.)

High-quality mammography images require appropriate compression. With compression the diameter of the breast decreases, the structures within the breast parenchyma are flattened, assessment is easier, and radiation exposure decreases as well as motion blur.

The two breast images have to be symmetric and the skin should not be crinkled.

(Figure 443.)

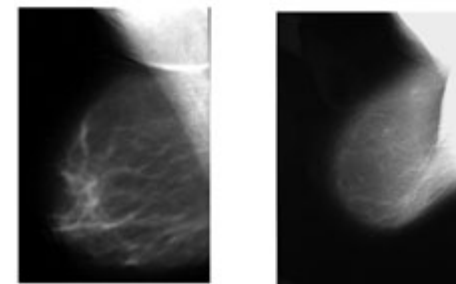
Felvélettechnikai hiba

Figure 443.

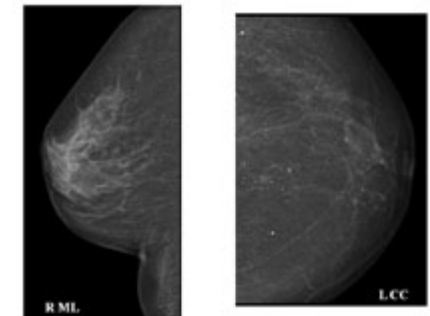
Lateralis felvétel

Figure 445.

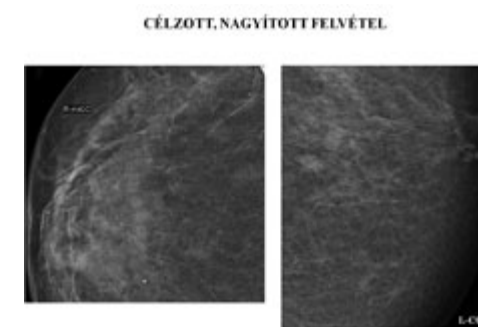
Céltolt, nagyított felvétel

Figure 444.

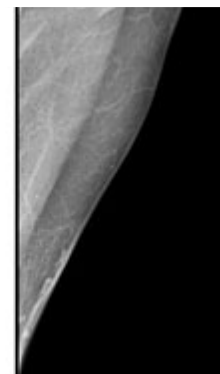Bal axillaris régió

Figure 446.

Targeted images can be taken for a more accurate characterization of the lesions.
(Figure 444.)

Lateral images provide accurate localization.
(Figure 445.)

Cleopatra images are appropriate to clarify lesions that are located in the axillary region.
(Figure 446.)

Ductography

When a nipple discharge is present in one of the multiple duct openings on the nipple, the milk duct can be studied using iodinated contrast medium. The purpose of the examination is to rule out an intraductal mass as the possible cause of the discharge. Upon successful injection, images can be obtained immediately.

(Figure 447.)

Galactográfia

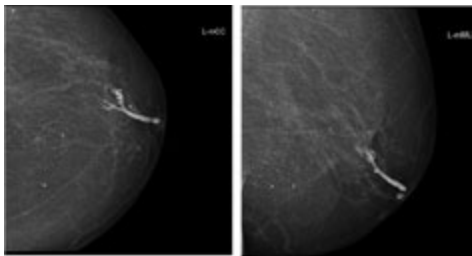


Figure 447.

Műtét előtti drótjelölés

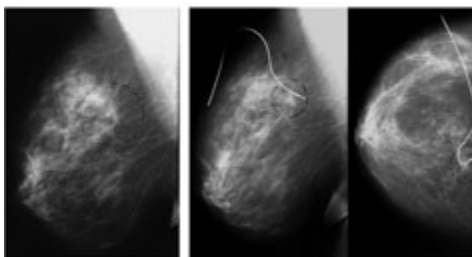


Figure 448.

Breast interventions

- FNA (fine-needle aspiration) or core biopsy can be done with the freehand technique in palpable lesions, while impalpable lesions produce unique problems.
- If necessary, the fluid can be drained out of a cyst, relieving any pressure it may have been causing.

Specimen mammográfia

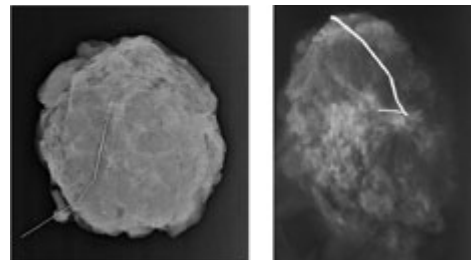


Figure 449.

- The marker wire that is used instead of the fine needle or the biopsy gun will depend on the preferences of the surgeon performing the biopsy or excision. The purpose of this localization is for a marker wire to be placed accurately in the breast lesion so that the surgeon can perform a diagnostic biopsy of the lesion. It is essential that the marker wire tip lies within the lesion so accurate assessment of the depth of the abnormality in the compressed breast is made. The position of the wire in relation to the abnormality in the breast must therefore be checked mammographically after marker insertion.

(Figure 448.)

- Specimen radiography is often performed shortly after excision, while the patient is still under anesthesia. Based on this, we decide whether the lesion has been removed and if the surgical margins are sufficient.

(Figure 449.)

III.17. Special x-ray examinations

External fistulas: Abnormal connection between an organ and the body surface. It can be due to a developmental disorder, cancer or it may occur as a complication of surgery.

Patient preparation:

No preliminary preparation of the patient is necessary.

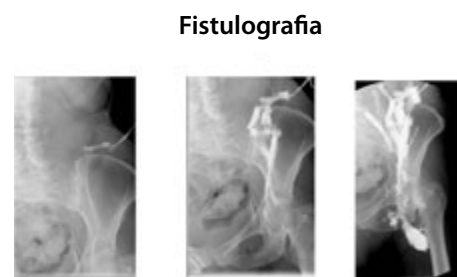Tools preparation:

- water-soluble contrast agent (10-30 ml)
- 10-20 ml of sterile syringes
- gloves
- skin disinfectant
- plaster

Examination:

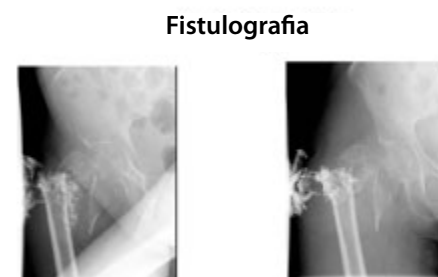After filling up the fistula with contrast material, the radiologist takes images in different positions. (Figures 450, 451.)

Internal fistulas: Abnormal connections between organs and body cavities. It can occur as a result of malformation, Crohn's disease, cancer, radiotherapy, or it may be a postoperative complication.



Retroperritonealis draenen befecskendezett kontrasztanyag tág, elágazódó fistula járatot rajzolt ki a vese hilus magasságától az inguialis hajlatig

Figure 450.



Combnyaktörés után kialakult sipolyjáratból a combcsont körül kettő szabálytalan 5-6 cm-es telődött

Figure 451.

Examinations:

For detecting fistulas between the gastrointestinal organs, we can perform a gastric emptying study, enterography or colonography. For detecting the fistulas of the urinary system, cystography, excretory urography, antegrade or retrograde urography can be performed.

For detecting internal fistulas, only water-soluble contrast media should be used.

Arthrography

Arthrography is a procedure involving multiple x-rays of a joint, using a fluoroscope. A contrast medium is (iodine solution) injected into the joint area helps highlight structures of the joint.

Sialography

Sialography is the term applied to the radiologic examination of the salivary glands and ducts with the use of a contrast material, usually one of the water-soluble iodinated media. After injection of the contrast material, x-ray images are taken.

Dacryocystography

Dacryocystography is the radiographic visualization of the lacrimal sacs and associated structures after injection of a contrast medium.

HSG

Hysterosalpingography is a radiologic procedure to investigate the shape of the uterine cavity and the shape and patency of the fallopian tubes. It entails the injection of a radio-opaque material into the cervical canal, and it is usually performed under fluoroscopic guidance with image intensification. To demonstrate tubal rupture, spillage of the material into the peritoneal cavity needs to be observed.

ERCP

Endoscopic retrograde cholangiopancreatography is a procedure used to diagnose biliary and pancreatic pathologic conditions. ERCP is a useful diagnostic method to visualize stenosis, in-

dentation, obstruction, filling defects and surpluses, and to guide therapeutic intervention (papillotomy, stone removal and drain implant). ERCP is performed by passing a fiberoptic

endoscope through the mouth into the duodenum, to the Vater ampulla under fluoroscopic control.

(Figure 452.)

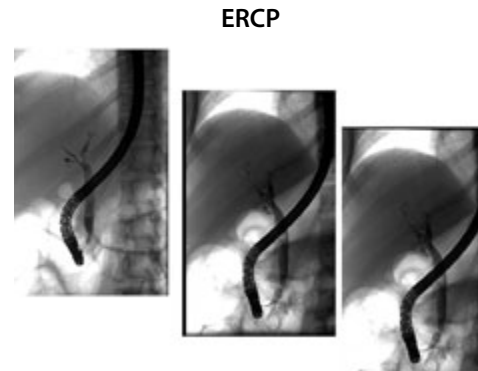


Figure 452.

III.18. X-ray imaging of polytrauma patients

Polytrauma: several body regions are injured while, an internal body cavity is also damaged, all of which lead to a state of shock.

Multiple and combined traumatization:

several body regions are damaged at the same time, but this will not lead to general deterioration.

Injuries usually occur during accidents, during which a sudden, external force causes adverse health effects.

(Figure 453.)

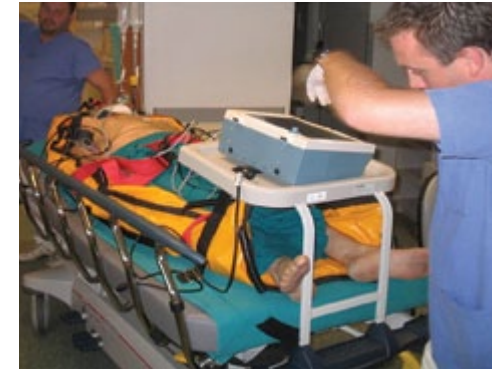

Figure 453.

The polytrauma patient care can be divided into four phases:

1. Alpha phase

After the patient is transported into the emergency department, in the first 5 minutes, measures are taken against direct life-threatening causes. Diagnostic imaging does not occur at this point.

2. Bravo phase

Five minutes after arrival to the emergency department, the following imaging procedures are done on-site :

- Chest images to rule out PTX, HTX, contusion, rib fracture with large dislocation, aspiration, and for the assessment of the mediastinum.
- Lateral images of the cervical spine for the assessment of an unstable fracture associated with a high grade dislocation.
- Pelvic images for the detection of an unstable fracture associated with high grade dislocation
- Ultrasonography for the examination of the liver, spleen, and to rule out large amounts of free abdominal fluid.

3. Charlie phase

30 minutes later, in the radiology department, a multislice spiral CT examination is done with skull, spine, chest, and abdominal polytrauma protocols.

4. Delta phase

After the CT, additional images are taken for the completion of diagnosis and for primary treatment. Controll studies are done during this phase.

Quiz

Simple choice

There is only one good answer

Multiple choice

There are more than one good answer

Correlation analysis

- A The statement and the justification are true, and the justification explains the statement.
- B The statement and the justification are true, but the justification does not explain the statement.
- C The statement is true, but the justification is false
- D The statement is false, but the justification is true
- E The statement and the justification are both false

1. Conventional radiology and the radiology workplace

Simple choice

1. When was X-ray discovered?

- A 1890
- B 1895
- C 1902

Multiple choice

2. What are the basic imaging tools of conventional radiology?

- A summation images
- B fluoroscopy
- C conventional x-ray tomography

2. X-ray photography

Simple choice

3. What are the consequences of central projection?

- A magnification, contrasty, summation, oblivescence
- B magnification, distorsion, summation, density
- C magnification, distorsion, summation, oblivescence
- D filmy, distorsion, summation, oblivescence

4. The following is characteristic of X-rays:

- A parallel
- B divergent
- C convergent

5. Does the shape of a spherical object change, if it is placed in an eccentric position?

- A yes, it does
- B no, it does not

Multiple choice

6. The extent of magnification depends on:

- A the FOD (film-object distance), if the distance is increased, magnification decreases – there is an inverse ratio between them
- B the FOD, if the distance is increased, magnification increases as well – they are directly proportional to each other
- C the OFD, if the distance is increased, magnification decreases – there is an inverse ratio between them
- D the OFD, if the distance is increased, magnification increases as well – they are directly proportional to each other

Correlation analysis

7. Motion unsharpness arises if the patient, or the x-ray tube or the cassette moves, that is why, if the patient is unable to hold still, you must use fixing tools and a short acquisition time.

3. Introduction to radiographic imaging techniques

Simple choice

8. What kind of patient positioning is not used?

- A standing
- B sitting
- C laying
- D kneeling

Multiple choice

9. Which of the following are characteristic of hard beam technology:

- A A high tube voltage of 100-150 kV and a lower mAs are used.
- B It provides more detailed images, especially when used for bone imaging
- C It improves efficient beam usage - under the same tube loading, a higher energy radiation is created.
- D The patient receives more radiation compared to the conventional imaging technique.
- E It decreases the radiation absorbed by the body.
- F We apply this technique almost exclusively when imaging the lungs and the chest.

10. Characteristic of the soft beam technology:

- A It is suitable for emphasizing the contrast difference of soft tissues; the idea is to harmonize contrast.
- B A low tube voltage of 25-50 kV, and a high mAs value are used.
- C It decreases the radiation absorption difference between soft tissues.
- D The patient receives less radiation.
- E It can show the presence of a pathological processes that causes a change in tissue contrast compared to the physiological state.
- F It's main area of application is mammography

11. What kind of beam directions can we use?

- A antero-posterior
- B medio-lateral
- C cranio-caudal
- D caudo-cranial

12. Underline the basic planes used in analogue radiography:

- A coronal plane
- B axial plane
- C median sagittal plane
- D sagittal plane
- E lateral direction

Correlation analysis

13. X-ray has no harmful effect, that is why x-ray imaging may be carried out even if the patient is pregnant.

14. We apply the hard beam technique when imaging the lungs and the chest, because with this technique, the chest and the lungs are more detailed and the ribs do not interfere with the evaluation of the lungs.

4. X-ray anatomy and imaging technique of the shoulder girdle and the humerus*Simple choice***15. How do you take a shoulder x-ray image?**

- A The arm is prone.
- B The arm is supine.

16. When taking a transthoracic shoulder image:

- A We can acquire images of the humerus with good bone structure detail.
- B We can adjudge fractures and/or dislocations of the surgical neck and luxation of the shoulder
- C We are allowed to acquire one only on the clinician's request.

17. How can we acquire a clavicle x-ray image?

- A in the axial direction
- B in the PA direction
- C in the AP direction

*Multiple choice***18. After a traumatic injury how do you take an AC joint x-ray image?**

- A Always take comparative x-ray images, if the patient is slim acquire the image in one exposition
- B Take only a two way x-ray image of the injured side
- C Take a two way x-ray image of the injured side and an AP image of the intact side
- D Always take comparative x-ray images separately, in a symmetric position

Correlation analysis

19. In case of a traumatic injury we always take comparative x-ray images of the AC joint, because both joints are damaged.

5. X-ray anatomy and imaging technique of the upper limb*Simple choice***20. In case of a suspected scaphoid bone fracture, is it enough to take a two way wrist x-ray image?**

- A Yes, it is enough
- B No, it is not enough

21. When imaging the hand in the lateral direction:

- A The hand is totally in a lateral position; it rests on the fifth finger.
- B From the basic AP position, the hand is externally rotated 45 degrees with the fingers extended.

22. Where do you center in case of an AP wrist x-ray?

- A To the middle of the distance between the two styloid processes, in other words, to the middle of the joint
- B To the head of the third metacarpus
- C To the center of the hand

*Multiple choice***23. In case of an elbow x-ray image:**

- A The patient's arm is in a comfortable position.
- B The shoulder is lowered to the same level as the elbow joint.
- C In case of a lateral image, the forearm and the humerus are 90 degrees to each other.
- D In case of a lateral image the forearm and the humerus are 45 degrees to each other.

*Correlation analysis***24. In case of a fracture of the surgical neck of the humerus we take an AP x-ray image, because on the transthoracic image the bony structure of the humerus cannot be assessed.****6. X-ray anatomy and imaging technique of the pelvis and the lower limb***Simple choice***25. In case of a pelvis x-ray:**

- A Both legs are extended
- B Both legs are extended and both feet are rotated about 15 degrees medially (so that the femoral necks are projected without shortening)
- C Both legs are extended and the feet are rotated laterally

26. Where do you center in case of a pelvis x-ray?

- A Midway between the upper border of the pubic symphysis and the iliac crest
- B To the umbilicus
- C Inferior to the patellar apex by approx 1 cm

27. In case of an injury of the proximal third of the tibia which joint has to be on the image as well?

- A The knee
- B The ankle
- C Both the knee and the ankle

28. When imaging long bones:

- A Whichever joint is comfortable for the patient is included on the image.
- B Both joints are included on the image.
- C The joint nearest to the injury is included on the image.

29. In case of ankle x-ray imaging

- A The legs are extended, and the plantar aspect of the foot is vertical and slightly rotated laterally.
- B The legs are extended, and the plantar aspect of the foot is vertical and perpendicular to the cassette, and the limb is rotated medially 30 degrees.
- C The legs are extended, and the plantar aspect of the foot is vertical and perpendicular to the cassette, and the limb is rotated medially 45 degrees.

30. Where do you center in case of a lateral ankle x-ray?

- A To the lateral malleolus
- B To the calcaneus
- C To the medial malleolus

31. What kind of images are taken from the calcaneus?

- A AP, lateral, and 4-way Broden
- B Lateral and axial
- C Lateral, axial and 4-way Broden

*Correlation analysis***32. In case of knee x-ray imaging, we center to the patella, because the patella's shape is like a chetsnut and it is located inferior to the joint space.**

7. X-ray anatomy and imaging technique of the spine and the sacroiliac joint

Simple choice

33. Which are the curvatures of the spine?

- A Cervical and lumbar lordosis, thoracic and sacral kyphosis
- B Thoracic and sacral kyphosis, cervical and sacral lordosis
- C Cervical and thoracic kyphosis, lumbar lordosis, sacral kyphosis
- D Lumbar and thoracic lordosis, cervical and sacral kyphosis

34. Which statement is true?

- A If you take an AP Ottonello cervical spine x-ray, the mandible is blurred and the C I-VII. vertebrae are clearly seen.
- B If you take an AP Ottonello cervical spine x-ray, then the image will be blurred due to the motion of the mandible.
- C AP Ottonello cervical spine X-ray is taken for the visualization of the first and second cervical vertebrae.

35. In case of an AP transthoracic x-ray where is the central ray directed?

- A To the middle of the sternum
- B To the jugulum
- C To the xyphoid process

36. In which position may the patient be during a spine x-ray?

- A Only in a lying position
- B Only in a standing position
- C In a lying or a standing position

37. In case of an AP lumbar x-ray

- A The knees are flexed, because this is comfortable for the patient.
- B The knees are flexed in order to reduce the lumbar lordosis and to bring the vertebral column as close to the cassette as possible.
- C The limbs are extended, they are not allowed to be flexed.

Correlation analysis

38. Spine x-rays are usually made in a lying position, because this position is the most comfortable for the patient.

39. We image the different parts of the spine separately, because the spine has different physiological curvatures.

8. X-ray anatomy and imaging technique of the bony chest and the respiratory system

Simple choice

40. Which statement is true?

- A When taking an x-ray image of the ribs the patient lies supine on the table
- B When taking an x-ray image of the ribs the patient lies prone on the table
- C Patient positioning depends on the injured ribs

41. Which statement is false?

- A We take x-rays of the lower and upper ribs separately
- B On chest x-rays the ribs are also well visualized
- C In case of a slim patient, the lower and upper ribs are imaged at the same time

Multiple choice

42. Which statements are true for a chest x-ray?

- A You should always use the hard beam technique.
- B Only take it in a standing position in PA direction.
- C Patient positioning and beam direction are determined by the patient's condition.

43. Which parameters are chosen for on-site x-ray images?

- A F-F: 150 cm, KV: 90 mAs: high
- B F-F: 60 cm, KV 125, mAs: low
- C F-F: 150cm, KV 120 mAs: low

44. How do you take a chest x-ray of a sick patient who has pleural fluid on the left?

- A The patient lies in a left lateral decubitus position and you take the image in either AP or PA direction with a horizontal x-ray beam.
- B The patient lies supine.
- C The patient lies in a left lateral decubitus position and you take the x-ray in a lateral direction.

45. In case of a two-way chest x-ray, what determines which side is nearest to the cassette?

- A The side where the lesion is.
- B We always take the lateral image with the left side nearest to the cassette.
- C It does not matter, whichever is the most comfortable for the patient.

46. How do you take a two-way chest x-ray if there is PTX on the left?

- A F-F 150 cm, in standing AP position and in expiration; on lateral images the left side is nearest to the cassette
- B F-F 150 cm, in standing PA position and in expiration; on lateral images the left side is nearest to the cassette
- C F-F 100 cm, in standing PA position and in breath hold; on lateral images the right side is nearest to the cassette

47. Which statement is false for an on-site chest x-ray?

- A The image is taken in a position most suitable for the patient's condition
- B If a F-F of 150 cm is not possible, try to choose the largest F-F distance as possible
- C The image is always taken in a lying position.

*Correlation analysis***48. When imaging the ribs you should always ask the patient where she has pain (anterior or posterior), because this will determine the direction of imaging (AP or PA).****49. If a PTX is suspected, the chest x-ray is always taken in expiration, because PTX is a result of rib fracture.****50. In case of a chest x-ray, the applied F-F is 150 cm, because the chest x-ray is carried out with the hard beam technique.****9. X-ray anatomy and imaging technique of the skull***Simple choice***51. The plane separating the skull and the facial bones is:**

- A the line connecting the upper edge of the orbit and the external ear
- B the line extending from the outer canthus of the eye to the external ear
- C the line connecting the lower edge of the orbit and the external ear

52. The most applied planes in skull imaging are:

- A Median-sagittal, infraorbito-meatal, and auricular planes
- B Median-sagittal, infraorbito-meatal, orbito-meatal, and auricular planes
- C Sagittal, infraorbito-meatal, orbito-meatal, and auricular planes

53. How do you take a skull x-ray of a traumatic, unconscious patient?

- A The patient lies prone, and rotates his head into a lateral position
- B The patient lies supine and you take the image using a horizontal x-ray beam and a Lysholm grid
- C The patient lies in a lateral decubitus position, rotates his head to the side, and you brace the patient in this position.

10. X-ray anatomy and imaging technique of the facial bones*Simple choice***54. How do you take an x-ray image of the sinuses?**

- A In sitting or in standing position
- B In standing or in lying position
- C In lying position

55. Which name refers to an otological x-ray imaging technique?

- A Waters
- B Dittmar
- C Schüller

56. How do you take an x-ray image of the facial bones?

- A The patient lies prone on the table and the patient's nose and chin are placed in contact with the cassette; the median sagittal plane is perpendicular to the cassette
- B The patient lies prone on the table and the patient's brow and nose are placed in contact with the cassette; the median sagittal plane is perpendicular to the cassette
- C The patient lies supine on the table and the patient's chin is raised up; the median sagittal plane is perpendicular to the cassette

*Correlation analysis***57. X-ray images of the sinuses are taken in a standing or in a sitting position, because fluid in the sinuses are visualized in the form of a horizontal line.****11. X-ray contrast agents***Simple choice***58. Which is not true for the storage of contrast agents?**

- A They should be stored in a closed place
- B They should be stored in the fridge
- C They should be stored in a dark place
- D They should be stored away from x-rays

*Multiple choice***59. Side effects caused by iodinated contrast agents:**

- A Nausea
- B Urge to urinate
- C Warmth
- D Cyanosis
- E Dry mouth

*Correlation analysis***60. Barium containing contrast agents are well suited for imaging the GI system, that is why we choose this type of contrast agent for imaging the esophagus in the post-operative state.****61. Iodinated contrast agents must not be given to patients with hypothyreosis, that is why, in this case, the patient is given a barium containing contrast agent.****62. Before administering an intravenous contrast agent, it is important to check the patient's renal function, because every type of contrast agent is secreted by the kidneys.****63. Complications of contrast agent administration depends on the volume of contrast media, that is why, if it is possible, you should not repeat intravenous contrast agent administration within 5-7 days.****64. We have to inform the patient about possible complications of contrast agent administration, that is why the non-cooperating patient is not allowed to get a contrast agent.****12. Abdominal X-ray: anatomy and imaging technique; acute abdominal disorders***Simple choice***65. When do we have to lay down the patient for a plain abdominal x-ray?**

- A If the patient is fat.
- B If it is more comfortable for us that way.
- C If it is required by the patient's condition.
- D If the patient asks to be positioned that way.

*Multiple choice***66. Plain abdominal x-ray imaging is indicated:**

- A In case of ventricular perforation
- B In case of small bowel ileus
- C In case of melena
- D If a child swallowed a coin

Correlation analysis

67. When taking a plain abdominal x-ray, always take a chest x-ray as well, because some chest diseases may simulate acute abdominal disorders.

68. The plain abdominal x-ray image is always taken in a standing position, because in this position free abdominal air is collected under the diaphragm.

13. X-ray anatomy and imaging technique of the urinary system*Simple choice***69. Which statement is not true for urography?**

- A We can get information of the function of the kidneys
- B It goes hand in hand with contrast agent administration
- C In case of a urinary secretory blockage this is the primary imaging method
- D The patient should empty his bladder before the examination.

*Multiple choice***70. Taking a plain kidney x-ray is indicated:**

- A if glomerulonephritis is suspected
- B if a renal stone is suspected
- C if a urethral stone is suspected
- D if bladder cancer is suspected

Correlation analysis

71. We can see every urinary tract stone on a plain kidney x-ray, because all stones contain calcium.

72. In pregnancy we do not take a plain kidney x-ray, because in pregnancy, the pain on the back is caused by urethral compression due to the growing uterus.

14-15. X-ray anatomy and imaging technique of the gastrointestinal tract I-II.*Simple choice***73. Patient preparation steps for colonography, except:**

- A The patient should not have dinner the night before the examination
- B On the day of the examination the patient should drink lots of liquids
- C The day before the examination the patient should drink a laxative solution
- D The patient should not smoke on the day of the examination

*Multiple choice***74. Parts of the colon:**

- A right colic-flexure (flexura hepatica)
- B colitis ulcerosa
- C transverse colon
- D ampulla recti
- E descending colon
- F cecum
- G fundus
- H left colic-flexure (flexura lienalis)

75. What kind of preparations are necessary for a selective enteroclysis?

- A Barium containing contrast material
- B Water-soluble contrast material
- C Transoral tube
- D Distilled water
- E Lidocaine spray
- F Methylcellulose
- G Enema tube
- H Calcimusc

Correlation analysis

76. The primary imaging method of the oesophagus is the video fluoroscopic swallowing exam, because endoscopy is uncomfortable for patients.

77. In case of gastric perforation we do the x-ray exam with a barium containing contrast material, because performing endoscopy is dangerous.

16. X-ray anatomy, imaging technique and interventional procedures of the breast

Simple choice

78. Which are the two basic x-ray images of screening mammography?

- A. cranio-caudal and medio-lateral
- B. postero-anterior and medio-lateral
- C. caudo-cranial and cranio-caudal

79. What does specimen mammography mean?

- A: This is an additional x-ray image
- B: This is an x-ray image in the lateral direction
- C: This is an x-ray image from a surgically removed lesion

Multiple choice

80. Which statements are true for screening mammography?

- A It is for women between the ages of 45 and 65
- B It is done every year
- C Its main goal is to uncover lesions as soon as possible

Correlation analysis

81. Proper compression is required for good image quality, because the two x-ray images have to be symmetrical and without skin crease.

Simple choice

82. Which statement is false?

- A **Arthrography** is a procedure when a contrast medium is injected into the joint area by percutan puncture.
- B **Sialography** is a procedure when a contrast medium is injected into the mammary ducts.
- C **Dacryocystography** is a procedure when a contrast medium is injected into the lacrimal sacs.
- D **ERCP** – Endoscopic retrograde cholangiopancreatography is a procedure when a contrast medium is injected into the biliary and/or pancreatic ducts.
- E **HSG** – Hysterosalpingography is a procedure when a contrast medium is injected into the uterine cavity and fallopian tubes by a catheter.

Solutions

- | | | |
|----------------|----------|----------------------|
| 1. B | 29. B | 57. A |
| 2. A, B | 30. C | 58. B |
| 3. C | 31. | 59. A, B, C, E |
| 4. B | 32. D | 60. C |
| 5. A | 33. A | 61. E |
| 6. A, D | 34. A | 62. C |
| 7. A | 35. A | 63. D |
| 8. D | 36. C | 64. C |
| 9. A, C, E, F | 37. B | 65. C |
| 10. A, B, E, F | 38. C | 66. A, B, D |
| 11. C, D | 39. B | 67. A |
| 12. A, C, D | 40. C | 68. D |
| 13. E | 41. B | 69. C |
| 14. A | 42. A, C | 70. B, C |
| 15. B | 43. C | 71. E |
| 16. B | 44. A | 72. C |
| 17. B | 45. A | 73. B |
| 18. A, D | 46. B | 74. A, C, D, E, F, H |
| 19. C | 47. B | 75. A, C, E, F |
| 20. B | 48. A | 76. D |
| 21. B | 49. B | 77. E |
| 22. A | 50. B | 78. A |
| 23. B, D | 51. B | 79. C |
| 24. B | 52. B | 80. A, C |
| 25. B | 53. B | 81. B |
| 26. A | 54. A | 82. B |
| 27. A | 55. C | |
| 28. C | 56. A | |