RECONSTRUCTION OF THE NASAL SEPTUM WITH COMPOUND GRAFT

PhD THESIS

MIRIAM BOENISCH MD

UNIVERSITY OF PÉCS; FACULTY OF MEDICINE

PÉCS

2007

Contents

Publications and Presentations

1. From Sushruta to Joseph, a historical review of the nasal surgery

This chapter is an abstract of the historical development of nasal surgery: from the first written source Sushruta's Ayurveda, to Joseph, the father of modern nasal surgery. Our retrospective view covers some three thousand years, and it shows that there have been three major reasons for the development of nasal surgery.

The first reason was the attempt to reconstruct total or partial nasal defects due to loss of, either the entire or parts of the nose as punishment or after fights, which we regard as the beginning of nasal surgery. This spans three time segments and different regions: ancient and medieval times in far East, the renaissance in Italy and the new age in west Europe.
The second was the establishment of the functional surgery correcting deformities of the inner parts of the nose, especially the nasal septum. The third period started at the end of the 19th century as the aesthetical rhinoplasty was born.

1.1. The beginning of nasal surgery

1.1.1. Ancient techniques in Far East and in Italy of the Renaissance

During the long lasting period from ancient times to the end of the 19th century, rhinoplasty only meant reconstruction of total or partial defects of the nasal pyramid. The loss of the outer nose represents a terrible mutilation causing the exclusion from the society. Therefore people tried to reconstruct the nose already in ancient times.

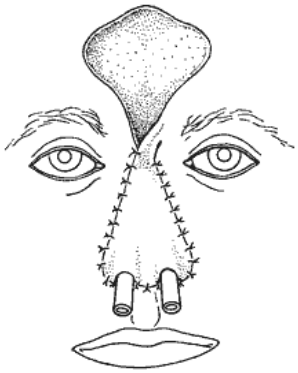

Fig. 1: The "Indian Method"

The first records dated about 1000 BC can be found in the Indian work "Sushrutas Ayurveda", about a technique to reconstruct noses which have been cut of for punishment, with skin from the forehead (Fig 1). This technique however, was unknown to Western medicine until 1400 AD.

We can be certain that it is no coincidence that this method was adopted in Europe during renaissance times in Italy. Italy's then prosperous cities where the classical starting points for most trade relations with Far East, including, of course, India.

The first European surgeon who restored a lost nose, was Branca de`Branca in Sicily about 1450 AC, what is reported from Peter Razano who was bishop in Luzera and told about this surgical technique in the 8th book of his "world history", which is preserved in Palermo. Branca took the flap from the cheek, but his son Antonio Branca took the reparative flap from the upper arm. Therefore he can be called the inventor of the so called "Italian method". He personally did not report about his technique, but we know that he practised it from a poet of this times, Elysius Calentius who wrote about it. This technique was carried on in Italy by the pupils of Branca, Balthasar Pavonvo and the Bojani family who lived in Tropäa in southern Italy until 1571.

But not only in Italy the "Italian method" has been used, it has been brought also to Germany by Heinrich von Pfalzpaint , who 1460 described precisely in his book "Wündarznei" the technique of a nasal reconstruction with a flap from the upper arm which he learned from "an Italian" :
After creation of a model with pergament paper the amount of skin is marked on the upper arm, exactly on this area where the biceps muscle touches the nose if the patient wraps his arm around his head. Next the skin is incised leaving a distal bridge, mobilised with subcutaneous tissue and on its proximal end sutured to the remnant of the nose, and the arm is fixed with pillows and bandages to the head for the next eight to ten days. After that during the second step the bridge to the upper arm is cut and formed to a new columella. The postoperative packing from the outside should help to give the new nose a better form and for internal splinting hemp with a pinfeather for breathing was used.

A very important step of the surgical reconstruction was made by Gaspare Tagliacozzi, who was born 1546 in Bologna and became Professor of the Anatomical Institute in Bologna (Fig 2). He reconstructed not only the outer parts of the nose but also the septum in 6 steps.

Fig.2. A monument of Tagliacozzi can be found in the library of the Universita antiqua in Bologna, where he is shown with a nose in his hand

Tagliacozzi made to parallel incisions on the skin of the upper arm, elevated the skin in between and left a piece of tissue under the flap. After 14 days he severed the flap on the central side from the arm. After another 14 days the he fixed the flap on the remnant of the nose with a difficult bandage for 6 days (Fig 3). On the 20th day the flap was severed from the arm and after another 14 days the flap was cut to form the nostrils and fixed on the upper lip.

Fig.3. The main steps of the surgical technique of Tagliacozzi:

His book "Chirurgia curtorum" published in Venice (Tagliacozzi 1597), was the state of the art at the 16th , and beginning of the 17th century in Europe. Unfortunately these techniques have been more and more forgotten during the next 150 years. Plastic reconstructive surgery was considered undesirably and mysteriously.

1.1.2. Reconstructive nasal surgery at the New Age

At the end of the 18th century a new impulse could revitalize nasal reconstructive surgery in Europe again:

1793, in the Gazette de Madras (described by Hircarrha 1793), an English speaking Journal reported about an indian surgeon, who reconstructed the noses of 5 English men, whose noses had been cut of in imprisonment, with forehead flaps. And second a report of a successful nasal reconstruction in India using a free flap from the backside has been published in the next edition. The newspapers reached England in the same year.

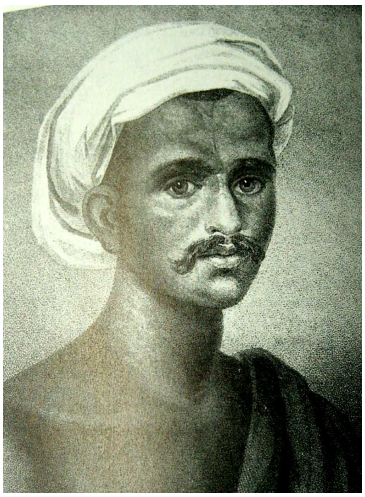

Fig.4. Facsimile of the drawing in the newspaper

1814 Carpue an English surgeon practised this techniques two times successfully. He published his work in 1816 in London.

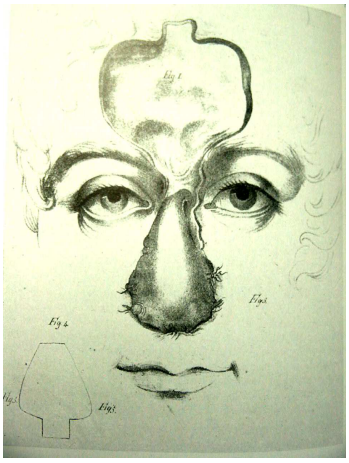

Fig.5. This picture shows the first in Europe

published drawing of the "Indian Method"

These techniques have been picked up by surgeons like Lukas in London, and Bünger, Graefe and Jüngken in Germany with varying success. In 1816 Graefe reconstructed the nose of a soldier with a flap from the upper arm like Tagliacozzi. Later he modified this technique in forming a nose already on the upper arm. He described his modification in Berlin 1818, calling it the "German Method".

In the following years these techniques have been practised also in France by Dupuytren, Lisfranc and Martinet and in Russia by Höfft and Dybeck.

Especially Dieffenbach in Berlin did innovative and pioneering work in this field in the beginning of the 19th century. He published his modifications in 1834 and 1845.
As well in ancient times as in the New Age, there where no attempts to reconstruct the nasal framework, or to reconstruct the nasal function.

The first successful implantation of bone to restore the nasal framework was carried out by Ollier (1861). The plastic reconstructive surgery in 1860s on the Charite in Berlin was carried on by Langenbeck (1859), who was the first in realizing that the new formed nose needed a stabile framework underneath. He tried to gain bony framework with periostium from the forehead in the hope for outgrowth of new bone from the periostium. König 1886 carried this idea forward in removing a piece of bone together with the forehead flap.

There also have been already experiments with other autogenous implants for nasal reconstruction in the 19th century with free bone transplants from fingers. Hardie described 1875 the partial reconstruction of the nose of a little child with a part of the index finger.
At the end of the 19th and the beginning of the 20th century a big number of reconstructive techniques had been developed. Nélaton 1902 was the first surgeon using rib cartilage for nasal reconstruction.

1.2. Septal Surgery – Beginning of functional nasal surgery

Although already in middle ages there have been trials to restore nasal function e.g. with burning nasal polyps with red hot iron, the real first step in functional nasal surgery was only possible after two important inventions.

First in 1848 when Türck in Vienna and Csermak in Prag developed the technique of indirect laryngoscopy with mirrors and artificial light (Csermak 1858). This was the first very important requirement also for septal surgery, enabling the surgeon to see even the posterior parts of the nasal cavitiy and the septum. Semeleder a pupil of Csermak published a monography about the Rhinoscopia in 1862.

Second was the knowledge of Cocaine for local anaesthesia which first was discovered by Freud in Vienna in 1884.

Now, with the possibility to see the entire septum and to discover its deviations, and with the local anaesthesia, longer and more complex surgical procedures where possible and accelerated the further development of septal surgery. Hajek and Zuckerkandl (1882) in Vienna where important for better anatomical and physiological understanding of the septum and the paranasal sinuses.

First reports from north America came from Ingals from Chicago 1882, who already described submucous resection of crests and spurs under chloroform. He also published a classification of septal deviations in 4 groups. Gleason and Watson from Philadelphia in 1896 published similar techniques for removing septal spurs and crests together with the mucosal lining with a saw under local anaesthesia with cocaine. They already emphasized to take good care not to injure the mucous membrane in the unobstructed naris. If the rest of the septum was still deflected it was thrust into the midline and retained there by means of a metal or cork tube or jodoform gaze. A big controversy between the two of them was the claim for originality of this technique, carried out in multiple statements in “The Laryngoscope”.

With the beginning of the new century, the systematic submucous resection of the nasal septum started with two now very well known surgeons, Otto Tiger Freer (1857-1932) from Chicago and Gustav Killian (1857-1932) from Freiburg. This technique of submucous resection of the septal cartilage (Freer 1902, Killian 1904) represented the state of the art for surgical correction of septal deformities for almost the next 50 years.

Fig 6: Gustav Killlian in 1887

It was only in 1950 when Maurice Cottle from Chicago modified the nasal septum operations for the benfit of the septal cartilage. In a presentation before the Colorado Otolaryngological Society in 1950 he emphasized the importance of new techniques. He realised that with the resection techniques in some patients cosmetic sequelae like saddling occurred, either already during surgery, either months later. He pointed out that it is necessary that surgery of the septum should include all parts of the septum. The surgeon should reconstruct and restore the septum, associating it with surgery of any other part of the nose rather than think of resection.

1.3. The birth of aesthetic rhinoplasty

With the overall risk of surgery decrease through anaesthesia and the development of sterile technique by Semmelweiss, Lister and others, the concept of performing surgery for reasons other than the reconstruction of damaged or altered anatomy was at least permitted to exist. More and more the idea that aesthetic ends alone are enough to warrant surgical intervention became accepted.

John Orlando Roe from Michigan was the first to publish in 1887 a paper about correction of a nasal deformity in a young woman. He emphasized special concern about external skin incisions and in 1891 he published an article about subcutaneous correction of an angular deformity of the nose. For anaesthesia Cocain was used topically and a weak solution injected. Therefore he may be called the originator of the intranasal approach for rhinoplasty.

Joseph, in 1898 described hump removal intranasally through intercartilaginous incisions. Jacques Joseph (1865 –1934), the German orthopaedic-trained surgeon, especially gained big experience in the first world war, where he had to operate on many patients with severe facial traumas. A lot of examples are shown in his wonderful book.



Fig 7: Prof. Joseph 1924

Joseph shows in his book already good photographic documentation of cosmetic nasal surgery prae, intra- and postoperative. He also concentrated on crooked noses, in surgical techniques in postoperative redressing therapies.

Fig. 8: photo documentation about a case of rhinoplasty from the book of Prof. Joseph

In a very comprehensive book about operational techniques, he also describes all the contexts of plastic surgery extensively. A rare feature is a photo of two patients dancing after



surgery, enabling Joseph to illustrate the “cheery mood” of his patients.

Fig 9: dancing patients from the book of Prof. Joseph

His analysis, classification and repair techniques for various types of nasal deformities turn him into the father of modern rhinoplasty.

The endonasal approaches by Roe and Joseph are still used in a majority of cases; but in some difficult deformities they do not give enough review of the nasal framework.

The so-called open approach was established only several decades later, probably due to fear of scars. The use of a columellar incision in nasal surgery began with Aurel Rethi, a Hungarian surgeon who became famous for larynx surgery. In 1934 he described this incision for reduce of an overprojecting tip. However he was unaware of the potential of this incision as a gateway to exposing the underlying nose.

This was left do Sercer from Yugoslavia. He realized that this incision could be used to raise a skin flap and visualize the nasal tip and entire nasal dorsum. He used the term “Decortication” (Sercer 1967).

The next advance was to expose the septum through the same incision. This was developed by Padovan, a pupil and successor of Sercer. He found the technique superior to the endonasal approach for complex and difficult procedures like post traumatic deformities and marked septal deviations. He introduced this approach to North America in 1970, by

delivering a lecture entitled: “ External approach to Rhinoplasty” at the first International Symposium on Plastic and Reconstructive Surgery of the Face and Neck in New York City. Goldmann, a Toronto otolaryngologist was attendance of this meeting and already a few years later published his own experience (Goldmann 1973).

2. Nasal septum – Key structure of the nose

The septum can be rightfully seen as key structure of the nose. It is of crucial relevance for normal development, appearance and function of the nose.

Since it is part of the cartilaginous nose capsule it is responsible for a normal growth of the nose and the upper maxilla, respectively from nurseling to adult age. For a normal postnatal development of nose and visceral cranium the growth plates within the septum are requisite (Krmpotic-Nemanic 1977, Poublon 1987, Lang 1987, Van Loosen 1997). If one of these growth plates is damaged by a trauma, it leads to an aberration of the outer nose or even a deficient formation of the upper maxilla, depending how much time has passed since the trauma has happened.

Linked to this phenomenon is one of those problems of nose surgery which remain unsolved: surgical correction of a pre-pubertal distortion of the septum. Unfortunately, it remains to be seen how the growing cartilage reacts upon a surgical intervention, in some cases this might cause iatrogenic disturbance of the development.

From a functional, as well as an aesthetic point of view, the septum is often segmented in two parts, see Tardy 1997. The parting line lies here between the dorsal cartilaginous and osseous anastomosis along the nasal bridge (rhinion) and the spina nasalis (Fig 10).

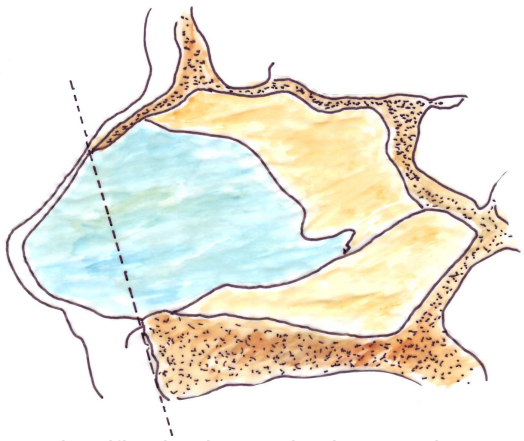

Fig 10: Classification by Tardy; the septal parts caudal of the line have great influence on the nasal dorsum and tip

The frontal parts co-determine the form of the nasal dorsum and the location of the tip of the nose crucially. Deformations of the septum largely lead to the development of a saddle-nose, hump or a cartilaginous crooked nose. The segments lying behind this line have practically no effect on the aesthetic aspect of the nose.

In addition, the septum creates a partitioning wall between the nasal cavities, as well as the median wall of each cavity. It is composed of the Columella, the membranous, cartilaginous and osseous septum.

2.1. Surgical anatomy

The columella is the caudal limitation of the septum and reaches from upper lip to lobulus, the actual tip of the nose. It is covered with skin, which on its medial side contains sebaceous glands and after puberty also hair follicle.

Right underneath the skin lay the medial crura of the alar cartilage which vary greatly in form and are determinant for the columella. Loose connective tissue, which makes the cartilages relocatable lies between the medial crura. Contingent on the mass of connective tissue the crura can be closer or further apart, separated by connective tissue; the columella can hence be more plump or narrow.

Right underneath the skin we find the medial crura of the alar cartilages, petering out caudally with the footplates, which constitute the broadening of the cartilages cambered towards the outside.

They are responsible for the broadening of the columella right at the junction of nose and upper lip and due to the stiff anastomosis of connective tissue to the caudal septal border it marks an important support mechanism to the tip of the nose.

Form and location of the columella are decisive for the nose's appearance. Any changes in form are immediately visible from the outside. Among the most common and bothersome deformities are: excessive size and width brought about by hypertrophic alar cartilage, eventual curvatures due to asymmetric alar cartilage or retractions caused by loss of cartilage or scars.

Subsequent to the columella follows a narrow strip: the membranous septum - only 1-2 mm wide, consisting of connective tissue without cartilaginous structure, and also covered by skin.

The membranous septum allows for relative movement between the flexible columella, the tip of the nose and the fixed, stiff septum. Adjacent to it is the cartilaginous and bony septum.

The cartilaginous septum is composed by the quadrangular cartilage, a stable, cartilaginous plate, which varies in size and appearance; its form soonest resembles a trapeze (Masing 1964). From a cosmetic viewpoint form and course of the caudal and dorsal edge of the trapezoids are crucial.

The caudal border connects with the membranous septum and shows a convex bend. This is where the cartilage forms three important angles: the anterior, the medial and the posterior septal angle.

Deformations of the caudal border can develop as a consequence of hypertrophic growth and have an influence on projection and rotation of the tip of the nose.

Abnormal bending or subluxation of the caudal border leads to an asymmetric tip of the nose or an asymmetric columella.

If parts of the caudal border are missing a hanging tip of the nose or a retraction of the columella will be the consequence.

The dorsal edge of the septum cartilage is solidly adhered to the triangular cartilage. A cross section of this catenation shows a T-shaped structure.

Deformations of the dorsal cartilaginous border result in an asymmetric or bent nasal dorsum in the medium third. Hypertrophic growth of the dorsal edge leads to humps. A concave upper edge of the septum caused by loss of septum cartilage or loss of the cartilage's stiffness automatically brings forth a saddle nose.

The lower rim of the cartilaginous disc begins at the spina nasalis and runs parallel to the nasal floor toward the choane, where it is solidly connected to the crista maxillaris (maxillary crest) of the upper jaw. From the anterior vomer angle it rises to the front edge of the Lamina perpendicularis, passing through a grove of the vomer.

In some cases a so-called sphenoidal cartilage spur can reach far between vomer and lamina perpendicularis toward choane. The posterior edge of the cartilage is solidly attached to the ethmoidal bone's lamina perpendicularis and goes as far as the rhinion.
Subsequent to the cartilaginous septum follows the bony septum, created by vomer and the ethmoidal bone's Lamina perpendicularis.

The posterior rim of the vomer forms the posterior edge of the septum; it is the border of the Choanes.

The skin cover of Columella and membranous septum turns into mucosa -a few millimetres behind the caudal border of the septum cartilage. From here on the cartilaginous structures of the nose are covered with Mucoperichondrium, and the nose's osseous structures with Mucoperiosteum.

It is crucial for surgical interventions that the Mucoperichondrium can be easily separated from the septum cartilage. However, on the border between cartilage and Crista maxillaris, as well as between vomer and the bone it consists of a stable soft tissue connection; when dissecting the septum structure this connective tissue has to be sharply divided.

2.2. The nasal cycle

Kayser (1895) found alternating changes in patency in both nasal cavities, which he called the nasal cycle. He ascribed these to a continuously changing blood volume in the nasal mucosa, which he felt was due to a continuous shifting in tonus between the two body-halfes. He stated that the nasal cycle did not influence the total nasal patency.

Lillie (1923) described how patients often complain of obstruction on alternate sides, but that this is normal, and that there appears to be a cycle of reaction: while the mucous membrane of one nostril is filling to a point approaching obstruction, the other nostril is opening and throwing off its secretion. Heetderks (1927) in a rhinoscopic investigation on the influence of various climatic conditions on the nasal mucous membranes found a definite cycle of relation in 80% of his test persons. In general, damp, cold atmosphere brought about the greatest swelling of the turbinates, and dry warm air a little less, while optimal atmospheric conditions (humidity 50-60%, temperature 13°-18°) caused cycl es of least degree.

The cycle is most active during adolescence which is explained by the hormonal activity at this age. In older persons a rather superficial cycle was observed. The same nose responded differently at various times under apparently the same conditions. These cycles, including both the phase of filling as well as the phase of emptying on the same side, occurred over periods from fifty minutes to four hours. In general more time was required under favourable conditions, when the cycle was of less degree. Heetderks explains these reactions of the turbinates by the great amount of airconditioning the nose has to perform and also as a reflex mechanism in preventing too free an admission of the air. The average time under all atmospheric conditions for a complete cycle was two and a half hours.

He also examined the effect of sleeping postures, and found that the lower nasal side filled to its maximum size of swelling in an average of twenty five minutes. By turning the patients over, the other side could be made to swell. He concluded that the distribution of the nasal vascular contents must be largely controlled by gravitation.

Stoksted (1952) also found a regular cycle in 80% of his normal test persons. He was the first to study the cycle rhinomanometrically. He was also able to calculate the total nasal resistance and to show experimentally that this figure remained practically constant, notwithstanding the bilaterally changing conchal volumes. This was an important addition to rhinologic examination, the total nasal passage being ultimately the most important. He showed and stressed the importance of the total resistance along with the cyclical curves in pathological cases (Stocksted 1953, Stoksted and Nielsen 1957).

As to the nervous regulation of the cycle Stocksted assumes that the rhythmic cycle is maintained through the peripheral vegetative centres, sphenopalatine and stellate ganglion, with eventual connections through which an increase in tonus in one set of centres may give a decrease in tonus in the other two. The two peripheral centres must be regulated by a central sympathetic centre possibly situated in the hypothalamus. By increasing or decreasing the tonus this centre will give increased or decreased nasal passage, so that it becomes possible to regulate the total nasal volume according to the requirement of the organism for intake of oxygen or discharge of carbon dioxyde. This is probably a reflex arising in the respiratory centres which, by acting on the central centre in the hypothalamus, elicits vasomotor changes in the nasal mucosa.

Ogura (1958) investigated the nasal cycle in pathological noses. When one nasal cavity is anatomically wide and the other one narrow the contribution of the narrow side to the total nasal respiration is small, so that the respiration through the wide side runs parallel to the total nasal respiration. Due to the cyclical changes of the turbinates of the wide nasal cavity the total nasal passage shows the same cyclical fluctuations, and during the swollen phase the patient may complain about obstruction of his wide side, which might seem improbable to the ill informed examiner who sees the patient during the shrunken phase.

Flottes (1961) studied the nasal cycle in 25 persons aged 20-30 years having normal noses. 80% of the testpersons had a cycle duration between 2 and 5 hours, with an average of three and a half hours, 20% had a cycle duration of up to 8 hours. The duration of the cycle seemed to be constant in the same person at repeated examinations. The total patency was not determinated; no subjective sensations of nasal obstruction had been experienced by the

testpersons. The amplitude of the cycles in normal noses was identical on both sides and the cycle evolved in a regular and harmonious way. In persons having an important septum deviation the cycle was irregular; the amplitudes differed on both sides while the maximal amplitudes exceeded those of cycles in normal nose.

Emotional influences were studied by Holmes (1950) who found vasoconstriction, a sympathetic reaction, in sudden fright situations, and vasodilatation, a parasympathetic reaction, in anxiety situations.

Drettner 1963 beautifully demonstrated the vasoconstriction in the nasal mucosa of a patient upon the entrance of the surgeon in the operating room.

Flottes a 1961 studied the action of nasal vasoconstrictor drops. He found, that the cycle stopped after the application, to resume its activity when the drugs activity was over. So he found a precise means to test the duration of activity of the several nasal vasoconstrictor agents. He also stated that the so called rebound-effect of nasal drops, a period of nasal stuffiness after the vasoconstriction phase, is nothing but the resumption of cyclical activity.

3. Septal deformity

Clinical studies and everyday observations show that some 80% of the overall population have a more or less deviated septum; however, only in a small group this septum deviation leads to discomfort.

As early as 1882, Zuckerkandl realised in his anatomical studies that in a skull - which is often asymmetrical - the septum is not straight but found approximately in the middle between the lateral walls. He then introduced the term “physiological septal deviation”.

Today we define physiological septal deviation as a deviation of the septum without subjective and objective obstruction to nasal breathing. This physiological deviation fulfils the requirement mentioned previously in connection with the nasal cycle.

The most frequent cause for a septum deviation predominantly among Caucasians is contingent to the history of human development. According to Sercer (1965) the three magisterial elements of the septum, septal cartilage, Os vomer and perpendicular plate

consist of tissues of differing thickness. In the centre of each part the tissue is thin, these being the so-called neutral fields which are separated by two ligamentous components, the so-called trajectors. One trajector stretches from the sphenoidal bone's rostrum to the Crista incisiva, the second is perpendicular to the first and stretches from the nasal spine via frontal bone along the rim of the perpendicular plate to the vomer.

There is no parallel growth of trajectors and neutral fields. Especially in a phase of quick growth of the Viscerocraniums (in puberty) the trajectors develop more swiftly than the neutral fields, which results in square-cut, pointed deformities, the development of a ledge or spur. In contrast, the rounded, cartilaginous deviations are ascribed to an imbalance of inner and outer tensile stress of the cartilage (Fry 1967). Sure enough also traumatic lesions of the nose structure can either lead to immediate deviations, or due to scarring or irregular development, to secondary nasal deviations.

From a surgical viewpoint it makes sense to classify septum deviations according to their location; depending on the location of the deformation it requires diverse surgical techniques to correct.

By virtue of my experience I rated a 4-area classification (Fig 11) of the septum as highly beneficial:

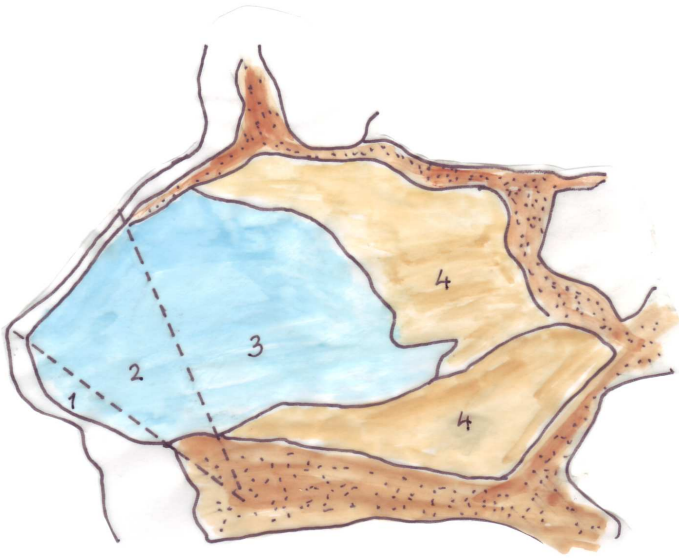

Fig 11: My own 4-area classification of the septum

Area 1 comprises the septum cartilage's caudal area, e.g. the "protuberant" part, caudal to the line between anterior septal angle and nasal spine. A typical deformation in area 1 is the subluxation. A subluxation distorts the Columella and thus does not only cause a clearly visible cosmetic change, but constricts the nasal entrance and disturbs the streaming conditions. Hypertrophy in area 1 leads to a hanging Columella. A loss of cartilage in this region, on the other hand entails Columella retraction and a slugging of the tip of the nose.

Area 2 covers a quadrangle immediately behind area 1 and reaches until the line delimited by rhinion and anterior vomer angle. From a functional point of view area 2 is the septum's most important section. In its projection lies the inner nasal valve, the narrowest area in the inner nose. Cole's (1988) and Chaban's measurements (1988) - who investigated the effect of stimulated septal deviations in different areas on the airflow resistance - show that even small deformities in this region encompass significant dysfunctions. Over and above, this area can be regarded as pivotal from a cosmetic point of view, since it constitutes the cartilaginous nasal dorsum. A deflection of the dorsal part of the quadrangular cartilage off the midline results in a deflection of the lower two thirds of the external nose in the same direction. A cartilaginous bereavement in the dorsal division of area 2 leads to the formation of a saddle nose, because of a defective backing of the cartilaginous bridge. Hypertrophy of the dorsal part of the quadrangular cartilage leads to hump deformity.

The cartilaginous septum's third posterior triangle is area 3, whereas area 4 comprises the osseous septum. The latter two are exposed neither functionally nor aesthetically. Deviations in area 3 or 4 do not lead to significant change in airflow resistance, even if they reach 5mm in height.

The indication for septoplasty or nasal surgery is not a deviated septum, but a septum that causes increased airway resistance and/or cosmetical problems. For nasal cavities of unequal width- as observed in septal deviations- the nasal cycle is severely disturbed (Masing1968).

Hence, the goal of surgical intervention would be not to create a straight septum, but to locate the septum in the middle of the lateral nasal wall in order to create two functionally equal nasal cavities. However, this often interferes with the aesthetic principles. The goal therefore should not be to shape a nasal septum in the centre of a crooked nose creating two similar cavities, but to straighten the outer nose as well.

4. Problems of a surgical solution: The “difficult septum”

In traditional sub-mucous septum resections the most bothering deformed sections of the cartilaginous and osseous septum framework were removed. Older colleagues who have practised this surgical method report that experienced surgeons could complete this intervention within 5 – 10 minutes. The surgery was performed on a seated patient (without preliminary medication) with a superficial anaesthesia of the mucous membrane therefore a short time period was vital.

The surgery had two obvious disadvantages: primary, supporting and cosmetically important structures had to remain untouched. Especially area 1 and area 2’s dorsal part were spared during resection. But many a times it was these parts which were distorted, putting the surgeon in a difficult situation: either leave the deformities untouched, what rendered functional results unsatisfactorily; or try to remove more cartilage from these areas, what lead to significant cosmetic changes of the saddle nose and retraction of the Columella later on (Cottle 1950, Frohn 1968).

In addition, post surgically, an important part of the septum consisted of blades of mucous membrane only, what caused vibrations when inhaling or exhaling deeply. Furthermore, unwanted complications developed frequently, especially perforations of the septum. When not too experienced surgeons performed the intervention the septum was practically destroyed; with severe consequences for the nasal cycle. On account of the disadvantages portrayed above a new surgical method has step by step removed the hitherto existing septum resection from the nineteen fifties on: septoplasty. This development was not always an easy one and frequently accompanied by conflicts; today however, we regard septum resection as obsolete.

Some disadvantages of septum resection, like postoperative perforations and vibration can be avoided with septoplasty. This surgical method does not remove the cartilaginous, osseous framework, but “straightens” (Cottle 1950, Goldmann 1955) it, using several surgical techniques. For the uncompromising straightening of the septum the advantages of septoplasty are not so evident. The problem scilicet is that the surgical manipulations used to straightening, e.g. serial incisions, crushing, island formation, etc. weaken the cartilage mechanically, and thus it loses its supporting function (Ey 1969, Vuyk 1997). By reason of the resulting aesthetic complications the deformities of caudal and dorsal cartilaginous areas (area 1 and 2) cannot be corrected even using this state-of-the-art method.

Septum deformations which cannot be corrected with a conventional septoplasty, are called "difficult septum".

In order to enhance septum surgery not only the aforementioned functional problems were decisive. In that regard, surgeons were forced to make a compromise. In interventions where cosmetic results, like a straightened dorsum or a deformed tip came to the fore, no compromises were possible; after all, caudal borders and dorsal region had to be corrected categorically. For decades the inner nose remained untouched due to the above cited reasons, plastic surgeons attempted to correct merely the septum regions visible from the outside. When necessary, endonasal surgery followed later on, in order to correct dysfunctions. For both surgical methods the surgeon was forced to make a compromise; thus in many cases, neither cosmetics nor function were improved satisfactorily. Only in the last forty years surgical solutions were aimed for which allowed correcting cosmetic and functional deformities thoroughgoingly in one session only (Lamont 1948, Wirth 1958, Clark 1967, Meyer 1983, Kastenbauer 1989). Such surgical techniques were published under synonymous names, e.g. full septum reconstruction, extra corporal septum reconstruction, etc. (Gubisch 1992, Rees 1986, Jugo 1987).

Precursor of full septum reconstruction was the so-called “Septumaustauschplastik” (Hellmich 1973). Based on the observation that the posterior section of the cartilage is generally more or less straight part of the cartilage was extracted from this area and engrafted instead of the deviated cartilaginous segments, which had been removed at the beginning of the operation. After straightening, the anterior abscised part has been engrafted on the back where no supporting function was required. More and more pronounced septum parts were substituted; still, the results failed to be ideal. The reason for it was that is was many times impossible to fix the engrafted part reliably on the other cartilage, since the entries from the hemitransfixation incision known to date, did not grant enough tolerance.

A wider access was only possible from an external incision.

Hence Rethi’s method, access to the nose through a Columella incision was readopted. The technique now employed by Sercer has also proven valid in septum surgery, because it allows to represent the entire septum in one piece and to correct it operationally (Sercer

1962 und 1965). Needless to say that many authors have modified the original access or refined the incision conduct; whereby not only the septum, but the entire tip of the nose and the complete dorsum could be accessed.

Due to this new access not only exchange techniques could be performed more easily, but as soon as the septum could be viewed as a whole it was found out that even a massively deviated septum is composed of individual parts, which are in itself straight; this then gave rise to the idea that the deformed cartilage could be dissected into its small straight sections and a straight septum be reconstructed with these. It was, however, necessary to mobilise, dislodge the entire cartilage temporarily, and straighten it outside of the nose and to re-implant it afterwards. This technique became known as extra corporal septoplasty or external septum reconstruction; literature shows several more modifications (Jones 1991, Mangat 1988, Gubisch 1992).

However, even the introduction of the extra corporal septoplasty failed to be the perfect solution for the correction of a difficult septum. The intervention remained a unique surgical technique, performed only by a few very experienced surgeons; because the deformed septum cartilage had to be segmented into several smaller sections, thereafter it was rather technically complex and time consuming to retain the sutures. The Hyaline cartilage is extremely difficult to stitch end to end because the fragments retained in such a way snap off easily under stress and shift.

An excellent fixation remained all the same requisite, in order to ensure that the re-implanted septum be sufficiently stable to support nasal dorsum, tip and columella. Furthermore, an overlapping of the cartilaginous sections would thicken the septum too much. If the fixation was inadequate grave cosmetic defects and dysfunctions would occur. Above all by reason of this risk the extra corporal septum resection has not become routine procedure. In everyday practice surgeons still engage in compromises.

5. Compound graft as solution for the difficult septum

5.1. Introduction

Like any other surgeon, I have had problems performing the extracorporal septoplasty. In the end the fixation of the 6-7 smaller and larger cartilage fragments was never satisfying. Not only the operation time has been prolonged by one hour on average, but I never was completely convinced that the mechanical quality of the cartilage graft was going to be sufficient to support the nasal dorsum. Despite meticulous suturing of the cartilage fragments a slight saddle deformity occurred almost in all cases 6 months after surgery.

In a search for a better solution it came to my mind that we had successfully used an alloplastic material, Polydioxanone (PDS), to correct posttraumatic deformities of the orbital floor. The PDS foil can bridge the bony defect and supports the eye ball until it will be fixed at the callus. After a few months the implant degrades and is resolved from the body.

The situation in extra corporal septal reconstruction is similar, and it seems to be an advantage to support divided fragments of cartilage, as long as solid tissue formation eventually ensues in order to strengthen the nasal dorsum. Literature lists the following basic requirements for implants:

Apart from the basic standards for an implant - biocompatibility, no risk of contamination with micro-organisms: AIDS, hepatitis, prions – materials used for support are presumed to fulfil the following special requirements:

- They must be available in a size matching the undivided septal cartilage (3x4 cm), and straight over their entire dimension.
- they must possess the desired qualities of stability and flexibility
- they must be thinner than 1mm in order to avoid widening of the septum
- they must be easily attached to the cartilage.

If we evaluate all the biomaterials generally used we come to the following conclusions: the ideal implant would be an autogenic cartilage plate, recognised as implant of first choice for nasal reconstruction. Unfortunately it is presently impossible to obtain an autogenic cartilage graft in the size and shape desired in this case.

Fascia or other soft tissue is unsuitable, due to its lack of stability. Autogenic bone grafts, although they have enough shape retaining characteristics, are not ideal because of the outstanding flexibility. It is also difficult to acquire them in the desired size and thickness. In addition, a solution to the problem of how to attach them to the cartilage has not yet been found.

Allografts are rejected nowadays due to risk of contamination with microorganisms (AIDS. Hepatitis).

Alloplastic materials currently offered are generally well tolerated. However, they must be implanted completely without tension or pressure on the overlying tissues, since this might cause ischaemia and necrosis. For this reason, their implantation in the area of the nose presents a perilous situation, for the lower two-fifths of the nose is in continuous motion. Besides, in the course of a lifetime, the nose is exposed to numerous minor or major traumas, leading to wound tension and pressure on the connected overlying tissues with negative consequences.

An ostensibly ideal solution is offered by resorbable implants. They ensure high mechanical steadiness for the reconstructive septum, until healing stabilizes the cartilage, and they will be resorbed within a few months, thus excluding long term complications.

5.2. Compound graft

To facilitate the extracorporal septal reconstruction, I have invented a new technique: the septal reconstruction with a resorbable alloplastic material — the ‘PDS foil’.

PDS or polydioxanone (produced by the Ethicon Company, Norderstedt, Germany) is degradable by hydrolysis and completely resorbed by the body, thus excluding the long-term complications of other artificial implants. PDS foils are available in various sizes and gauges, and they have been used successfully for a number of years for the restoration of bone discontinuities (Hollinger 1986). This PDS foil serves as carrying material.

The trimmed fragments of the removed septal cartilage can not only be fixed to the foil by PDS suture material easily, but the PDS also supports the nasal dorsum until the stabilization of the cartilage fragments by scar tissue is guaranteed. (Fig 12-14)

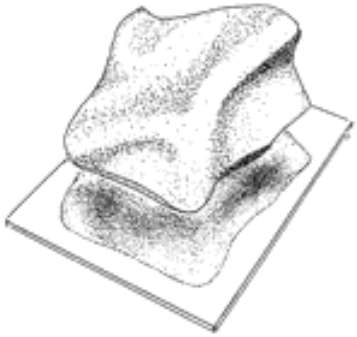

Fig 12: The removed septal cartilage is copied onto the foil to determine the exact size of the needed graft

Fig 13: The cartilage is divided into its straight pieces

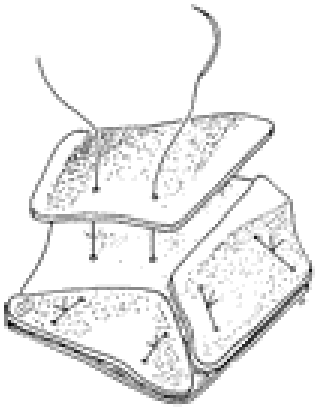

Fig 14: The cartilage fragments are sutured to the PDS foil

The herewith created graft, consisting of autologous cartilage and the PDS foil, was called „Compound Graft“ (Boenisch 1999).

5.3. Animal studies

After searching the literature, no data could be found concerning the biological properties of PDS foil in combination with hyaline cartilage. Therefore we started two series of animal experiments with young rabbits.
During the first study we inserted the PDS foil underneath the skin in direct connection to the ear cartilage and in the second study we combined the PDS foil with growing septal cartilage.

5.3.1. Influence of PDS-foil on hyalin catilage

5 rabbits aged 4 weeks have been operated under general anaesthesia using Ketamin (100mg/kg i.m.). A PDS foil has been implanted in combination with cartilage into the outer ear. After a 2 cm long vertical skin incision on the dorsal side of the outer ear and blunt division of the muscle, the perichondrium was incised to free the cartilage. Next a 0.5 x 0.5 cm cartilage defect was created and a 1.5 x 1.5 cm piece of PDS foil (ZX8, 0.15 mm thick) was implanted, covering both the defect and the cartilage. The incision was closed using catgut sutures in one layer. Finally the rabbits received a single dose of antibiotics peroral. The animals were observed periodically. All wounds healed per primam and the further development of the animals was undisturbed. After 2, 5, 10,15 and 25 weeks the animals were killed and the prepared region of the outer ear removed in toto. Specimen were formalin fixated, Haematoxy- Eosin stained and light microscopic examinated. (During the operation, the observation time and the killing the valid animal protecting law was reflected.)

In examinating the specimen we particularly took care of information concerning the following points:

- How long remains the continuity of the implant unchanged?
- How long takes the resorption procedure?
- Which kind are the side effects (inflammatory or foreign body reaction), occurring whilst the resorption procedure?
- Is there a modification of the cartilage 1. Underneath the foil, 2. At the border of the cartilage defect?
- What about the remaining scar tissue?

2 weeks after implantation the implant is completely unchanged and surrounded by minimal reactive tissue, forming a thin capsule. There is no inflammatory infiltration and no foreign body reaction. The cartilage remains unchanged as well. (Fig 15)

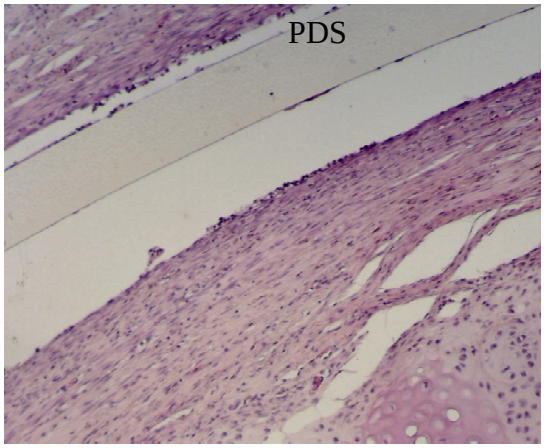

Fig 15: 2 weeks after implantation, PDS-foil (PDS) completely unchanged

5 weeks after implantation the situation appears similar. The continuity of the implant is still just as it was. There is absolutely no inflammatory or foreign body reaction. The cartilage is unchanged. (Fig 16)

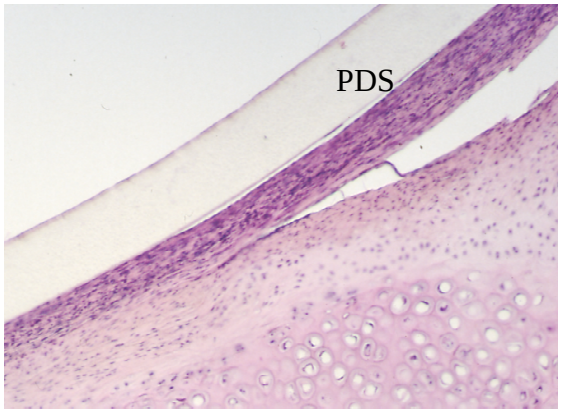

Fig 16: 5 weeks after implantation, no significant changes

10 weeks after implantation resorption of the implant has already begun and its continuity is interrupted. The implant is still surrounded by the thin layer of reactive tissue, which additionally fills the perforation of the foil, guaranteeing good fixation. For the first time chondroblasts occur on the border of the cartilage defect. (Fig 17)

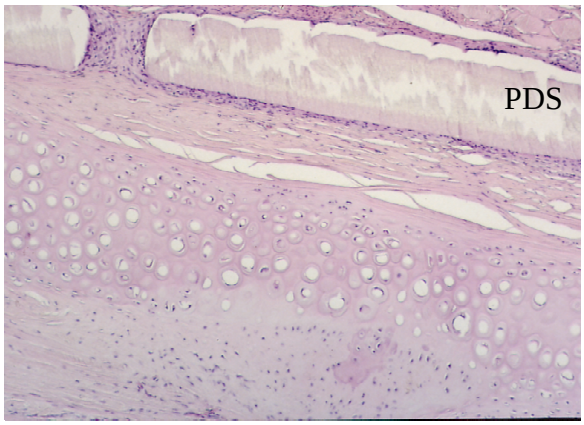

Fig 17: 10 weeks after implantation, the degradation of the foil begins

15 weeks after implantation the resorption procedure has progressed, the PDS particles are encapsulated by fibrous tissue. Noticeable tissue reaction remains solely in the area of the implant. (Fig 18)

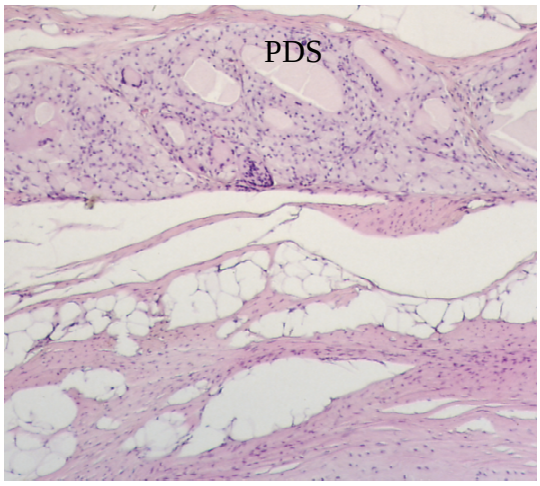

Fig. 18: 15 weeks after implantation, PDS particles are encapsulated by fibrous tissue

Bordering the cartilage defect newly formed cartilage has developed. The cartilage underneath the foil is unchanged. (Fig 19)

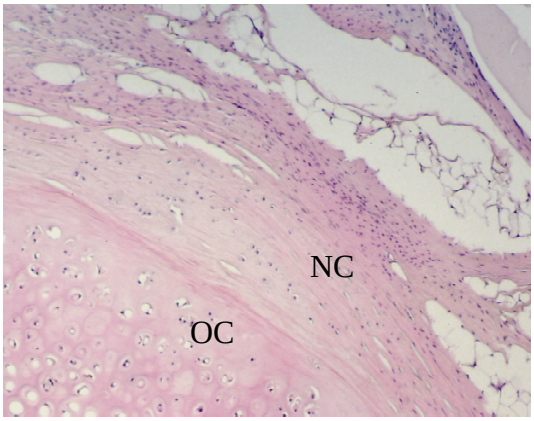

Fig 19: 15 weeks after implantation of PDS foil NC: newly formed cartilage, OC: original cartilage

25 weeks after implantation the implant is completely resorbed. Even after examination of the entire specimen no residues were found. Only minimal remains of fibrous scar tissue stays behind. (Fig 20)

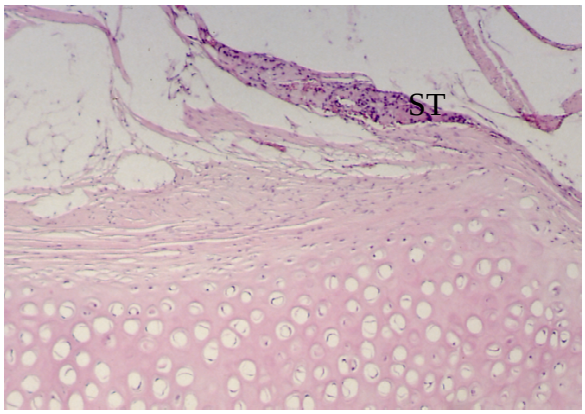

Fig 20: 25 weeks after implantation, only minimal scar tissue (ST) is left

From these findings one can draw the following observations:

- The implant remains at least 10 weeks unchanged from light-microscopic view.
- After 25 weeks the implant is completely resorbed.
- Only in the immediate vicinity of the implant tissue reaction occurs. The operation area remains free of inflammatory reactions and granulation tissue.

- The cartilage underneath the implant remains completely unchanged from histological view. Bordering the cartilage defect initially chondroblasts and subsequently new formed cartilage occurs.
- Finally, after conclusion of the resorption procedure only minimal fibrous scar tissue remains.

5.3.2. Morphological and histological findings after typical surgical manipulations on growing septal cartilage in rabbits

The most typical surgical steps during septoplasty are: the elevation and reposition of the mucoperichondrium, the excision, the excision and reimplantation of crushed and non crushed septal cartilage. The resulting surgical trauma is well tolerated in adults. However, in growing septal cartilage it often leads to severe late complications, such as growth inhibition of the nose and maxilla and recurrent deviations of the septum. These deformities occur because the regenerated cartilage, which is formed during the healing process, is different from the original septal cartilage. Histologically the regenerated cartilage shows smaller chondrocytes without any columnar arrangement, which is typical for original septal cartilage (Nolst Trenité 1988) . Besides, an overlap and deviation of cartilage fragments due to the interlocked stresses often occurs during the healing process (Verwoerd 1991).

Our clinical experiences referring to septal reconstruction with PDS-foil in adults (Boenisch 1999) as well as our observation of experiments using the PDS-foil in connection with ear cartilage in rabbits (Boenisch 2000) suggested, that the PDS foil successfully prevents postoperative sequelae like dislocation of the reimplanted cartilage fragments, and recurrent deviation caused by overlapping of the cartilage borders. Furthermore it seems to stimulate cartilage regeneration.

The question occurs, whether the same effect can be expected if growing septal cartilage is supported by the PDS-foil. To answer this question an experimental and histological study was performed, using growing New Zealand White rabbits as a model.

8 groups of 5 New Zealand White female rabbits where used in this experimental study. The animals were operated on under general anaesthesia with Ketamine 100 mg/kg i.m.

Surgery was performed under direct operating-microscopic view. The nasal septum was approached via the nasal dorsum: The operation field was infiltrated with 1ml Xylocain 1% with Epinephrin 1:100 000. After a vertical skin incision the nasal bones were separated in the sutura internasalis. (Fig 21)

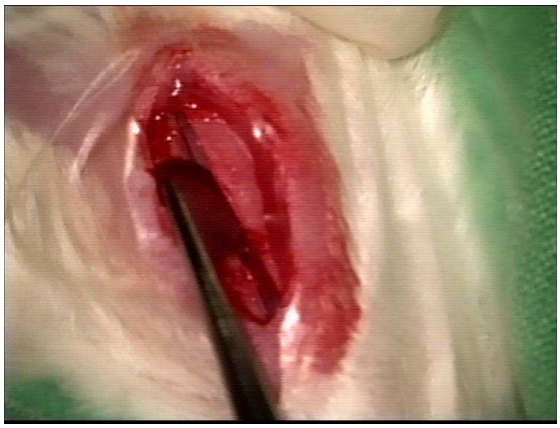

Fig.21:The nasal bones are separated in the sutura internasalis

The bones were spread out to a distance of 5 mm without further traumatisation.
This technical modification of the approach allows to preserve the integrity of the mucoperichondrium on both sides, which prevents local infections and makes any nasal package unnecessary. (Fig 22)

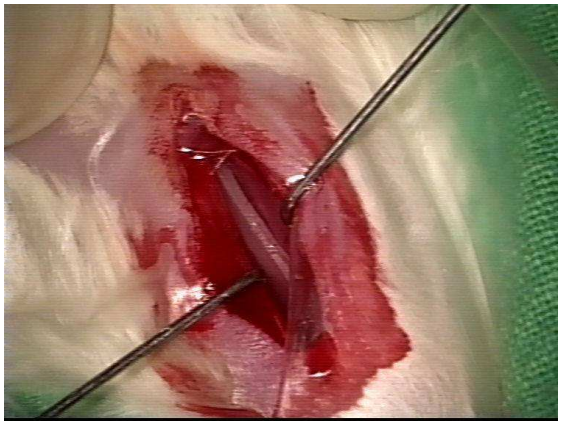

Fig. 22: After separation of the nasal bones, the mucoperichondrium is incised and the septal cartilage is visible

The mucoperichondrium was separated from the dorsal border of the septal cartilage and elevated on both sides over the middle third of the septum.

In group I/a the mucoperichondrium was simply elevated and repositioned, in group I/b a square PDS foil 15x15mm (Ethicon, Norderstedt, Germany) was inserted submucoperichondrial on the left side.

Concerning the other groups the following cartilage work was performed after creating a subperichondrial tunnel on both sides:

In group II/a five animals a 10x10mm piece of cartilage of the middle third was resected (after elevation of the mucoperichondrium) without reimplantation and the mucoperichondrium was repositioned. In group II/b the resulting cartilage defect was covered with a 15x15mm PDS foil on the left side without a special fixation.

In group III a 10x10mm piece of cartilage was resected, trimmed to the size of the defect (which became smaller due to the interlocked stresses) to achieve an end to end connection, and reimplanted, respectively sutured onto a PDS foil (15x15mm) and reimplanted together. (groupIII/b)

In the last two groups the resected piece of cartilage was crushed and shortened before reimplantation without (IV/a) and with (IV/b) PDS foil. (Fig 23)

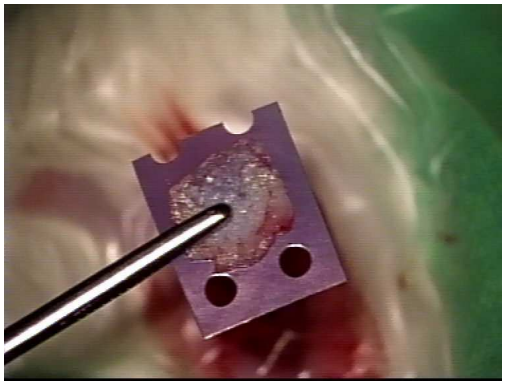

Fig.23: Crushed septal cartilage with a piece of PDS foil

After finishing the septal work, the wound was closed primarily. (Fig 24)

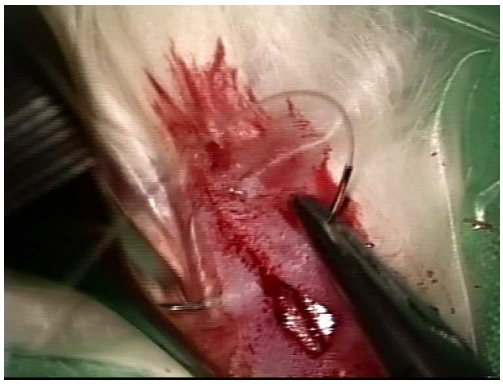

Fig 24: Primarily wound closure

The animals were sacrificed 2, 4, 10, 16 and 25 weeks after surgery. For histologic examinations the septa were resected monoblock (Fig. 25) with parts of the bony palate and the nasal bones, and fixated in 5% formaldehyde.

Fig. 25: The removed nasal septum with parts of the bony palate and nasal bones of a rabbit 25 weeks after surgery

The specimen were cut horizontally to make sure that the operated area is included completely, cut in serial sections with 4µm and stained with HE and PAS. By the light microscopic examination we wanted to investigate the following questions concerning the healing process:

- Is the PDS-Foil a guideline for regenerated cartilage ?
- Is the PDS-Foil able to prevent overlapping of cartilage fragments ?
- Is there an effect on the histological properties of the new formed cartilage ?

In group I there are no significant differences concerning the histologic reactions between the group with and the group without PDS. After 2, 4 and 10weeks the foil did not show microscopic resorption, and the surrounding tissue reaction is similar to the group a without PDS.

After 16 weeks in the group without PDS there are no further histological reactions to observe. The mucoperichondrium is of normal thickness and the cartilage is histologically unchanged. In the group I b the PDS foil is already partially resorbed, with persisting fragments of PDS surrounded by a thin layer of fibrous tissue without inflammatory reaction. The cartilage is unchanged as well.

After 25 weeks the PDS foil is completely resorbed. Beneath the normal cartilage only very thin remnants of scar tissue, practically without thickening of the septum could be observed.

In group II the essential difference between the two subgroups is the fact, that after resection of septal cartilage, in group II a, the two layers of mucoperichondrium are in direct contact, but in group II b the mucoperichondrium is separated by the PDS. After 2 and 4 weeks there are no notable differences in histologic reactions of remaining cartilage and surrounding tissue. In both subgroups proliferative reactions between the mucoperichondrium blades occur, with a growing tendency of cell differentiation into chondroblasts. After 10 weeks in both subgroups regenerated cartilage occur, but the chondrocytes are smaller and without a columnar arrangement. In later specimen an obvious morphologic alteration between the subgroups can be found: without PDS the new formed cartilage often develops secondary deviations, which is remarkable reduced with PDS.(Fig. 26 a, 26 b)

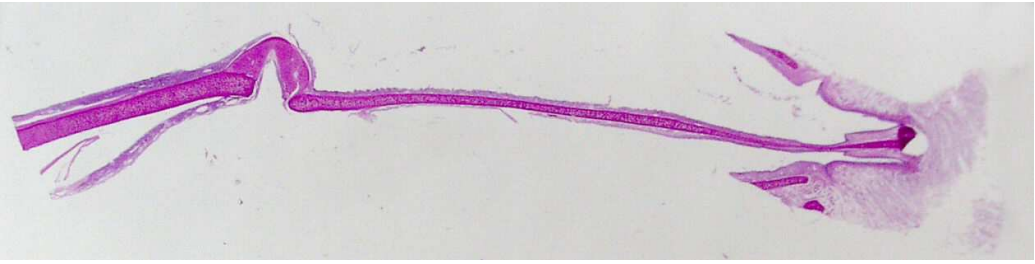

Fig. 26 a:. 25 weeks after cartilage resection without PDS. The new formed cartilage forms a deviation between the to ends of the original cartilage

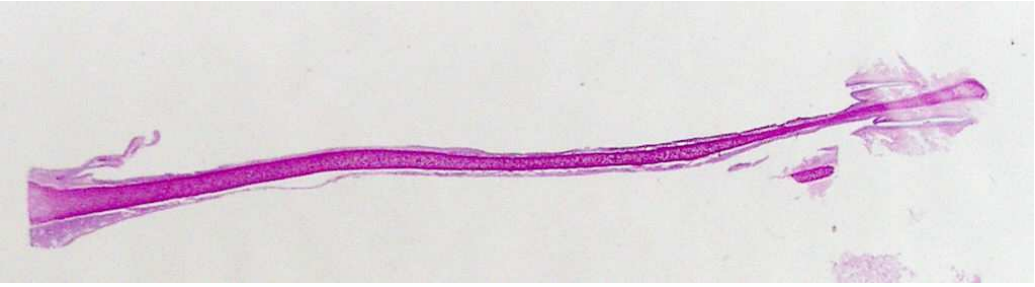

Fig 26 b.:25 weeks after cartilage resection with PDS. There is no deviation visible

The difference is also significant from histological view: In group II a the area of the new formed cartilage showed smaller chondrocytes without any arrangement. The new formed cartilage in the group II b (with PDS-foil) however, shows a mature appearance, similar to original septal cartilage. (Fig. 27 a, b)

Fig 27 a: 25 weeks after cartilage resection without PDS, the new formed cartilage shows smaller chondrocytes without any columnar arrangement

Fig 27 b: 25 weeks after cartilage resection with PDS there is normal appearance off the cartilage

In group III a, 4 weeks after surgery the reimplanted cartilage grafts often show an overlapping in the area of the cut edges, although this area is firmly covered by the mucoperichondrium on both sides. The beginning cartilage regeneration causes development of new deviation. In group III b the PDS foil stabilizes the free graft and prevents overlapping. (Fig 28 a,b)

Fig 28 a: 6 months after excision and reimplantation without PDS. There is overlapping and deviation of the cartilage

Fig 28 b: 6 months after excision and reimplantation with PDS without any overlapping or deviation

In the area of the connection between original cartilage and the cartilage graft, in groupIIIa there was no real cartilaginous healing without fibrous tissue, whereas in group IIIb real cartilaginous healing, proved by blood vessels in the cartilage could be found. (Fig 29 a. b)

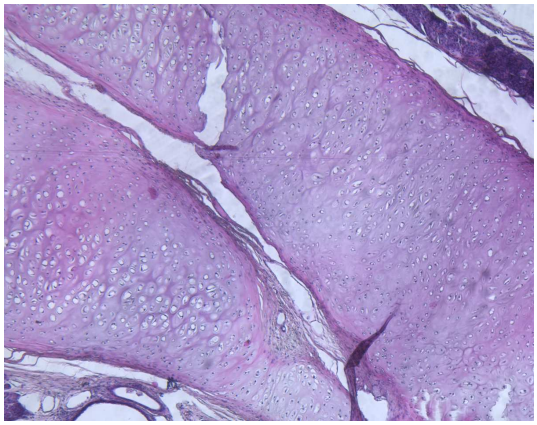

Fig 29 a: group III a without PDS, fibrous tissue between the overlapped cartilage fragments

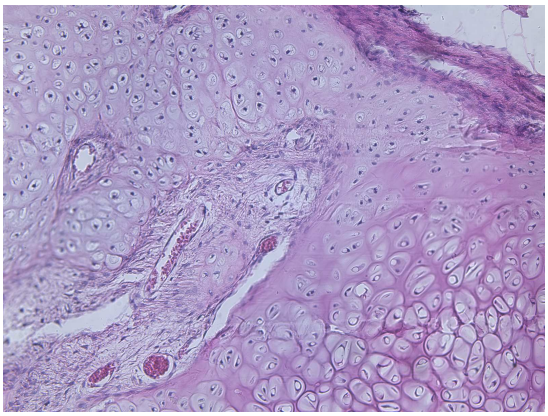

Fig 29 b: group III b, with PDS there is real cartilaginous healing proofed by the blood vessel

In group IV with reimplantation of crushed cartilage, the most significant morphologic and histologic differences can be found. The early results of the two subgroups after 2 and 4 weeks are again quite similar, but after 10, 16 and 25 weeks the differences are increasing: In group IV a without PDS, in the area of the reimplanted crushed cartilage the regenerated cartilage causes various degrees of deviations .In areas where the crushed cartilage gets resorbed new bone formation occurs (Fig. 30 a,b)

Fig. 30 a: 25 weeks after reimplantation of a crushed cartilage graft without PDS not only deviated

Fig 30 b: 25 weeks after reimplantation of a crushed cartilage graft without PDS we see an area of cartilage resorption and bone transformation

In group IV b with PDS the crushed cartilage healed almost without macroscopic trace. (Fig. 31 a, b).

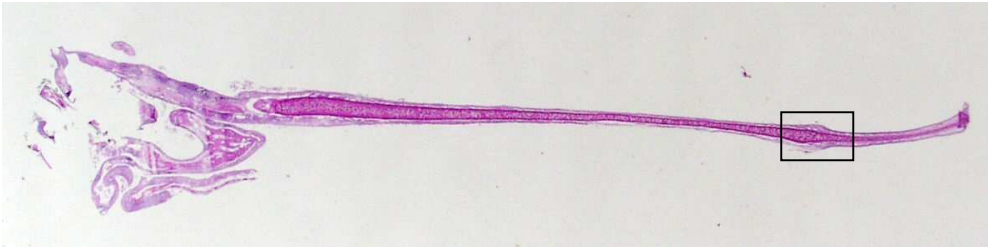

Fig 31 a: 25 weeks after excision and reimplantation of a crushed cartilage graft in combination with PDS

Fig 31 b: 25 weeks after reimplantation of crushed cartilage in combination with PDS. Only microscopic changes of the cartilage structure are visible

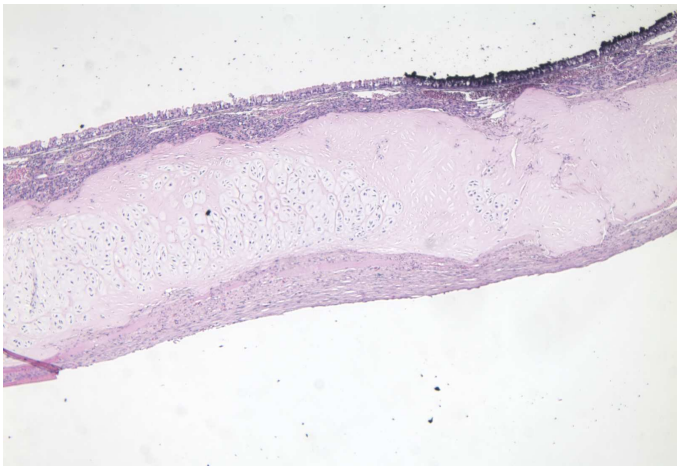

5.3.3. Conclusions of the animal studies

In that kind of application of a resorbable implant, we have to consider three special questions concerning the implant:

1. Remains the form stability and the continuity of the implant as long as the healing process of the supporting tissue is finished?
2. Are the degradation products interfering with the healing tissue?

3. How many scar tissue remains after resorption in the implantation area?

The general biological properties of Polydioxanone (PDS) has been examined in numerous studies in combination of the implant with bone (Hollinger 1986). They proofed, that the degradation products of the synthetic aliphatic polymer did not interfere with the normal healing process at all, but stimulated the regeneration of bone as osteoconductive properties. Regarding our animal study, we were able to examine the histological background of the healing process of an artificial cartilage defect in combination of the PDS foil. Up to the 10th week after the implantation the foil remained untouched from degradation and the continuing form stability enabled the desired supporting function. If the foil was implanted subperichondrial directly covering the cartilage thin reactive tissue, forming a pseudo capsule quickly occurred, preventing necrosis of the underlying cartilage as reported after implantation of some non resorbable implants. Additionally this thin tissue layer ensures nutrition of the chondrocyts. Obviously new formed cartilage developed of in the area of the artificial cartilage defects. The degradation products resulting from the resorption and metabolisation of the Polydioxanone, had no bad effect on the regeneration process of the cartilage, as known from other artificial implants (Nolst Trenité 1984). It even provides a guarding support of the cartilage regeneration, similar to the osteoconductive properties. During the resorption procedure tissue reaction remained strictly in the area of the implant, which can account for the lack of reaction of the septal mucosa after septal surgery using the PDS foil. Besides, tissue reaction disappears completely after closure of the resorption procedure, thus excluding unilateral scarring, which can lead to postoperative deformation and bending of the septal cartilage, as well as persistent postoperative thickening of the septum.

Elevation of the mucoperichondrium, excision, reimplantation and crushing of cartilage are standard procedures in septoplasty. The consequence of these procedures for septal surgery in children has been investigated in former studies (Poublon 1987, Lang 1987).

In this recent research project the effect of the utilization of the resorbable pds foil was studied in the above mentioned standard septoplasty procedures.

The elevation of the mucoperichondrium does not induce significant histological reactions and has no affection on the growth of the septal cartilage. The PDS foil inserted on one side of the cartilage causes no significant change of these reactions and after 25 weeks after complete resorption of the foil almost no fibrous scar tissue could be found, so there was no thickening of the septum.

After elevation of the mucoperichondrium in combination with cartilage resection, regeneration occurs and forms a bridge between the anterior and posterior fragments of the original cartilage. But even after 25 weeks this new formed cartilage remains histologically different from the original cartilage with smaller chondrocytes and without any columnar arrangement. This type of cartilage has a tendency of bending, causing secondary septal deviations. The insertion of a PDS foil after cartilage resection which covers the area of the cartilage defect seems to work as some sort of guiding material for the regenerated cartilage. This helps significant to decrease the secondary deviation of the new formed cartilage . It even seems to have an effect on the histological appearance of this regenerated cartilage, because in some specimen we could find no difference between the original and regenerated cartilage.

After resection and reimplantation of the original septal cartilage as a free graft, there is always a tendency of overlapping and angulation between the original septal cartilage and the graft (Verwoerd 1991) . The cut edges stay covered with fibrous tissue, thus representing a permanent weak point of the septum. The specimen with PDS foil showed significantly less secondary deviations, and in some specimen even the cut edges could not be identified after 25 weeks. An entire plate of septal cartilage had developed. After complete resorption of the foil almost no scar tissue was left.

After implantation of crushed cartilage grafts the connection between the graft and the original cartilage is always better, as we know from former studies (Rees 1986). Secondary deviations however occur as a result of bending of the cartilage graft itself. This bending can be reduced significantly by combining the crushed cartilage with a PDS foil, which supports the graft as some sort of guiding material, stimulating normal growth.

Alloplastic implants are generally used for their mechanical stability as supporting material, which is also useful for the combination of cartilage and resorbable PDS foil. Besides, implants are only necessary as long as the healing process of the supporting tissue takes, afterwards they have to be removed, to avoid long-term complications. This can easily be evaded, using resorbable implants, which are completely eliminated after a limited period.
The combination of septal cartilage with a resorbable Polydioxanone foil therefore enables a combination of the technical advantages during the operation with the postoperative advantages of a resorbable implant. There were no inflammatory and no foreign body reactions found, and in the area of an artificial cartilage defect newly formed cartilage had developed.

This study shows remarkable effects of the resorbable PDS-foil in healing and regeneration of the growing septum up to complete resorption of the PDS, which coincidentally parallels the outgrowth of the septal cartilage in rabbits. Such as in cartilage regeneration and in prevention of secondary septal deviations due to bending of the new formed cartilage or incomplete healing of cut edges.

5.4. Clinical Studies

5.4.1. Patient Evaluation

The goal of either functional or cosmetic rhinoplasty is to obtain a good functional and/or cosmetic result, and also to meet the patient's expectations. Therefore it is essential to evaluate motivations, expectations and mental health of the patient, as well as to guide the patient to a form of self- analysis.

Patients seek nasal surgery for a variety of reasons; patients after trauma however, compose a slightly different category. Many of them would have never considered surgery, if acute trauma had not produced a deformity or an airway insufficiency. Their motivations often differ from the patient troubled by a long standing nasal deformity, since they essentially wish the nose restored to its former pre-injury appearance and contour. Others will expect a pre-existing deformity to be corrected under the justification of the recent nasal injury. Generally, trauma patients do not seem to be troubled by an altered self image, and they are clearly well motivated as a result of nasal injury. It is necessary, however, to investigate their inner concern with sensitivity, just as one would with a patient contemplating aesthetic rhinoplasty.

I personally follow a routine programme including generally two preoperative consultations: starting with a personal approach of the patient -physical examination, standard photographs and a medical interview- to a kind of patient education in analysing and planning the surgical procedure.

The physical examination starts with an external inspection of the nose. Before concentrating on the nose it is essential to evaluate the balance between the nose and the rest of the face to ascertain possible asymmetries. These asymmetries pass often unnoticed by the patient and have to be explained later on while analysing the pictures, which helps to prevent possible later complaints about the result (Fig 32 a-c)

External examination of the nose includes the inspection and palpation of the nose, concerning the overall form, length, possible deviations, form and height of the nasal bridge, form and projection of the nasal tip and columella.



Fig 32 a-c: original frontal view (a), mirroring the right (b) and left (c) half of the face to demonstrate asymmetries

.
The internal examination starts first without a speculum in gentle and forced inhalation, in order to realize possible alar insufficiency or stenosis in the area of the nasal valve. It also includes an inspection of the vestibulum, the angle between the upper lateral cartilage and the septum, form and protrusion of the medial crura. Further inspection with the speculum reveals the inner parts of the septum and nose to assess possible septal deviations or mucosa pathology.

Following the physical examination is the objective functional examination with anterior rhinomanometry. The rhinomanometer divice I use is called “Flowhandy ZAN 100 USB”. This is a computer based system which can be operated via a locally installed computer or via notebook (Fig 33). This helps to document the airway resistances however, functional problems due to deformities in area 1, alar weakness or stenosis of the nasal valve are not always easy to record.

During the first consultation I always take a series of 6 standardised photographs, showing a frontal view, right and left oblique, lateral view and basal view (Fig 35). Immediately afterwards these pictures are studied and analysed on the computer with the aid of a computer imaging programme to show the patient how the nose will probably look like.



Fig 33: Flowhandy ZAN 100 USB Rhinomanometer

That is the time when I fill in my rhinoplasty assessment form, in order to have the possibility to discuss the steps of surgery with the patient (Fig 34). Subsequently we fill in the medical history, focusing on questions like bleeding disorders, previous trauma, previous surgery and allergies.

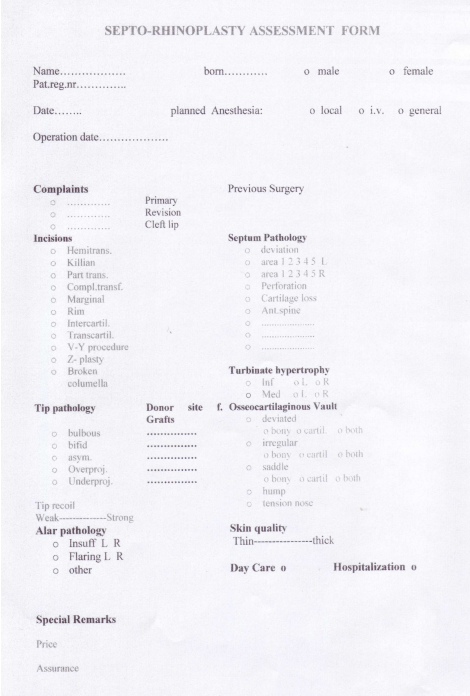

SEPTO-RHINOPLASTY ASSESSMENT FORM

Name…… born…… o male o female
Pat.reg.nr……..

Date…….. planned Anesthesia: o local o i.v. o general

Operation date……

Complaints
o ……
o ……
o ……

Primary
Revision
Cleft lip

Previous Surgery

Incisions
o Hemitrans.
o Killian
o Part trans.
o Compl.transf.
o Marginal
o Rim
o Intercartil.
o Transcartil.
o V-Y procedure
o Z- plasty
o Broken columella

Septum Pathology
o deviation
o area 1 2 3 4 5 L
o area 1 2 3 4 5 R
o Perforation
o Cartilage loss
o Ant.spine
o ……
o ……
o ……

Turbinate hypertrophy
o Inf o L o R
o Med o L o R

Tip pathology
o bulbous
o bifid
o asym.
o Overproj.
o Underproj.

Donor site Grafts
……
……
……
……
……

f. Osseocartilaginous Vault
o deviated
o bony o cartil. o both
o irregular
o bony o cartil o both
o saddle
o bony o cartil o both
o hump
o tension nose

Tip recoil
Weak----------Strong

Alar pathology
o Insuff L R
o Flaring L R
o other

Skin quality
Thin----------thick

Day Care o **Hospitalization o**

Special Remarks

Price

Assurance

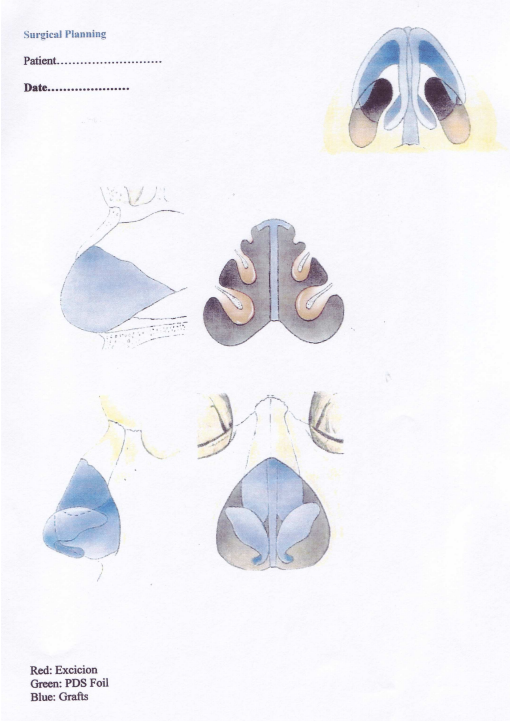

Fig 34: My own rhinoplasty assessment form (developed together with Dr. Petropoulos)

We also discuss the events before and after surgery and the patient receives written information about the rhinoplasty procedure and postoperative time.

The second examination takes place the day before or several days before surgery. We review the pictures taken during the first consultation, once more discuss the different steps of the procedure, answer possible questions and finally both sign the surgical consent.

Fig 35: standard series of 6 pre-operative pictures.

5.4.2. Surgical technique

Surgery can be performed under local- or general anaesthesia. For local anaesthesia mild sedation of the patient is recommended. 30 min. before surgery the patient receives 3ml of Dormicum® p.o. and already in the OR mild intravenous sedation with 2-3ml Nalbuphin® (2ml soluted in 5ml NaCl) i.v. If necessary, the rest of that solution can be given during surgery.

Local anaesthesia of the nose starts with the application of topical agent (Cocain 5% 3 ml) on cotton strips for several minutes. After that, local infiltration anaesthesia is carried out with lidocaine 2% with epinephrine 1:80.000. This provides long lasting anaesthesia and good vasoconstriction. Infiltration starts with a nerve blockage of the infraorbital nerve on both sides, making the infiltration of the nose more comfortable to the patient. For infiltration of the nose small amounts of solution are deposited in the right surgical planes, first along the planned incision lines, over the nasal dorsum, in the septum and in the area of the osteotomy lines. No more than 6 ml of this solution is needed for total anaesthesia of the entire outer and inner nose.

If surgery is performed under general anaesthesia, a mild controlled hypotension is recommended. Local infiltration of the inner and outer nose is the same (without nerve blockage) because of the need for vasoconstriction.

We usually start with a broken columella incision followed by marginal incisions for an external approach, which is very appropriate in case of an extra-corporal septoplasty. (Fig36)

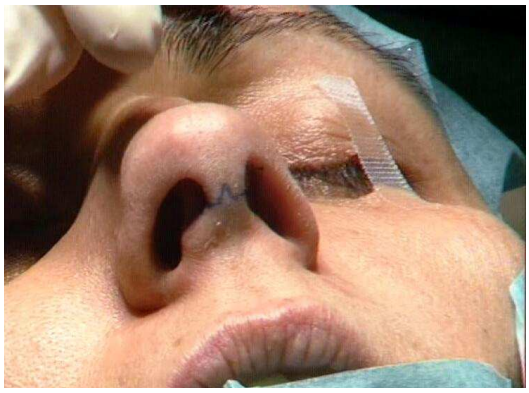

Fig 36: Marking of the broken columella incision

The next step, as usual in an external approach is the decollement of the skin and the soft tissue over the tip, the cartilaginous and bony dorsum in the right surgical plane. (Fig 37)

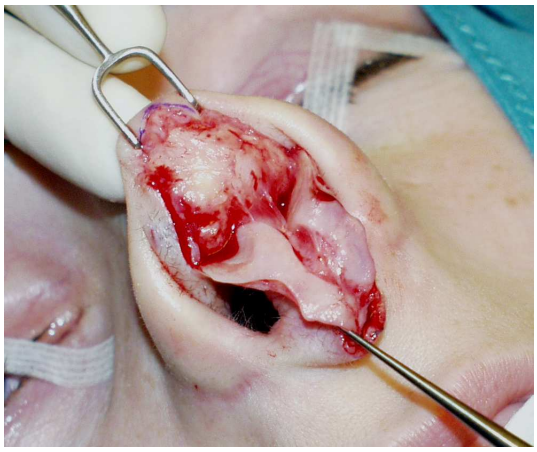

Fig. 37 Decollement of the skin and soft tissue over the tip

After separation of the medial crura of the lower laterals (Fig 38), we reach the caudal end of the septum. (Fig 39).

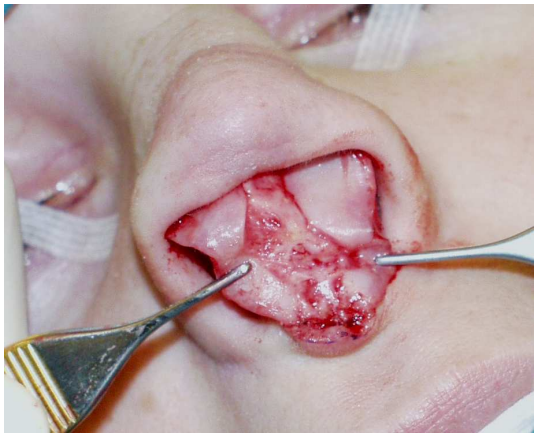

Fig 38: Separating the medial crura of the lower laterals

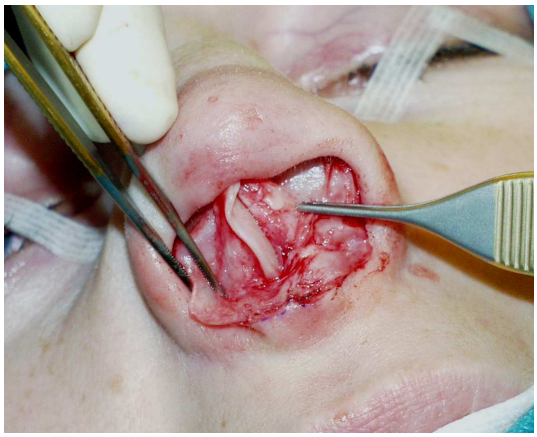

Fig 39: The caudal end of the septum is visible

Starting from here the mucoperichondrium is dissected free on both sides. (Fig 40)

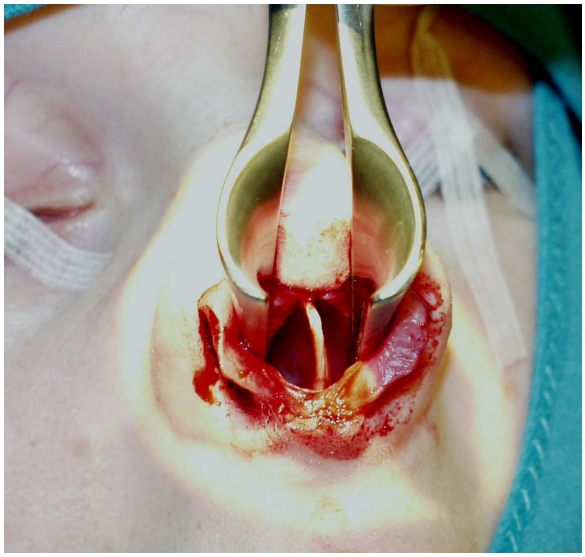

Fig 40: The mucoperichondrium is dissected free on both sides

After a posterior chondrotomy the upper laterals are separated from the septum. After detaching the septal cartilage from the maxillary crest and the vomer the septal cartilage is completely free and can be removed in one piece. (Fig 41)

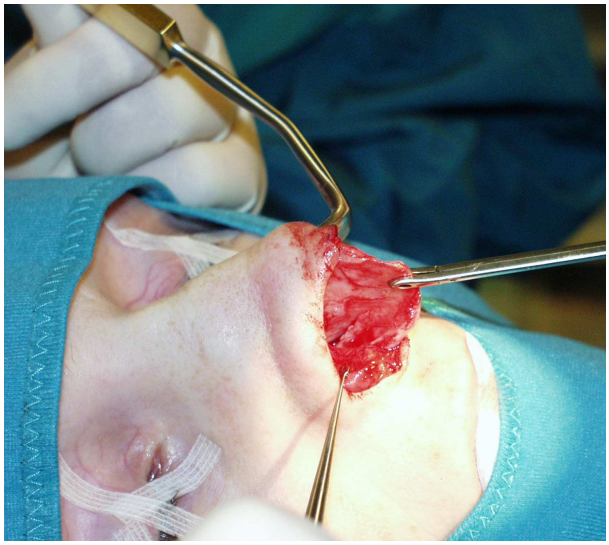

Fig41: The deviated cartilage is removed in one piece, the fracture lines can be identified

The removed cartilage is used as a template for cutting the foil. It is placed on the foil, the outlines of the removed cartilage are copied onto the PDS foil in order to determine the exact size of the septum to be reconstructed. (Fig42)

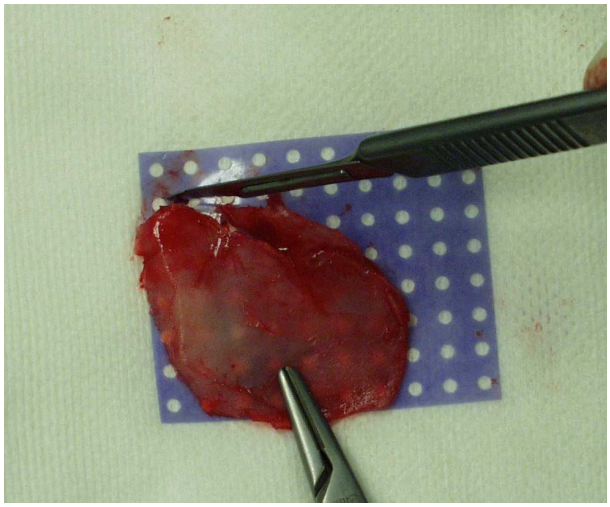

Fig 42: The cartilage is placed on the foil to determine the exact size of the needed graft

Using scissors, the foil is cut along marked lines, and the deviated cartilage can now be separated into straight pieces. These pieces are arranged upon the foil, ideally covering most of it. Particular attention should be paid to the pieces of cartilage composing the dorsal and caudal septal borders. In each of these two cases only one piece of cartilage should be used, regardless of its former position. After all the pieces are satisfactorily placed, they are sutured to the foil with PDS suture material, usually 6/0 (Fig 43) thus immediately creating a straight and stable graft ready for reimplantation. (Fig 44).

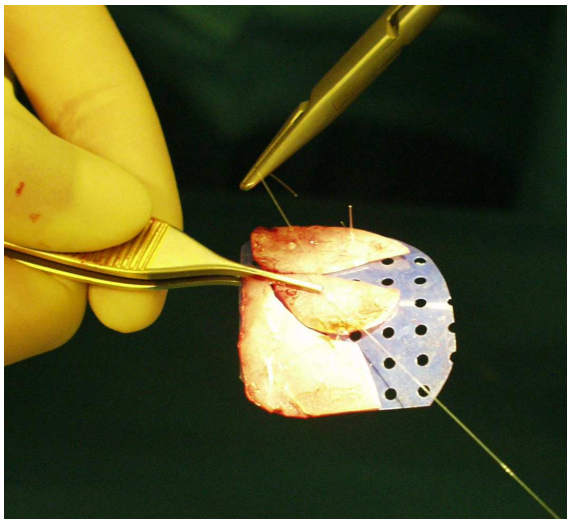

Fig 43: The pieces of cartilage are sutured to the PDS foil

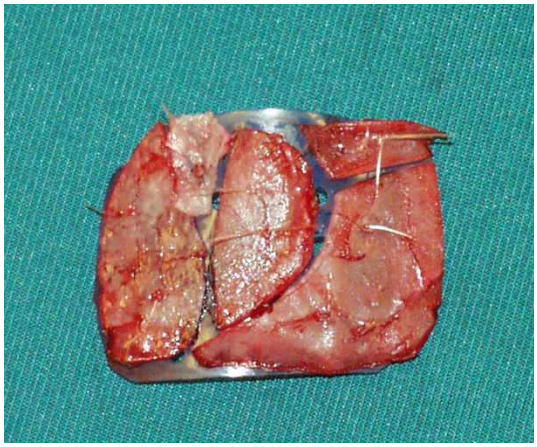

Fig 44: The finished graft

After correction of any possible deformities of the perpendicular plate and vomer, the reconstructed part of the septum, now combined with the PDS- foil, is placed between the two layers of septal mucosa and adjusted to the correct position (Fig 45-46).

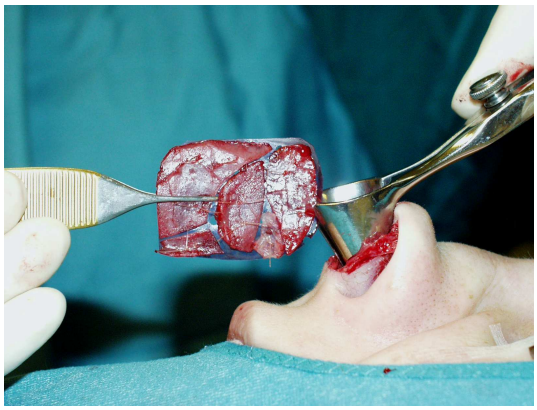

Fig 45: The graft is reimplanted into the nose

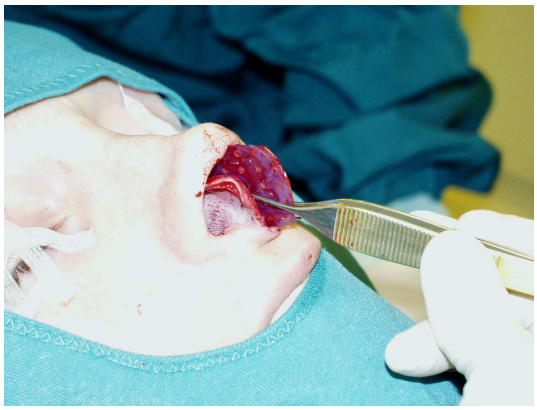

Fig 46: The graft is adjusted to the right position

In order to hold the graft in place, it is fixed with PDS sutures to the upper laterals, in the K-area, and to the periosteum of the anterior nasal spine. (Fig 47)

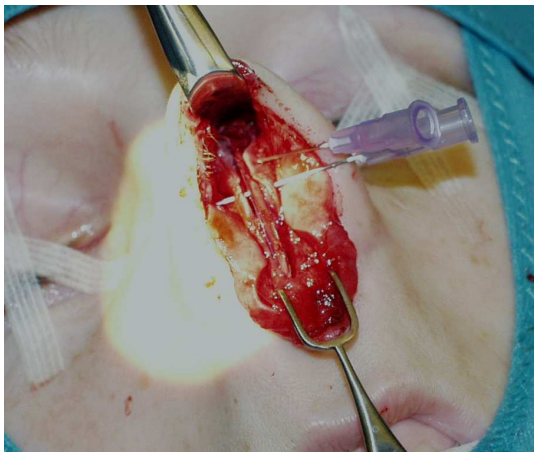

Fig 47: The graft is sutured to the upper lateral cartilages

Afterward a series of continuous trans-septal through- and through sutures is positioned to fix the septal flaps, thereby closing all dead space and firmly stabilising the septal component. (Fig 48). This mattress suture also prevents septal haematoma, therefore endonasal packing is not required.

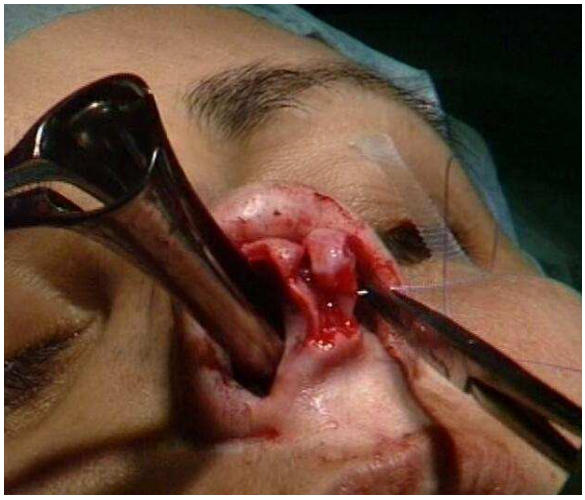

Fig 48: A series of transseptal mattress sutures fixes the septal flaps

Subsequently, the medial crura of the lower laterals are sutured over a columellar strut to maintain tip projection (Fig 49).

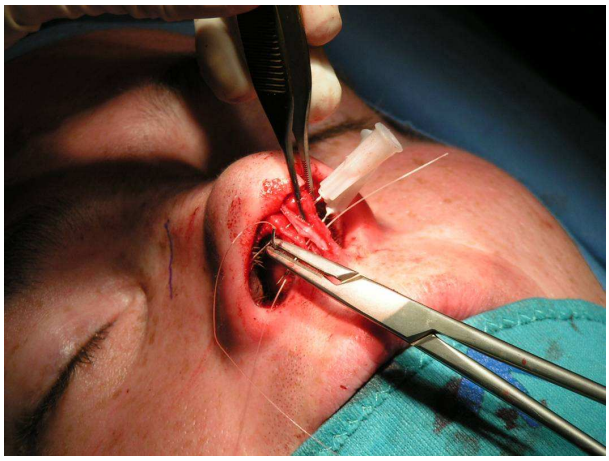

Fig 49: The medial crura of the lower laterals are sutured to the columella strut

In addition depending on the deformity, all the other well known steps of rhinoplasty as trimming of the lower laterals, tip suturing or osteotomies are performed. However, this is not further explained because it is not the topic of this thesis,.

After meticulous closure of the skin incision with nylon 6/0 (Fig 50), the nose is dressed from outside with a Denver splint (Fig 51).

Fig 50: The skin incision is closed meticulously

The external fixation is removed on the 6th day together with the columella sutures.
As a matter of routine, patients receive antibiotic prophylaxis (e. g. with an amoxycillin) over a three day period. For local follow-up treatment, patients use a spray of saline solution.

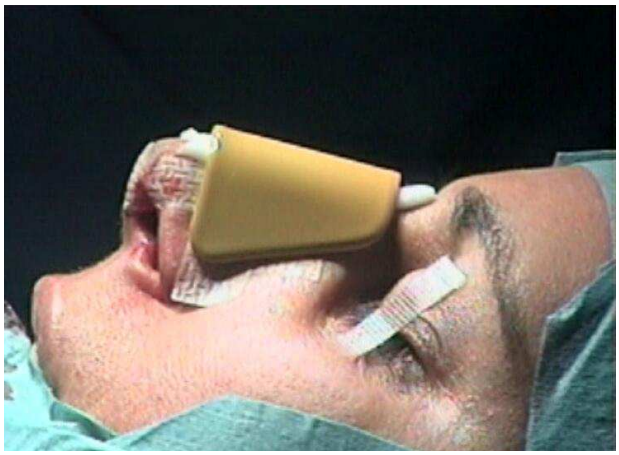

Fig 51: The nose is fixed from outside with a Denver splint

5.4.2. Further applications of compound graft

5.4.2.1. Combining septum and auricular conchal cartilage

In the case that owing to one or several prior surgeries there is not enough septum cartilage left, but a septum reconstruction is required in order to restore the function of the nose, then the missing cartilage can be supplanted with auricular conchal cartilage.
The auricular conchal cartilage is extracted in one session obeying the following procedure: (Nolst Trenité 2005):

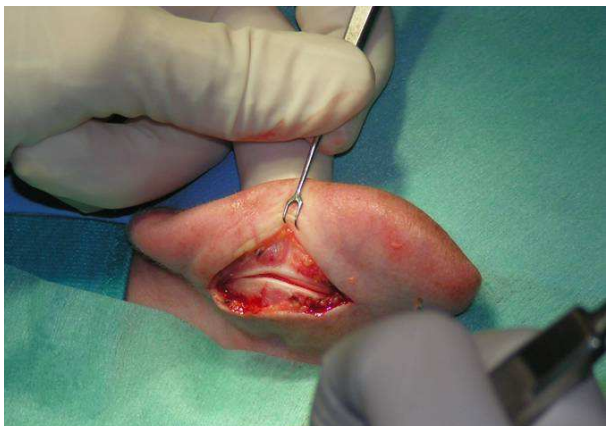

Fig 52: skin and cartilage incision on the posterior auricular side

After infiltration into the subperichondrial plane at the anterior side of the concha using the same local anaesthetic solution as in the nose (2% lidocaine with 1:80.000 epinephrine), the posterior side of the auricle is infiltrated into the supraperichondrial plane. After a skin incision on the posterior side, posterior perichondrium and cartilage are incised in a line just below the anthelix. (Fig 52)

Now blunt subperichondrial tunnelling is carried out on the anterior side of the cavum and cymba conchae, followed by dissection on the supraperichondrial posterior side. After incision of the cartilage lateral to the ear canal, leaving a 3mm strip to avoid stenosis of the meatus acusticus externus and the radix helicis intact the entire piece of cartilage is removed and put into saline solution. (Fig 53)

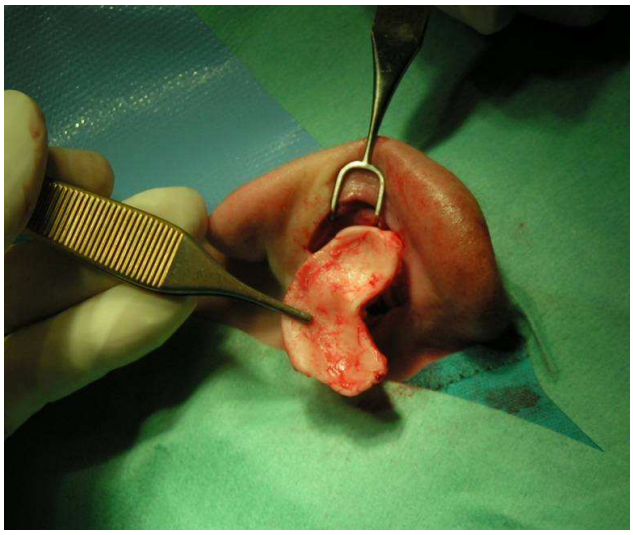

Fig 53: The removed conchal cartilage

After meticulous hemostasis, the skin incision is closed with 5/0 atraumatic suture in single stitches. Carefully applied conchal packing with through and through mattress sutures for 4 days will prevent hematoma.

The approach to the septum, as usual, is carried out with a Columella incision. After dissecting the remaining septum structures of Mucoperichondrium and Mucoperiosteum the Septum cartilage is removed in toto (Fig 54).

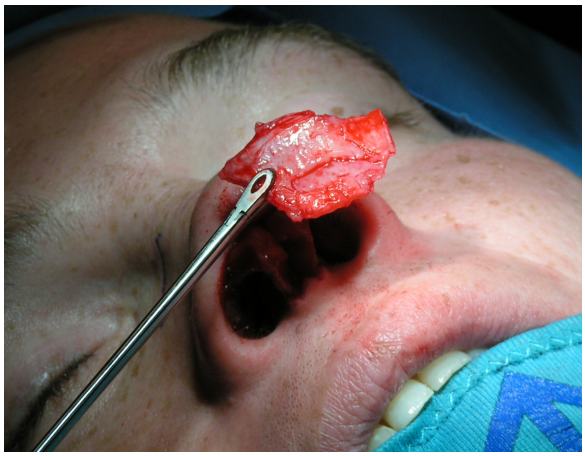

Fig 54: The remnant of septal cartilage is removed

Possibly existing deviations in the septum's osseous area or the nasal bone are straightened. To produce a Compound graft one first has to assess the approximate size of the graft needed, using PDS foil and placing it between the mucoperichondrial sheets of the nose (Fig 55 a and b)

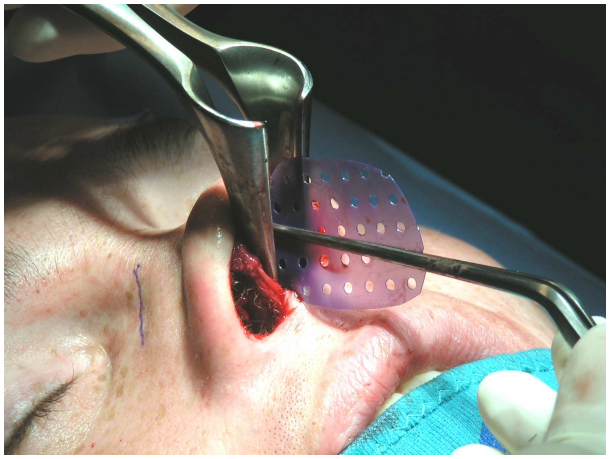

Fig 55 a: To assess the approximate size-

Fig 55 b: the PDS-foil is placed between the mucoperichondrial sheets

With the help of the foil, the existing septum cartilage and the harvested auricular cartilage are arranged in a way that the largest and most stable cartilage fragments are located along the dorsal and caudal borders. Subsequent to this the cartilage parts are fixed to the foil with PDS sutures and then reimplanted and fixed into the nose, as usual (Fig 56-57).

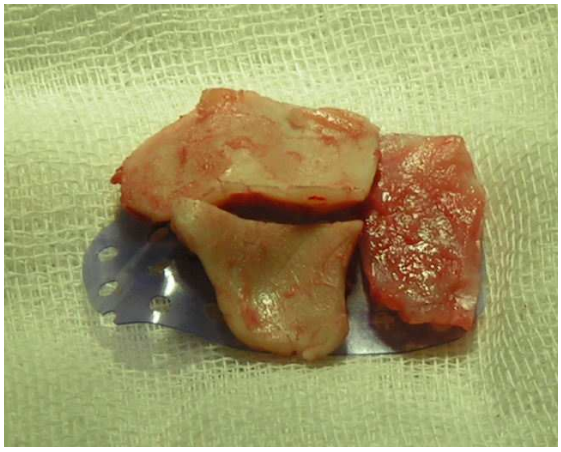

Fig 56: The cartilage is arranged upon the PDS foil

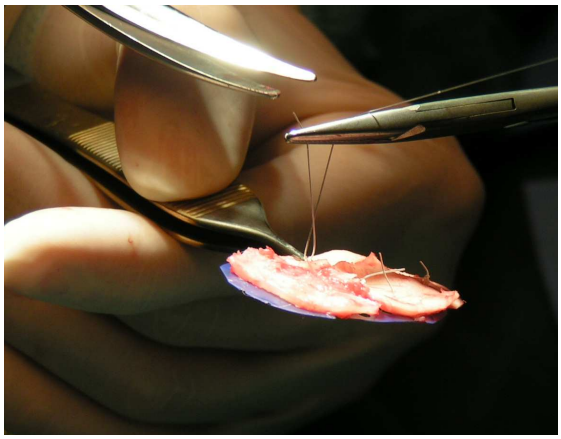

Fig 57: The cartilage fragments are sutured to the PDS foil

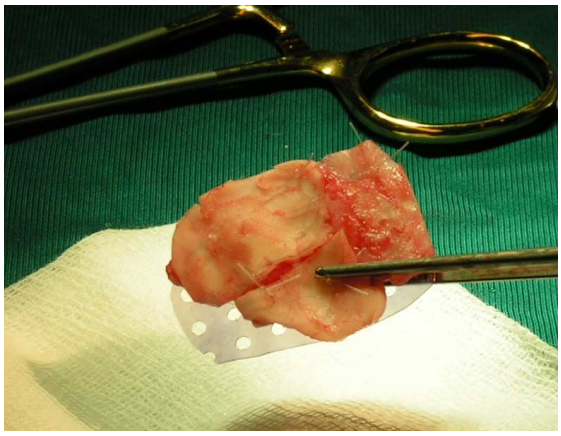

Fig: 58:The finished graft with septum and conchal cartilage

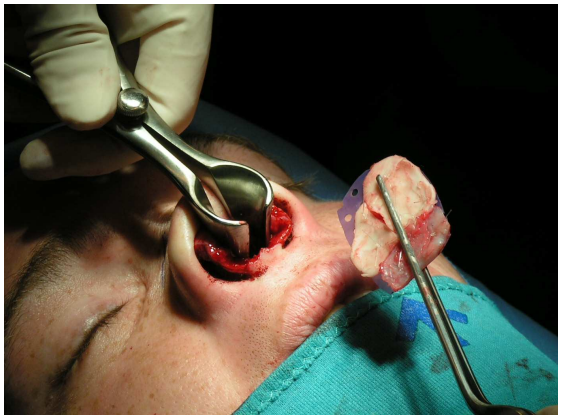

Fig 59:The graft is reimplantated

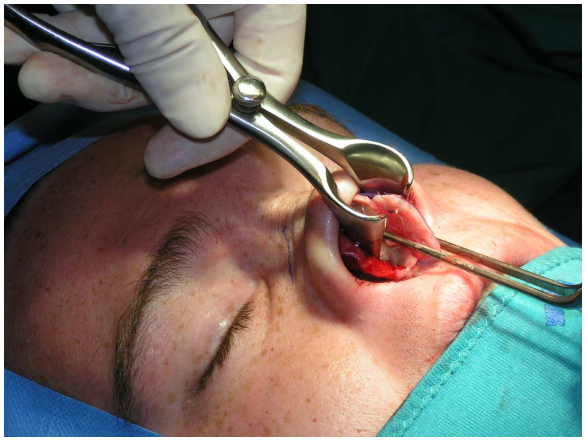

Fig 60: The reimplanted septal graft is adjusted to the right position

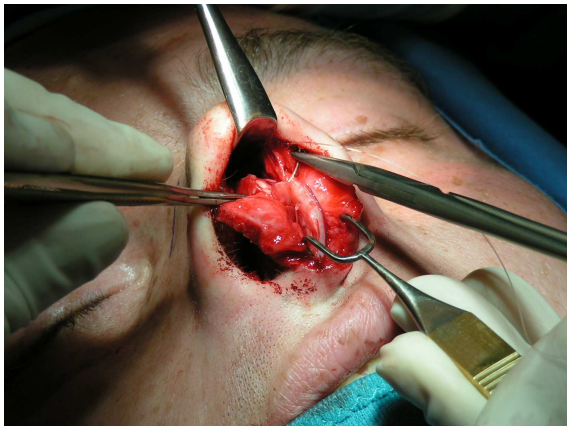

Fig 61: The graft is fixed with sutures to the upper lateral cartilages

5.4.2.2. Complete septum reconstruction with bilateral auricular cartilage

By way of using the PDS foil even septum cartilage gone entirely amiss (e.g. after septum abscessus) can be recuperated as a straight and stable septum with the help of auricular cartilage; although it is generally not adequate for septum reconstruction –the auricular cartilage is cambered and not as stable as septum cartilage. The PDS foil retains the auricular cartilage until sufficient stability is gained by tissular healing, in order to ensure that the septum remains straight after foil resorption. Therefore a reconstruction of pronounced saddle noses using auricular cartilage alone is feasible. The great advantage of this solution for the patient is the missing thoracal scar and there is no risk for pneumothorax. For the surgeon it is an advantage to keep surgery in one region of the body and there is no need for extra instruments. At the beginning of the surgery the auricular conchal cartilage is extracted from both auricles according to the above described procedure, one part of the cartilage serves to reconstruct the cartilaginous septum with the help of the PDS foil, whereas the other part is basis for building up an on-lay graft to obtain a nose bridge and Columella strut to stabilise the tip of the nose.

5.4.2.3. Closure of a septum perforation using compound graft

Septum perforations of a diameter of up to 2 cm can be occluded trouble-free with the help of a compound graft. For that purpose conchal cartilage is generally combined with septum cartilage.

Typically in patients with septal perforation is the loss of tip support due to diminished stability of the quadrangular cartilage (Fig 62). Therefore it is also necessary to rebuild tip support usually not only with the reconstructed septum but also with a strong columella strut.

Fig 62: typical loss of tip support, due to diminished stability of the cartilaginous septum

Starting from an external aditus the entire cartilaginous septum, as well as the anterior osseous sections are dissected (Fig 63).

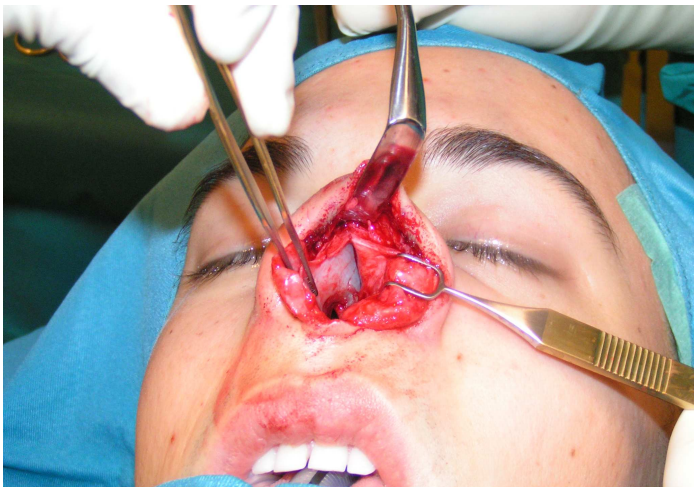

Fig 63:The entire septal cartilage is dissected free

The still remaining cartilaginous septum is removed in toto. (Fig 64)

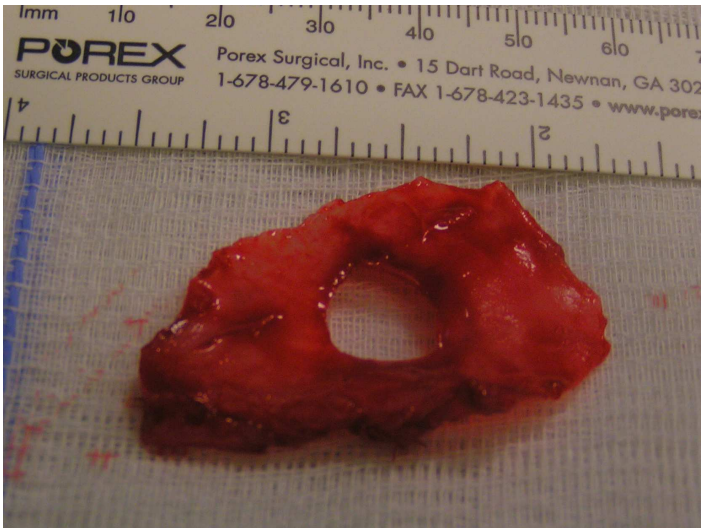

Fig 64: The septal cartilage is removed in toto

After an extensive bilateral elevation of the mucosa from the nasal dome and the nasal floor bipedicled advancement flaps are created Schultz-Coulon (2005).

The mucosal defects are sutured, as described. After that septum cartilage, the auricular cartilage removed prior and the PDS foil are used to produce a compound graft. It is of special importance to heed that there is a stable piece of cartilage in the area of dorsal and caudal border and of the previous perforation alike.

Besides, as documented in Fig 65, mostly an extra support of the nasal tip is required, which is created from the cartilage of the posterior septum. Therefore the posterior part of the septal cartilage is resected. The thus constructed compound graft is reimplanted and as usually retained with sutures along lateral cartilage and periosteum of the nasal spine. Subsequent to that the mucosa is reclined and retained through mattress sutures. Nasal packing is not necessary.

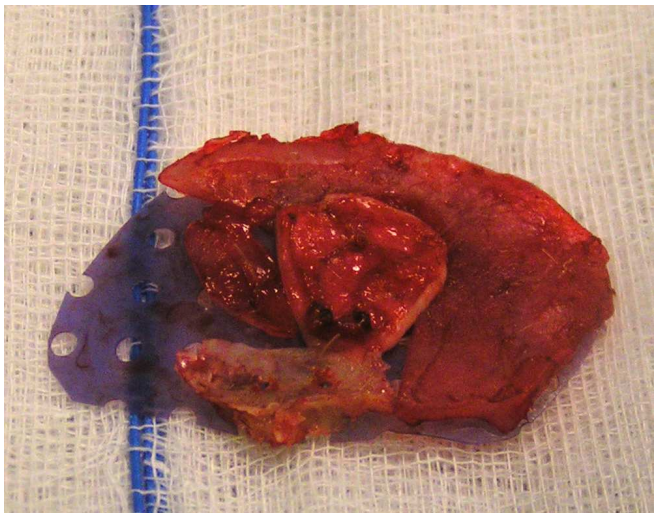

Fig 65: The compound graft consisting of septal cartilage and conchal cartilage

Fig 66: The nose at the end of the surgery with strong tip support

5.3.3. Clinical Results

For evaluation of the results we used a patients report, pre- and postoperative photographs and anterior rhinoscopy within the scope of follow up examinations 2days, 1,3, and 8 weeks, 6 months and afterwards once a year postoperatively. Concerning the reported patients the average follow-up period amounts 12 months (longest follow- up 10 years).

Up to now 396 patients have been operated using the septal reconstruction with compound graft. 217 male and 179 female patients, from 17 to 61 years of age. 380 (96%) of the patients came to the first four of the postoperative follow up examinations, 285 (72%) came to the 6 month follow up and 257 (65%) came to the late follow up examinations.
No immediate complications such as haematoma or inflammatory response or necrosis occurred. Postoperative crusts disappeared in nearly every case after two weeks. Only in 2 cases they lasted 2 weeks longer.

19 (5%) of the patients postoperatively had a slight thickening of the septum for about three weeks, which disappeared completely during the following 2 months.
A postoperative straight septum was achieved in 87% (344) cases. In 19 patients (5%) a secondary revision surgery has been performed, to correct either redeviation or slight polly beak deformity. In 8% (31) patients the redeviation did not cause functional problems or patients did not want revision surgery.

93% of the patients related to an improvement of the nasal airway after surgery. To confirm this results objectively we performed a postoperative control rhinomanometry usually 2 months after surgery. The results showed in 82% (324) patients remarkably improvement of the nasal flow, as shown in the example of one patient (Fig 73 a,b).

One patient operated because of a posttraumatic saddle nose deformity, had a nasal trauma 4 weeks after surgery which resulted in a recurrent saddle deformity after 5 months, after resorption of the foil. A revision surgery has been performed 7 months after the first surgery, using the compound graft in connection with auricular conchal cartilage, and after the second surgery the nose healed well. There was no septal perforation even after intraoperative tearing of the mucosa. We have never seen a rejection of the foil.

Even with severe preoperative nasal deformities, the cosmetical results were satisfying.

27 patients aged 17 to 65, 16 female and 11 male have been operated to date with the compound graft in connection with auricular cartilage. The follow up period ranges from 4 months to 4 years. There was no immediate complication like haematoma or infection. The long term result was good 24 patients, in 3 patients a slight saddle deformity occurred, which has been corrected using conchal cartilage from the other ear as dorsal onlay graft.

6 patients with septal perforations have been operated to date with the compound graft. The diameter of the perforations was between 8mm and 2cm. The first operation was 8 years the last 3 months ago. One perforation (2cm) reoccurred, all the other have been closed successfully.

The following pictures show some typical cases:
Case 1:
21 year old man with slight saddle nose after nasal trauma one year ago. Fig 67 a and b shows the pre and postoperative frontal view. Fig 68 and 69a show the pre - and Fig 68 and 69b the postoperative endoscopic views, demonstrating the posttraumatic septal deformity with high deviation in the right nasal cavity and complete blockage in the left nasal cavity. Correction was performed using the extracorporal septal reconstruction with the compound graft, osteotomies and tip sculpturing.

Fig 67 a and b: pre (a) and postop(b) view after septal reconstruction with the compound graft

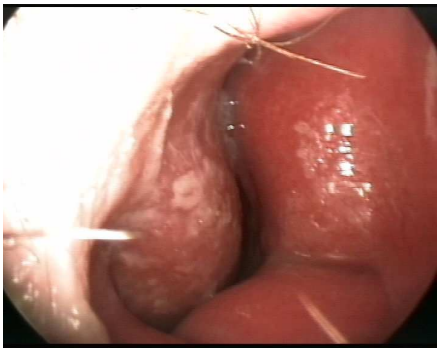

Fig 67a: right endoscopic view pre-operative

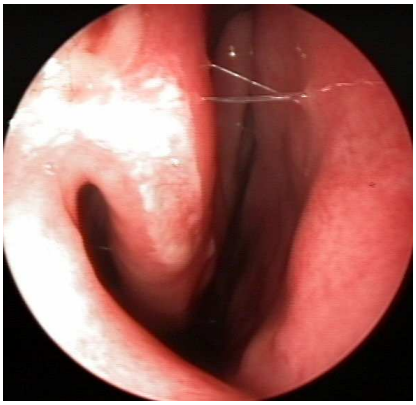

Fig 67b: right endoscopic view 2 months postoperative

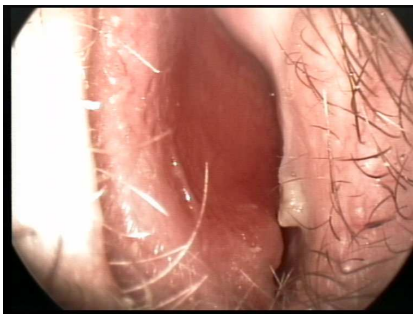

Fig 68a: left endoscopic view pre-operative

Fig 68b : left endoscopic view 2 months postoperative

Case 2:

Pre (69-72a) - and postoperative (69-72b) views of a 26 years young lady presenting a severe posttraumatic deformity with deviation of the nose towards the left side, pseudohump and slight saddle deformity. Corrected by external septoplasty with compound graft. The Fig 73 a and b show the Rhinomanometry pre- and 2 months postop.

Fig 69 a, b: frontal view pre- and 6 months postoperatively

Fig 70 a, b: oblique view pre- and 6 months postoperatively

Fig 71 a ,b: lateral view pre- and 6 months postoperatively

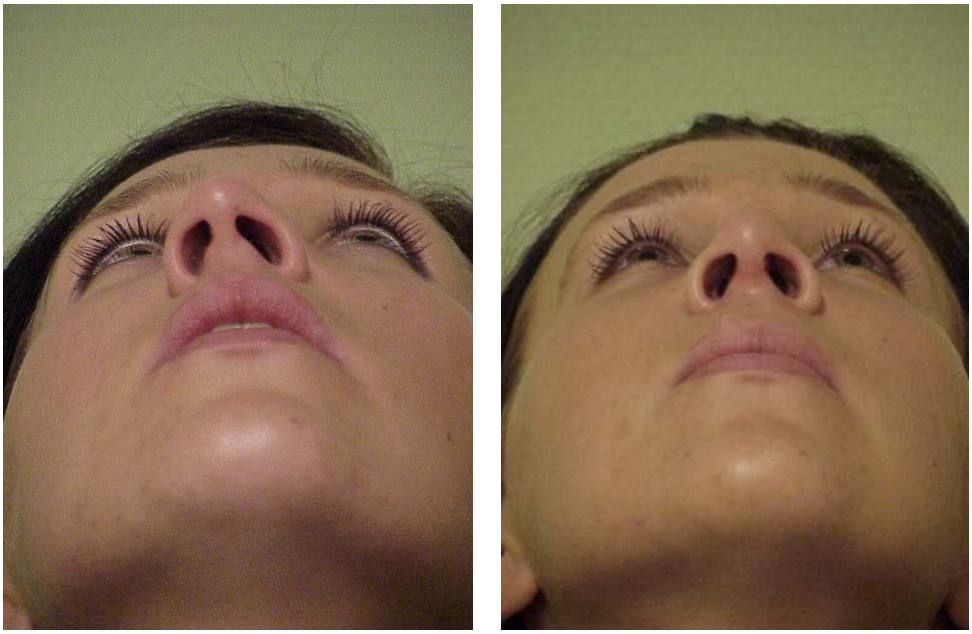

Fig 72 a, b: pre- and 6 months postoperative basal view

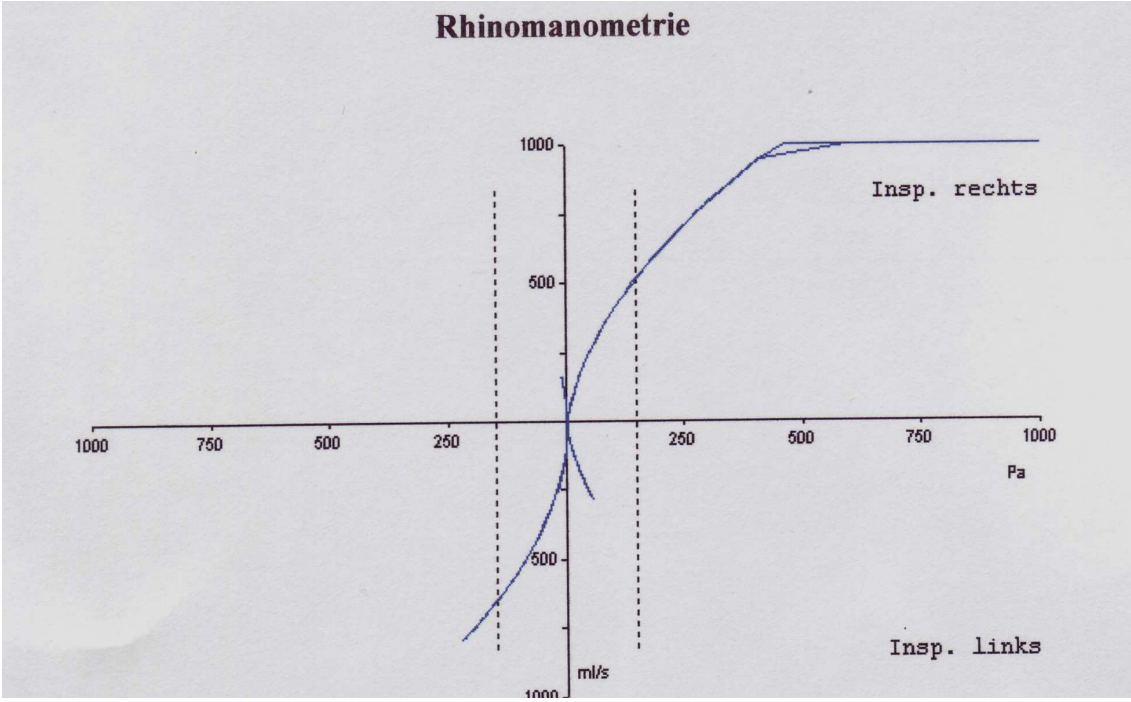

Fig 73 a: preoperative Rhinomanometry demonstrating the complete blockage on the left side

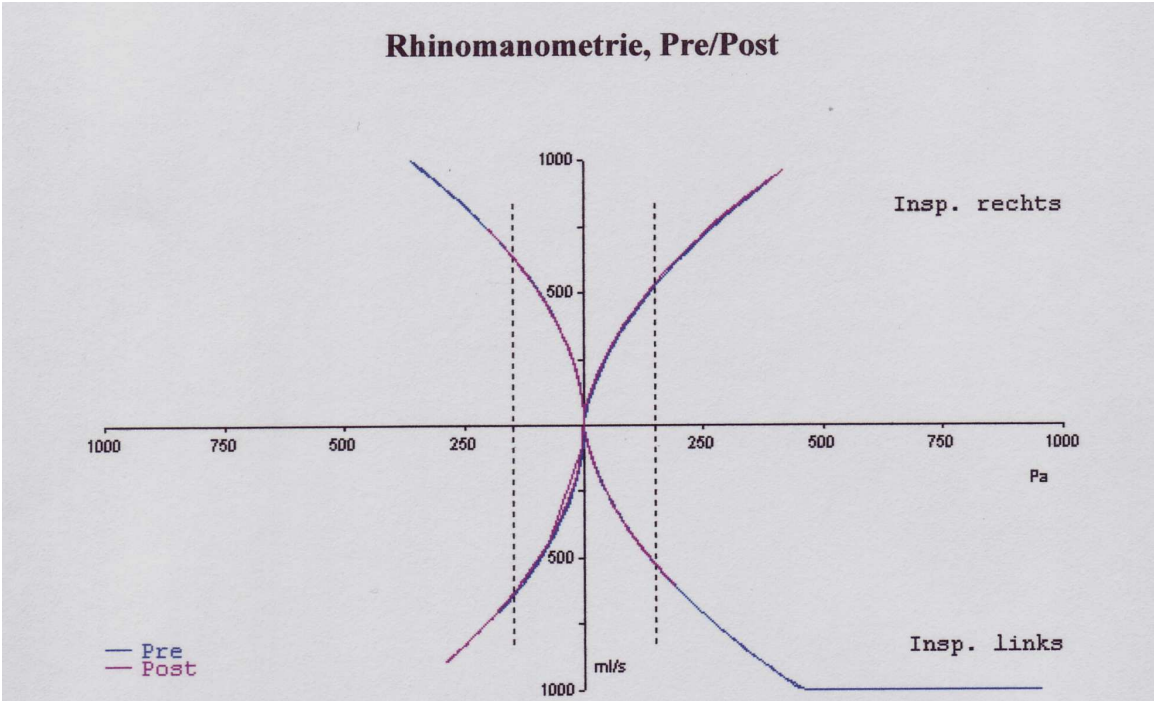

Fig73 b: postoperative Rhinomanometry showing symmetrical flow

Case 3:

Pre (74-77 a) - and postoperative(74-77 b, c) views of a 46 year old patient with nasal deformity after 4 nasal traumas, leading to a complete blockage of the right nasal cavity after septum fracture and a C- shaped deviation of the entire nose towards the right. Corrected with septal reconstruction using compound graft. The first postoperative pictures are taken 6 months after surgery and the second ones 8 years after surgery. They clearly demonstrate the long-lasting, stable result even years after surgery.

Fig74 a ,b ,c pre-, 6 months and 8 years postop. view

Fig 75 a, b, c: pre-, 6 months and 8 years postop oblique view

Fig 76 a, b, c: pre-, 6 months and 8 years postop lateral view

Fig 77 a, b, c: pre-, 6 months and 8 years postop basal view

Case 5:

Pre (78-81 a) - and postoperative (78-81 b, c) views of a young man with severe saddle nose due to a septal abscess after nasal trauma one year ago. The septal abscess had destroyed the entire septal cartilage. The nose was reconstructed with auricular conchal cartilages of both ears; one cartilage has been used as compound graft to reconstruct the septum, the second one as dorsal on-lay graft and columella strut to restore tip support.

The first series of postop pictures has been taken 6 days after surgery, immediately after removing the external dressing. It shows that there is no increased swelling or bruising after using the compound graft, compared to any other techniques. The second series is taken 6 months after surgery, after the resorption of the PDS foil has been finished.

Fig 78 a,b,c: pre-, 6 days and 6 months postop frontal view

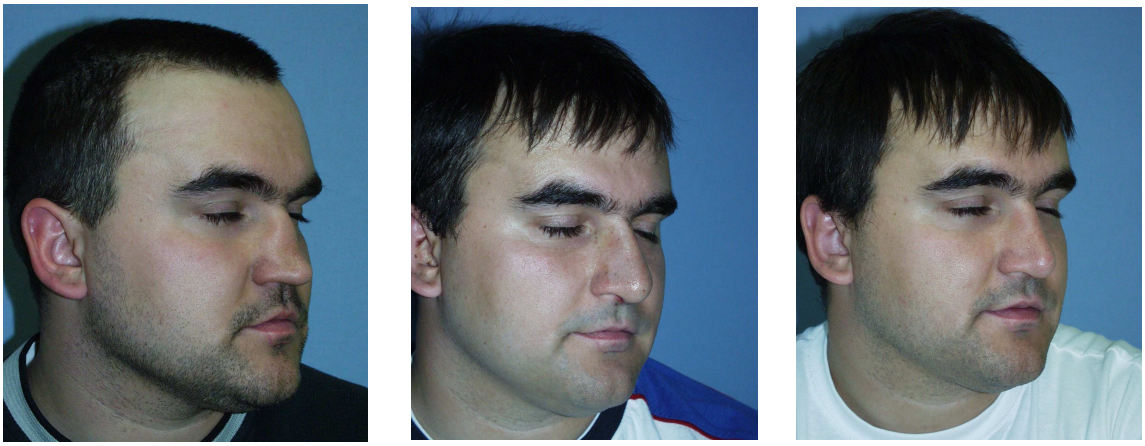

Fig 79 a, b, c: pre-, 6 days and 6 months postop oblique view

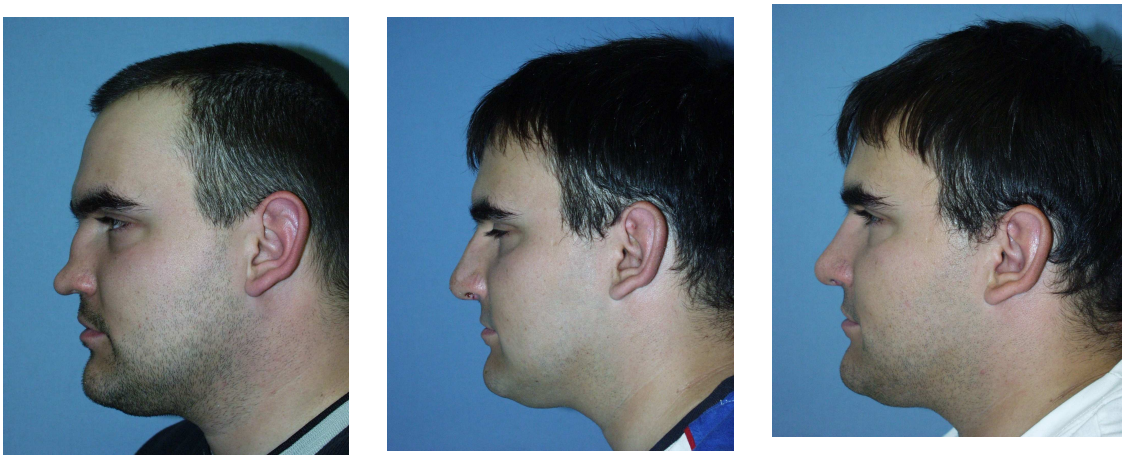

Fig 80 a, b, c: pre- 6 days and 6 months postop lateral view

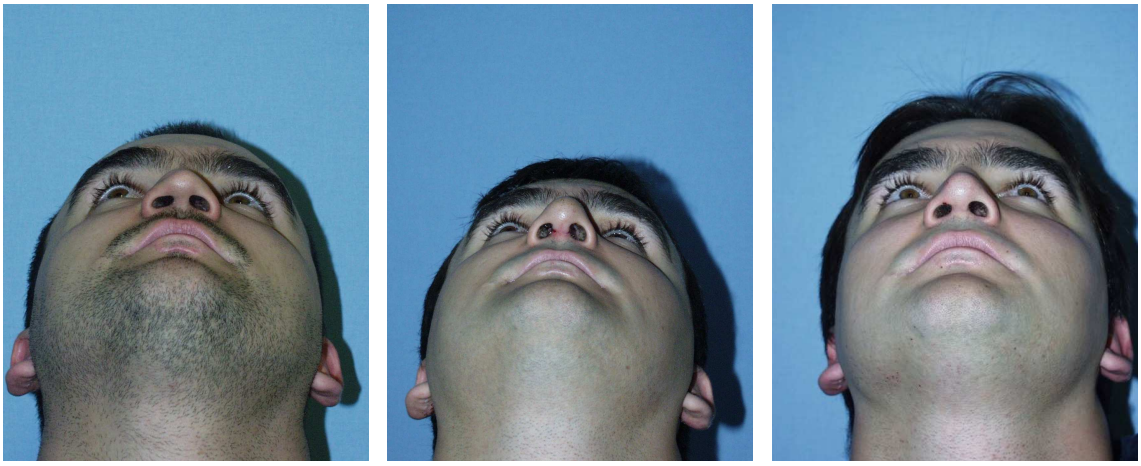

Fig 81 a, b, c: pre-, 6 days and 6 months postop basal view

Case 6

Pre (82-85 a) - and postoperative (82- 85 b, c) view of a man 36 year old man with septal perforation of 1cm diameter and complete loss of tip support due to diminished stability of the septal cartilage. He had had a nasal trauma several years ago. Surgery has been performed from an open approach with a V- columella incision, to perform a V-Y procedure to lengthen the columella in order to correct the severe retraction. The closure of the perforation has been successful.

Fig 82 a, b: pre- and postop frontal view closure of septal perforation with compound graft

Fig 83 a, b: pre and postop oblique view

Fig 84 a, b: pre- and postop lateral view

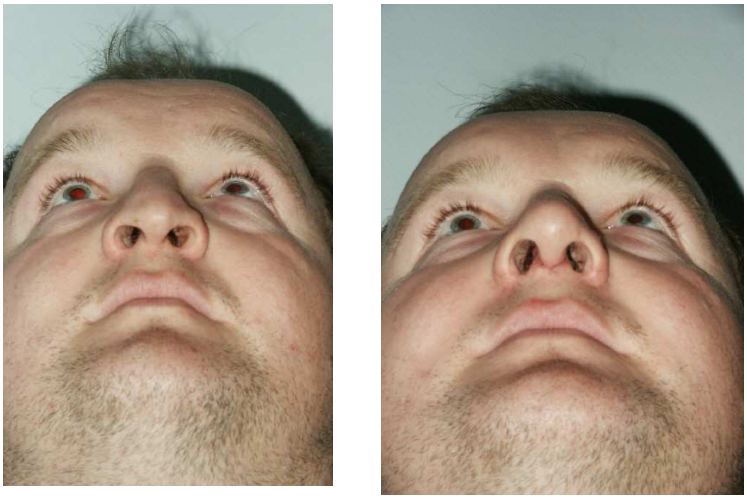

Fig 85 a, b: pre- and postop basal view

The final two series of pictures show my first and my last case since I started using the compound graft.

Case 6:

The first case, pre (86-89 a) and postop (86– 89b) pictures of a 24 years old man, presenting a posttraumatic deformity with deviation of the entire cartilaginous nose towards the right and, as can be seen on the basal view a difficult septum with deviation in all areas.

I did an extra corporal septoplasty as described above and reconstructed the septum with the compound graft. Furthermore, osteotomies, tip sculpturing and columella strut.

Fig 86: pre- and postop frontal view

Fig 87: pre- and postop oblique view

Fig88: pre- and postop lateral view

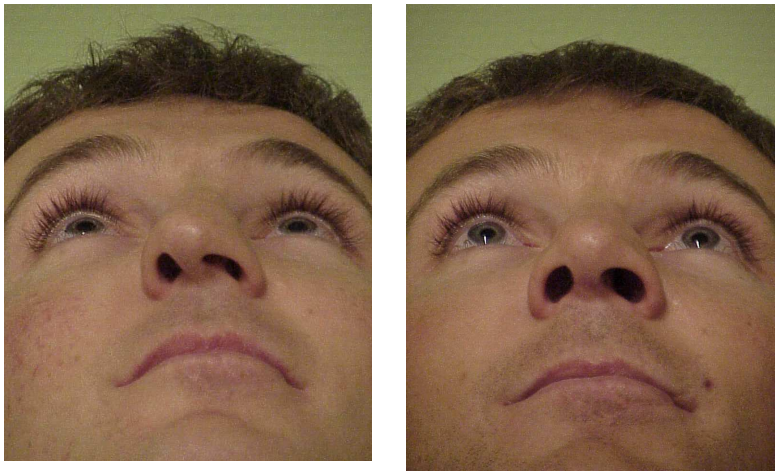

Fig 89: pre-and postop basal view

Case 6

Pre(90-93a) and postop (90-93b) pictures of a 29 year old patient with an iatrogenic deformity after rhinoplasty elsewhere 2 years ago, presenting a crooked nose with deviation to the right, breathing problems and an overresection of a bony hump. Corrected with septal reconstruction with compound graft and cartilaginous dorsal onlay graft and osteotomies.

The postoperative pictures are taken only 6 days after surgery after removement of the external dressing.

Fig 90 a, b: Pre- and postop frontal view after septal reconstruction with PDS

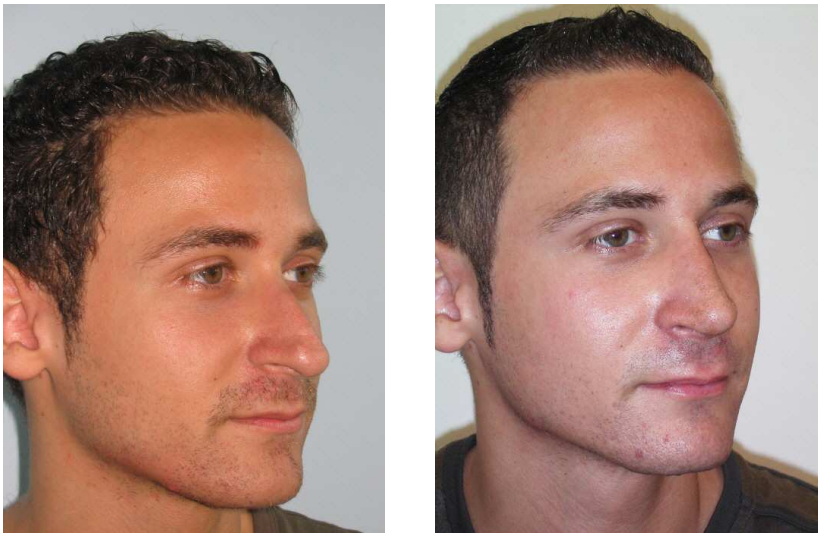

Fig 91 a, b: Pre and postop oblique view after septal reconstruction with PDS

Fig 92 a, b: pre- and postop lateral view after septal reconstruction with PDS and cartilaginous onlay graft

Fig 93 a, b: pre- and postop basal view

6. Final conclusions and clinical relevance

Surgical correction of a deviated nasal septum is one of the most frequently performed surgical procedures. Different ethnic groups are affected differently by septal deviations; basically, the highest incidence can be found among Caucasians. Statistics from North America and Europe vary however they show an average rate of nasal septal surgery of 1.2 /1000 people.

90 % of these septal surgery procedures are routine, whereas the other 10% -usually combined functional-aesthetic deformities- require rather complex correction. External or extracorporal septoplasty seems to be a viable solution for the above mentioned 10%. External septoplasty surgery is recommended by several authors (Rees 1986, Gubisch 1988, Hellmich 1997) to correct severe, especially posttraumatic deformities of the nasal septum.
The extracorporal reconstruction of the nasal septum however, is not only very time consuming, but techniqually very demanding and therefore usually done only by specialists. Even in their hands there might be a risk of overlapping of the cartilage fragments leading to postoperative saddle deformity.

The utilization of the resorbable PDS foil facilitates this surgical technique immediately. While doing so the trimmed septal cartilage fragments are sutured to the resorbable PDS foil, thus creating a stable and straight free graft, which can easily be reimplanted into the nose. The foil fixes the cartilage fragments, thereby supporting the nasal dorsum until the healing process stabilizes the cartilage. Afterwards the foil is completely resorbed, excluding long term complications of other artificial implants.

The general biological properties of Polydioxanone (PDS) have been examined in numerous studies in combination of the implant with bone (Hollinger 1986, Merten 1994). They proofed, that the degradation products of the synthetic aliphatic polymer did not interfere with the normal healing process at all, but stimulated the regeneration of bone as osteoconductive properties.

Regarding our animal studies, we were able to examine the histological background of the healing process of an artificial cartilage defect in combination of the PDS foil. Up to the 10th week after the implantation the foil remained untouched from degradation and the continuing form stability enabled the desired supporting function. If the foil was implanted subperichondrial directly covering the cartilage thin reactive tissue, forming a pseudo capsule

quickly occurred, preventing necrosis of the underlying cartilage as reported after implantation of some non resorbable implants. Additionally this thin tissue layer ensures nutrition of the chondrocyts. Obviously new formed cartilage developed of in the area of the artificial cartilage defects. The degradation products resulting from the resorption and metabolisation of the Polydioxanone, had no bad effect on the regeneration process of the cartilage, as known from other artificial implants. It even provides a guarding support of the cartilage regeneration, similar to the osteoconductive properties. During the resorption procedure tissue reaction remained strictly in the area of the implant, which can account for the lack of reaction of the septal mucosa after septal surgery using the PDS foil. Besides, tissue reaction disappears completely after closure of the resorption procedure, thus excluding unilateral scarring, which can lead to postoperative deformation and bending of the septal cartilage, as well as persistent postoperative thickening of the septum.

Alloplastic implants are generally used for their mechanical stability as supporting material, which is also useful for the combination of cartilage and resorbable PDS foil. Besides, implants are only necessary as long as the healing process of the supporting tissue takes, afterwards they have to be removed, to avoid long-term complications. This can easily be evaded, using resorbable implants, which are completely eliminated after a limited period.
The combination of septal cartilage with a resorbable Polydioxanone foil therefore enables a combination of the technical advantages during the operation and the healing process with the advantages of a resorbable implant.

The good results of the histological examination have been verified undoubtedly by the good clinical experiences.Up to now, we have used this technique in 397 cases. Starting from the original utilisation, the technique has been further developed, in using the PDS foil in combination with conchal ear cartilage. This turned out to be a great advantage, because only with this combination it is possible to create a stable cartilaginous septum with only with conchal cartilage. Therefore the harvesting of rib cartilage is not absolutely necessary.

We have never to date seen an acute or chronic complication as a consequence of the usage of PDS foil. We have never seen allergic reactions or rejection of the foil either. There was no local necrosis or infection. The compound graft proved to be stable enough to support the cartilaginous part of the nose. The only postoperative saddle nose did not occur due to the instability of the compound graft, but because of postoperative nasal trauma.
The cosmetic results happened to be convincing and stable, even years after surgery these remain satisfying.

The fundamental surgical goal, creating a straight nasal septum could be achieved in about 87% of the cases. With regard to the improvement of nasal breathing the success rate was even higher from a patient's viewpoint, also supported by rhinomanometry.

With further development of the technique and more routine we were able to decrease the inconveniences for the patients in postoperative time. Due to special suture techniques we could forgo any postoperative nasal packing. For three years 95 % of all cases have been operated in day care surgery without any negative consequences.

The utilisation of PDS foil during septal surgery seems to be an applicable method to facilitate external septal surgery, to correct several combined nasal deformities such as posttraumatic and iatrogenic irregularities and it helps to avoid postoperative saddle deformities with certainty, with no risk whatsoever for the patient.

References

- Bönisch M, Mink A. Septal Reconstruction with a Polydioxanone Plate (PDS) FACE 1999; 6: 149-154
- Bönisch M, Nolst Trenité GJ. New concepts in reconstructive septoplasty. Rhinoplasty 3rd edition, 2005 Kugler Publications, The Hague Netherlands, Chapter 25:257-84
- Bönisch M, Nolst Trenité GJ. Fibrinkleber bei Septumplastik. HNO 2004;52:963-967
- Bönisch M, Nolst Trenité GJ. Reconstructive Septal Surgery. Facial Plast Surg 2006;22:251-56
- Bönisch M, Hajas T, Nolst Trenitè GJ. Histologic findings on operated growing septal cartilage with and without PDS-foil in an animal model. Course book of the „International Symposium on Functional – Aesthetic Nasal Reconstruction. October 2001, Amsterdam
- Bönisch M, Hajas T, Nolst Trenité GJ. Influence of Polydioxanone Foil on Growing Septal Cartilage After Surgery in an Animal Model. New Aspects of Cartilage Healing and Regeneration. Arch Facial Plast Surg 2003; 5: 316-319
- Bönisch M, MinkA. Myringoplastik mit „Underlay Technik“ und „Pull-back“. Eine sichere Methode zum Verschluss anteriorer Trommelfellperforationen. Otorhinolaryngologia Nova 1997; 7: 230–234
- Bönisch M, Mink A. Az orrsövény rekonstruktioja Compound Grafttal. *Fül-Orr-Gégegyógyászat* 1999; 45: 20-24
- Bönisch M, Mink A. Clinical and Histogical Results of Septoplasty With a Resorbable Implant. Archives of Otolaryngology-Head &Neck Surgery 2000; 126: 1373-1377
- Bönisch M, Mink A. Comment article: Septoplasty with resorbable implant. Current Medical Literature, Ear, Nose and Throat 2002; 3: 1-3
- Bönisch M, Mink A. Heilungsprozess des Knorpels mit PDS Folie. HNO 2000; 48: 743-746
- Bönisch M, Mink A. Septumrekonstruktion mit PDS-Folie. HNO 1999; 47: 546-550
- Bönisch M. Fibrinklebung bei Septumplastik. Ellipse 2002; 18: 69-72
- Carpue J.C. An account of two succesful operations for restoring the lost nose from integuments of the forehead. London 1816
- Chaban. Simulated Septal Deviaitons. Arch. Otolaryng. 1988;114
- Clark G, M. The Role of the Nasal Septum in One-Stage Rhinoplasty. Arch. Otolaryng., 1967;85:418-423

- Cole. The Obstructive Nasal Septum. Arch. Otolaryng. 1988;114:410-412
- Cottle M H. Modified Nasal Septum Operations. The Eye, Ear, Nose and Throat Monthly 29 (1950) 9: 480-84
- Cottle M.H. Modified Nasal Septum Operations. The Eye, Ear, Nose and Throat Monthly, 1950; 24:480-484
- Dieffenbach. Chirurgische Erfahrungen in der Wiederanheilung zerstörter Teile, Berlin 1834.
- Drettner B. The effect of infrared rays and short wave diathermy on the nasal mucosa. Acta Oto-Laryng. 1963;56:643-654
- Eccles RB. The nasal cycle in respiratory defence. Acta Otorhinololaryngol Belg 2000; 54:281-286
- Ey W. Fehler und Gefahren bei operativer Behandlung anatomischer und funktioneller Veränderungen am vorderen Septum. Laryngol-Rhino-Otol. 1969; 48:38-43
- Flottes L et al. Importance du cycle nasal dans l'appréciation de l'action des drogues vasomotrices. J. franc Oto-Rhinno-Laryng. 1961;10:417-430
- Freer O. T. The correction of deflections of the nasal septum with minimal traumatism. J. Amer. Med. Ass. 38 (1902) 636-42
- Freud Siegmund: Ueber Coca. Centralbl. F. ges. Therapie 2 (1884) Juli
- Frohn K. Die Septumresektion nach Killian aus neuer Sicht. Laryng-Rhinol-Otol. 1968;47:747-749
- Fry H. Nasal skeletal trauma and the interlocked stresses of the nasal septal cartilage.Brit. J. Plast. Surg. 1967;20:146
- Goldmann I.B. New Technique in Surgery of the Deviated Nasal Septum: Arch. Otolaryng. 1956;64:183-189
- Goodmann WS. External Approach to Rhinoplasty. J. Otolaryngol 2 (1973) 1: 3207-210
- Graefe C.F. Rhinoplastik oder die Kunst die Nase organisch zu ersetzen. Mit 6 Kupfertafeln. Berlin 1818,4.
- Gubisch W. Neue Techniken zur Korrektur des schwierigen Septums.Laryng- Rhinol-Otol.1992;71:39-42
- Gubisch. W. Das schwierige Septum. HNO 1988;36:286-289
- Hardie. A new rhinoplastic operation. The Brit. Med. Journ. Sept. 25, 1875
- Heetderks DR. Observations on the reaction of normal nasal mucous membrane. Amer. J. med. Sci. 1927;174:231-244
- Hellmich S. Septumplastik. Laryngorhinootol 1997;76:663-666
- Hellmich S. The problem of cartilage bending in nose surgery. HNO 1973;21:223-6

- Hircarrha. Gazette de Madras. 1793
- Hollinger J.O, Battistone G. Biodegradable bone repair materials. Clin Orthop. 1986;207:290-305
- Holmes Th H. et al. The nose. An experimental study of reactions within the nose in human subjects during varying life experiences. Thomas, Springfield 1950;154pp
- Ingals E.F. Deflections of the nasal septum. Arch. Laryngol. (N.Y.)3 (1882)291-99
- Jones A.S. The external approach for rhinoplasty and septoplasty. Clin. Otolaryngol. 1991;16:97-99
- Joseph J. Erster Fall der intranasalen Korrektur der Sattelnase, Berl. Klin. Wochenschr. 1907, Nr. 16
- Joseph. J. Nasenplastik und sonstige Gesichtsplastik nebst Mammaplastik. Verlag Curt Kabitzsch. Leipzig 1931
- Jugo S.B. Total septal reconstruction through decortication (external) approach in children. Arch Otolaryngol. 1987;113:173-178
- Kastenbauer E. Was hat sich in der ästhetischen und funktionellen korrektiven Nasenchirurgie geändert? Laryng- Rhinol- Otolaryngol. 1989;68:4-11
- KayserR. Die exacte Messung der Luftdurchgängigkeit der Nase. Arch Larygol Rhinol 1894; 3: 101-120
- Killian G. Die submuköse Fensterresektion der Nasenscheidewand. Arch. Laryng. Rhinol. Berlin 16 (1904) 362-87
- Körner F. Über Drosselvenen im Schwellgewebe der Nasenschleimhaut. Z. Anat. Entwickl. Gesch. 1937;41:131
- Krmpotic-Nemanic J. Hals-Nasen-Ohren- Heilkunde in Praxis und Klinik, Entwicklungsgeschichte und Anatomie der Nase und der Nasennebenhöhlen 1-36, Thieme Verlag Stuttgart, 1977
- Lamont E.S. Plastic surgery of the septum in conjunction with Rhino-osteoplasty. Arch Otolaryngol. 1948;48:536-551
- Lang C, Grutzenmacher S, Mlynski B. Investigating the nasal cycle using endoscopy, rhinoresistometry, and acoustic rhinometry. Laryngoscope 2003; 113: 284-289
- Lang J. Über das postnatale Wachstum der Außennase. Gegenb. Morph. Jahrb. 1987; 133: 5-32
- Langenbeck. Deutsche Klinik 1859, Nr.48
- Lillie H. Some practical considerations of the physiology of the upper respiratory trct. J. Iowa med. Soc. 1923;13:403
- Mangat D.S. Septoplasty via the external approach . Facial Plast. Surg. 1988; 5: 161-166
- Masing , H. Patho-physiology of the nasal airflow. Int. Rhinology 1967; 5: 63-67

- Masing, H. Klinisch-anatomische Bemerkungen zur Cartilago septi nasi. Laryngologie Rhinologie Otologie 1964; 43:604-612
- Masing,H. Nasenkorrektur und Atmungsfunktion. Laryngologie Rhinologie Otologie 1968;47: 277-288
- Merten HA, Luhr HG. Resorbierbare PDS Folien zur Orbitadefektüberbrückung im tierexperimentellen Vergleich. Dtsch Z Mund-Kiefer- und Gesichtschir 1994;18:100-104
- Meyer R. Funktionelle plastische Chirurgie der Nase. Laryng- Rhinol- Otol.1983;62:179-184
- Mlynski G. Physiology and pathophysilogy of nasal breathing. In: Behrbohm H, Tardy ME, eds. Essentials of Septorhinoplasty. New York, NY: Thieme; 2004
- Nolst Trenité GJ, VerwoerdCDA, Verwoerd-Verhoef HL. Reimplantation of autologous septal cartilage in the growing nasal septum Rhinology 1988;26:25-32
- Nolst Trenité GJ. Implantaten in een groeiend neustussenschot. Swets&Zeitlinger, Amsterdam 1984:99-107
- Nolst Trenité GJ. Rhinoplasty. A practical guide to functional and aesthetic surgery of the nose. 3rd Edition, Kugler Publications, The Hague, The Netherlands 2005. Part II pp.49-67
- Ogura JH, Stocksted P. Rhinomanometry in some rhinologic diseases. Laryngoscope 1958; 68: 2001-2014
- Ollier. Gazette des hopitaux. 19. November 1861, Nr. 135
- Pirsig W.: Septumdeviation 1882: Beginn der systematischen submukösen septumchirugie. Laryng. Rhinol. Otol. 61 (1982) 547-551
- Poublon R.M.L. The cartilaginous nasal dorsum and the postnatal growth of the nose, Eburon Publisher, Delft, The Netherlands, 1987
- Rees T.D. Surgical correction of the severely deviated nose by extramucosal excision of the osseocartilaginous septum and replacement as a free graft. Plast. Reconstr. Surgery 1986;78:320-330
- Rethi A. Raccourcisement du nez trop long. Rev. Chir. Plast. 2 (1934) 85 –106
- Roe J.O. Deformity Termed “Pug Nose” and its Correction by Simple Operation. Med Rec 31 (1887) 621-23
- Roe J.O. the Correction of Angular Deformity of the Nose by a Subcutaneous Operation. Med Rec 35 (1891) 57
- Schultz Coulon HJ. Three layer repair of nasoseptal defects. Otolaryngol Head Neck Surg 2005;132:213-218
- Semeleder: Die Rhinoskopie und ihr Werth für die ärztliche Praxis. Leipzig (1862)
- Sercer A Otorinolarygologija, BdII. Leksigogarfski Zavod, Zagrab 1965

- Sercer A. Current viewpoints on rhinoplasty.
  Arch Ohren Nasen Kehlkopfheilkunde 1962;180:352-77
- Sercer A. La decortication du nez et sa valeur pour la chirurgie cosmetique.
  Rev. Laryngol Otol Rhinol 3 (1967) pp
- Shiroiwa A. et al. Clinical studies on the micro-circulation of the nasal mucous membrane. Int. Rhinology 1966;4:63-66
- Stephan. Gourmelen. Chirurgicae artis libr. III Parisis 1580. 8. pag.72
- Stocksted P. Rhinometric measurements for determination of the nasal cycle.
  Acta Oto-Laryngol suppl. 1953;109:176-181
- Stocksted P. The physiologic cycle of the nose under normal and pathologic conditions. Acta Oto-Laryng. 1952;42:175-179
- Stocksted P., Nielsen JZ. Rhinomanometric measurements of the nasal passage.
  Ann. Otol. Rhinol. Laryng. (St. Louis) 1957;66:187-197
- Stoksted P. Measurements of resistance in the nose during respiration at rest.
  Acta Otolaryngol Suppl 1953; 109: 143-158
- Tagliacozzi. De chirurgia curtorum per institutionem. Venedig 1597
- Tardy Jr. M.E. Rhinoplasty the Art and the Science, Practical Surgical Anatomy 2-126; W.B. Saunders Company, 1997
- Tardy M, Eugene JR. The versatile cartilage autograft in reconstruction of the nose and face. Laryngoscope1985;95:523-533
- Van Loosen J. A cephalometric analysis of nasal septal growth.Clin. Otolaryngol. 1997;22:453-458
- Verwoerd CDA, Verwoerd-Verhoef HJ, Meeuwis CA et al.Wound healing of autologous implants in the nasal septal cartilage. ORL J. Otorhinolaryngol Relat Spec 1991;53:310-314
- Vuyk H.D. Aesthetic sequelae of septoplasty. Clin. Otolaryngol. 1997;22:226-232
- Wirth F. Die Korrekturen der vorderen Anteile des Septumknorpels zur Verbesserung der Nasenform und –atmung. Laryngol- Rhinol-Otol. 1958;37:674-690
- Wustrow E. Schwellkörper am Septum nasi. Z. Anat. Enwickl. Gesch. 1951;116:139
  Czermak Johann: Über den Kehlkopfspiegel.
  Wiener Medizinische Wochenschrift 8(1858) 196-198
- Wyklicky Helmut: Der Vater der endonasalen Chirurgie. Österr. Ärztezeitung. Sammlung der Titelblätter des Jahres 1975, Nr. 15/16
- Zuckerkandl E. Normale und pathologische Anatomie der Nasenhöhle.
  I. Bd. Braumüller, Wien 1882

Publications

1. **Bönisch**, Mink (Landeskrankenhaus Steyr, Austria): Myringoplastik mit „Underlay Technik“ und „Pull-back“. Eine sichere Methode zum Verschluss anteriorer Trommelfellperforationen. *Otorhinolaryngologia Nova* 1997; 7: 230–234
2. **Bönisch**, Mink(Landeskrankenhaus Steyr, Austria): Az orrsöveny rekonstruktioja Compound Grafttal. *Fül-Orr-Gégegygyaszat* 1999; 45: 20-24
3. **Bönisch**, Mink(Landeskrankenhaus Steyr, Austria): Septumrekonstruktion mit PDS-Folie. *HNO* 1999; 47: 546-550
4. **Bönisch**, Mink(Landeskrankenhaus Steyr, Austria): Septal Reconstruction with a Polydioxanone Plate (PDS) *FACE* 1999; 6: 149-154
5. **Bönisch**, Mink(Landeskrankenhaus Steyr, Austria): Clinical and Histogical Results of Septoplasty With a Resorbable Implant. *Archives of Otolaryngology-Head &Neck Surgery* 2000; 126: 1373-1377
6. **Bönisch**, Mink(Landeskrankenhaus Steyr, Austria): Heilungsprozess des Knorpels mit PDS Folie. *HNO* 2000; 48: 743-746
7. **Bönisch**(Landeskrankenhaus Steyr, Austria), Hajas (Fül-orr-gége Klinika Pécs), Nolst Trenitè(AMC Amsterdam): Histologic findings on operated growing septal cartilage with and without PDS-foil in an animal model. Course book of the „International Symposium on Functional –Aesthetic Nasal Reconstruction. October 2001, Amsterdam
8. **Bönisch**, Mink(Landeskrankenhaus Steyr, Austria): Comment article: Septoplasty with resorbable implant. *Current Medical Literature, Ear, Nose and Throat* 2002; 3: 1-3
9. **Bönisch**: Fibrinklebung bei Septumplastik. *Ellipse* 2002; 18: 69-72
10. **Bönisch**(Landeskrankenhaus Steyr, Austria), Hajas(Fül-orr-gége Klinika Pécs), Nolst Trenité(AMC Amsterdam): Influence of Polydioxanone Foil on Growing Septal Cartilage After Surgery in an Animal Model. New Aspects of Cartilage Healing and Regeneration. *Arch Facial Plast Surg* 2003; 5: 316-319
11. **Bönisch**(Diakonissenkrankenhaus Linz, Austria), Nolst Trenité(AMC Amsterdam): Fibrinkleber bei Septumplastik. *HNO* 2004;52:963-967
12. **Bönisch**(Diakonissenkrankenhaus Linz, Austria), Nolst Trenité(AMC Amsterdam): Reconstructive Septal Surgery. *Facial Plast Surg* 2006;22:251-56
13. **Bönisch**(Diakonissenkrankenhaus Linz), Nolst Trenité(AMC Amsterdam): New concepts in reconstructive septoplasty. *Rhinoplasty 3rd edition*, Kugler Publications, The Hague Netherlands, Chapter 25:257-84

Presentations

1. **Boenisch M**., Mink A., Myringoplastik mittels Underlay und Pull Back. Eine sichere Methode zum Verschluss anteriorer Trommelfellperforationen, 41. Österreichischer HNO Kongress Innsbruck, Austria, September 15-18, 1997
2. **Boenisch M**., Septal reconstruction with polydioxanone plate (PDS), Summer Meeting European Academy of Facial Plastic Surgery, Bonn, Germany, June 12-14, 1998
3. **Boenisch M**, Mink A Septumrekonstruktion mit PDS Folie , 42. Österreichischer HNO Kongress Baden/ Wien, Austria, September 16.- 19, 1998,
4. **Boenisch M**.: Healing process of cartilage in connection with PDS foil. A histological study of the compound graft, International Meeting of the European Academy of Facial Plastic Surgery, Barcelona, Spain, 6.-8. May 1999
5. **Boenisch M**, Mink A.: Resorbierbare PDS Folie in der Septumchirurgie, Österreichischer HNO Kongress, Rust am Neusiedlersee, Austria, September 15.-19,1999
6. **Boenisch M**., Mink A.: Prevention of Iatrogenic Septal Perforation using PDS Foil, International Meeting of the European Academy of Facial Plastic Surgery, Thessaloniki, Greece, September 6.-8., 2000
7. Mink A, **Bönisch M**.: KTP-Laser asissted Stapedotomy, Magyar Fül-Orr-Gégeorvosok 36. Nemzeti Kongresszusa, Heviz, Hungary, Október 24.-28., 2000
8. **Boenisch M**., Mink A.: Prevention of Iatrogenic Septal Perforation using PDS Foil, Magyar Fül-Orr-Gégeorvosok 36. Nemzeti Kongresszusa, Heviz, Hungary, Oktober 24.-28., 2000
9. **Boenisch M**., Hajas T., Nolst Trenité G.J.: Histologische Reaktionen des wachsenden Septumknorpels nach Septumplastik mit und ohne PDS Folie im Tiermodell,. 45. Österreichischer HNO Kongress, Graz, Austria, September 12.-15., 2001
10. **Boenisch M**, Hajas T., Nolst Trenité G.J.: Influence of PDS foil on the operated growing septal cartilage in an animal model, 19th Congress of the European Rhinologic Society, Ulm, Germany, June 16-19, 2002
11. **Boenisch M**., Fibrinklebung in der Septumchirurgie, Symposium Biosurgery – Wound Healing- Tissue Engeneering mit Hilfe der Fibrinklebung, Linz, Austria, 3. Juli, 2002
12. **Boenisch M**, Hajas T. Septal Reconstruction with PDS Foil, European Academy Wintermeeting, St. Christoph am Arlberg, Austria, März 8-15, 2003

13. **Boenisch M**., Hajas T. Septal Reconstruction with PDS Foil, Milano Masterclass, Milano, Italy, 2003, March 23-25
14. **Boenisch M**. Hajas T.Septal Reconstruction in the growing nose with PDS foil, European Academy Meeting, Amsterdam, The Netherlands, October 19-21., 2003
15. **Boenisch M**.,: Septal Reconstruction with PDS foil, 9th International Symposium of Facial Plastic Surgery, Las Vegas, United States, May 1-4, 2006
16. Petropoulos I., **Boenisch M**., Kontzoglou G., PDS Foil in External Septal Reconstruction, 21st Congress of the European Rhinologic Society, Tampere, Finnland, June 11-15, 2006
17. **Boenisch M**., Septal Reconstruction with PDS Foil, 21st Congress of the European Rhinologic Society, Tampere, Finnland, June 11-15, 2006
18. **Boenisch M**., Septal reconstruction with PDS-foil, Meet the International Elite of Facial Plastic Surgeons, Vienna, Austria, Oct. 19-22, 2006