

**CONGENITAL AND ACQUIRED URETHRAL AND  
EXTERNAL GENITALIA PATHOLOGIES AND THEIR  
SURGICAL CORRECTION IN CHILDREN**

**KHALED FATHI M.D**

**PhD thesis**

**Programme Leader**

**PROF. BALÁZS SÜMEGI MD, D.Sc**

**Theme leader**

**PROF. ANDRÁS PINTÉR MD, PhD, D.Sc**

**University of Pécs, Faculty of Medicine**

**Department of Paediatrics**

**Surgical Unit**

**2015**

# CONTENT

<b>1. ABBREVIATIONS</b>	6
<b>2. INTRODUCTION</b>	7
<b>3. AIM OF THE THESIS</b>	9
<b>4. GENERAL CONSIDERATIONS</b>	11
<b>4.1. Anatomy of human urethra</b>	11
4.1.1. Embryology	11
4.1.2. Male urethra	12
4.1.2.1. Posterior urethra	12
4.1.2.2. Anterior urethra	13
4.1.3. Female urethra	13
<b>5. CONGENITAL AND ACQUIRED ANOMALIES OF URETHRA AND EXTERNAL GENITALIA</b>	14
<b>5.1. Hypospadias</b>	15
5.1.1. History	15
5.1.2. Incidence	16
5.1.3. Etiology	16
5.1.4. Pathophysiology	18
5.1.5. Associated anomalies and intersex	18
5.1.6. Classification	19
5.1.7. Diagnosis	19
5.1.8. Surgical correction	20
5.1.9. Goal of surgical repair	20
5.1.10. Role of preoperative hormone stimulation	21
5.1.11. Time of surgical repair	21

5.1.12. Surgical techniques	21
5.1.13. Post-operative management	22
5.1.13.1. Dressing	22
5.1.13.2. Urinary diversion	23
5.1.13.3. Analgesia and pain control	24
5.1.14. Uroflowmetry	24
<b>5.2. Tubularised incised plate urethroplasty-Snodgrass repair</b>	<b>26</b>
5.2.1. Aim	26
5.2.2. Patients and methods	26
5.2.3. Results	27
5.2.4. Discussion	29
<b>5.3. The Y-V glanuloplasty modified “Mathieu” hypospadias repair</b>	<b>31</b>
5.3.1. Aim	31
5.3.2. Patients and methods	31
5.3.3. Results	32
5.3.4. Discussion	34
<b>5.4. Comparative study between Snodgrass and Y-V glanuloplasty modified “Mathieu” techniques</b>	<b>35</b>
5.4.1. Objectives	35
5.4.2. Patients and methods	35
5.4.3. Results	35
5.4.4. Discussion	37
<b>5.5. Congenital posterior urethral polyp</b>	<b>40</b>
5.5.1. Introduction	40

5.5.2. Case report	40
5.5.3. Discussion	43
<b>5.6. Surgical correction of an extreme severe form of penoscrotal transposition with ectopic penis</b>	<b>44</b>
5.6.1. Introduction	44
5.6.2. Case report.	45
5.6.3. Discussion	50
<b>5.7. Penile granuloma annulare associated with urethral anomaly</b>	<b>52</b>
5.7.1. Introduction	52
5.7.2. Case report	52
5.7.3. Discussion	55
5.7.4. Conclusion	55
<b>5.8. Priapism in children</b>	<b>56</b>
5.8.1. Introduction	56
5.8.2. Case reports	56
5.8.3. Discussion	58
5.8.4. Conclusion	59
<b>5.9. Posterior cloaca with accessory urethra</b>	<b>60</b>
5.9.1. Introduction	60
5.9.2. Case report	60
5.9.3. Discussion	62
5.9.4. Conclusion	63
<b>5.10. Paraurethral cyst in female neonates</b>	<b>64</b>
5.10.1. Introduction	64

5.10.2. Case reports	64
5.10.3. Discussion	65
<b>5.11. Semiconservative management of neonatal vaginal prolapse</b>	<b>67</b>
5.11.1. Introduction	67
5.11.2. Case report	67
5.11.3. Discussion	69
 <b>6. THESIS RELATED NOVAL OBSERVATIONS</b>	 <b>71</b>
6.1. Successful surgical correction of an extreme severe form of ectopic penis	71
6.2. Dribbling diversion in Y-V glanuloplasty modified Mathieu repair	71
6.3. Congenital posterior urethral polyp	71
6.4. Penile granuloma annulare associated with urethral anomaly	72
6.5. Paraurethral cyst in female neonate	72
6.6. Semiconservative management of neonatal vaginal prolapse	72
 <b>7. REFERENCES</b>	 <b>73</b>
 <b>8. PUBLICATIONS AND PRESENTATIONS</b>	 <b>81</b>
8.1. Publications related to the thesis	81
8.2. Presentations related to the thesis	82
8.3. Other publications	83
8.4. Cumulative Impact Factor	84
8.5. Total number of citations	84
 <b>9. ACKNOWLEDGEMENT</b>	 <b>85</b>

## 1. ABBREVIATIONS

DHT:	Dihydrotestosterone
DMRT1:	Doublesex and mab-3 related transcription factor 1
DSD:	Disorder of Sex Differentiation
FGF:	Fibroblast Growth Factor
GA:	Granuloma annulare
HOXA :	Homeobox genes family A
HOXD:	Homeobox genes family D
IVF:	In Vitro Fertilisation
LH:	Luteinizing Hormone
MAGPI:	Meatal Advancement and Glanuloplasty
MAVIS:	Mathieu and “V” Incision Suture
USS:	Ultrasonography
NSAID:	Non-steroidal anti-inflammatory drug
PST:	Penoscrotal transposition
$Q_{ave}$ :	Average flow
$Q_{max}$ :	Maximum flow
$Q_{time}$ :	Flow time
TIP:	Tubularised Incised Plate
TUM:	Total Urogenital Mobilisation
UGS:	Urogenital Sinus
VCUG:	Voiding cystourethrogram
WBC:	White Blood Cell

## **2. INTRODUCTION**

Disorders of the external genitalia are especially troubling for parents because of the unconscious emotional significance of these reproductive structures and, probably, the consequent impact of deformities on future generations.

Boys and men with urethral anomalies develop a variety of emotional responses related to the condition. They may begin to avoid situations that are part of everyday life, such as using a public urinal. This feeling of being “different” and “inferior” can generate a range of negative emotions such as depression, anxiety, insecurity, frustration, anger, confusion, humiliation, shame and powerlessness. With time, the experience of these negative emotions can profoundly impair the psychological, social and sexual functioning of the young boy and the man he becomes (1).

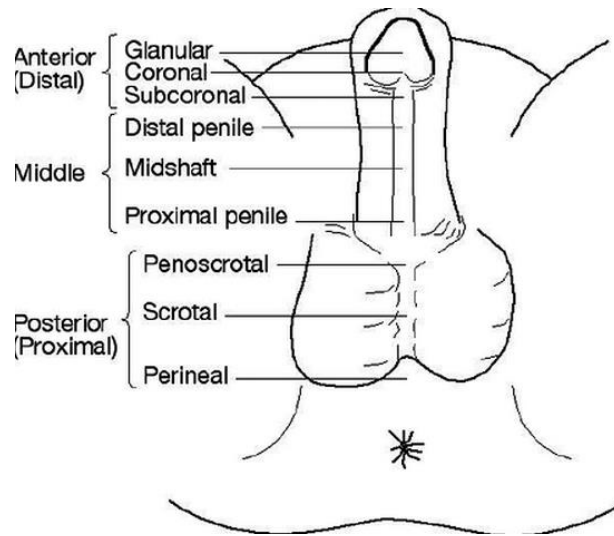
The urethra is a tube which connects the urinary bladder to the outside of the body. The urethra has an excretory function in both sexes, and also a reproductive function in male, as a passage for semen.

The development of the genitourinary system is complex. The urinary system includes the kidneys, ureter, the bladder and the urethra. In terms of their development, the kidney and the ureter develop from intermediate mesoderm. The bladder and the urethra develop from the urogenital sinus. Numerous anomalies of the urethra exist with wide diversity, either as isolated defect or as a part of external genitalia anomalies or in combination with other disorders.

Congenital anomalies of the urethra in boys usually involve anatomic abnormalities of the penis and vice versa. In girls, urethral anomalies may exist without other external genital abnormalities. Surgical repair is needed when function is impaired and/or cosmetic correction is desired.

Hypospadias is the most common urethral anomaly in boys usually associated with three anatomical anomalies, namely ventral opening of the external urethral meatus, ventral curvature (chordee) of penis and hooded foreskin. Based on the location of meatus

hypospadias is divided into distal (glandular, coronal, subcoronal), middle (distal penile, mid shaft, proximal penile) and proximal (penoscrotal, scrotal and perineal) forms (Fig.1) (2,3).



*Fig. 1. Different types of hypospadias*

The greater understanding of the psychologic and emotional issues related to hypospadias repair has led to this procedure being performed at an earlier age. The goal of surgical reconstruction is to bring slit-like meatus to the tip of glans, correct associated chordee if present, to create a conical-shaped glans and to achieve cosmetically acceptable penis (4).



### 3. AIM OF THE THESIS

The purpose of my thesis is to look for and provide new knowledge for surgical repair of the most common malformation of male urethra, the hypospadias, as well as the clinical and surgical management of very rare anomalies of male and female urethra and external genitalia in young infants and children.

In the last century more than 100 different surgical methods have been reported for the repair of hypospadias, this reflect that none of them is the optimal technique to bring about the expected results. Therefore in hypospadias surgery one should not always look for new techniques, but to modify, improve and refine the existing ones. In the first part of my thesis I deal with these kind of modifications.

The second part of my thesis is dedicated to the surgical treatment of rare anomalies of male and female urethra and external genitalia. These rare congenital and acquired urethral and external genitalia anomalies can be a real challenge for pediatric urologist and pediatric surgeon. Because such a rare and complex urogenital anomalies cannot be found in any text book or in the literature. Thus the surgical correction of these rare anomalies need to be individualized and often requires multidisciplinary approach and international collaboration.

In my thesis I would be dealing with the following topics:

1. To find the most effective surgical technique for distal hypospadias repair we studied:

- a. Tubularized Incised Plate urethroplasty (TIP)-Snodgrass repair
- b. The Y-V glanuloplasty modified “Mathieu” hypospadias repair
- c. Comparison between Snodgrass and Y-V glanuloplasty modified Mathieu technique.

2. The surgical corrections of rare forms of congenital and acquired urethral, penile and external genitalia anomalies in young infants and children are described:

- a. congenital posterior urethral polyp
- b. surgical correction of extreme severe form of complete penoscrotal transposition with ectopic penis
- c. penile granuloma annulare associated with urethral anomaly
- d. priapism in children
- e. posterior cloaca with accessory urethra
- f. paraurethral cyst in female neonates
- g. semiconservative management of neonatal vaginal prolapse

## 4. GENERAL CONSIDERATIONS

### 4.1. Anatomy of Human Urethra

#### 4.1.1. Embryology

Between weeks four and five of fetal life, the cloaca, the terminal portion of the hindgut is divided into the dorsal primitive rectum and ventral primitive urogenital sinus. The urethra derives from the primitive urogenital sinus. The urogenital sinus may be divided into three component parts. The first of these is the cranial portion which is continuous with the allantois (later urachus) and forms the bladder proper (Fig.2). The pelvic portion of the urogenital sinus which becomes the proximal urethra in the female and the membranous and prostatic urethra in the male, and the phallic portion of the urogenital sinus which becomes the penile urethra in the male and the vestibule and part of the urethra and vagina in the female (5).

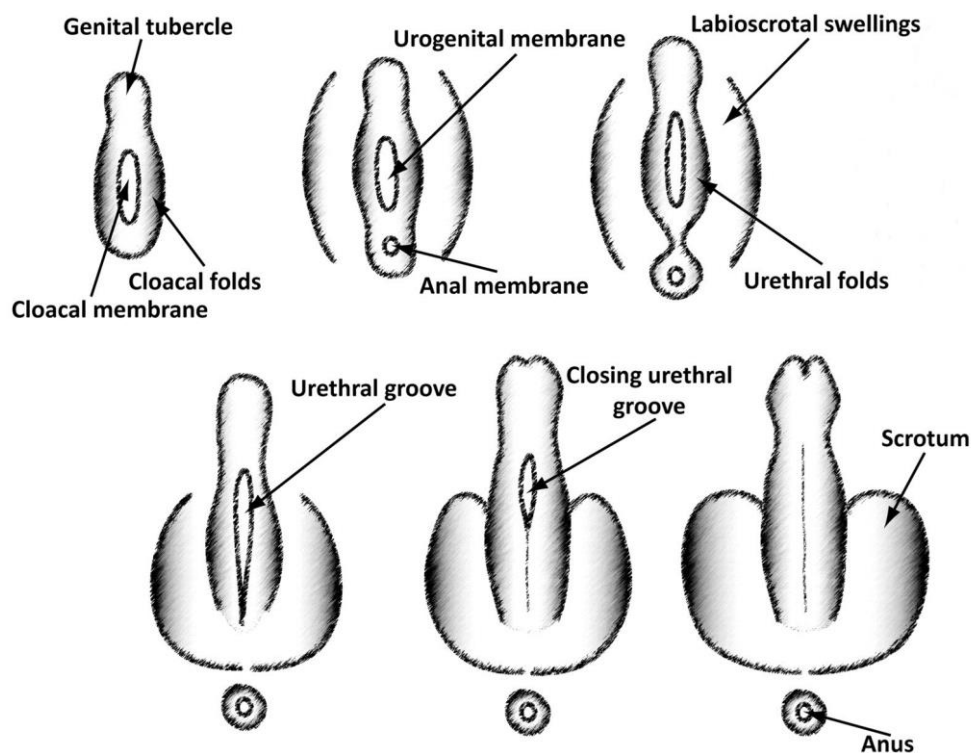


Fig. 2. Embryology of the human male external genitalia. (Marshall FF: Embryology of the lower genitourinary tract. Urol Clin North Am. 1978; 5:3-15)

#### 4.1.2. Male urethra (urethra masculina)

In the human male, the urethra is about 17.5-20 cm long and extends from urinary bladder and opens at the end of the penis (6). The male urethra can be divided into anterior (distal) and posterior (proximal) portions (7). The anterior urethra is subdivided into the glanular, penile, and bulbous portions. The posterior urethra is subdivided into the membranous and prostatic portions (Fig. 3).

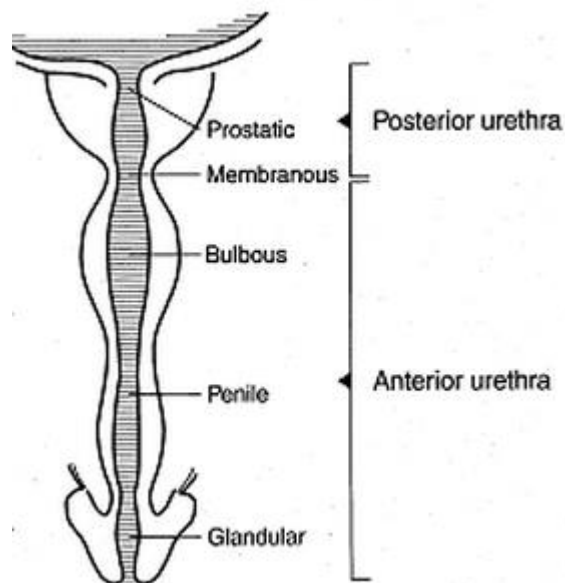


Fig. 3. Anatomy of male urethra

4.1.2.1. Posterior urethra consisting of prostatic and membranous part. The prostatic urethra (*pars prostatica*) begins at the neck of the bladder and includes all of the section that passes through the prostate gland. It is about 3 cm long and lined with transitional epithelium. Urethral crest (verumontanum) is formed by an elevation of the mucous membrane and its subjacent tissue. It is 15-17 mm in length, and about 3 mm in diameter. Verumontanum contains the ejaculatory duct, several prostatic ducts and the prostatic utricle.

The membranous portion (*pars membranacea*) is the shortest and narrowest part of the male urethra. It is about 12 - 19 mm in length, covered with pseudostratified columnar epithelium and completely surrounded by the fibers of the external urethral sphincter, a voluntary muscle controlling the passage of urine along the urethra.

4.1.2.2. Anterior urethra consists of bulbar, penile and navicular (glanular) segment, is 15 cm long and extends from the end of the membranous urethra to the external meatus. The anterior urethra is a tubular structure which has its own wall, the *corpus spongiosum*, which at each end, expands, forming the glans distally and the bulb proximally.

The corpus spongiosum is enclosed in a connective tissue capsule named *tunica albuginea*. Spongiosum and both corpora cavernosa are contained within two fascial layers: Buck's fascia and fascia dartos.

The external urethral orifice is the most contracted part of the urethra; it is a vertical slit, about 6 mm long, bounded on either side by two small labia (7).

#### **4.1.3. Female urethra (*urethra feminina*)**

The female urethra is a narrow membranous canal, about 2-5 cm long and diameter of 6 mm (when undilated), opens between the clitoris and the vaginal opening, extending from the internal to the external urethral orifice. It is placed behind the symphysis pubis, imbedded in the anterior wall of the vagina, and its direction is obliquely downward and forward. Its lining is composed of stratified squamous epithelium, which becomes transitional near the bladder. Structure of the urethra consists of three coats: muscular, erectile, and mucous (8).

## 5. CONGENITAL AND ACQUIRED ANOMALIES OF URETHRA AND EXTERNAL GENITALIA

The current understanding of the embryology and anatomy of normal urethral development might help explain the causes of the various anomalies as well as their relationships. The congenital and acquired anomalies of male and female urethra (9) are demonstrated in the table 1.

<b>Congenital and acquired urethral anomalies</b>	
<b>Male</b>	<b>Female</b>
Lacuna magna	Urethral prolapse
Anterior urethral valve	<b>Paraurethral cysts*</b>
Anterior urethral diverticula	Urogenital sinus
Megalourethra	Persisted cloaca
Urethral duplication	<b>Posterior cloaca*</b>
Congenital urethral fistula	<b>Vaginal prolapse*</b>
Congenital urethral stricture	
<b>Congenital urethral polyps*</b>	
Mullerian duct remnant	
Posterior urethral valve	
Epispadias	
<b>Penoscrotal transposition*</b>	
Megameatus intact prepuce	
Lichen sclerosis/BXO	
<b>Hypospadias*</b>	
<b>Penile granuloma annulare*</b>	
<b>Priapism*</b>	

*Table 1. Congenital and acquired anomalies of human urethra (\* anomalies treated and analysed in details in the thesis)*

Urethral anomaly can be a part or associated with other congenital disorder such as: anorectal malformation, epispadias-exstrophy-complex, Prune belly syndrome and tumours.

The detailed description of all urethral anomaly is beyond the scope of my thesis, however the most common urethral pathologies as well as some rare cases of external genitalia and their management are discussed.

## **5.1. Hypospadias**

The term hypospadias comes from the Greek terms hypo meaning “under” and spadon meaning "a tear". Hypospadias is a congenital anomaly in which the urethral meatus is abnormally located ventrally anywhere from the glans to the perineum. The associated penile shortening and ventral curvature known as chordee are more likely to be present with proximal defects. Therefore hypospadias is associated with three anatomical anomalies of the penis, abnormal ventral urethral opening, chordee of the penis and hooded foreskin. However, not all patients have all three features (10).

### **5.1.1 History**

Galen was the first who used the term hypospadias in the second century AD, he appreciated the major significance of chordee. Mettaure in 1842 recognised penile skin shortening as a cause of chordee. Using penile skin for urethroplasty was first described by Thiersch in 1869 and Duplay in 1874, he also described a technique very similar to MAGPI later popularised by Duckett in the 1970s. The modern enthusiasm for pedicle tubes from prepuce was first employed by Van Hook in 1896, Rochet in 1899, Hamilton Russell in 1900, and Mayo in 1901. Free grafts, so popularised in the last 2 decades, were performed by Nové-Josserand in

1897 (11). Poisson first reported a meatal-based flip-flap repair which later popularised with great success by Mathieu (12).

### 5.1.2. Incidence

The incidence of hypospadias in general is 1 in 300, approximately 1 in every 250 male births in the United States. However, the data for different countries show considerable variation. In several countries, the incidence of hypospadias may be rising but seems rather constant, at 0.26 per 1000 live births in Mexico and Scandinavia and 2.11 per 1000 live births in Hungary. The incidence of hypospadias is greater in whites than in blacks, and it is more common in those of Jewish and Italian descent (13).

### 5.1.3. Etiology

The etiology of hypospadias is multifactorial. In 66-75% of hypospadias the cause remains unknown. Several etiologies for hypospadias have been suggested, including genetic, endocrine, and environmental factors.

*Genetic factors:* Hypospadias is more common among monozygotic twins and offsprings of fathers who have hypospadias. The prevalence of hypospadias in male children of fathers with hypospadias has been reported as 8%, and 14% of brothers of children with hypospadias are also affected. The inheritance is likely polygenic (14).

Several genes are involved in the sexual determination, acting with the environmental influences might be responsible for occurrence of hypospadias. These genes act at different levels of sexual development:

1- Level of phallus development: Homeobox genes family, A (HOXA) and D (HOXD), fibroblast growth factor (FGF) 2, 8, 10 genes, the FGF (fibroblast growth factor) gene family, especially FGF2, FGF8 and FGF10 (15).



2- Level of testicular determination: SOX9, DMRT1 and GATA4 encode transcription factors acting immediately before the differentiation of the gonad into testis. Mutations of these genes induce testicular dysgenesis and are associated with 46,XY disorders of sex differentiation (DSD), including severe hypospadias (16).

3- Level of androgen biosynthesis: Mutations in the LH receptor gene (inducing a Leydig cell hypoplasia) and the 5 $\alpha$ -reductase gene (inducing a defect of dihydrotestosterone synthesis) induce hypospadias, most often in a severe form with associated cryptorchidism and/or micropenis (17).

4- Level of androgen action: Mutations in the androgen receptor gene have been found in patients with severe forms of hypospadias (18).

*Endocrine factors:* A decrease in available androgen or an inability to use available androgen appropriately may result in hypospadias. Aaronson et al, reported 66% of boys with mild hypospadias and 40% with severe hypospadias were found to have a defect in testosterone biosynthesis (19). Mutations in the 5-alpha reductase enzyme, which converts testosterone to the more potent dihydrotestosterone (DHT), have been associated with hypospadias.

Males born through IVF have 5-fold increased risk of hypospadias when compared with a control group. This may reflect maternal exposure to progesterone, which is commonly administered in IVF protocols. Progesterone is a substrate for 5-alpha reductase and acts as a competitive inhibitor of the testosterone to DHT conversion.

*Environmental factors:* Estrogens have been implicated in abnormal penile development in many animal models. Estrogenic activity are ubiquitous in industrialized society and are ingested as pesticides on fruits and vegetables, endogenous plant estrogens, in milk from lactating pregnant dairy cows, from plastic linings in metal cans, and in pharmaceuticals (14).

*Combination theory:* A growing body of evidence suggests that the development of hypospadias has a two-hit etiology involving a genetic predisposition coupled with fetal exposure to an environmental disruptor. There is evidence that poor semen quality, testicular cancer, undescended testes and hypospadias are symptoms of one underlying entity, testicular dysgenesis syndrome (TDS), which may be increasingly common due to adverse environmental influences. Experimental and epidemiological studies suggest that TDS is the

result of disruption of embryonal programming and gonadal development during fetal life (20).

#### 5.1.4. Pathophysiology

Hypospadias is a congenital defect that is thought to occur embryologically during urethral development, from 8-20 weeks' gestation. As the phallus grows, the open urethral groove extends from its base to the level of the corona. The classic theory is that the urethral folds coalesce in the midline from base to tip, forming a tubularised penile urethra and median scrotal raphe. This accounts for the posterior, bulbar and penile urethra. The anterior or glanular urethra is thought to develop in a proximal direction, with an ectodermal core forming at the tip of the glans penis, which canalizes to join with the more proximal urethra at the level of the corona. The higher incidence of subcoronal hypospadias supports the vulnerable final step in this theory of development. Therefore 65% of hypospadias occur in the distal part of urethra, 15% in mid-penile and 20% in the proximal region.

The prepuce normally forms as a ridge of skin from the corona that grows circumferentially, fusing with the glans. Failure of fusion of the urethral folds in hypospadias impedes this process, and the result is a dorsal hooded prepuce (14).

#### 5.1.5. Associated anomalies and Intersex

The most common anomalies associated with hypospadias are undescended testes 9.3% and inguinal hernias 9.1% which increase in the severe form of hypospadias up to 30% of undescended testes and to 20% of inguinal hernias (21).

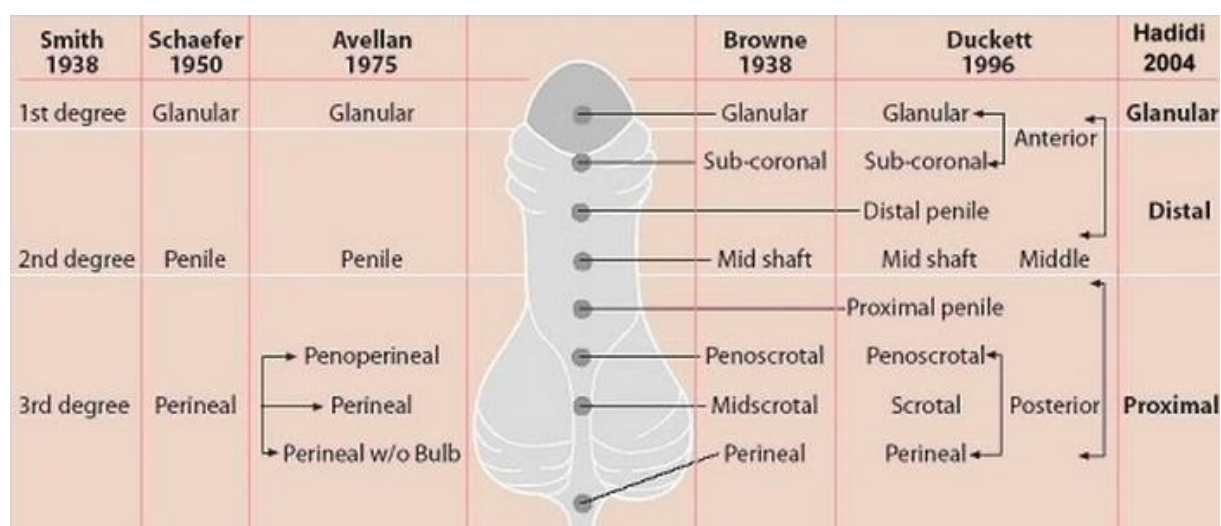
Severe form of hypospadias can be the presentation of disorder of sexual development (DSD), particularly when associated with undescended testis. Moreover, if any gonad was non-palpable, the incidence rose to 50%. In this instance there should always be a karyotype and hormonal study and ultrasound scan of the urinary tract and the internal organs (22).

Associated persistent prostatic utricle is present in 20% of case, and occasionally noted when catheterization of the urethra is attempted in patients with hypospadias. Bifid scrotum is also associated with severe hypospadias.

Associated abnormalities of the upper urinary tract such as pelviureteric junction obstruction, vesicoureteral reflux are rare, occurring about 2% of patients with severe hypospadias, therefore routine ultrasound scan is not necessary in mild form of hypospadias (14).

#### 5.1.6. Classification

There are many classification described in the literature based on the position of the ectopic urethral meatus. However the most frequently used classification is the Barcat, modified by Duckett's classification, which describes the location of the meatus after correction of any associated chordee (23, 24). Descriptive locations include anterior (glanular and subcoronal), middle (distal penile, midshaft, and proximal penile), and posterior (penoscrotal, scrotal, and perineal). The location is anterior in 50% of cases, middle in 20%, and posterior in 30%; the subcoronal position is the most common overall (Fig. 4).



*Fig. 4. Different classifications of hypospadias, according to location of meatus (From Hadidi AT, Azmy AF: Hypospadias Surgery: An Illustrated Guide, Heidelberg: Springer Verlag 2004)*

#### 5.1.7. Diagnosis

Hypospadias is typically diagnosed during a newborn examination. A dorsal hood of foreskin and glanular groove is evident, but, upon closer inspection, the prepuce is incomplete ventrally and the urethral meatus is noted in a proximally ectopic position. Occasionally, a

specific type of hypospadias, known as megameatus intact prepuce variant of hypospadias, is not noted until a circumcision has been performed (14). The penile curvature or chordee may be readily apparent or discernible only during erection. Proximal hypospadias is commonly associated with a bifid scrotum and penoscrotal transposition.

#### 5.1.8. Surgical correction

Over 200 original urethral reconstruction methods have been reported in the literature which reflects that none can be used to correct all type of hypospadias. Surgical correction of hypospadias remains a great challenge for paediatric surgeon/urologist. The major technical advances in hypospadias surgery that have improved surgical outcomes are:

- 1) Preservation of the urethral plate
- 2) Incision of the urethral plate
- 3) Dorsal midline plication to correct penile curvature
- 4) Deepithelized urethroplasty dartos flap coverage

Combination of these factors can result in better functional and aesthetic outcome (25).

#### 5.1.9. Goal of surgical repair

The goals of hypospadias repair is to create a straight penis by correcting any curvature (orthoplasty), to create a urethra with its meatus at the tip of the penis (urethroplasty and meatoplasty), to re-form the glans into a more natural conical configuration (glansplasty). The resulting penis should enable the patient to void while standing, should be suitable for future sexual intercourse, and should present an acceptable cosmetic appearance. Culp and McRoberts asserted that *‘It is the inalienable right of every boy to be a pointer instead of a sitter by the time he starts school and to write his name legibly in the snow’* (26).

The attitude toward hypospadias repair has significantly changed in the last 2 decades due to the emphasis on the preservation of urethral plate and its role in urethroplasty results. Erol and Baskin reported that the urethral plate is well vascularised, has a rich nerve supply, muscular

backing and gland formation and advocated the preservation of the urethral plate whenever possible (25).

#### 5.1.10. Role of preoperative hormone stimulation

Preoperative androgen therapy has been suggested to enhance the size of the penis, improve the blood supply and to achieve better surgical repair. Gonadotrophin or testosterone may be used for this purpose administered intramuscularly or as topical ointment 4-6 weeks preoperatively (27).

#### 5.1.11. Time of surgical repair

The timing of hypospadias repair has changed over the past 2 decades. Currently, most surgeons attempt to repair hypospadias when the child is aged 6-18 months, trending toward earlier intervention. Gianantonio et al recommend the ideal time for primary hypospadias repair is to be the age of 6-12 months. This has been associated with an improved emotional and psychological result, as the genital awareness does not occur before age 18 months (4).

#### 5.1.12. Surgical techniques

Reconstruction of urethra can be performed in a single-stage or in a two-staged procedure. As a general rule, a single-stage repair is appropriate for distal, mid shaft and proximal hypospadias without significant chordee. (1, 2, 4, 28). A two-staged repair is preserved for hypospadias with severe chordee, perineal hypospadias and for “*hypospadias cripples*” (Table 2).

<b>Single-stage repair</b>		
<b>1. Urethra reposition</b>	<b>2. Tubularising urethral plate</b>	<b>3. Pedicle flap</b>
i) MAGPI	i) Thiersch-Duplay	i) Meatal-based flap <b>“Mathieu”</b>
		ii) Y-V glanuloplasty modified Mathieu
ii) Beck’s procedure	ii) Tubularised incised plate (TIP) <b>“Snodgrass”</b>	iii) Duckett onlay
	iii) Urethral augmentation “Snod-graft”	iv) Duckett inlay
<b>Two staged repair</b>		
<b>Stage I</b>	Chordectomy + free full-thickness (Wolf) graft from inner prepuce or buccal mucosa	
<b>Stage II</b>	Tubularising the graft as in Thiersch-Duplay	

*Table 2. Surgical procedures for correction of hypospadias*

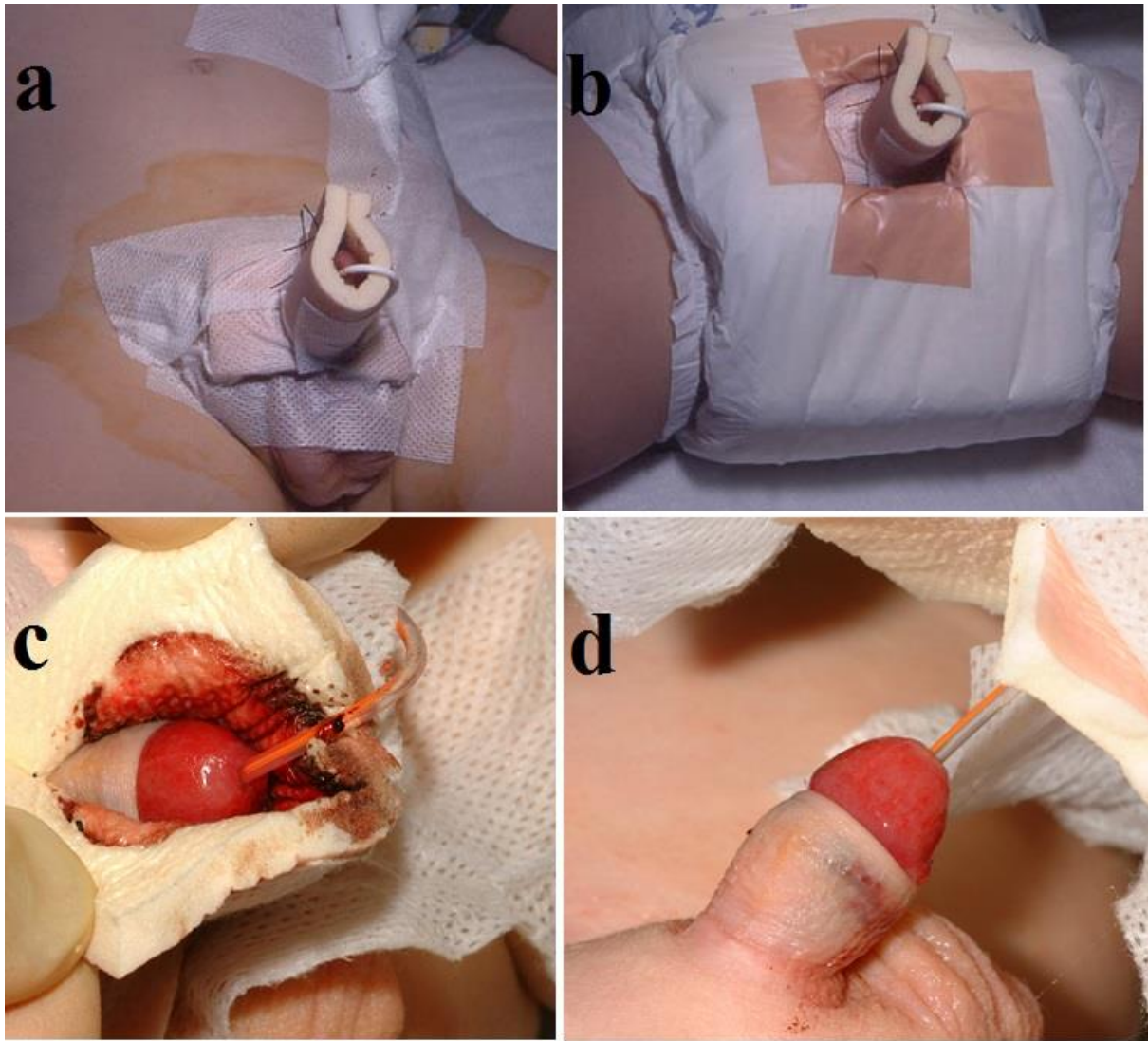
### 5.1.13. Post-operative management

#### 5.1.13.1. Dressing

The aim of dressings in hypospadias repair is to maintain haemostatic pressure over the wound and maintaining the phallus in an upright position. It should be easy to apply and comfortable.

The main purpose of dressing is to immobilise the penis, minimise oedema and prevent haematoma formation. Many dressing modes are available and mostly subject to the surgeon preference. The dressing may be divided into three main categories: 1. Totally concealing, 2. Partial concealing, 3. Unconcealing. Common dressing include silastic foam, a clean bandage, bio-occlusive membrane dressing, and non-adhesive dressing. The dressing should also be easy to remove with the least discomfort and distress to the patient and their family. Most dressings are bulky, hard to apply or remove, and may fall off in an active child. Allevyn dressing has a unique tri-laminate structure, inner non-adherent, central absorbent

and outer water- and microbial-proof layers. (Fig. 5) It is a non-adherent, easy to apply and removable without pain or distress to the patient (29).



*Fig. 5. Non-adherent dressing: a-b application of dressing, c-d removal of dressing*

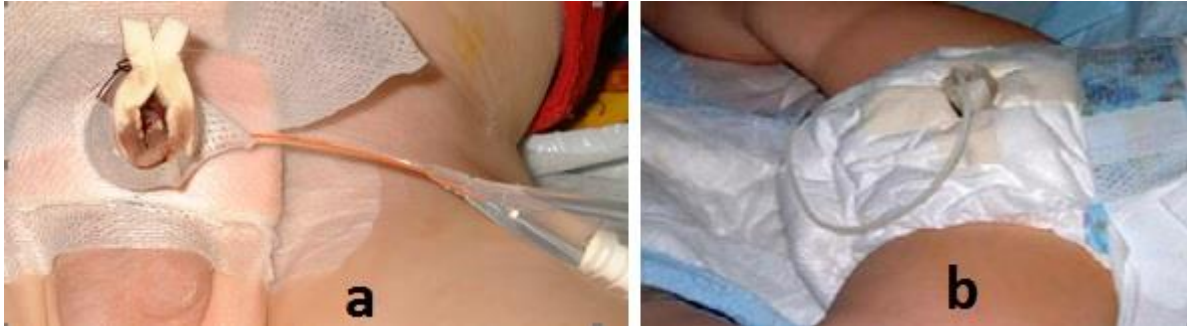#### 5.1.13.2. Urinary diversion

The goal of urinary diversion is to prevent urethral oedema from obstructing urine flow, putting the suture line under pressure and to allow the neourethra to heal completely before contact with urine flow.

Basically there are two different types of urinary diversion available:

1. Suprapubic urinary diversion with a puncture catheter (cystofix)
2. Transurethral urinary diversion with (Fig. 6):

- a. a balloon catheter which drains into a urine bag.
- b. "dribbling stent", which drains the bladder into a diaper continuously



*Fig. 6. Balloon catheter (a) and dripping stent (b)*

One advantage of the transurethral drainage, especially with "dribbling stent and double diaper, is that it is much more comfortable, since the child can be mobilized quickly without urinary bag , while a suprapubic drainage system limits child's mobility.

#### 5.1.13.3. Analgesia and pain control

Post-operative analgesia and pain control is extremely important in hypospadias surgery. It can be achieved by caudal anesthetic block, epidural anesthetic or penile block. We almost always use a caudal anesthetic block to help decrease postoperative pain by bupivacaine 0.25% followed by oral or suppository diclofenac. Bladder spasm caused by catheters can be managed with Oxybutynin.

#### 5.1.14. Uroflowmetry

Uroflowmetry is an excellent non-invasive tool to assess urinary flow after hypospadias repair in children. Urinary flow is described by its rate and pattern, which may be either continuous or intermittent. The flow rate is defined as the volume of fluid expelled via the urethra per unit time, expressed in ml/sec (Fig. 7). Normal uroflow has bell-shaped pattern and the following parameters:



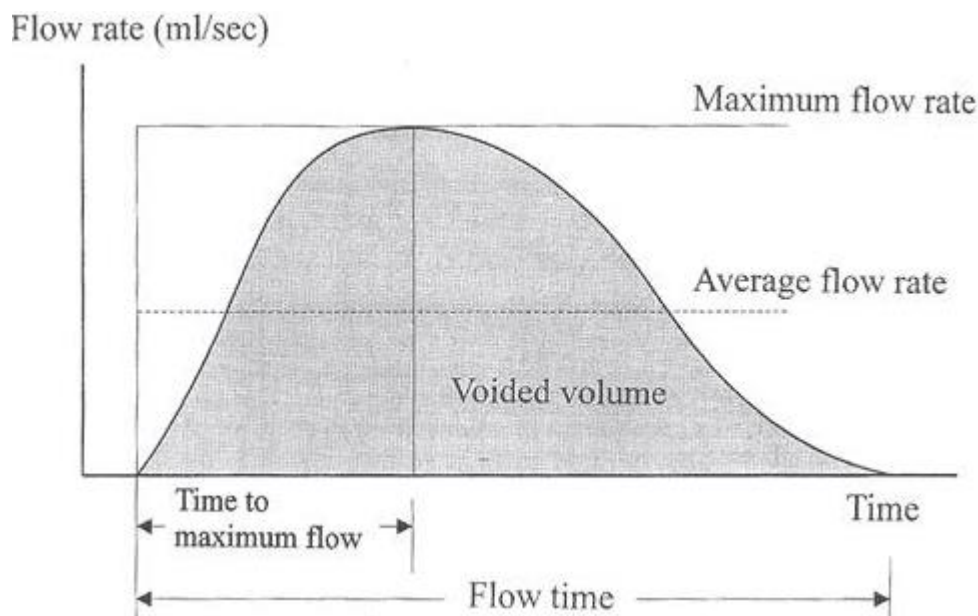
Flow time (Qtime) - the time over which measurable flow actually occurs

Flow rate (Q) - it is defined as the volume of fluid expelled via the urethra per unit time and is expressed in millilitres per second (ml/sec)

Maximum flow rate (Q<sub>max</sub>) - the maximum measured value of the flow rate

Average flow rate (Q<sub>ave</sub>) - it is voided volume divided by flow time.

Time to maximum flow - the elapsed time from the onset of flow to the point of maximum flow (30).



*Fig. 7. Normal bell-shaped uroflow curve.*

The recorded flow pattern, maximum (Q<sub>max</sub>) and average (Q<sub>ave</sub>) flow rates expressed as percentiles and compared with paediatric uroflow rate nomogram obtained by Toguri et al. The Q<sub>max</sub> and Q<sub>ave</sub> greater than 25<sup>th</sup> percentile accepted as normal, from 5<sup>th</sup> -25<sup>th</sup> percentile was considered equivocally obstructed and obstructed below 5<sup>th</sup> percentile (31).

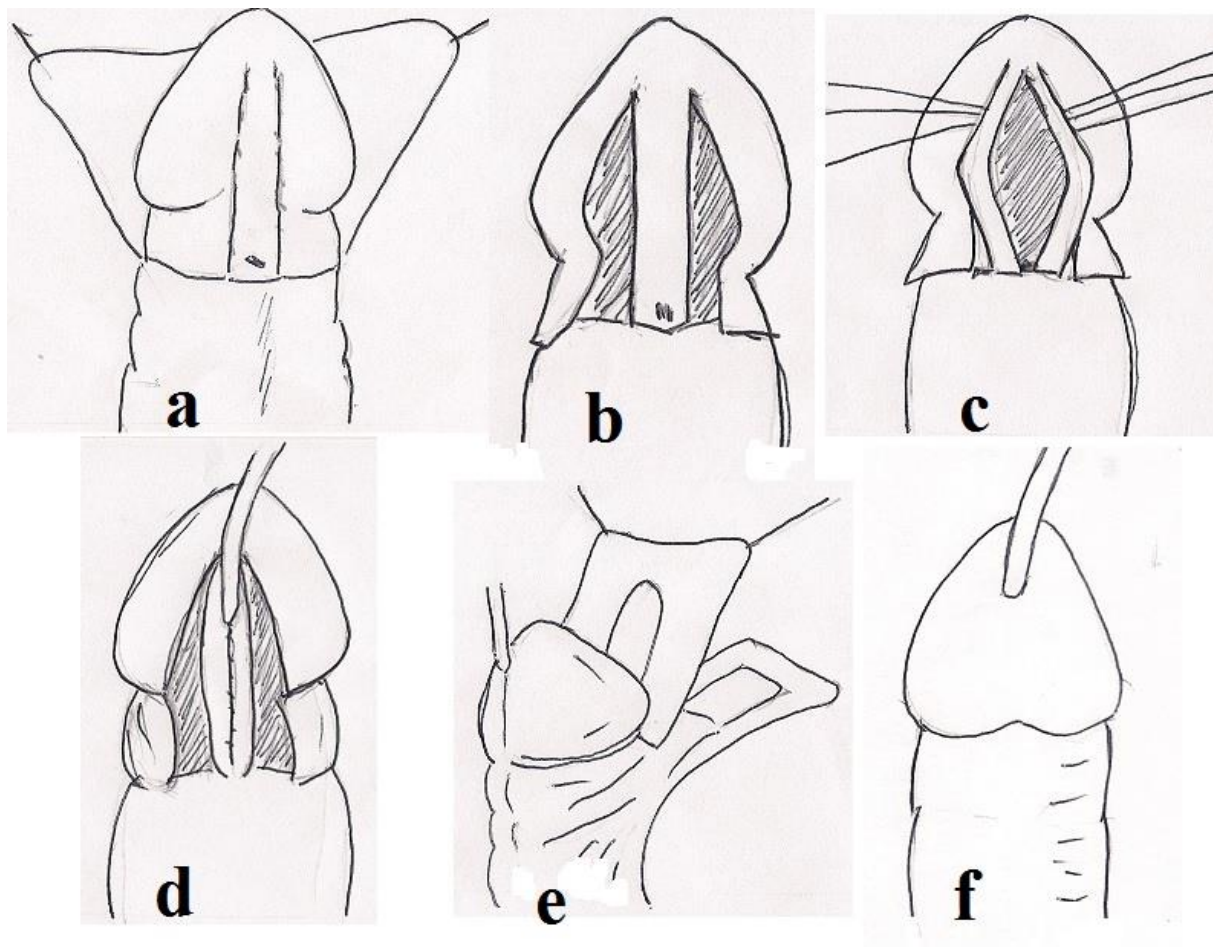
## **5.2. TUBULARIZED INCISED PLATE URETHROPLASTY-SNODGRASS REPAIR (32)**

### **5.2.1. Aim**

To evaluate the outcome of tubularised incised plate (TIP) urethroplasty for the treatment of coronal and distal penile hypospadias.

### **5.2.2. Patients and methods**

We retrospectively reviewed the medical records of 54 patients, who underwent tubularised incised plate urethroplasty for distal hypospadias at the Surgical Unit of the Department of Paediatrics of Pecs University between November 1998 and October 2002. All children had primary coronal or distal penile hypospadias without chordee. The original tubularised incised plate urethroplasty procedure was used as describe by Warrant T. Snodgrass (33). Incision is made along urethral plate-glans junction creating two lateral glans wing (Fig. 8/a-b). Urethral plate incised in the midline deep to subcutaneous layer from meatus to the glans tip (Fig. 8/c), and the plate tubularised with running suture (Fig. 8/d). Dorsal subcutaneous tissue dissected from preputial and shaft skin rotated ventrally to cover the neourethra as a protective layer (Fig. 8/e). Glanuloplasty was done in two layers (Fig. 8/f) and the neourethra stented. The urethroplasty was performed over 6 Fr, 8Fr and 10Fr catheter in 5, 41 and 8 patients respectively. Compression dressing was applied in all boys. The urinary diversion was in the form of urethral stent in 7 patients, transurethral indwelling stent in 31 patients and 16 patients had combination of urethral stent and suprapubic bladder catheter. The procedure was done under general anaesthesia supplemented with penile block or caudal anaesthesia as additional post-operative pain management.



*Fig. 8. Tubularised incised plate urethroplasty, a-b) incision along urethral plate and creation of glandular wings, c) incised urethral plate, d) tubularisation of urethral plate, e) protective dorsal subcutaneous tissue, f) glanuloplasty..*

### **5.2.3. Results**

The median age of the patients at operation was 28 months (range 17-207). The mean follow up period was 34.2 months (range 2-55). The mean operative time was 95 minutes (range 65-135), mean time of urinary diversion was 14,6 days (range 8-15), and mean hospital stay was 7.3 days (range 3-18). Postoperatively we observed 27 (50%) patients with mild-moderate degree of meatal stenosis. All these patients were managed by home self-intermittent meatal dilatation done by their parents using 8-10-12 metal dilator depending on the age of the patient and the degree of stenosis. Meatal stenosis successfully resolved in 18 boys with mean period of home meatal dilatation of 9,6 months (range 1-51). The uroflowmetry performed in cooperative boys, obtained at the start of home self meatal dilatation programme,

subsequently in parallel with the clinical progress and at the end of treatment (Fig. 9). Pre-dilatation flow pattern, maximum flow rate ( $Q_{\max}$ ), average flow rate ( $Q_{\text{ave}}$ ) were compared to end of treatment uroflowmetry parameters. Tougri nomogram was used for assessment of obstruction which was represented in percentile. The  $Q_{\max}$  and  $Q_{\text{ave}}$  were consider normal if  $>25^{\text{th}}$  percentile, as equivocally obstructed when in the  $5\text{--}25^{\text{th}}$  percentile and obstructed if  $<5^{\text{th}}$  percentile (31).

The uroflowmetry showed significant improvement in  $Q_{\max}$  and  $Q_{\text{ave}}$  between pre-dilatation and at end of treatment results ( $p < 0.05$ ).

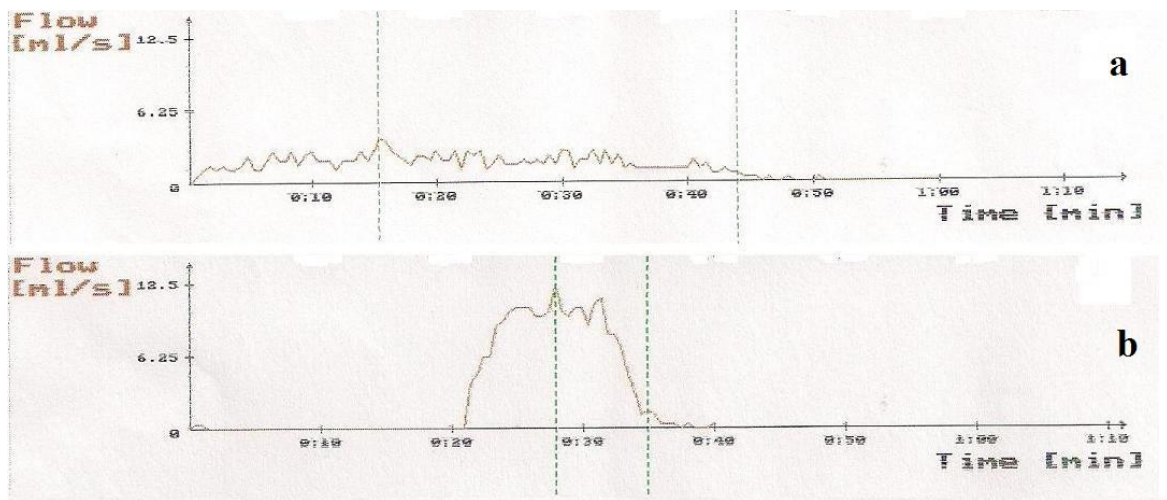
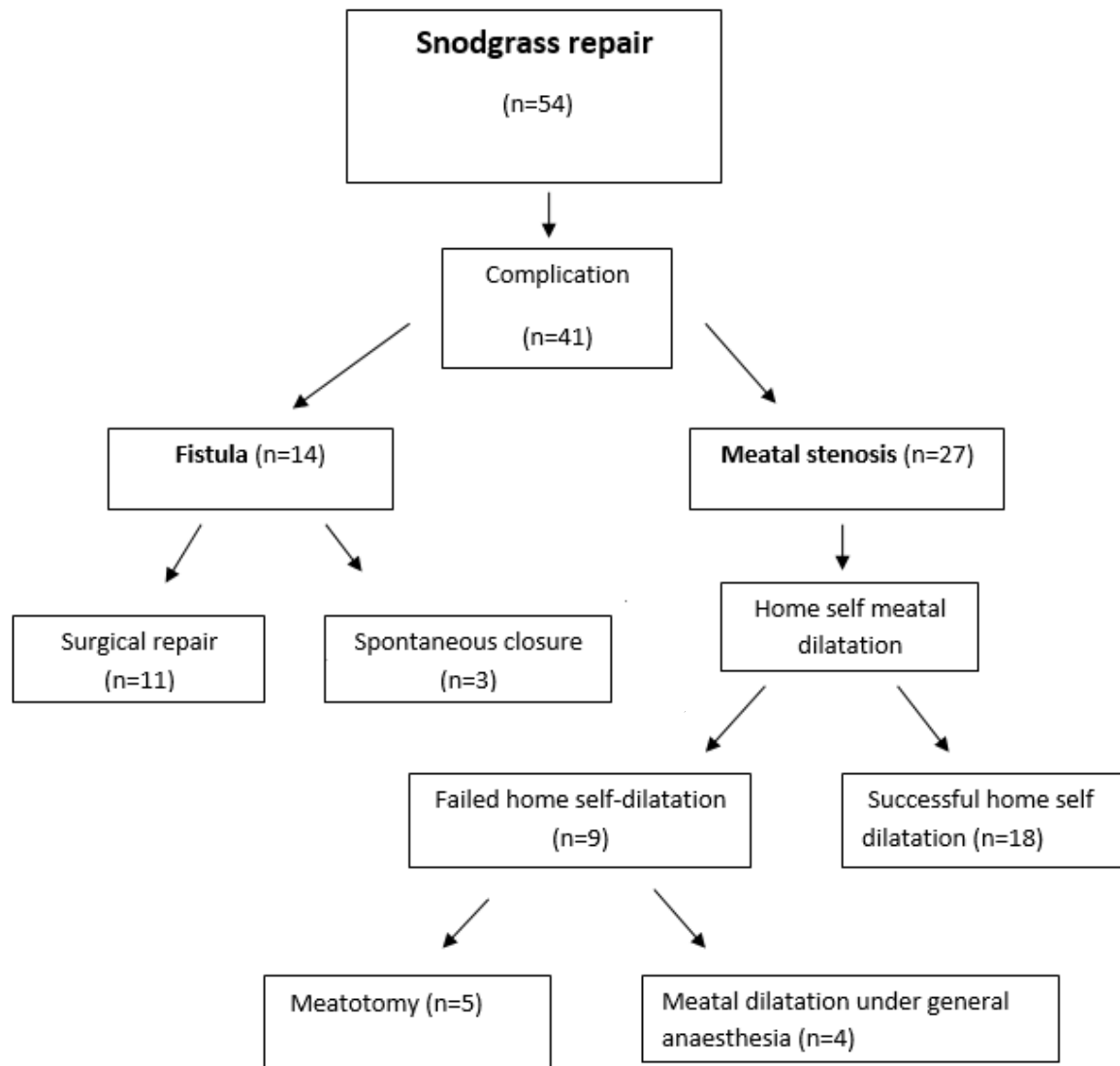


Fig. 9. Uroflow pattern in 8-year-old boy (a) before home self-dilatation and (b) after end of dilatation treatment.

Four patients required re-hospitalization for meatal dilatation under general anesthesia. Additional 5 patients eventually underwent meatotomy due to unsuccessful home self meatal dilatation. The uroflowmetry was used to assess the progress of home self-dilatation. Fourteen boys developed fistula, 3 of them closed spontaneously and remaining 11 were surgically repaired (Fig. 10).



*Fig. 10. Results of tubularised incised plate hypospadias repair.*

#### 5.2.4. Discussion

Urethral stenosis is one of the most common complications of hypospadias surgery. Stenosis is mostly found in the meatal region or along the anastomosis between the native and neourethra (34). Some authors attribute the meatal stenosis in TIP urethroplasty to the formation of adhesions between raw surfaces of incised urethral plate, and contraction at the neomeatus area (35). Different healing character of the incised glans tip may also account for this complication. Other factor such as extensive glandular wing mobilization causing ischemia and subsequent contraction can also result in meatal stenosis (36, 37). To avoid

meatal stenosis several technical modifications has been reported. Singh et al suggested that the urethral plate incision must not extend too far distally, in a series of 75 patients 25 of them did not develop meatal stenosis using this modification (34). In addition Stehr et al advocated the intactness of the anticipated dorsal lip of the neomeatus, creating a generous wide elliptical external meatus (35). Y-V glanuloplasty can further reduce the occurrence of meatal stenosis (38).

Routine dilatation after hypospadias repair and routine assessments by uroflowmetry post-operatively remained controversial (36). Uroflowmetry is simple and non-invasive way of evaluating the dynamics of micturition and diagnosis of meatal stenosis in conjunction with the clinical findings (30, 31).

The meatal stenosis can be treated by self meatal dilatation, meatotomy and meatoplasty. Home self meatal dilatation using urethral meatal dilators can be taught successfully to boys and their parents and performed at the comfort of home environment. It avoids the need for repeated general anaesthesia and repeated clinic attendance.

In our series we observed 27 meatal stenosis. However, 15 patients developed the meatal stenosis during first 1,5 years of study which can partly be attributed to the technical errors. All 27 patients required regular home self-intermittent meatal dilatation for mean period of 9,6 months and 5 patients had to undergo meatotomy in spite of long period of meatal dilatation. Although tubularized incised plate urethroplasty has gained a world-wide popularity and much single and multicenter reports support its application for primary distal, proximal and even secondary hypospadias, our experience indicates that the healing process in TIP urethroplasty might lead to shrinkage around the meatal area resulting in meatal stenosis. Home self-dilatation is first mode of treatment with high success rate. However, meatotomy or meatoplasty might be required in unsuccessful cases of home self-dilatation.

### **5.3. THE Y-V GLANULOPLASTY MODIFIED “MATHIEU” HYPOSPADIAS REPAIR (39)**

#### **5.3.1. Aim**

To investigate the surgical results and the role of indwelling transurethral catheter on the post-operative micturation in Y-V glanuloplasty modified Mathieu repair for primary hypospadias. The major drawback of the original Mathieu technique is “bucket-handle or half-moon” final appearance of meatus. Boddy and Samuel modified Mathieu repair by excision of a triangle from the apex of perimeatal flap (Mathieu and ‘V’ Incision Suture-MAVIS) to improve the neomeatus (40). Hadidi described Y-V glanuloplasty modification to produce slit-like meatus (38).

#### **5.3.2. Patients and methods**

Between October 2002 and March 2006 in our Surgical Unit of the Department of Paediatrics of Medical Faculty of Pecs University, 59 consecutive boys underwent Y-V glanuloplasty modified Mathieu repair for primary distal hypospadias as described by Hadidi (37). A Y-shaped incision is made on the glans with the centre of the Y where the tip of the neo-meatus will be located. Each limb of the Y is 0.5 cm long and the angle between the upper two limbs of Y is 60° (Fig. 11/A). The Y-shaped incision is made deep to result into 3 flaps, 1 upper and 2 lateral. Y sutured as V using continuous 6.0 Viracyl suture (Fig. 11/B). A U-shaped flap is elevated, taking care to preserve its fascia (Fig. 11/C). Urethroplasty is performed in two layers followed by glanuloplasty (Fig. 11/D-E).

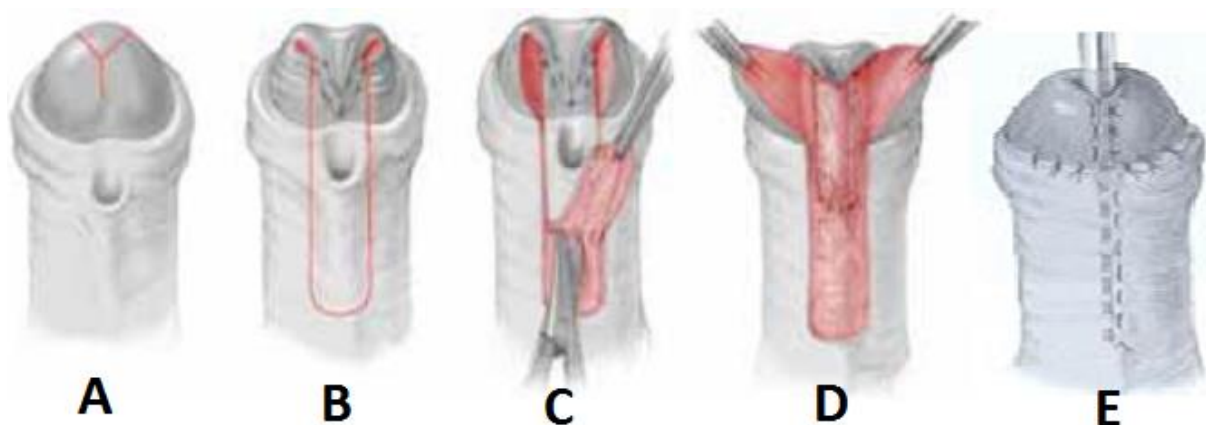


Fig. 11. Y-V glanuloplasty modified Mathieu hypospadias repair. A) Y-shaped incision, B) Y sutured as V-shape, C) U-shaped flap elevated, D) urethroplasty, E) glanuloplasty.

The first 37 patients classified as group A, had catheterless repair as suggested by Hadidi to avoid irritation. Due to significant distressing painful post-operative voiding, the next 22 children (group B) had the indwelling transurethral catheter for 24-48 hours as a *dribbling diversion* into the nappy in non-toilet trained patients or attached to a urinary bag in older toilet trained boys. The urethroplasty was made over an 8-10Fr feeding tube, and at the end of procedure, a 5Fr feeding tube was passed through the tube used for the repair into the bladder. Adjunct caudal analgesia or penile block with 0.25% bupivacaine was given in 30 and 29 cases respectively, followed by 2-5 days of oral diclofenac for postoperative pain management. Meatal stenosis was assessed clinically and in cooperative children, with uroflowmetry. Post-operative painful voiding, urinary retention, meatal stenosis and fistula *was* statistically analysed with Wilcoxon signed rank test in the 2 groups. For statistical analysis SPSS ver11.5, IL, USA was used,  $p < 0.05$  considered to be significant.

### 5.3.3. Results

In group A (catheterless repair) the median age was 25 months (range 17 to 168 months). All patients had distressing painful first micturation. Eight children failed to pass urine for more than 8 hours. Five patients (13.5%) had urinary retention presented with palpable bladder, pain and distress; three required catheterisation. Of these 5 children, 2 had a caudal block and 3 a penile block of 0.25% bupivacaine for postoperative pain control. Furthermore 6 (16%)



boys developed meatal stenosis determined by uroflowmetry which resolved by dilatation. Urethrocutaneous fistula was seen in 5 (13.5%) patients.

In group B (transurethral catheter), the median age was 27 months (range 13-190). All boys had painless micturation after removal of the indwelling (catheter in the bladder) transurethral catheter. Only 1 (4.5%) patient had urethrocutaneous fistula and none presented with meatal stenosis. Post-operative painful voiding and urinary retention was statistically significant ( $p<0.05$ ) when the 2 groups compared. In spite of higher rate of meatal stenosis and urethrocutaneous fistula in group A, it did not show statistical significance (Fig. 12).

Mean follow up was 22.1 months (range 1-45), mean duration of operative time was 96.44 minutes (range 70-130) and mean hospital stay was 3.64 days (range 2-11).

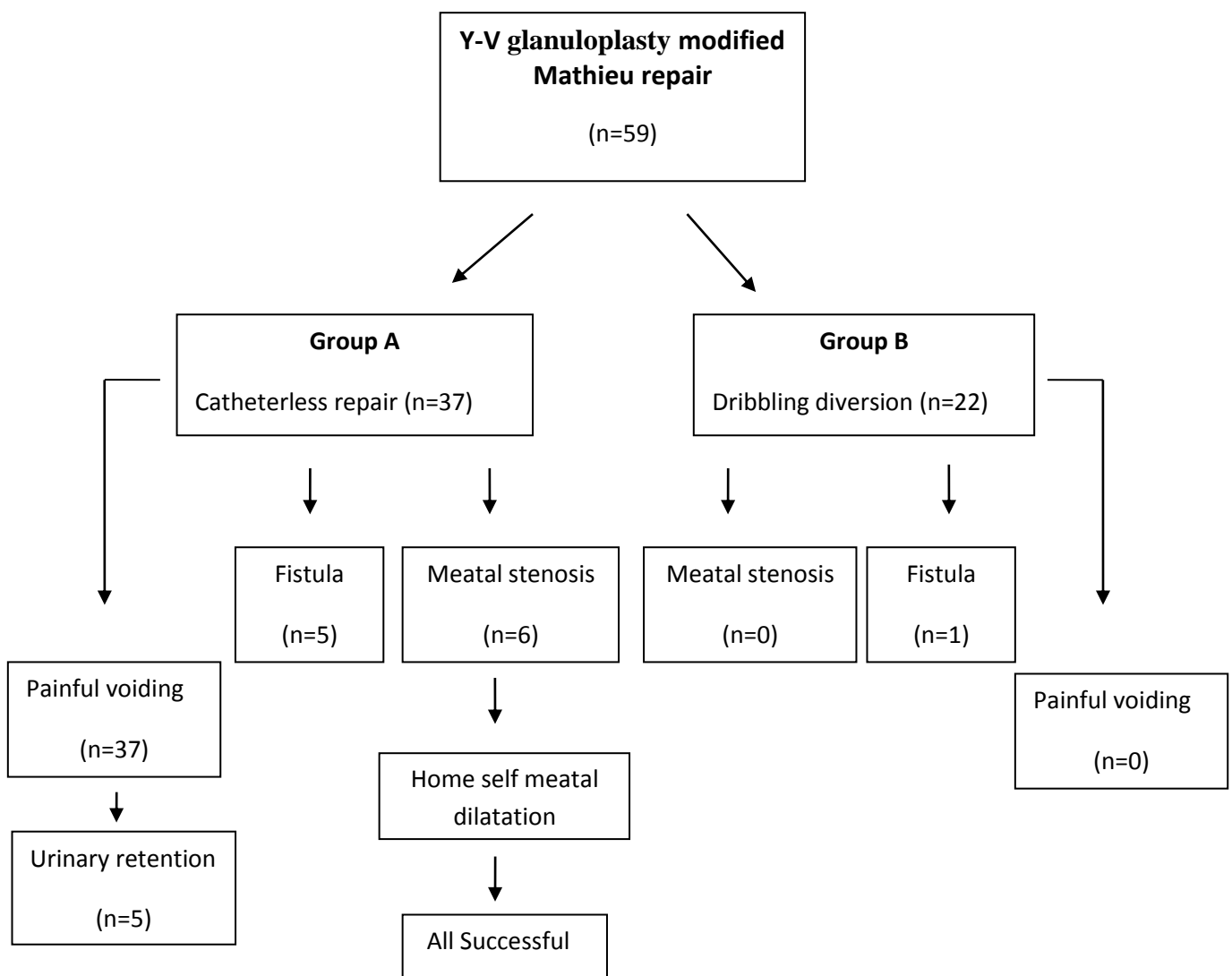


Fig. 12. Result of Y-V glanuloplasty modified Mathieu hypospadias repair.

### 5.3.4. Discussion

The role of stent and catheter in the hypospadias repair for urinary diversion remains controversial. Mathieu originally performed the procedure without catheter drainage. Rabinowitz reported catheterless Mathieu hypospadias repair on an outpatient basis with good results, no fistulae and few complications (41). Hakeem reported no difference in the outcome when compared stented versus unstented repair (42).

In contrast, Buson reported higher complication rates (18.9% unstented vs. 4.6% stented repair) and advocated the use of a stent in Mathieu repair. The use of a stent can reduce the incidence of fistula formation while adding only minimally to morbidity (43).

To reduce the morbidity associated with catheters, we initially performed Y-V glanuloplasty modified Mathieu repair without catheter. All patients had distressful postoperative voiding in spite of adequate analgesia. Eight patients had delayed postoperative micturition (> 8 hours). Five patients developed urethrocutaneous fistula including 1 boy who needed postoperative catheterization for urinary retention. Six boys presented with clinical symptoms of meatal stenosis supported by uroflowmetry which subsequently resolved by dilatation. In order to overcome these complications, particularly painful voiding, we left a smaller calibre indwelling transurethral catheter at the end of procedure as a *dribbling diversion* for 24-48 hours. This provided drainage and at the same time, the smaller calibre tube allowed space for the development of postoperative oedema without increasing tension on the suture line or damaging to the urethra mucosal blood supply. All boys had smooth painless voiding after removal of the indwelling catheter and only 1 had urethrocutaneous fistula.

Our results suggest that short term (24-48 hours) use of an indwelling transurethral catheter in Y-V glanuloplasty modified Mathieu hypospadias repair reduces the postoperative complications such as distressing painful postoperative voiding and urinary retention. In addition, it reduces the incidence of meatal stenosis and urethrocutaneous fistula.

Nevertheless it requires a larger number of patients in each group to determine the significant difference in outcome in relation to fistula rate. We continue to advocate the use of a small calibre indwelling transurethral catheter as a *dribbling diversion* for 24-48 hours in Y-V glanuloplasty modified Mathieu hypospadias repair.

## **5.4. COMPARATIVE STUDY BETWEEN SNODGRASS AND Y-V GLANULOPLASTY MODIFIED MATHIEU TECHNIQUE (44)**

### **5.4.1. Objective**

To compare the surgical outcome, success rate, postoperative complication and cosmetic result of tubularised incised plate (Snodgrass) and Y-V glanuloplasty modified perimeatal-based flap (Mathieu) urethroplasty in primary distal hypospadias repair.

### **5.4.2. Patients and methods**

The case notes of all patients underwent distal hypospadias repair in our surgical unit between November 1998 and March 2006 were reviewed. Snodgrass procedure was done in 54 patients and 59 boys underwent Y-V glanuloplasty modified Mathieu repair. The mean follow up was 28 months (2-55) for Snodgrass repair and 22.1 months (range 1-45) in Y-V glanuloplasty modified Mathieu procedure. The surgical outcome, duration of surgery, hospital stay, complication, parental satisfaction and uroflowmetry results were recorded.

### **5.4.3. Results**

The mean duration of operation time was similar, 95 minutes in Snodgrass and 96.4 minutes in Mathieu repair. The urethrocutaneous fistula rate were 14 (27%) and 6 (10.1%) ( $p<0.05$ ) and meatal stenosis were 27 (50%) and 6 (10.1%) ( $p<0.05$ ) in Snodgrass group and in Y-V glanuloplasty modified Mathieu group, respectively. The mean hospital stay was significantly shorter in Y-V glanuloplasty modified Mathieu repair in compare to Snodgrass 7.3 days and 3.6 days ( $p<0.05$ ) respectively (Table 3).

	<b>Snodgrass</b>	<b>Y-V glanuloplasty modified Mathieu</b>	<b>P values</b>
<b>Number of patients</b>	54	59	-
<b>Median age</b> (months)	28	25	-
<b>Mean follow up</b> (months)	28	22.1	-
<b>Mean operation time</b> (minutes)	95	96	0.68
<b>Mean hospital stay</b> (days)	7.3	3.6	<0,05
<b>Mean duration of stenting</b> (days)	14	1	
<b>Meatal stenosis</b> (%)	50	10.1	<0.05
<b>Fistula</b> (%)	25.9	10.1	<0.05

*Table 3. Overall comparison of patients' characteristics and surgical outcome between Snodgrass and Y-V glanuloplasty modified Mathieu procedures.*

The parental satisfaction questionnaire were obtained from 45/54 (83.3%) of Snodgrass and 49/59 (83%) of Y-V glanuloplasty modified Mathieu group. Parents were asked to rate their satisfaction in term of surgical result, functional and cosmetic outcome on a scale of 1 to 5 (1=failed, 2=poor, 3=average, 4=good, 5=excellent). In Snodgrass group 51.1% rated 5, whereas 65.3% in Mathieu group were excellently satisfied (Table 4).

	<b>Excellent (5)</b>	<b>Good (4)</b>	<b>Average (3)</b>	<b>Poor (2)</b>	<b>Failed (1)</b>
<b>Snodgrass</b>	23 (51.1%)	16 (35.5%)	5 (11.1%)	0	1 (2.2%)
Y-V glanuloplasty modified <b>Mathieu</b>	32 (65.3%)	11 (22.4%)	4 (8.1%)	1 (2%)	1 (2%)

*Table 4. Parental satisfaction of the cosmetic result and surgical outcome of hypospadias repair.*

#### 5.4.4. Discussion

Hypospadias repair continues to be a great challenge for paediatric surgeon/urologist. More than two thirds of the cases of hypospadias are of anterior type. Several surgical techniques have been advocated for repair of anterior hypospadias such as MAGPI, Beck, Mathieu and Snodgrass just to name a few. However Mathieu and Snodgrass are the most commonly used techniques (45).

Complications are common after hypospadias repair varying with the severity of the hypospadias. Recent studies indicated the overall complication rate range of 3-11.2% for Mathieu repair and 5.5% for Snodgrass procedure (46, 47).

Early complications include postoperative haemorrhage, infection, oedema and bladder spasm. Use of dressing in hypospadias repair reduces postoperative bleeding and minimises the haematoma formation which can act as a focus for infection and subsequent fistula formation or complete breakdown of the repair.

Late complications of hypospadias repair are fistula, meatal stenosis, urethral stenosis, hairy urethra, persistent chordee, urethral diverticulum (urethrocele) and balanitis xerotica obliterans.

Fistulae are the most common complication and can occur with varying range of 0%-5% of patients. It can present immediately after the surgery or years after repair. The location of fistula varies, most common site is at the junction of the glans and the penile shaft. Before fistula repair proximal obstructions such as urethral stenosis/stricture should be excluded (48). In our series of 54 Snodgrass repair 14 boys developed fistula in compare to 6 fistulae noted in 59 of Y-V glanuloplasty modified Mathieu repair.

Meatal stenosis and urethral stricture are the second most common complications after urethrocuteaneous fistula. Meatal stenosis may results from either ischemia of the flap, inadequately mobilised glans wings or due to tight glans closure (49). The incidence of meatal stenosis is reported 0% to 5% in recent review in hypospadias repair (36). In our series of 54 Snodgrass repair we observed 27 boys with meatal stenosis requiring regular home self

meatal dilatation. Eighteen were treated successfully, 4 needed further dilatation under general anaesthesia and 5 patients had to undergo meatotomy. We believe home self meatal dilatation should be the first mode of treatment with high success rate. However, meatotomy or meatoplasty might be required in unsuccessful cases of home self meatal dilatation. In our series of 59 Y-V glanuloplasty modified Mathieu hypospadias repair we observed only 6 meatal stenosis responded well to home self-dilatation.

Balanitis xerotica obliterans is a form of lichen sclerosus et atrophicus causing chronic inflammation and fibrosis of glans leading to meatal and urethral stenosis after hypospadias repair (50).

Tarek et al reported 21 patients underwent Snodgrass repair with excellent results and 2 fistula and 2 meatal stenosis (51).

As the most commonly used techniques many authors have reported studies comparing Snodgrass and Mathiesu procedures. Oswald J et al reported a study of 60 patients underwent Snodgrass and Mathieu repair for distal hypospadias with 30 boys in each group. The 2 techniques were compared with regard to fistula, appearance and duration of operative time. The mean duration of operative time was found significantly shorter in Snodgrass procedure than in Mathieu repair (75 vs. 115 minutes  $p < 0.05$ ). Fistula rate was more frequent in Mathieu repair and meatus was slit-like in Snodgrass and round and horizontal in Mathieu repair. They concluded that Snodgrass procedure has lower complication rate and results in better, more naturally looking meatus (46).

In study by Imamoglu et al, 56 patients operated by Snodgrass technique and 54 boys were operated using Mathieu procedure with mean postoperative follow up of 24 months. Wound dehiscence and flap necrosis were less in Snodgrass repair whereas meatal stenosis were more frequent in tubularised incised plate repair. There was no significant difference between the 2 groups regarding fistula formation. Therefore Snodgrass repair was preferred in distal hypospadias with normal (deep groove) urethral plate and if the urethra plate was not healthy, Mathieu repair advocated (52).

Moradi et al reported a study of 15 patients operated by Snodgrass procedure and 18 boys underwent Mathieu repair. Fistula rate and meatal stenosis were 13.32% vs 5.55% and 6.66%

vs 0% in Snodgrass and Mathieu repair respectively. Success rate was also significantly higher in Mathieu group than in Snodgrass group (94.45% vs 80.02%). The conclusion was that both techniques are as acceptable and as effective in spite of some reports in favour of Snodgrass procedure (53).

To avoid the risk of devascularisation of the neourethral flap, Kiss et al, combined perimeatal-base flap with midline incision of the urethral plate to decrease the tension and achieve adequate diameter neourethra. They reported 19 patients operated on using this combined technique, only 1 developed fistula without any other complication. This modification resulted in successful hypospadias repair with low complication and better functional and cosmetic outcome (54).

In our study we experienced higher overall complications, longer days of hospital stay (mean 7 vs 3 days) and longer stenting days (mean 14 vs 1) in Snodgrass group than Y-V glanuloplasty modified Mathieu repair. The mean operative time was similar (95 vs 96 minutes) and the parents were equally satisfied with the outcome (83.3% vs 83.0%) in both groups. The relatively higher meatal stenosis in Snodgrass was partly associated with learning curve as 15/27 developed meatal stenosis in the first 18 months of using tubularised incised plate technique. Being a teaching surgical unit, operation were also done by paediatric surgical trainees assisted by a consultant. The healing of raw surface of incised plate could contribute to this complications. In comparison Y-V glanuloplasty modified Mathieu group had higher success rate and lower complication. The critics of “half-moon” shaped meatus in Mathieu repair was corrected by Y-V glanuloplasty modification resulting in a slit-like meatus. We noted that using a small calibre indwelling transurethral catheter as a *dribbling diversion* for 24-48 hours significantly improves the post-operative painful micturition and also reduces the incidence of meatal stenosis and fistula rate.

There is no single, universally applicable technique for hypospadias repair. In spite of some reports in favour of Snodgrass repair, we concluded that Y-V glanuloplasty modified Mathieu technique has higher success rate, less complications and shorter hospital stay for primary distal hypospadias repair.

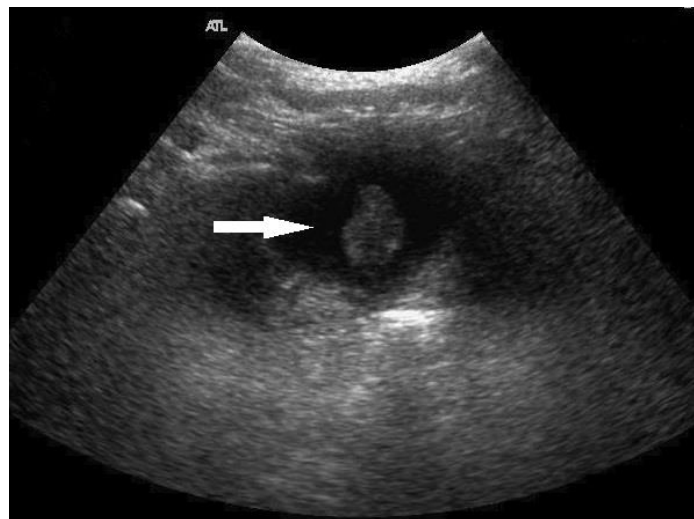
## 5.5. CONGENITAL POSTERIOR URETHRAL POLYP (55)

### 5.5.1. Introduction

Congenital urethral polyps are rare, benign anomalies characterized as benign urothelial-lined masses attached to a fibrovascular stalk arising from the verumontanum, presenting almost exclusively in boys. They are composed of vascular connective tissue, glandular and nerve tissue have also been described. Because they have a stalk, these polyps are mobile and can move proximally into the bladder or distally into the bulbous urethra. Urethral polyps' association to the verumontanum suggests the embryologic persistence of Müllerian structures. These polyps may present as acute urinary retention or intermittent obstruction due to prolapse into the bladder or urethral obstruction.

### 5.5.2. Case report

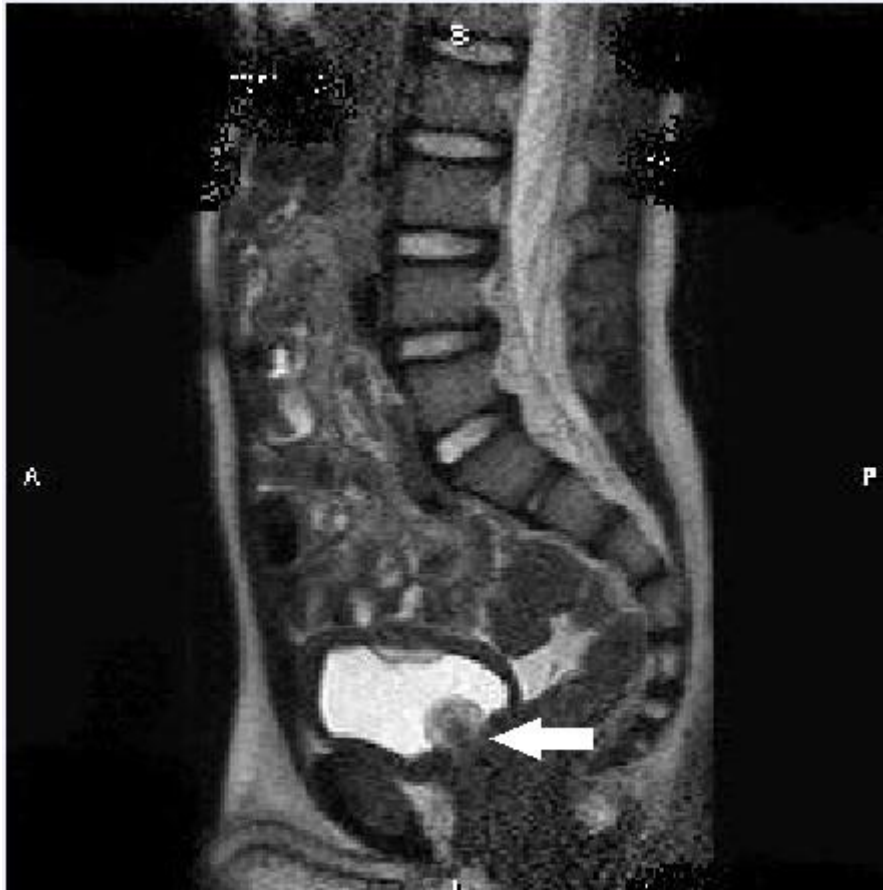A 3 year-old boy presented with hematuria, dysuria and urinary retention. Initially he was treated a urinary tract infection with antibiotics in a district hospital. Bladder ultrasound scan showed a polypoid lesion at the bladder base with mild thickness of the bladder wall (Fig. 13).



*Fig.13. Ultrasonography of polypoid soft tissue mass at the bladder base (arrow).*

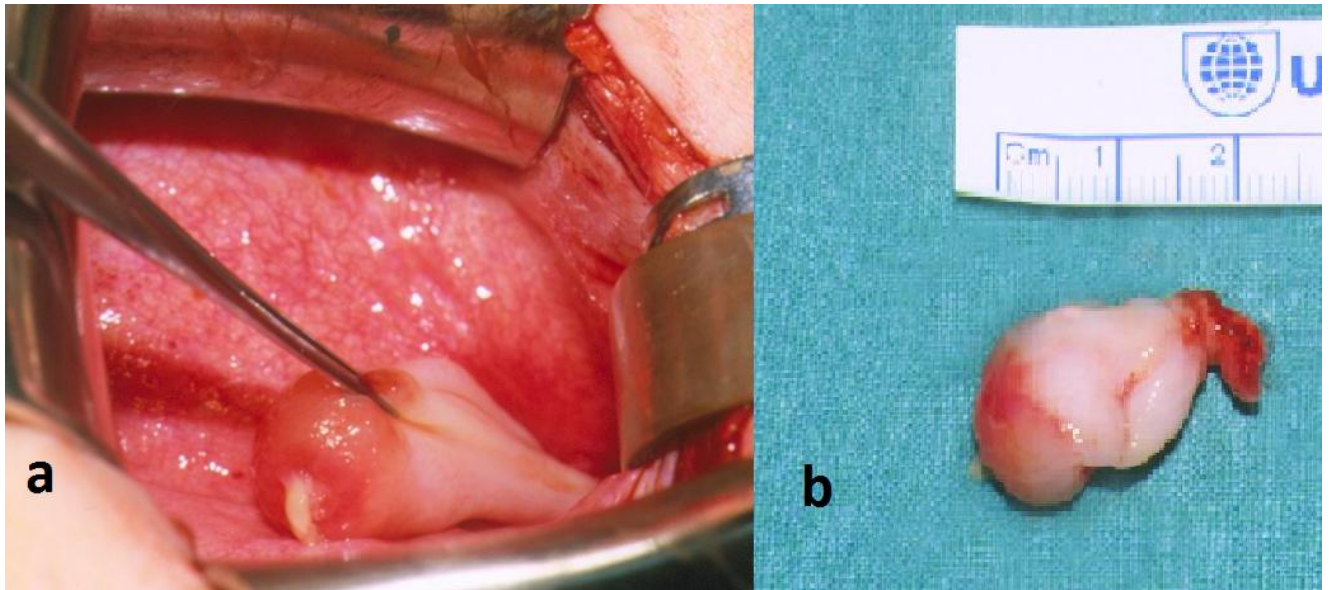
MRI revealed a lobulated mass arising from the posterior urethra with no evidence of infiltration or invasion into the bladder wall (Fig. 14).





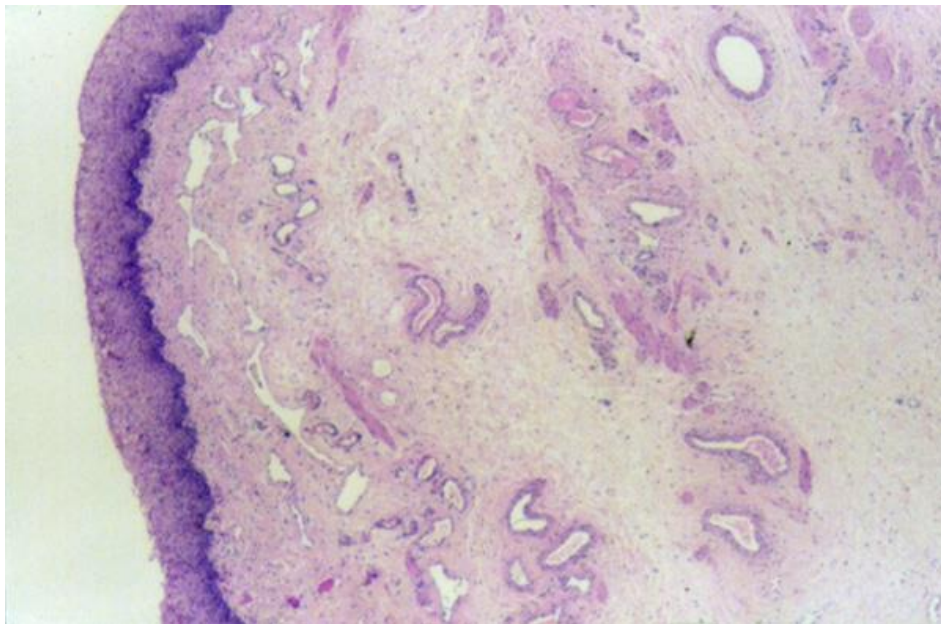
*Fig.14. MRI of polypoid mass arising from the bladder base just over the urethral origin (arrow).*

Uretherocystoscopy demonstrated a 2.5 cm urethral polyp, arising from the verumontanum prolapsing into the bladder. It was unsuitable for endoscopic removal because it had a smooth surface and was tense, therefore it was excised through a cystostomy (Fig. 15/a-b).



*Fig.15. Intraoperative (a) and post-resection (b) polyp.*

Histopathology confirmed the lesion to be a benign fibroepithelial polyp (Fig. 16).



*Fig. 16. Fibrous core covered by transitional urothelium (Haematoxylin-eosin; magnification: 40x).*

### 5.5.3. Discussion

Congenital posterior urethral polyps are benign mesodermal tumours occurring in male children arising from the verumontanum and often prolapse through to the bladder neck causing acute or intermittent bladder outlet obstruction (56). The etiology of urethral polyps is still controversial. Congenital, infective, irritative, infectious, traumatic and obstructive causes have been proposed. The presence of a large polyp in healthy newborns and infants is a strong argument in favour of congenital origin. They may arise as a result of developmental error in the invagination process of the glandular material of the inner zone of the prostate. Downs (57) postulated a protrusion from the posterior urethral wall while Kuppusami (58) is in favour of the metaplastic epithelial change secondary to maternal estrogen during pregnancy.

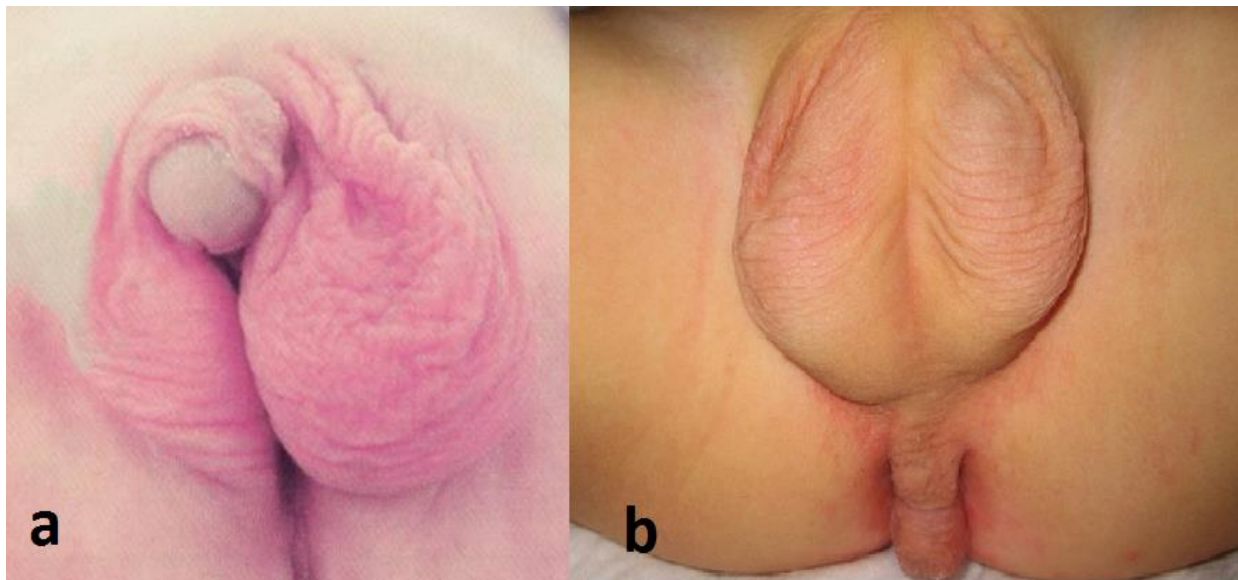
The most important differential diagnoses of fibroepithelial polyps include blood clot, posterior urethral valve, stone, and constipation with faecal mass compressing bladder neck, urothelial papilloma, and rhabdomyosarcoma of the bladder. Clinical presentations include infection, haematuria, dysuria, urinary urgency and hesitancy, intermittent or acute urinary retention and enuresis. Associated anomalies such as hypospadias, unilateral hydronephrosis, vesicoureteral reflux and bladder diverticulum has been reported (59).

The radiological evaluation includes renal and bladder ultrasound and voiding cystourethrography. Additional imaging such as non-contrast CT and MRI are helpful to precisely localize the lesion. Urethrocystoscopy confirms the lesion by demonstrating its origin, shape and size. Histologically they are described as benign polyps composed of a fibrous core covered by normal transitional urothelium. Formerly the posterior urethral polyps were mostly treated by open cystotomy, but in the last 2 decades the preferred treatment method has been transurethral resection, or laser therapy.

## 5.6. SURGICAL CORRECTION OF AN EXTREME SEVERE FORM OF PENOSCROTAL TRANSPOSITION WITH ECTOPIC PENIS (60)

### 5.6.1. Introduction

Complete penoscrotal transposition (PST) is rare congenital anomaly of external genitalia, characterized by malposition of the penis in relation to the scrotum. Most reported cases of PST are sporadic. There are two form of penoscrotal transposition. In incomplete type which is more common, the penis lies in the bifid mid-scrotum (Fig. 17/a). In complete transposition, the scrotum is not bifid and located cephal to penis, which emerges from the perineum (Fig. 17/b) (61).



*Fig. 17. a) incomplete and b) complete forms of penoscrotal transposition.*

Complete PST are most often associated with severe forms of hypospadias. The embryological sequence responsible for this malformation remains unclear; however, it has been suggested that at 12 weeks of gestation genital tubercle and labioscrotal migrates inferiorly to form scrotum. Failure of migration, possibly due to a gubernaculum defect that may be unilateral or bilateral leads to anomalies like incomplete, complete transposition or ectopic scrotum (62).

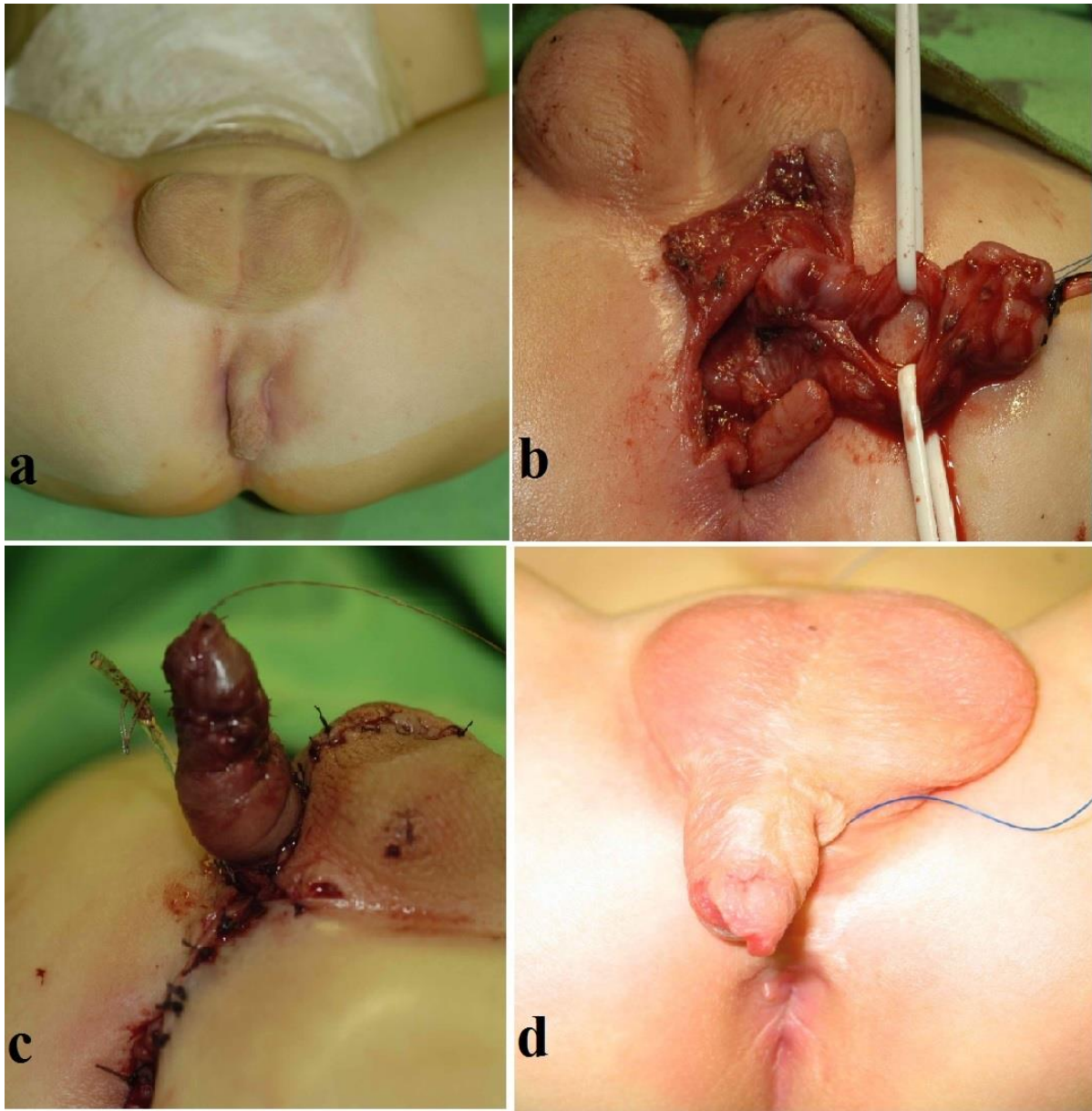
### 5.6.2. Case report

A male neonate was treated in our department who presented with ectopic penis, an extremely severe form of complete penoscrotal transposition (Fig 18/a). The baby delivered at 35 weeks of gestation, received a vesicostomy on day 2 at the referral hospital, mother was offered a gender change operation for the baby, but she refused and subsequently the neonate was transferred to our department.

Physical examination showed a slightly ventrally located, normally looking scrotum containing normal sized testicles. A 2-cm hypoplastic phallus with hypospadias and chordee ectopically placed in the perineum just cephal to the normally placed anus (Fig 20 a). Postnatal abdominal ultrasound scan revealed left crossed ectopic kidney. Cystogram via vesicostomy did not show vesicoureteral reflux. There was no associated cardiac anomaly and karyotype showed 46 XY. He underwent multistage surgeries to correct his ectopic penis.

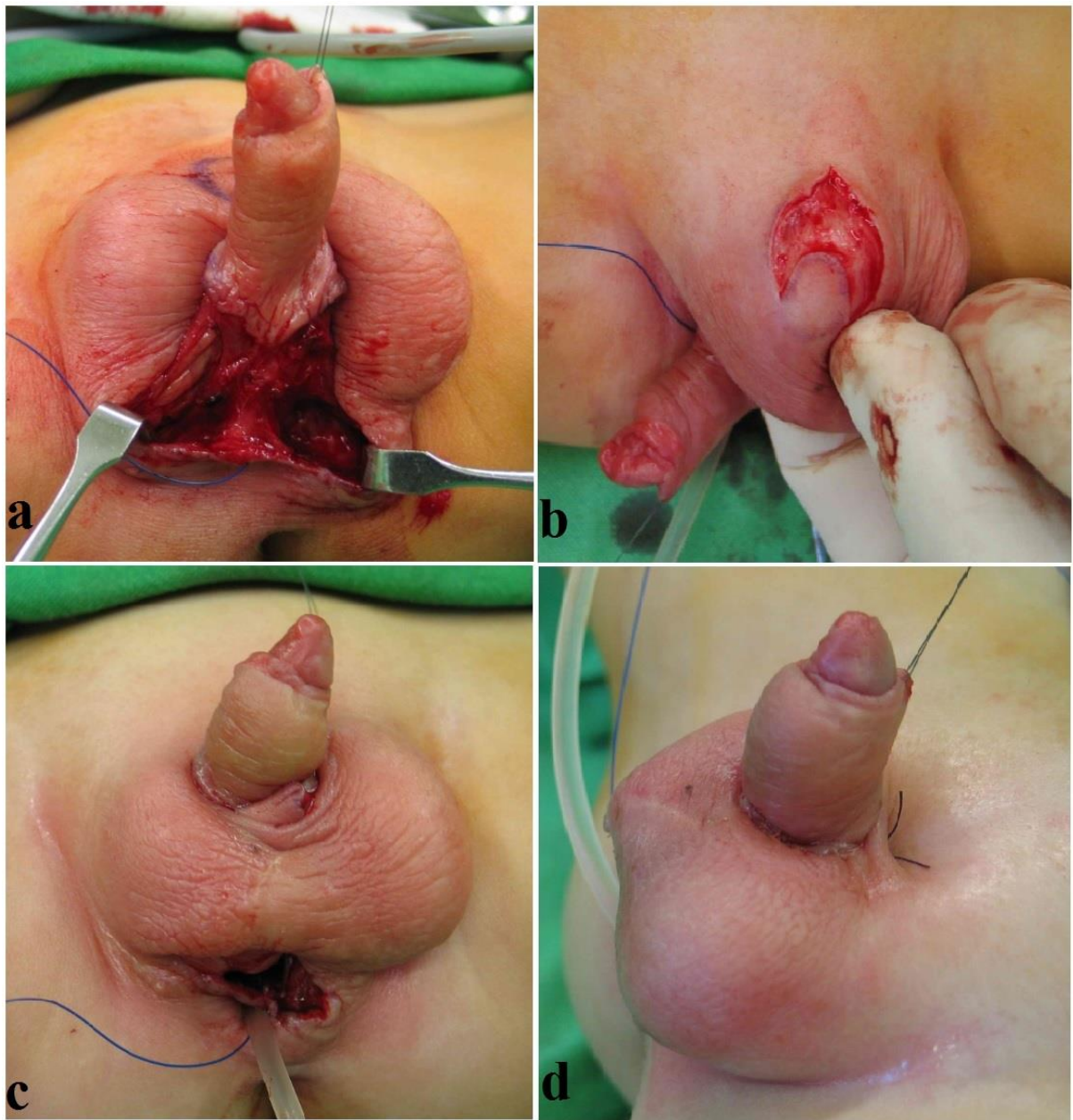
Stage1. Primary mobilization of the hypoplastic phallus at 8 months of age. Following penile denudation, only 1 corpus cavernosum noted, chordectomy performed and penis moved cephal to the scrotum (Fig. 18 a-d).





*Fig.18. Ectopic penis located in the perineum close to the anus (a), penile denudation, only 1 corpus cavernosum noted (b), proximal mobilization of penis (c), 4 month post-op result (d).*

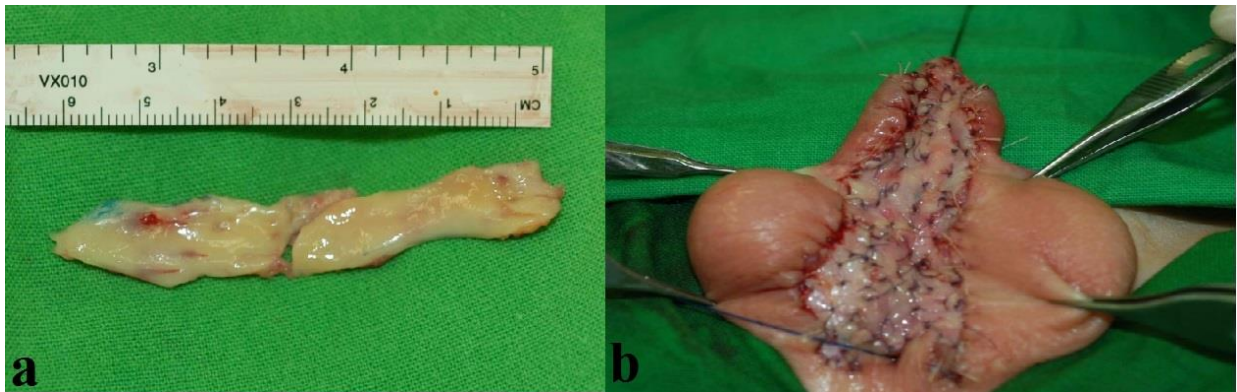Stage 2. Anteposition of the penis at the age of 1 year. The penis was further mobilised, and pulled through a button-hole to be placed cephal to scrotum (Fig.19 a-d).



*Fig.19. Anteposition of the penis. Further extended mobilization of penis (a), button-hole site prepared (b), penis pulled through (c) penis fixed at its new position (d).*

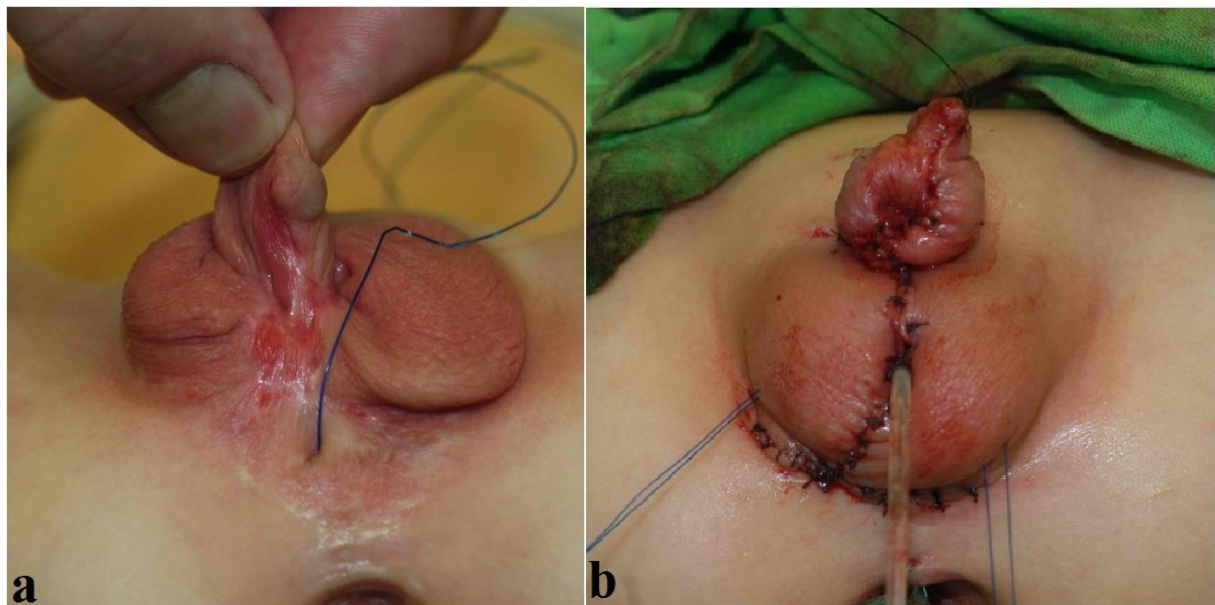


Stage 3. Urethral replacement with buccal mucosa at 18 months of age (Fig.20)



*Fig.20. harvested free buccal mucosal graft (a) and implanted (b).*

Stage 4. Partial urethroplasty at the age of 2 years (Fig.21).

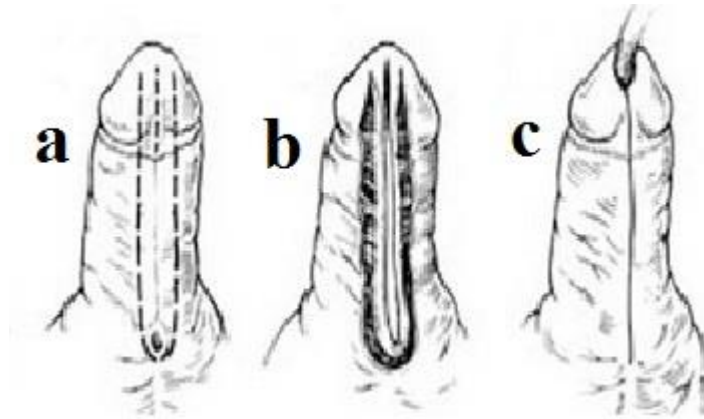


*Fig.21. a) healed buccal mucosal graft b) tubularised free graft.*

Stage 5. Further Thiersch-Duplay urethroplasty at the age of 4 years

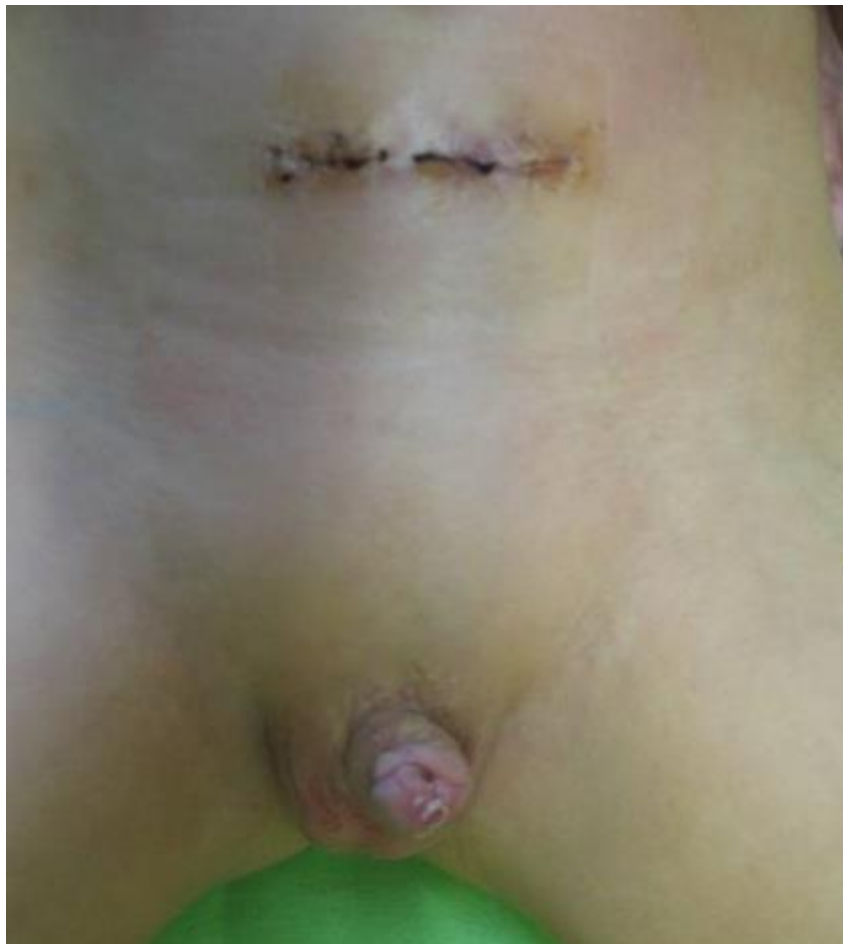The healed buccal mucosa was tubularised to bring the meatus to the glans (Fig. 22).





*Fig. 22.a) healed buccal mucosa marked, b) mobilization of the plate, c) tubularisation of the plate.*

Stage 6. Closure of vesicostomy at the age of 6 years (Fig. 23)



*Fig. 23. Post-vesicostomy closure.*

Postoperative urethral stricture managed by dilatation. Currently the child is 7 year-old, attending school, is dry (day and night) with complete urinary continent, good urinary sensation, erection and recurrent urinary tract infection . Uroflowmetry showed average single urine stream, with voided volume 87ml, and maximum ( $Q_{\max}$ ) and mean ( $Q_{\text{ave}}$ ) flow rate of 13 ml/s and 5ml/s respectively (Fig.24).



*Fig.24. Uroflowmetry showed good urine stream.*

### **5.6.3. Discussion**

Penoscrotal transposition is an uncommon abnormality of the external genitalia first reported by Appelby in 1923 (63). There are two form of penoscrotal transposition. In incomplete type which is more common, the penis lies in the bifid mid-scrotum. In complete transposition, which is very rare, the scrotum is not bifid and located cephal to penis, which emerges from the perineum (61).

The etiology of penoscrotal transposition is unknown. The genital tubercle and labioscrotal swellings are the embryological origins of penis and scrotum, respectively. During 4<sup>th</sup>-6<sup>th</sup> weeks of gestation the labioscrotal swellings migrate dorsally to their normal anatomic location under the influence of androgens. Several factors have been proposed leading to penoscrotal transposition, including defect of the androgen receptor, abnormality in

chromosome 13 and 18 or failure of normal developmental progression. Pinke et al reported 13% of a series of 53 patients to have familial penoscrotal transposition (64).

Patients with penoscrotal transposition often present with associated genital anomalies, including hypospadias and chordee. The renal defect in these patients is as high as 100% of reported cases (64), our case also had left crossed ectopic kidney. Other associated malformations include cardiac, imperforate anus, musculoskeletal and central nervous system. Bladder agenesis associated with penoscrotal transposition has also been reported (64).

Isolated penoscrotal transposition with bifid scrotum is usually performed as a single stage procedure. There are a number of surgical correction including reorienting the scrotum inferiorly with limited rotational flaps, inguinal based groin flap or transposing the penis superiorly (65, 66).

There is not any description of the technique for correction and results of severe cases of penoscrotal transposition associated with severe hypospadias. Our case was an extreme severe form of complete penoscrotal transposition where the ectopic penis with hypospadias and chordee was located in the perineum just cephal to normally located anus. We were unable to find any surgical technique in the literature. After consulting with a number of international pediatric surgeons/urologists expert on the anomalies of external genitalia, a multistage procedure was suggested for this rare case. It required a multistage procedure to step by step mobilize and advance the penis to its normal anatomical position. The severe chordee, single corpus cavernosum, long urethral gap were all had to be addressed and corrected in separate stages. The urethroplasty was performed using free buccal mucosal graft as in Bracka procedure (67) and ventral penile skin. The main steps of multistage surgery were performed in collaboration with Professor Sava Perovic of Belgrade in Pecs. Postoperative urethral stricture was managed initially by dilatation under general anesthesia followed by home self-dilatation.

A successful surgical correction of ectopic penis needs a well-planned multistage surgical procedure. Preoperatively the severity of penoscrotal transposition should be determined, associated anomalies (hypospadias, chordee, cryptorchidism, renal anomalies, etc) must be defined and intersexuality ought to be ruled out. Following completion of a multistage surgical repair of our case, the child has straight, slightly hypoplastic penis, with erection, urinary continent and satisfactory uroflow rate.

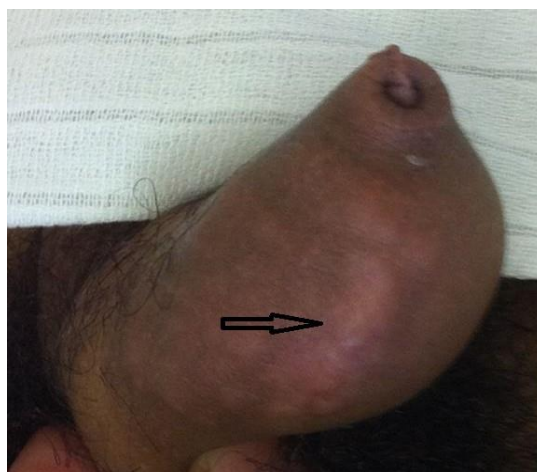## **5.7. PENILE GRANULOMA ANNULARE ASSOCIATED WITH URETHRAL ANOMALY (68)**

### **5.7.1. Introduction**

Granuloma annulare (GA) is an inflammatory, benign, uncommon disease of the dermis, usually involving the hands and feet, predominantly diagnosed in young females. The disease is characterized by focal degeneration of collagen with a surrounding area of reactive inflammation and fibrosis (69). Penile GA is remarkably rare, and an uncommon presentation of the disease. To the best of our knowledge, only 15 cases have been previously reported in the literature (70). Herein, we present a new case of penile GA associated with a urethral anomaly and review of the literature.

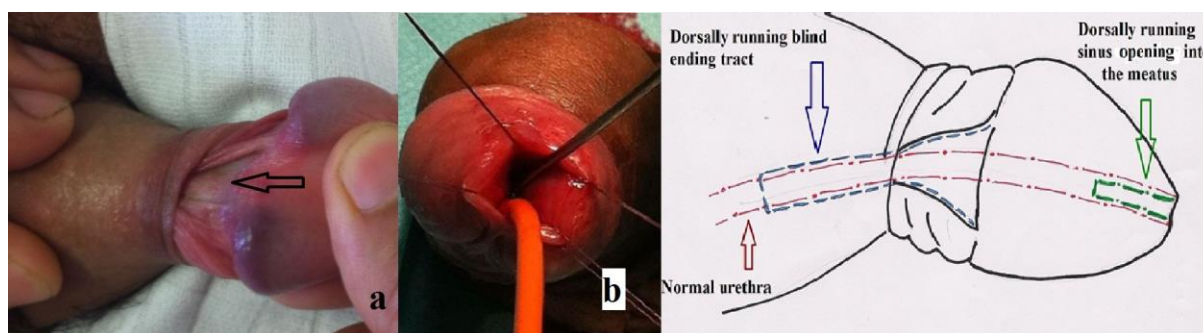
### **5.7.2. Case report**

A 15-year-old boy presented to our paediatric surgery clinic with 1 year history of asymptomatic penile nodules which progressively increased in number and size. His medical and family history was unremarkable. There was no history of trauma, allergy, diabetes or rheumatoid arthritis, and he did not have any urinary symptoms. Routine laboratory studies were normal. Physical examination revealed multiple pea-sized subcutaneous lesions largely on the left side of the penile shaft and limited to the distal 1/3 of foreskin. The lesions were neither painful nor pruritic and overlying skin was intact (Fig 25).



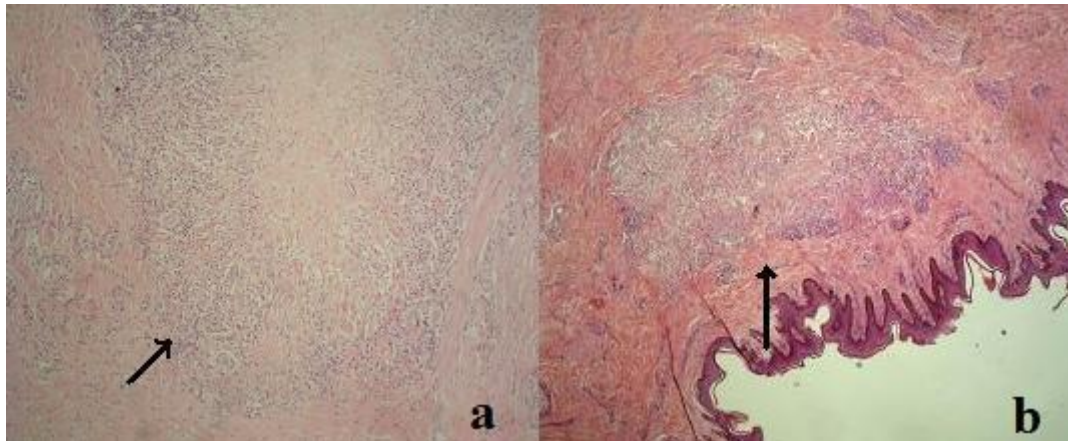
*Fig. 25. Multiple penile subcutaneous granuloma annulare nodules of varying size.*

The foreskin was extremely tight with a phimotic ring. After preputial retraction, a 2 cm blind ending tract was noted dorsally, running parallel with the normal urethra (Fig.26/a). At surgery, after exposing the normally located meatus, a 1 cm dorsal running sinus was found, which did not communicate with the dorsally located tract (Fig 26/b). The urethra was otherwise normal (Fig 26/c). Circumcision was performed together with removal of all penile lesions and the dorsally located tract. The blind ending sinus in the meatus was left intact as it did not interfere with normal micturition.



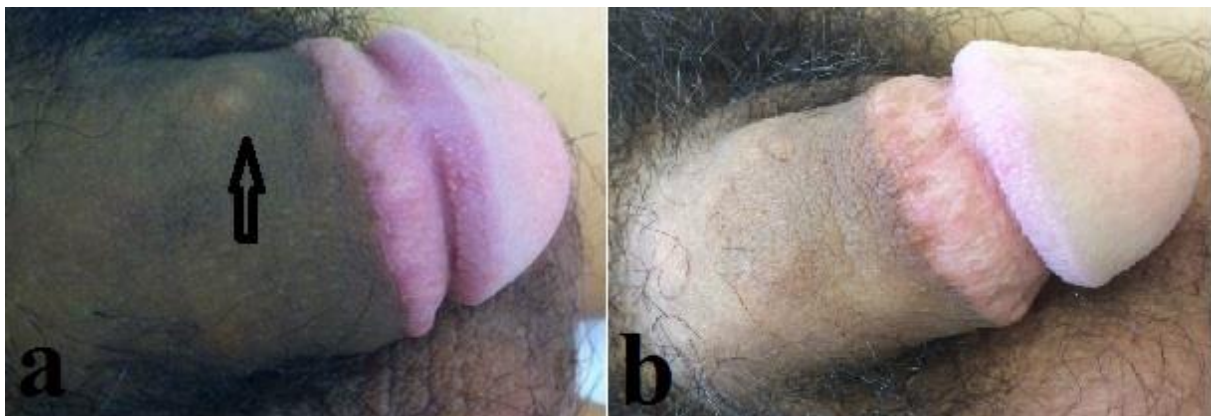*Fig. 26. a. Dorsally running blind-ending tract (arrow). b. Probe shows 1 cm long sinus running parallel to the normal urethra, marked by urethral catheter. c. Dorsal schematic drawing of the penis showing normal urethra, blind ending tract and the sinus opening in the meatus.*

Histological examination revealed granulomatous lesions with necrobiotic collagen fibers surrounded by palisading histiocytes, mucin and few giant cells. The features were consistent with subcutaneous granuloma annulare (Fig. 27).



*Fig.27. Histological examination showing subcutaneous granuloma annulare. a. Localized necrobiotic collagen fibers surrounded with histiocytes and rare giant cell. b. Palisaded granuloma (Haemotoxylin-eosin; magnification: a: 100x, b: 40x).*

At a three month post-operative follow-up, he presented with a new lesion on the penile shaft (Fig. 28 a). Considering the benign nature of subcutaneous GA and relatively high risk of recurrence, the patient and the parents were reassured and the decision made to continue follow-up without further treatment. The lesion spontaneously resolved 16 months post-operative period (Fig. 28 b).



*Fig. 28. Recurrence of subcutaneous granuloma lesion 3 months post-operatively (a) and spontaneous regression 16 months postoperatively (b).*

### **5.7.3. Discussion**

Subcutaneous GA of the penis is characterized by firm, non-tender, multiple nodules of varying diameters covered by normal coloured skin. There are four different clinical variants: localized, generalized, subcutaneous, and perforating forms, each with its characteristic clinical manifestation (69). The subcutaneous form is rare, and most commonly affects the skin of bony prominences, especially the anterior tibia, feet, hands, and occipital scalp of children under 5 years old (71). Granuloma annulare of the penis is very rare, with only 15 cases previously reported in the English medical literature (70).

.

The etiology of GA is unknown. However, a few factors such as primary necrobiosis, trauma, fungal, and viral infection are proposed as contributing factors. The disease process remains unclear, though there are four as yet unproven theories: vasculitis leading to necrotic changes, trauma induced necrobiosis, monocytic release of lysosomal enzymes, and type IV hypersensitivity reaction (70). As in our case, phimosis may increase the risk of infection and trauma associated with forceful foreskin retraction which contributed to the development of GA.

Histological findings in GA include degenerated collagen surrounded by palisading inflammatory cells, which are mostly histiocytes mixed with monocytes, possibly with few lymphocytes and fibroblasts (71).

Suggested treatments for GA are associated with varying degrees of success. These are steroids (intra-lesional injection, topical or systemic), and surgical removal. Localized trauma or diagnostic biopsy may initiate resolution of the lesions. Post-operative recurrence of GA at other sites in children occurs in up to 79% of reported cases. Kossard performed circumcision at the time of removal of GA nodules, in which case there was no recurrence 2 years post-surgery (72). In our case, a new nodule developed at 3 months after circumcision.

### **5.7.4. Conclusion**

Localized GA is an asymptomatic, self-limiting disease, and may resolve spontaneously within a few years. Penile subcutaneous GA is remarkably rare, and the lesions are



asymptomatic, therefore many patients may remain undiagnosed. Biopsy for accurate histological diagnosis is required. Familiarity with subcutaneous GA of the penis can prevent overtreatment. Patient reassurance and a non-invasive approach is advocated, aggressive surgical removal is unnecessary, except in selected cases related to concerns with cosmetic appearance or patient anxiety.

## **5.8. PRIAPISM IN CHILDREN (73)**

### **5.8.1. Introduction**

Priapism is a rare genito-urinary disease, particularly in childhood. It is defined as a long lasting pathological penile erection that is not associated with sexual desire and which does not subside after sexual intercourse or masturbation. There are two clinical subtypes described: low-flow (ischemic) or veno-occlusive priapism and high-flow (non-ischemic) priapism. Ischemic priapism is an emergency condition and needs immediate treatment. Whereas non-ischemic priapism is not an emergency however, close observation is mandatory. Erectile function remains preserved after an episode of high-flow priapism in most of the cases. However, in case of low-flow priapism erectile function and potency are dependent on prompt and adequate intervention (74).

### **5.8.2. Case reports**

#### **Case 1.**

12 year-old boy was admitted for penile erection lasted for 48 hours. Cavernosal blood aspiration and cavernosal dopamine injection at the local hospital proved unsuccessful. Emergency Winter-shunt was performed, but priapism returned within 24 hours. Re-do Winter-shunt was done which did not result in detumescence. Further conservative treatment with local ice-pack, analgesia and antibiotics lead to gradual improvement. The etiology



remained unknown. The patient was discharged 2 weeks later. At three months and later follow-up he remained asymptomatic, but he did not report any further erection.

#### Case 2.

A 7 year-old boy presented with history of 12 hours of painful erection. He denied any penoscrotal or spinal trauma, drug or alcohol ingestion. Examination revealed erectile but flexible penis. Colour Doppler ultrasound showed high-flow (14cm/sec) in the dorsal penile vein. The dorsal penile artery flow maintained but the cavernosal turbulence could not be detected. Complete blood count was normal, hematologic or urologic cause of priapism could not be revealed. Conservative management including compression, ice-pack, Non-steroid anti-inflammatory drug (NSAID) and antibiotic resulted in gradual improvement. Considering the age of the patient and expected spontaneous regression of priapism, arteriography, microembolization and surgery was not performed. His high-flow priapism resolved within few weeks. At follow-up his parents reported morning erection.

#### Case 3.

14 year-old boy developed priapism secondary to his treatment for chronic myeloid leukaemia. He presented with painful persisted erection. Complete blood count showed high WBC (419 G/l) suggesting the cause of priapism. He underwent emergency leukopheresis. His priapism persisted therefore cavernosal aspiration and dopamine (0.5 mg/ml) injection was done. It was ineffective that's why he underwent Winter-shunt which lead to gradual improvement of priapism. He was discharged after 12 days. He reported spontaneous erection during follow-up.

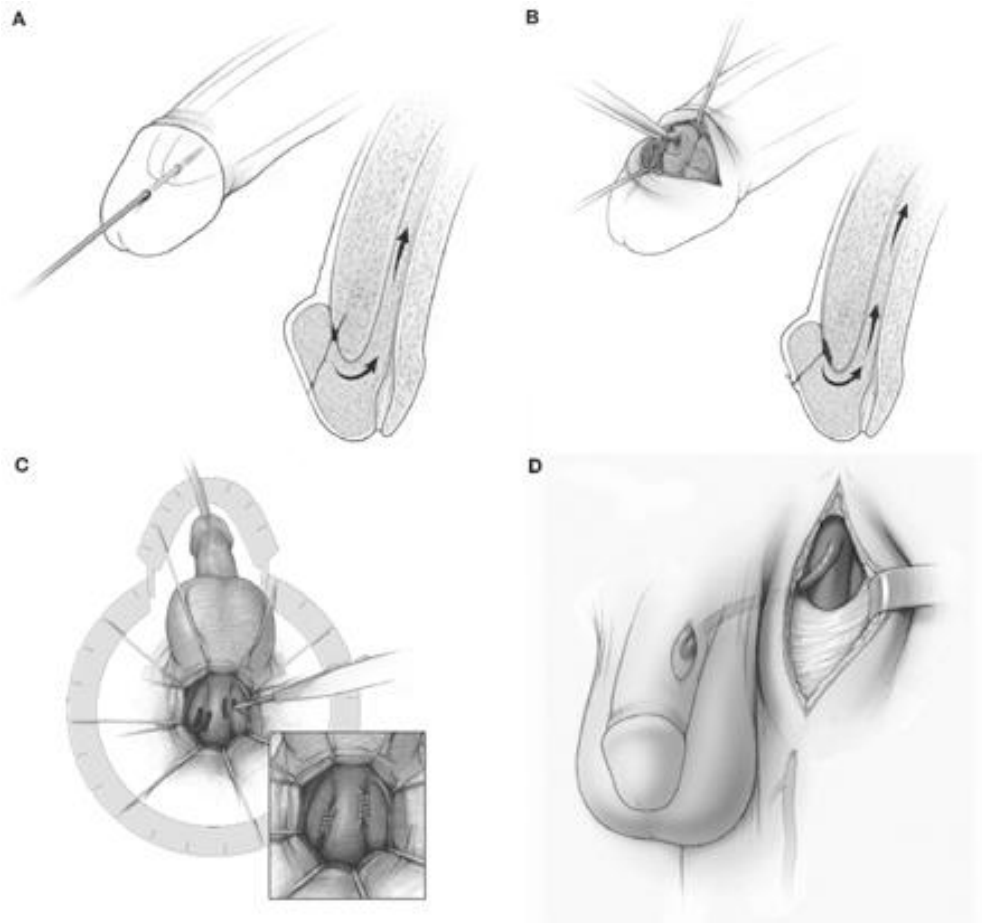
### 5.8.3. Discussion

The incidence of priapism is about 1–3/100 000. Intracavernosal pharmacotherapy and sickle cell disease are strong risk factors. Cause of priapism: 50% idiopathic, 20% medication and drug (cocaine, alcohol, painkillers, psychiatric drugs, anesthetics, anticonvulsants or antihypertensives) induced, 10-20% Sickle cell disease. Malignant neoplasm such as leukemia, and trauma to perineum 5-10 % can play a role in development of priapism. Age groups at special risk are children between 5–10 years (sickle cell disease) and men between 20–50 years (pharmacotherapy), but priapism can be possible at any age (75).

Priapism must be defined as either a low-flow (ischemic) or a high-flow (non-ischemic) type because the causes and treatments for these 2 types are different. Low-flow priapism is due to an excessive release of neurotransmitters, blockage of draining venules (veno-occlusive), paralysis of the intrinsic detumescence mechanism, or prolonged relaxation of the intracavernous smooth muscles (74). High-flow priapism, in contrast, is the result of uncontrolled arterial inflow from a fistula between the cavernosal artery and the corpus cavernosum. This is generally secondary to blunt or penetrating injury to the penis or perineum (75). Differentiation between these 2 types of priapism is accomplished by taking a thorough history, performing a careful physical examination, and measuring the oxygen content of blood within the corpora cavernosa by penile blood gas analysis.

Treatment of priapism is aspiration and irrigation of cavernosal tissue and injection of an alpha adrenergic agonist (76).

If conservative treatment of ischemic priapism fails, implementation of a surgical shunt (Fig. 29) between corpus spongiosum and corpus cavernosum is necessary immediately (77, 78)



*Fig. 29. (A) Winter and (B) El-Ghorab are cavernoglanular shunts (C) Quackels/Sacher and (D) Grayhack represent cavernovenosal shunts. (Burnett AL: Therapy insight: priapism associated with hematologic dyscrasias. Nat Clin Pract Urol 2005, 2: 449–456).*

#### **5.8.4. Conclusion**

Priapism is a true urological emergency, and early intervention permits the best chance of functional recovery. Priapism must be defined as either a low flow (ischaemic) or a high flow (non-ischaemic) type because the treatments and outcomes for these two types are significantly different.

## **5.9. POSTERIOR CLOACA WITH ACCESSORY URETHRA (79)**

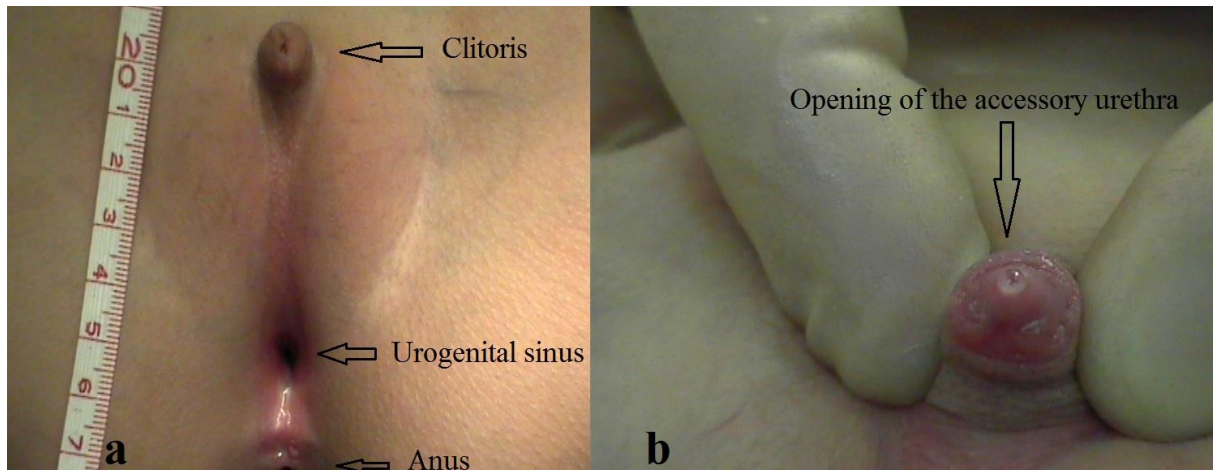
### **5.9.1. Introduction**

The cloaca malformation is a complex form of imperforate anus where the rectum, vagina and bladder open as a common channel in the perineum. As described by Pena the posterior cloaca is variant of cloaca malformation in which the urethra and vagina are fused, forming a urogenital sinus that deviates posteriorly to open in the anterior rectal wall or immediately anterior to the anus (80). The posterior cloaca occasionally is associated with an accessory urethra in the form of a filiform channel or sinus that connect the bladder or urethra to the perineum. The most important characteristic of the posterior cloaca is the high frequency of a normal anus, which differentiates this malformation from the classic cloaca. Often, many associated malformations are present and therefore should be suspected and diagnosed. The main goal during the operation is not to mobilize the anus and thereby preserve the anal canal (81).

### **5.9.2. Case report**

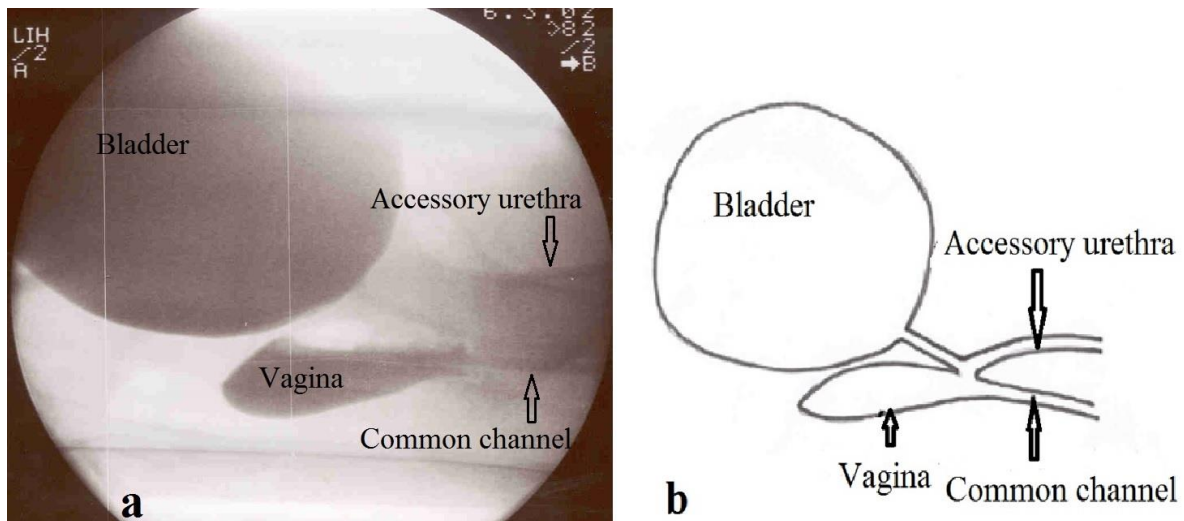
We report an 8 year-old girl with atypical urogenital sinus (UGS). At birth she was noted to have abnormal genitalia and enlarged clitoris, her karyotype was 46XX and adrenogenital syndrome was ruled out. She had associated spinal and cardiac anomaly requiring surgical correction at 1 and 4 years of age. She had been followed up by nephrology team for recurrent urinary tract infection. Ultrasound and pelvic MRI showed normal ovaries.

Examination under anaesthesia revealed normally located anus, just anterior to it a single opening noted (the UGS), clitoris was enlarged with a meatus-like opening at its tip few drops of urine passed through it. Proximal to the UGS the labia major were fused up to the enlarged clitoris (Fig. 30).



*Fig.30. (a) Normally located anus and (b) urogenital sinus hypertrophied clitoris with accessory urethral opening.*

Genitogram showed 2-3 cm long common channel (UGS), bladder and vagina. The accessory urethra (male urethra) joined the common channel just at the bifurcation of vagina and urethra (female urethra) (Fig 31).



*Fig.31. (a) Genitogram image and (b) schematic drawing showing bladder, vagina, common channel (urogenital sinus) and accessory urethra.*

Total Urogenital Mobilisation (TUM) was performed. The 3 cm long UGS (common channel) was mobilised and brought to the perineum, Y-V vaginoplasty performed to form an

appropriate vaginal opening. The clitoris mobilised caudally and placed closer to the urethral orifice. The accessory urethra (male urethra) closed by electrocauterisation of its uroepithelium.

Postoperative course was uneventful, at 18 months follow up she remained urinary continence without any further urinary tract infection and normal female genital appearance (Fig. 32).

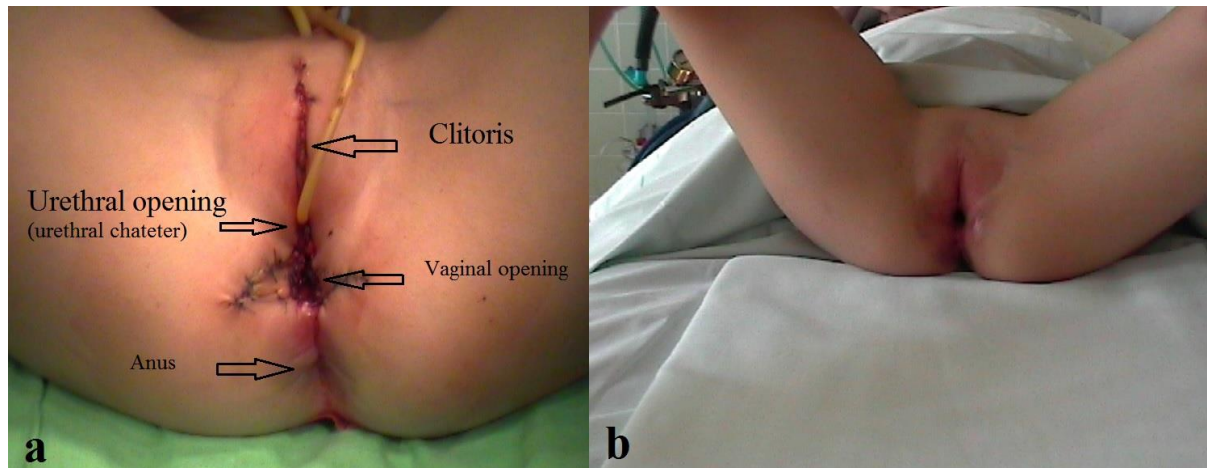
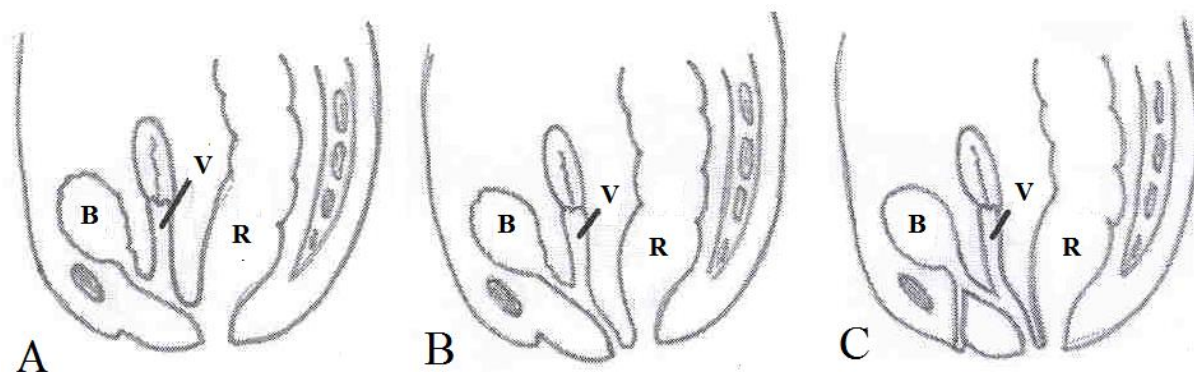


Fig. 32. (a) Immediate and (b) 1 year post-operative result.

### 5.9.3. Discussion

Pena and Kessler created term *posterior cloaca* to emphasize the fact that the UGS opening is located posteriorly next to normal anus or into the rectum (80).

Three anatomic variants of this defect were described (Fig.33). Type A, the UGS opens into the anterior rectal wall or into the anus. Type B, the UGS opens into the perineum immediately anterior to the anus. Type C, the UGS opens either in the rectum or the perineum and there is a rudimentary urethral opening at the tip of a pseudophallus (clitoris hypertrophy) (82).



*Fig.33. Three variant of posterior cloaca (R-Rectum, V-Vagina, B-Bladder)*

The initial diagnosis can be missed, because in some cases the external genitalia look almost normal. Only after manually separating the labia major, one can realise that there is no urethra and no vaginal opening. Posterior cloaca is associated with a wide spectrum of complex anatomic abnormalities involving urinary, spinal, genital and gastrointestinal tract systems, dominated by urologic anomalies. Beside spinal and sacral involvement our patient had cardiac anomaly requiring repeated operation. According to Pena and Kessler posterior cloaca is repaired by Total Urogenital Mobilization (TUM) through posterior transanorectal approach without mobilizing or dissecting the rectum. As the rectum has a normal sphincter mechanism, these patients are expected to have normal bowel control (80). Krstic et al treated 2 posterior cloaca patients with TUM by perineal approach without opening the rectum (82). We also agree that in older age and shorter common channel posterior cloaca can be repaired by perineal approach and TUM as in our case.

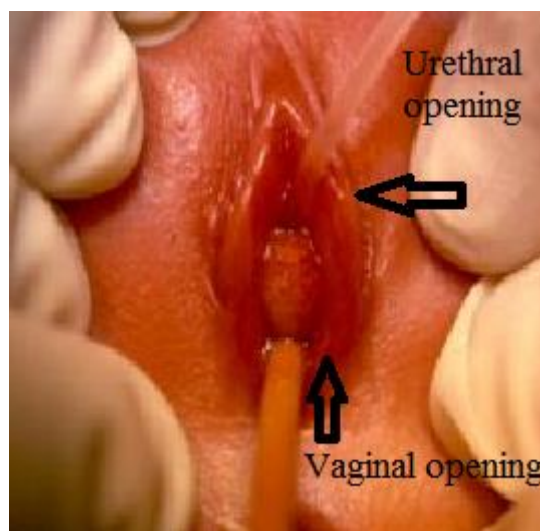
#### **5.9.4. Conclusion**

Posterior cloaca is a unique defect. The UGS opens into or just anterior to normally located anus and rectum. Diagnosis requires meticulous physical examination followed by radiourologic evaluation. During the repair of these defects by TUM approach of UGS the rectum must remain intact. Since the rectum is located normally and within the limit of the sphincteric mechanism, provided that sacrum is normal almost all of these patients are expected to have normal bowel control as it observed in our case.

## 5.10. PARAURETHRAL CYSTS IN FEMALE NEONATES (83)

### 5.10.1. Introduction

Paraurethral or Skene's duct cysts are rare congenital abnormality of female neonate, characterised by round, yellow or orange coloured cystic mass on either side of the urethra meatus (Fig. 34). The origin of the congenital cysts adjacent to the urethral orifice is thought to be the result of Skene's duct obstruction, which leads to cyst formation (84, 85). Characteristic paraurethral cysts are asymptomatic non-tender soft cystic ovoid masses approximately 6-10 mm in diameter yellowish in colour located on either side of the urethral meatus. Skene's duct cysts are usually single, however bilateral Skene's duct cysts have been reported (83).



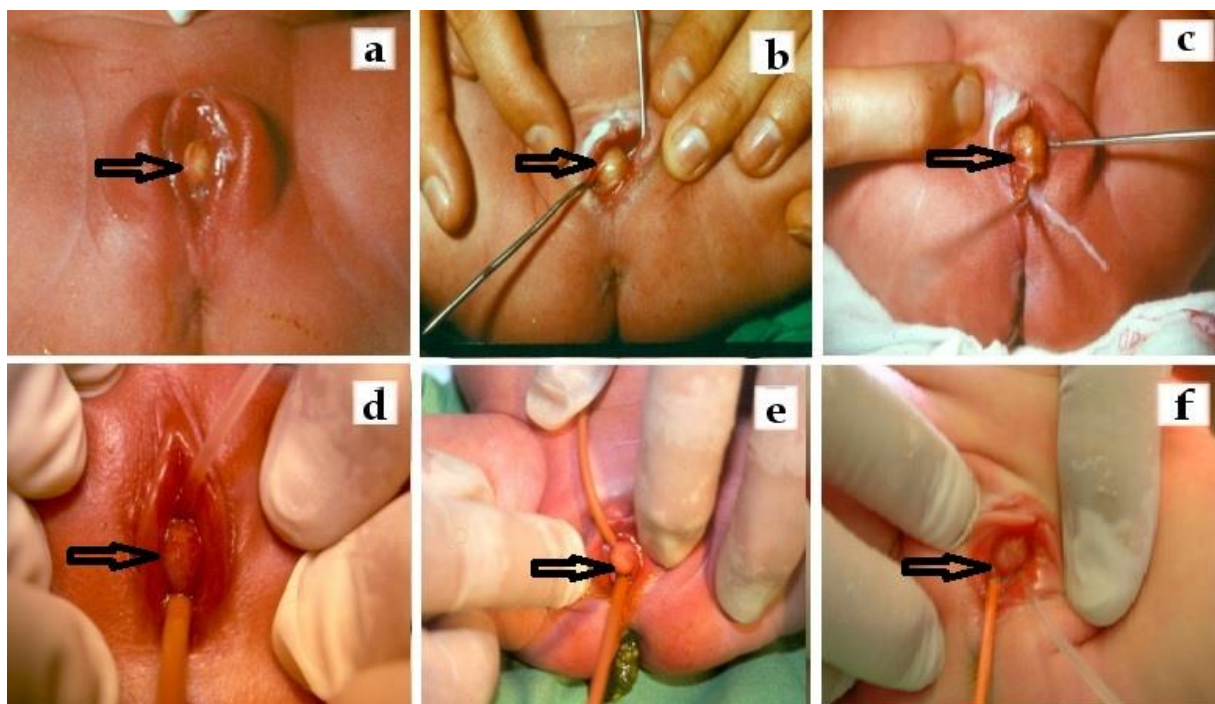
*Fig. 34. Paraurethral cyst, catheter shows the urethral opening.*

### 5.10.2. Case reports

Over 17 years period we treated 6 cases of paraurethral cysts in our unit. All patients were full-term and natural vaginal deliveries with normal body weights without any other associated anomalies. The lesions were discovered accidentally by the mother or by the paediatrician. The main symptom was of lateral deviation of the urinary stream. On physical



examination, all neonates had a non-tender soft yellowish mass on the posterior aspect of the urethral orifice predominantly right sided. Although the cysts seemingly obscured both the urethra and the vagina, there were no clinical symptoms of urinary retention. Probing revealed patent urethral and vaginal openings (Fig 35). Incision of the cyst in the first 4 cases and unroofing of the cyst, in the last 2 patients were performed. All patients healed without complication and no sign of recurrent cyst formation was observed in any of our patients on follow up. Histological examination of the latter showed stratified squamous epithelium with limited area of transitional epithelium lining.



*Fig. 35. (a-f) Ovoid yellow protruded paraurethral cyst in 6 patients'.*

### 5.10.3. Discussion

Paraurethral cysts arise from the periurethral glands and ducts that empty into the female urethra and are rudimentary homologues of the prostate. There are between 6 and 30 paraurethral ducts as demonstrated by Huffman (86). The 2 largest ducts commonly are referred to as Skene's ducts (85). Skene's glands are well developed in the foetus and small

child and do not change noticeably with adolescence. The exact aetiology of paraurethral cysts is unknown, however obstruction of Skene's duct by infection or inflammation has been postulated (87). The diagnosis of paraurethral cysts can be made by physical examination. Renal ultrasonography and further urological investigation is mandatory in case of urinary outflow obstruction. Differential diagnosis includes other interlabial masses such as prolapsed ectopic ureterocele, prolapsed urethra, imperforate hymen and rhabdomyosarcoma of the vagina (84).

Although the reported incidence of the lesion is between 1 in 2000 and 1 in 7000 live female births, only 41 examples have been reported in literature. Merlob et al reported 6 cases in 3026 female neonates (88) and Lee et al published 1 case in 2074 female new born (87). These observations would suggest that the exact incidence of paraurethral cyst is expected to be much higher than the reported figures.

All our 6 cases of Skene's duct cysts had the classical characteristic morphological and clinical findings of paraurethral cysts, incision and unroofing of the cysts was successfully performed.

There is no consensus on the treatment of paraurethral cysts, needle aspiration, excision or marsupialization all have been reported to be equally successful. Herek et al reported 1 case of a paraurethral cyst that resolved spontaneously (89). We successfully treated all our patients by incision and unroofing of the cysts. However, considering the fact that paraurethral cysts are asymptomatic lesions in nature and spontaneous resolution is quite likely, initial conservative approach is advisable in asymptomatic cases.

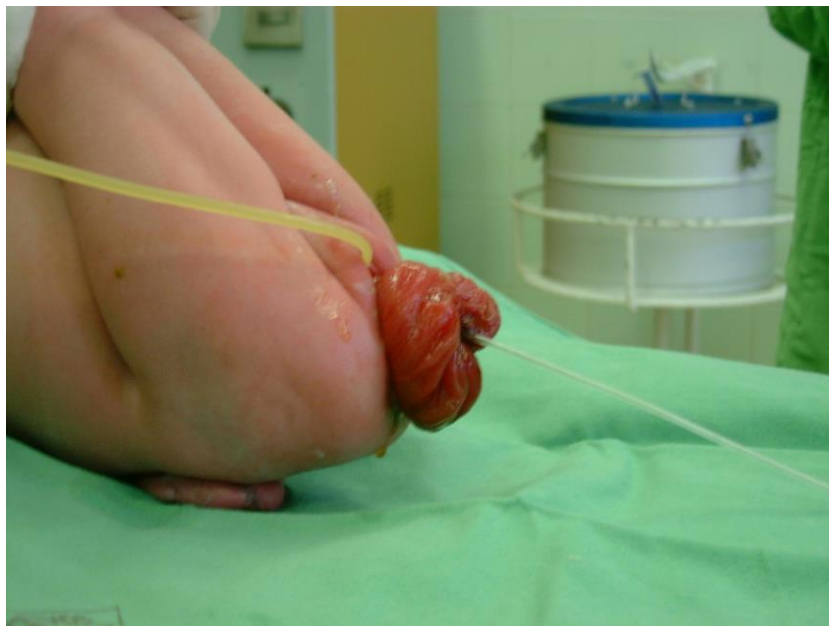## **5.11. SEMICONSERVATIVE MANAGEMENT OF NEONATAL VAGINAL PROLAPSE (90)**

### **5.11.1. Introduction**

Neonatal genital prolapse is a rare condition, more than 80% of cases are associated with congenital spinal cord malformation (91). Several conservative and surgical treatments have been advocated. We report a neonatal total vaginal prolapse in a spina bifida baby treated successfully and permanently by partial labial fusion.

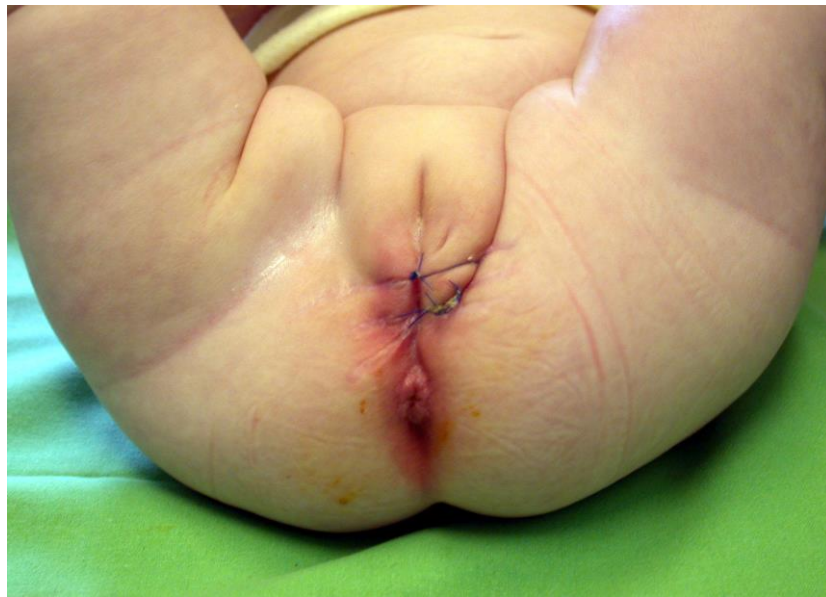### **5.11.2. Case report**

A full term 3100 g female baby was born by caesarean section to a 30-year-old, gravida 2 mother. The history and the obstetric course were unremarkable. At delivery, she presented with ruptured lumbosacral meningocele. Thorough physical examination revealed ruptured meningocele, paraplegia with bilateral clubbed feet, urinary and faecal incontinence, hydrocephalus and recurrent total vaginal prolapse (Fig. 36).



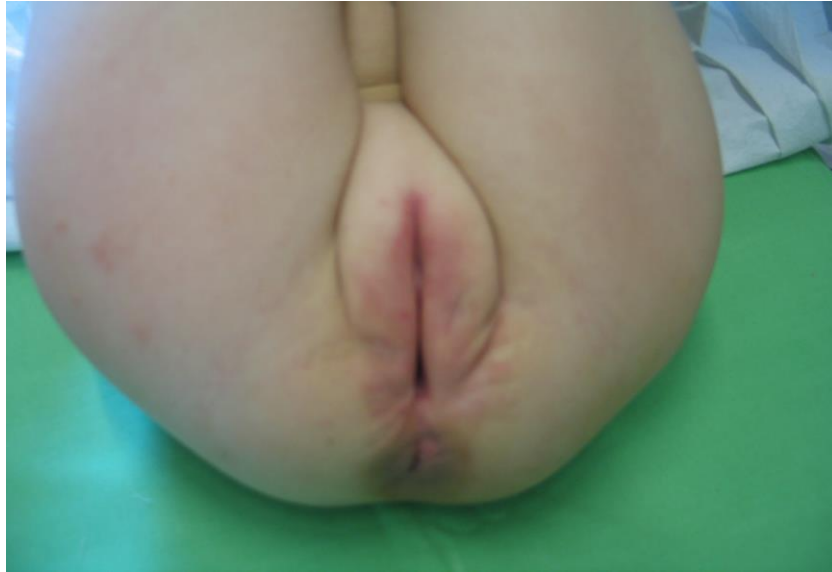*Fig. 36. Total vaginal prolapse with lumbosacral meningocele. Indwelling bladder catheter (yellow) and a catheter passed into the vagina (white) can be seen.*

The urethral orifice was normal. Radiological investigation (spine X-ray, brain USS and CT) showed wide spinal bony defect from L2 to sacral segment and marked symmetrical ventricular dilatation. The meningocele closed on day 2 and later ventriculo-peritoneal shunt inserted for her hydrocephalus. Total vaginal prolapse subsequently lead to urinary retention requiring indwelling bladder catheter. On day 4, the vaginal prolapse was reduced under general anaesthesia and the labia majora were partially fused with 2 interrupted 2.0 Prolene (non-absorbable) sutures (Fig. 37).



*Fig. 37. Two weeks after labial fusion.*

The urinary catheter removed after 2 weeks and the sutures left in place for 2 months. No further vaginal prolapse noted during 18 months of follow up (Fig. 38).



*Fig. 38. Three years follow up, normal looking external genitalia.*

### **5.11.3. Discussion**

Neonatal genital prolapse is a rare condition usually occurs in association with spina bifida (meningomyelocele and spina bifida occulta). In 1917 Findley suggested that 85% of neonatal genital prolapse are associated with congenital abnormalities of the spine, leading to pelvic floor weakness as a consequence of disturbed sacral innervations (92). However neonatal genital prolapse can also occur in the absence of underlying spinal defect, such as prolonged labor with a breech-presenting fetus or intrapartum trauma (93). Malpas subdivided neonatal genital prolapse into primary and secondary with spinal malformation and abnormal stress respectively (94).

Differential diagnosis of neonatal intralabial mass includes vaginal polyps, urethral prolapse, paraurethral cysts and rhabdomyosarcoma. Treatment modalities should be tailored to the severity of genital prolapse. In mild forms conservative treatment is advocated such as single or repeated digital reduction, use of hypertonic saline pads, vaginal pessary and insertion of Foley catheter into vagina (95). Surgical intervention indicated if the conservative treatment fails such as recurrent prolapse in spite of repeated reduction, evidence of vaginal mucosal ulceration or hypertrophy and urethral orifice obstruction. Several operative methods

including uterine ventrosuspension, sling or sacral cervicopexy have been described (91). Ajabor et al in 1976 reported partial labial fusion following decompression of local oedema with application of hypertonic saline pads (96). We used a new unique technique for the treatment of total vaginal prolapse in our case. Following failed repeated digital reduction and morbidity of urinary retention, partial labial fusion performed as a semi-conservative treatment which proved to be a successful and permanent method for management of this condition.

## **6. THESIS RELATED NOVEL OBSERVATIONS**

### **6.1. Successful surgical correction of an extreme severe form of ectopic penis**

Complete penoscrotal transposition is a rare anomaly of the external genitalia, characterized by malposition of the penis in relation to the scrotum. In complete and severe penoscrotal transposition as in our case, the penis located caudal to the scrotum, emerges from the perineum in an ectopic position. To our knowledge this is the first successful surgical repair of very severe form of ectopic penis. The surgical correction of extreme severe form of ectopic penis needs multi-stage surgical procedure possibly with international collaboration.

### **6.2. Dribbling diversion in Y-V glanuloplasty modified Mathieu repair**

The role of catheter and stent placement for urinary diversion in Mathieu distal hypospadias repair remains debatable. To overcome painful and distressful postoperative voiding, a small calibre indwelling transurethral catheter can be used as a dribbling diversion for 24-48 hours. This provides postoperative drainage and due to small calibre and short period would reduce classic catheter related morbidities.

### **6.3. Congenital posterior urethral polyp**

Congenital urethral polyps are rare, benign anomalies arising from the verumontanum, presenting as an acute or intermittent subvesical urinary retention. Posterior urethral polyps can be treated by transurethral endoscopic resection or suprapubic open excision.

#### **6.4. Penile granuloma annulare associated with urethral anomaly**

Penile subcutaneous granuloma annulare is remarkably rare, it is a self-limiting disease. The lesions are asymptomatic and resolves spontaneously. Aggressive surgical excision is unnecessary, a non-invasive approach is advocated.

#### **6.5. Paraurethral cyst in female neonates**

Paraurethral cysts originating from Skene's duct obstruction are rare congenital abnormality in the female neonate. It is an asymptomatic lesion resolves spontaneously. Therefore surgical treatment such as needle aspiration, or marsupialization is unnecessary.

#### **6.6. Semiconservative management of neonatal vaginal prolapse**

Congenital vaginal prolapse is a rare condition occurring in neonates and is usually associated with spinal cord malformations in about 80% of cases. Conservative treatment in the form of simple digital reduction, usage of a pessary or insertion of Foley catheter is usually sufficient to treat this condition. However, if the conservative treatment methods failed, partial labial fusion as a semiconservative minimal invasive management of neonatal vaginal prolapse should be considered before deciding radical invasive surgery .



## 7. REFERENCES

1. Sandberg DE, Meyer-Bahlburg MFL, et al.: Boys with hypospadias: a survey of behavioural difficulties. *J Pediatr Psychol.* 1989; 14:491-514
2. Mouriquand PDE, Persad R, Sharma S: Hypospadias repair: current principles and procedures. *Br J Urol* 1995; 76 (Suppl 3):9-22
3. Wilcox D, Snodgrass W: Long-term outcome following hypospadias repair. *World J Urol* 2006; 24(3): 240-243
4. Manzoni G, Bracka A, Palminteri E, Marrocco G: Hypospadias surgery: when, what and by whom? *BJU Int* 2004; 94:1188-95
5. Marshall FF: Embryology of the lower genitourinary tract. *Urol Clin North Am.* 1978; 5:3-15
6. Levine R: Urethral cancer. *Cancer* 45(suppl 7):1965-1972, 1980
7. [www.theodora.com/anatomy/the\\_male\\_urethra.html](http://www.theodora.com/anatomy/the_male_urethra.html)
8. [www.theodora.com/anatomy/the\\_female\\_urethra.html](http://www.theodora.com/anatomy/the_female_urethra.html)
9. Upadhyay J, Angel CA: Urethral anomalies and urethral prolapse. [emedicine.medscape.com/article/1015912-overview](http://emedicine.medscape.com/article/1015912-overview)
10. Mouriquand PDE, Mure PY: Hypospadias. In: Gearhart JP, Mouriquand PDE, Rink R (eds) *Pediatric urology*. Saunders, Philadelphia, pp 713-728; 2001
11. Smith ED: The history of hypospadias. *Pediatr Surg Int* 1997; 12: 81-85
12. Mathieu, P.: Traitement en un temps de l'hypospadias balanique et juxtabalanique. *J. Chir* 1932; 39: 481
13. Kallen B, Bertollini R, Castilla E, et al.: A joint international study on the epidemiology of hypospadias. *Acta Paediatr Scand Suppl.* 1986; 324:1-52
14. Gatti JM, Krisch AJ, Snyder HM: Hypospadias. [emedicine.medscape.com/article/1015227-overview](http://emedicine.medscape.com/article/1015227-overview)

15. Anatomical studies of the fibroblast growth factor-10 mutant, Sonic Hedge Hog mutant and androgen receptor mutant mouse genital tubercle. *Adv Exp Med Biol* 545,123-48
16. Leipoldt, M., Erdel, M., Bien-Willner, et al.: Two novel translocation breakpoints upstream of SOX9 define borders of the proximal and distal breakpoint cluster region in campomelic dysplasia. *Clin Genet* 2007; 71: 67-75
17. Ocal, G., Adiyaman, P., Berberoglu, M., et al.: Mutations of the 5alpha-steroid reductase type 2 gene in six Turkish patients from unrelated families and a large pedigree of an isolated Turkish village. *J Pediatr Endocrinol Metab* 2002; 15: 411-21
18. Kaspar, F., Cato, A.C., Denninger, A., et al.: Characterization of two point mutations in the androgen receptor gene of patients with perineoscrotal hypospadias. *J Steroid Biochem Mol Biol* 1993; 47: 127-35
19. Aaronson IA, Cakmak MA, Key LL: Defects of the testosterone biosynthetic pathway in boys with hypospadias. *J Urol.* May 1997; 157:1884-8
20. Skakkebaek NE, Rajpert-De Meyts E, Main KM. Testicular dysgenesis syndrome: an increasingly common developmental disorder with environmental aspects. *Human Reproduction* 2001 **16** 972–978)
21. Khuri FJ, Hardy BE, Churchill BM: Urologic anomalies associated with hypospadias. *Urol Clin North Am.* Oct 1981; 8:565-71
22. Kaefer M, Diamond D, Hendren WH, Vemulapalli S, et al.: The incidence of intersexuality in children with cryptorchidism and hypospadias: stratification based on gonadal palpability and meatal position. *J Urol* 1999; 162:1003-6; discussion 1006-7
23. Barcat J: Current concepts in of treatment. In: Horton CE, ed. *Plastic and Reconstructive Surgery of the Genital Area*. Boston, Mass: Little Brown; 1973:249-62
24. Duckett JW: The current hype in hypospadiology. *Br J Urol.* 1995; 76 [Supp 3]:1-7
25. Erol A, Baskin L, Li YW et al.: Anatomical studies of the urethral plate: why preservation of urethral plate is important in hypospadias repair. *BJU Int* 2000; 85:728-734

26. Culp OS, McRoberts JW: Hypospadias. In Alken CE, Dix VW, Goodwin WE, et al, Encyclopedia of Urology, New York, Springer 1968: 11: 307-344
27. Tsur H, Shafir R, Shachar J: Microphallic hypospadias: testosterone therapy prior to surgical repair.Br J Plast Surg 1983; 36:398–400
28. Pinter A: Hypospadiasis sebészete a korai életkorban. Magyar Urologia 2001 XIII. Évfolyam, 2. Szám
29. K. Fathi, T. Tsang: A technique for applying a non-adherent, tri-laminate dressing for hypospadias repair. Ann R Coll Surg 164 Engl 2009; 91: 161–170
30. Kajbafzadeh AM, Yazdi CA, Rouhi O, Tajik P and Mohseni P: Uroflowmetry nomogram in Iranian children aged 7 to 14 years. BMC Urology 2005, 5:3
31. Toguri AG, Uchida T, Bee DE: Pediatric uroflow nomograms. J Urol 1982; 127:27-31
32. Fathi K, Vastyan A., Pinter A: Meatal stenosis after tubularized incised urethroplasty. Magyar Urologia 2006; 4: 207-210
33. Snodgrass WT. Tubularized incised plate urethroplasty for distal hypospadias. J Urol 1994; 151: 464-465
34. Gürdal M, Tekin A, et al. Intermediate-term functional and cosmetic results of the Snodgrass procedure in distal and midpenile hypospadias. Pediatr Surg Int 2004; 20: 197-199
35. Stehr M, Lehner M, et al. Tubularized incised plate (TIP) urethroplasty (Snodgrass) in primary hypospadias repair. Eur J Pediatr Surg 2005; 15: 420-424
36. Lorenzo AJ, Snodgrass WT. Regular dilatation is unnecessary after tubularized incised-plate hypospadias repair. BJU Int 2002; 89: 94-97
37. Snodgrass W. TIP urethroplasty: new directions in distal hypospadias repair. Contemp Urol 2001; 9: 28-42

38. Hadidi AT: Y-V glanuloplasty; A new modification in the surgery of hypospadias. Kasr El Aini Med J 1996; 2: 223-233
39. K Fathi, A Pinter: Dribbling diversion in Y-V glanuloplasty modified Mathieu repair.. Eur J Pediatr Surg 2009; 19: 87-9
40. Boddy SA, Samuel M: A natural glanular meatus after “Mathieu and V incision sutured” MAVIS. BJU Int. 2000; 86:394-397
41. Rabinowitz, R.: Outpatient catheterless modified Mathieu hypospadias repair. J. Urol 1987; 138: 1074-2143
42. Samuel Hakeem et al.: Outcome analysis of the modified Mathieu hypospadias repair: Comparison of stented and unstented repairs : J Urol 1996; 156: 836-8
43. Buson, H., Smiley, D., Reinberg, Y. and Gonzalez, R.: Distal hypospadias repair without stents: is it better? J. Urol 1994; 151: 1059
44. Fathi K, Vastyán A., Pinter A. Snodgrass és módosított Mathieu húgycsőképző-műtét összehasonlító vizsgálata - saját beteganyag és irodalmi áttekintés. Magyar Urológia 2013, 4:171-4
45. Duckett JW. Hypospadias. . In: Walsh PC, Retik AB, Stamey TA, Vaughan ED Jr, et al, editors. Campbell’s urology. 7<sup>th</sup> ed. Philadelphia: WB Saunders; 1998. p.2093-119
46. Oswald J, Komer LI, Riccabona M: Comparison of the perimeatal-based flap (Mathieu) and tubularized incised-plate urethroplasty (Snodgrass) in primary distal hypospadias. Br J Urol Int 2000; 85:725-727
47. Snodgrass WT. Tubularised incised plate hypospadias repair: Indications, techniques and complications. Urology 1999; 54:6-11
48. Snodgrass W: Suture tracts after hypospadias surgery. BJU Int. 1999; 84:843-4
49. Snodgrass W: Does tubularised incised urethral plate hypospadias repair create neourethral stricture? J Urol 1999; 162:1159-1161

50. Uemura S, Huston JM, Woodward AA, et al: Balanitis xerotica obliterans with urethral stricture after hypospadias repair. *Pediatr Surg Int.* 2000; 16:144-145
51. Tarek A., Porkoláb Z. Hypospadiasis újabb műtétechnikai megoldása : (Snodgrass) *Magyar Urológia* 1999; 3:259-262
52. Imamoglu MA, Bakirtas H. Comparison of two methods-Mathieu and Snodgrass-in hypospadias repair. *Urol Int.* 2003; 71:251-4
53. Moradi M, Moradi A, Ghaderpanah F. Comparison of Snodgrass and Mathieu surgical techniques in anterior distal shaft hypospadias repair. *Urol J.* 2005; 2:28-31
54. Kiss A, Nyirady P, Pirot L, Merksz M: Combined use of perimeatal based flap urethroplasty. *Eur J Pediatr Surg* 2003; 13:383-5
55. K. Fathi, A. Azmy, A. Howatson, R. Carachi: Congenital posterior urethral polyps in children. *Eur J Pediatr Surg* 2004; 14: 215-217
56. De Castro R, Campobasso P, Belloli G and Pavanello P: Solitary polyp of posterior urethra in children, *Eur J Pediatr Surg* 1993; 3: 92-96
57. Downs RA: Congenital polyps of the prostatic urethra: A review of the literature and report of two cases. *Br J Urol* 1970; 42:76-85
58. Kuppasami K, Moors DE: Fibrous polyp of the verumontanum. *Canad J Surg* 1968; 11:388-390
59. Tsuzuki T, Epstein JI. Fibroepithelial polyp of the lower urinary tract in adults. *Am J Surg Pathol* 2005; 29:460-6.
60. K. Fathi, S. Perovic, A. Pinter: Successful surgical correction of an extreme form of ectopic penis. *J Ped Urology* 2010; 6: 426-8
61. Perovic PS. Penoscrotal transposition. *Advanced Urologic Surgery. Third Edition.* 2005, pp 199-211
62. Kain R, Arulprakash S. Complete penoscrotal transposition. *Indian Pediatr* 2005; 42:718

63. Appleby LH. An unusual arrangement of the external genitalia. *Can Med Ass J* 1923; 13:514-6
64. Pinke LA, Rathbun SR, Husmann DA, Krame SA. Penoscrotal transposition: review of 53 patients. *J Urol* 2001; 166:1865-8
65. Glenn JF, Anderson EE. Surgical correction of incomplete penoscrotal transposition. *J Urol* 1973; 110:603-5
66. Perovic S, Vukadinovic. Penoscrotal transposition with hypospadias: 1-stage repair. *J Urol*. 1992; 148:1510-3
67. Bracka A. A versatile two-stage hypospadias repair. *Br J Plast Surg* 1995; 48:345-52
68. K. Fathi, F. Harangi, A. Kravjak, A. Pinter. Subcutaneous granuloma annulare of the penis associated with urethral anomaly. A case report and review of the literature. *Pediatric Dermatology* 2014; 31: No. 4 e100-e103
69. Dahl MV. Granuloma annulare. In: Fitzpatrick TB, Eisen AZ, Wolff K, et al, eds. *Dermatology in general medicine*. New York: McGraw-Hill, 1993:1187–91
70. Suarez Peñaranda JM, Aliste C. Granuloma Annulare of the Penis: A Uncommon Location for an Usual Disease. *AM J Dermatology* 2011;33:e44-e46
71. Sidwell RU, Green JS, Agnew K, et al. Subcutaneous granuloma annulare of the penis in 2 adolescents. *J Pediatr Surg*. 2005; 40:1329-1331
72. Kossard S, Collins AG, Wegman A, et al. Necrobiotic granulomas localised to the penis: a possible variant of subcutaneous granuloma annulare. *J Cutan Pathol* 1990; 17:101–4
73. Biró E. Pytel Á. Ottóffy Gábor Mohay G. Farkas A.: Priapismus - ritka gyermekurologiai kórkép. *Gyermekegyészet*, 2012; 63: (5) 251-253
74. Cherian J, Rao AR, Thwaini A, et al. Medical and surgical management of priapism *Postgrad Med J*. 2006; 82: 89-94

75. Jesus LE, Dekermacher S. Priapism in children: review of pathophysiology and treatment. *J Pediatr*. 2009; 85: 194-200.
76. Sandler G, Chennapragada SM, Soundappan SS, et al. Pediatric high-flow priapism and super-selective angiography - an Australian perspective. *J Pediatr Surg*. 2008; 43: 1898-1901
77. Tabibi A, Abdi H, Mahmoudnejad N. Erectile function and dysfunction following low flow priapism: a comparison of distal and proximal shunts. *Urol J*. 2010; 7: 174-177
78. Burnett AL. Therapy insight: priapism associated with hematologic dyscrasias. *Nat Clin Pract Urol* 2005; 2: 449–456
79. Fathi K, Davidovics S. Pinter A.: Posterior cloaca with accessory urethra. *Orv. Hetilap* 2005; 16: 753-755
80. Peña A., Kessler O.: Posterior cloaca: a unique defect. *J Pediatr Surg.*, 1998, 33:407-412
81. Pena A, Bischoff A, Breech L, et al. Posterior cloaca-further experience and guidelines for the treatment of an unusual anorectal malformation. *J Pediatr Surg* 2010; 45:1234-40
82. Krstic Z.D, Lukas M, Lukas R., et al.: Surgical treatment of cloaca anomalies. *Pediatr Surg Int.*, 2001, 17, 329-333
83. K. Fathi, A. Pinter: Paraurethral cysts in female neonates. Case reports. *Acta aediat* 2003; 92: 758-9
84. Bergner DM. Paraurethral cysts in the newborn. *South Med J* 1985; 78:749-750
85. Skene AJC. The anatomy and pathology of two important glands of the female urethra. *Am J Obstet* 1880; 13:265-270
86. Huffman JW. The detailed anatomy of the paraurethral ducts in the adult human female. *Am J Obstet Gynecol* 1975; 45:632-637
87. Lee NH, Kim SY. Skene's duct cysts in female newborns. *J Pediatr Surg* 1992; 27:15-17

88. Merlob P, Bahari C, Liban E, et al. Cysts of female external genitalia in the newborn infant. *Am J Obstet Gynecol* 1978; 13:607-610
89. Herek O, Ergin H, Karaduman D, Cetin O, et al. Paraurethral cysts in newborn: A case report and review of literature. *Eur J Pediatr Surg* 2000; 10:65-67
90. K. Fathi, A. Pinter: Semiconservative Management of Neonatal Vaginal Prolapse. *Journal of Pediatric Surgical Specialties* 2008; 2:40-41
91. Loret DeMola JR, Carpenter SE: Management of genital prolapse in neonates and young women. *Obstet Gynecol Surg* 1996; 51:253-260
92. Findley P: Prolapse of the uterus in nulliparous women. *Am J Obstet Dis Wom* 1917; 75:12-21
93. Fraser RD: A case of genital prolapse in a newborn baby. *BMJ* 1961; (5231):1011-1012
94. Malpas P: Genital prolapse-allied conditions, (Chepter 2). The etiology of genital prolapse. 1955. p. 31-38
95. Abdelsalam SE, Desouki NM, Abd alaal NA: Use of Foley catheter for management of neonatal genital prolapse: case report and review of the literature. *J Pediatr Surg* 2006; 41:449-452
96. Ajabor LN, Okojie SL: Genital prolapse in the newborn. *Int Surg* 1976; 61:496-497



## 8. PUBLICATIONS AND PRESENTATIONS

### 8.1. Publications related to the thesis

1. **K. Fathi**, A. Pinter: Paraurethral cysts in female neonates. Case reports. Acta Paediat 2003 92(6): 758-9 (IF<sub>2003</sub>: 1.128)
2. **K. Fathi**, A. Azmy, A. Howatson, R. Carachi: Congenital posterior urethral polyps in children. Eur J Pediatr Surg 2004; 14: 215-217 (F<sub>2004</sub>: 0.535)
3. Andrew B. Pinter, Peter Vajda, Tamas Kovesi and **Khaled Fathi**. Long Frenulum Leading to a Giant Preputial Sac Associated with Concealed Penis. Sacnd J Urol Nephrol 2004; 38: 186-187 (F<sub>2004</sub>: 0.743)
4. **Fathi K.** Davidovics S. Pinter A.: Posterior cloaca with accessory urethra. Orv. Hetilap 2005; 16: 753-755
5. **Fathi K.** Vastyan A. Pinter A.: Meatal stenosis after tubularized incised urethroplasty. Magyar Urologia 2006; 4: 207-210
6. **K Fathi**, AEE Burger, MS Kulkarni, AB Mathur: Duckett versus Bracka technique for proximal hypospadias repair: A single centre experience. Journal of Pediatric Surgical Specialities. 2008; 2(2):11-13
7. **K. Fathi**, A. Pinter: Semiconservative Management of Neonatal Vaginal Prolapse. Journal of Pediatric Surgical Specialties 2008; 2(3):40-41
8. **K Fathi**, A Pinter: Dribbling diversion in Y-V glanuloplasty modified Mathieu repair. Eur J Pediatr Surg 2009; 19: 87-9 (IF<sub>2009</sub>:0.743)
9. **K. Fathi**, T. Tsang: A technique for applying a non-adherent, tri-laminate dressing for hypospadias repair. Ann R Coll Surg 164 Engl 2009; 91: 161–170 (IF<sub>2009</sub>: 0.989)

10. **K. Fathi**, S. Perovic, A. Pinter: Successful surgical correction of an extreme form of ectopic penis. J Ped Urology 2010; 6: 426-8

11. **Fathi K.** Vastyan A. Pinter A.: Snodgrass és módosított Mathieu húgycsőképző-műtét összehasonlító vizsgálata - saját beteganyag és irodalmi áttekintés. Magyar Urológia 2013, 4:171-4

12. **K. Fathi**, F. Harangi, A. Kravjak, A. Pinter. Subcutaneous granuloma annulare of the penis associated with urethral anomaly. A case report and review of the literature. Pediatric Dermatology 2014; 31: No. 4 e100-e103 (IF<sub>2013</sub>: 1.041)

## **8.2. Presentation related to the thesis**

1. **K. Fathi**, A. Azmy, A. Howatson, R. Carachi. Congenital Posterior Urethral Polyps in Childhood. 5<sup>th</sup> European Congress of Paediatric Surgery- EUPSA. Tours, France, 2003

2. Z. Juhasz, **K. Fathi**. Serious form of Penile Transposition. Salzburg Philadelphia Seminar. Pediatric Urology. Schloss Leopoldskron, December 11-16, 2003 Salzburg, Austria, 2003

3. **K. Fathi**, A. Pinter. Meatal stenosis after tubularized incised urethroplasty. 7th Annual Congress of the European Paediatric Surgeons' Association (EUPSA), May 10-13, 2006 Maastricht-Netherlands

4. **K. Fathi**, Pinter A. Is stent still needed in Y-V glanuloplasty modified Mathieu hypospadias repair? 8<sup>th</sup> Annual Congress of the European Paediatric Surgeons' Association (EUPSA), May 16-19, 2007 Turin-Italy

5. **K. Fathi**, T. Tsang. A technique for applying Allevyn dressing for hypospadias repair. II World Congress on Hypospadias and Disorder of Sex Development. November 16-18, 2007 Rome-Italy

6. **K. Fathi**, AEE. Burger, MS. Kulkarni, AB. Mathur. Duckett versus Bracka technique for proximal hypospadias repair. A single centre experience. II World Congress on Hypospadias and Disorder of Sex Development. November 16-18, 2007 Rome-Italy

7. **K. Fathi**, A. Jordan, AR. Khan, A. Saeed, M. Kazmierski, MPL. Williams. Home management of meatal stenosis in children. British Association of Paediatric Surgeon (BAPS) and European Paediatric Surgeons' Association (EUPSA) joint congress. June 17-20, 2009 Graz-Austria

8. **K. Fathi**, M. Djordjevic, A. Pinter, S. Perovic. Successful surgical correction of ectopic penis with hypospadias. 14<sup>th</sup> Congress of Hungarian Association of Pediatric Surgeons with International Participation. September 10-12, 2009 Balatonfüred-Hungary

9. **K. Fathi**, M Shoukry, A Coates, N Fraser, A Williams, M Shenoy. Foreskin reconstruction in hypospadias repair. IV World Congress on Hypospadias and Disorder of Sex Development. 17<sup>th</sup>-19<sup>th</sup> September 17-19, 2011 London-UK

10. **K. Fathi**, F. Harangi, A. Kravjak, A. Pinter. Penile granuloma annulare associated with urethral anomaly. 15<sup>th</sup> Congress of Hungarian Association of Pediatric Surgeons with International Participation. September 12-14, 2013 Debrecen-Hungary

### **8.3. Other publications**

1. **Fathi K**, Pintér A.: Spontaneous perforation of the common bile duct in the neonate. Gyermekgyógyászat 1995; 46:446-449

2. **Fathi K**, Pintér A, Tornoczky T.: Fibroepithelial polyp causing ureteropelvic obstruction in childhood. Orv. Hetilap 1998; 139:3019-3021

3. **Fathi K.** Pinter A. Farkas A.: Emesis following pyloromyotomy in congenital hypertrophic pyloric stenosis: incomplete pyloromyotomy, recurring pyloric stenosis or obstruction in the gastric outlet?. Orv. Hetilap 2002; 31: 1853-1854

4. Vastyán A. Pinter A. Farkas A. Vajda P. Juhasz Zs. Oberritter Zs. **Fathi K.**: Surgical bladder augmentation with a gastric segment-gastrocystoplasty. Gyermekgyógyászat 2005; 56:(1) 67-72

5. Peter Vajda, Andrew Pinter, Tamas Magyarlaci, Attila Vastyán, Zsolt Juhasz, Zsolt Oberritter, **Khaled Fathi**: Histologic findings after gastrocystoplasty in rabbits. J Pediatr Surg. 2005, 40; 1470-4 (IF<sub>2005</sub>: 1.125)

6. Juhasz Zs. Somogyi R. Vajda P. Oberritter Zs. **Fathi K**, Pinter AB.: Does the type of bladder augmentation influence the resolution of pre-existing vesicoureteral reflux? Urodynamic studies. Neurourology and Urodynamics 2007; 26:1-5 (IF<sub>2006</sub>: 2.733)

7. N. Featherstone, **K. Fathi**, D. McIver, MS. Kulkarni: Meconium per vagina: a rare presentation of meconium peritonitis. J Pediatr Surg 2008; 43: e5-7 (IF<sub>2008</sub>: 1.557)

8. Vass I. **Fathi K.** Tóth G. Vajda K. Szekeres I. Harangi F.: Rapunzel – szindróma : avagy mit rejthet a gasztrointesztinum. Gyermekgyógyászat. 2013; 64:35-38

**8.4. Cumulative Impact Factor: 10.594**

**8.5. Total number of citations: 37**

## **9. ACKNOWLEDGEMENT**

I am grateful to Prof. Balazs Sumegi for being a part of his doctoral programme.

I owe my deepest gratitude to my theme leader Prof. Andras Pinter for his continuous support, encouragement, guidance, motivation, enthusiasm and immense knowledge throughout the preparation of my thesis.

I would like to thank all my colleagues and staffs of the Surgical Unit of the Department of Paediatrics of Pecs University for their help and support in collection and analysis of the data.

Lastly, I would like to thank my wife Agnes and my children Meetra and Omid for their endless patience and moral support without which this thesis would not have been possible.