

Diffusion weighted imaging in the normal appearing white matter of glioma patients

PhD Thesis

Andrea Horváth, MD

Supervisors:

Prof. Péter Bogner, MD, PhD

Prof. Tamás Dóczi, MD, DSc

Program Director: Prof. András Büki, MD, DSc

Doctoral School Director: Prof. Sámuel Komoly, MD, DSc



University of Pécs, Medical School

Clinical Neuroscience Doctoral School

Pécs, 2016

1. Introduction

Central nervous system (CNS) neoplasms affect adults and children of all ages, and they are the second leading-cause of tumor-related death in children and adolescents. CNS tumors are classified as primary tumors, if they arise from brain tissue cells, or metastatic tumors, if they originate from cancers outside of the CNS. Glial cell-derived tumors account for 27% of all primary CNS tumors, and 80% of malignant CNS neoplasms. The annual incidence is 18 054 /100 000 individuals and they occur at a rate of 5.55/100 000 individuals annually in the United States according to the Central Brain Tumor Registry of the United States. They require special attention in the field of neuro-oncology due to their complex behavior and histopathology and relatively high mortality rate.

Despite the improvements of diagnostic methods and surgical techniques and the intense effort in developing new, targeted therapies the prognosis for patients with glioma still remains poor. Only 5.1% of patients with the most malignant glioma subtype survive 5 years after diagnosis. A possible reason for the poor prognosis is the diffuse, infiltrative nature of gliomas which hinders complete resection and reduces the efficacy of local radiation therapy or radiosurgery.

Tumor infiltration in macroscopically inconspicuous areas distant from the tumor was shown in post mortem human brains. Recently, several research groups tried to show tumor infiltration with magnetic resonance imaging (MRI). Abnormalities were revealed in the contralateral normal appearing white matter (NAWM) of glioma patients with diffusion tensor imaging and whole brain spectroscopy,

and they explained their findings with the presence of tumor infiltration. However, the question may arise, whether these diffusion alterations are really related to infiltrative tumor cells, and whether apparent diffusion coefficient (ADC) can be used as a marker of tumor infiltration.

Water diffusion in the brain is affected by tissue microstructure, and thus it can be used to monitor changes accompanying various pathologies. Signal decay with high b factors can better be described with a biexponential function. This model assumes a fast and slow diffusion pool with fast and slow diffusion coefficients, whose origin is yet unclear. The most reasonable explanation is that the slow diffusion pool corresponds to highly structured water layers bound to membrane surfaces and cytoskeleton (i.e. hydration shell around proteins and macromolecules) and the fast diffusion pool originates from the remaining extra and intracellular tissue water. Consequently, diffusion imaging with an extended b factor range enables more specific tissue characterization and differentiation. More complete understanding of diseases could promote the development of more efficient therapies which might result in improved outcome.

2. Objectives

The primary aim of this thesis was to clarify the nature of elevated ADC in the NAWM of glioma patients.

An indirect way to prove or exclude the role of distant tumor infiltration in altering diffusion in the contralateral NAWM is to examine the contralateral NAWM of patients with non-infiltrative tumors. If ADC is elevated in the NAWM of both infiltrative tumor (i.e. glioma) and non-infiltrative tumor (i.e. meningioma) patients, the diffusion alteration

cannot be explained exclusively by the presence of tumor infiltration. Therefore, the primary aim of the first study was to determine if diffusion abnormality was also present in the contralateral NAWM of patients with non-infiltrative tumors such as meningiomas.

The secondary aim was to search for other possible factors that could contribute to ADC elevation in the contralateral NAWM. Since a certain amount of mass effect is present in tumors regardless of their infiltrative or non-infiltrative behavior, the further purpose of the study was to investigate its role in causing contralateral NAWM diffusion abnormalities.

The goal of the second study was to further clarify the nature of elevated ADC in NAWM of glioma patients with the more detailed biexponential diffusion analysis and to reveal if the observed diffusion alterations were region specific or global.

3. Methods

Increased diffusion in the normal appearing white matter of brain tumor patients: is this just tumor infiltration?

Twenty-seven patients with histologically verified glioma (13 females, 14 males; mean age: 49.0 ± 16.9 years, grade II-IV), 22 meningioma patients (15 females, 7 males; mean age: 53.5 ± 12.3 years) and two groups of age- and sex-matched healthy controls underwent diffusion weighted imaging (DWI) on a 3T MR before any treatment or intervention. ADC values were calculated in the entire NAWM of the hemisphere contralateral to the tumor. ADC values of the NAWM were compared between groups with Mann-Whitney U-test and multiple linear regression. The relations of ADC in NAWM to glioma grade and to tumor volume were also investigated.

Biexponential diffusion alterations in the normal appearing white matter of glioma patients might indicate the presence of global vasogenic edema

Twenty-four newly diagnosed glioma patients (10 females, 14 males, mean age: 42.29 ± 11.44 years, grade II-IV) and 24 matched control subjects underwent diffusion weighted imaging at 3T. Diffusion parameters were calculated using monoexponential and biexponential models. ADC values were measured in the entire NAWM of the hemisphere contralateral and ipsilateral to the tumor. In the contralateral NAWM, regional ADC values were assessed in the frontal, parietal, occipital and temporal NAWM. Both total hemispheric and regional diffusion values were compared between patient and control groups by Student's t test or two tailed Mann-Whitney-U test according to the statistical distribution of the data. Two-way mixed ANOVA was performed to evaluate whether regional differences in diffusion parameters were significant between patients and controls.

4. Results

Increased diffusion in the normal appearing white matter of brain tumor patients: is this just tumor infiltration?

ADC values of the contralateral NAWM were significantly higher in both glioma and meningioma patients compared to controls ($P=0.0006$ and $P=0.0099$, respectively, Fig. 1a). ADC value was higher in the NAWM of high grade gliomas than in low grade gliomas ($P=0.0181$) and in healthy control subjects ($P=0.0003$)(Fig. 1b). ADC did not depend on tumor volume in any of the patient groups.

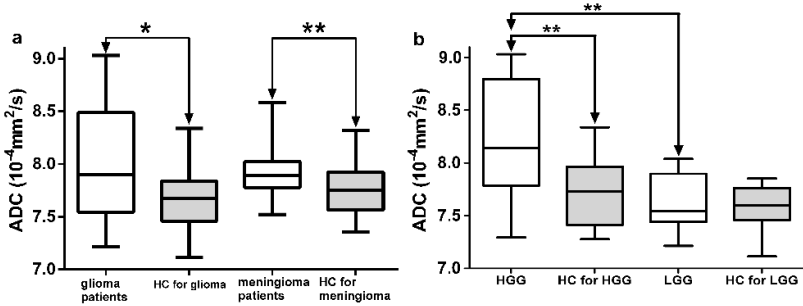


Fig. 1. a) Boxplot illustrating the significantly increased ADC in the contralateral NAWM of glioma and meningioma patients compared with healthy control subjects. b) Boxplot illustrating the significantly increased ADC in the contralateral NAWM of HGG patients compared with healthy control subjects and LGG patients. Whiskers are set at minimum and maximum, the horizontal line marks the median, whereas box indicates the interquartile range (25-75%). * indicates $P < 0.05$, ** indicates $P < 0.01$. HC: healthy control, HGG and LGG: high and low grade glioma.

Biexponential diffusion alterations in the normal appearing white matter of glioma patients might indicate the presence of global vasogenic edema

Results of the hemispheric and regional analyses are presented on Fig 2. ADC_{mono} and ADC_{fast} were significantly higher than control values in all investigated regions except the temporal NAWM ($P < 0.04$). ADC_{slow} was significantly increased in the total contralateral, the frontal and parietal NAWM ($P < 0.03$), while p_{slow} was decreased in both total hemispheric NAWM and the parietal NAWM of glioma patients compared to controls ($P < 0.04$). Significant differences were observed in all diffusion parameters among the NAWM of the four lobes of the contralateral hemisphere in both groups ($P < 0.0001$), these regional differences were similar in patients and controls ($P > 0.05$). Hemispheric ADC_{mono} and p_{slow} differences were different between groups ($P < 0.05$).

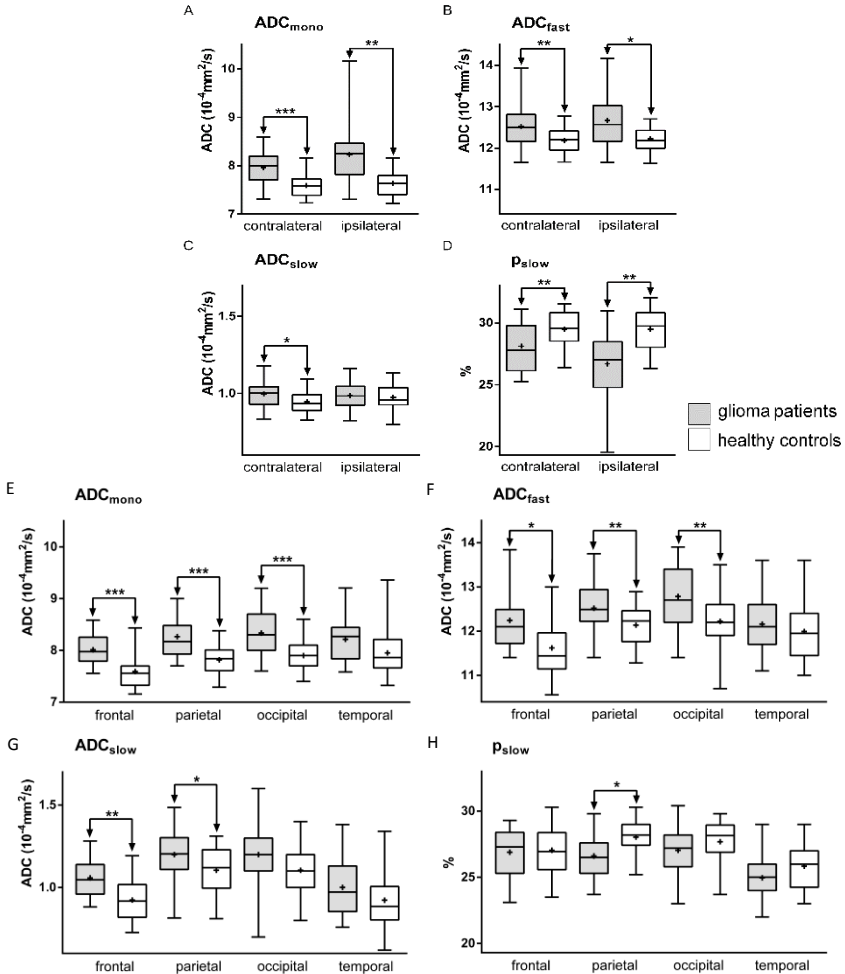


Fig. 2. Results of the hemispheric (A-D) and regional (E-H) analyses. Comparisons of monoexponential ADC_{mono} values (A and E), biexponential ADC_{fast} (B and F), ADC_{slow} (C and G) and p_{slow} (D and H) in the NAWM of glioma patients and healthy controls. In the boxplots, whiskers are set at minimum and maximum, the horizontal line marks the median, + indicates the mean, whereas box indicates the interquartile range (25-75%). * indicates P<0.05, ** indicates P<0.01, *** indicates P<0.001. Contralateral and ipsilateral indicate the total NAWM in the hemisphere contralateral and ipsilateral to the tumor. Frontal, parietal, occipital and temporal indicate the regional NAWM ROIs in the hemisphere contralateral to the tumor.

5. Discussion

Altered diffusion in the NAWM of glioma patients has previously been explained by tumor infiltration. In this thesis we intended to clarify the nature of elevated ADC in the NAWM of glioma patients.

Our study tested the hypothesis whether abnormal ADC values in the normal appearing white matter contralateral to brain tumors can be explained exclusively by tumor infiltration.

An indirect way to test this hypothesis was to check if ADC was altered in the contralateral NAWM of patients with non-infiltrative tumors. We assumed, if ADC was increased in the NAWM of both infiltrative tumor (i.e. glioma) and non-infiltrative tumor (i.e. meningioma) patients, the diffusion alteration could not have been explained exclusively by the presence of tumor infiltration.

Our results revealed elevated ADC in the contralateral NAWM of both infiltrative and non-infiltrative tumor patients that might suggest that the effect of infiltrating tumor cells is not the only reason for the alteration. One alternative explanation, mass effect, was investigated and not found to play a role in increasing ADC values in the contralateral NAWM, since ADC in the contralateral NAWM was not related to tumor volume. The literature was searched for other possible factors that could explain our results (Figure 3). There are complex mechanisms that might be present in both infiltrative and non-infiltrative tumors possibly related to the secretory activity of the tumors. Besides these, effects of tumor infiltration in infiltrative tumors might also contribute to elevated ADC. This contribution seems to be greater in the NAWM of high grade glioma patients than in low grade glioma patients.

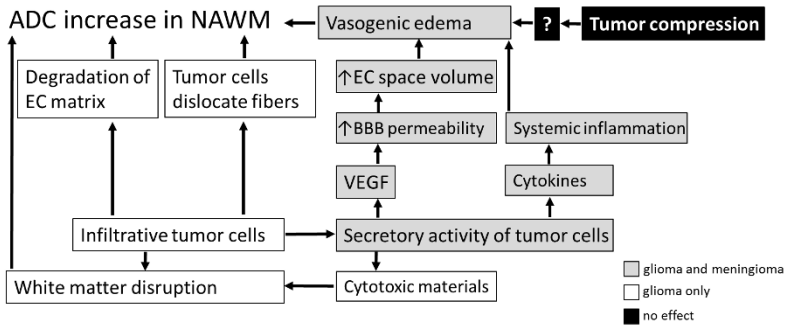


Fig. 3. Summary of possible factors based on literature data that could contribute to ADC elevation in the NAWM. Grey boxes: factors possibly present in both gliomas and meningiomas. White boxes: factors that might only be present in infiltrating tumors such as gliomas. Black boxes: factors whose contribution to increased ADC appears unlikely based on our results. Abbreviations: EC: extracellular, BBB: blood brain barrier. VEGF: vascular endothelial growth factor.

In the second study, we aimed to reveal the cause of observed diffusion abnormality prospectively with the slow (structured) and fast (free) diffusing water compartment model described by LeBihan. The biexponential analysis revealed increased ADC_{mono} , ADC_{fast} and ADC_{slow} values and decreased p_{slow} value in the NAWM of the unaffected hemisphere of glioma patients, which suggested the presence of global vasogenic brain edema in glioma patients. This study revealed that regional differences in patients followed those found in controls, which also supported the global nature of the phenomenon. Besides the presence of edema, tumor infiltration might be responsible for the diffusion abnormalities in the ipsilateral NAWM, however, the increase in ADC is probably not an indicator of tumor infiltration only.

In conclusion, gliomas affect the brain in areas where they are not macroscopically present. Although this thesis intended to clarify the

reason for altered diffusion in NAWM, it is still not clear what happens exactly and whether these diffusion abnormalities are associated with the poor prognosis of gliomas. Our retrospective study including non-infiltrative and infiltrative patients showed, that altered diffusion in the NAWM is not exclusively caused by tumor infiltration, although the difference between low and high grade gliomas might indicate some degree of infiltration. One alternative explanation, mass effect was excluded during the first study. The potential role of vasogenic edema in causing the observed diffusion alterations was shown in the second, prospective study. Our results might contribute to the development of diagnostic or prognostic methods in the future.

6. List of publications

6.1. Articles related to this thesis

Horvath A, Perlaki G, Toth A, Orsi G, Nagy S, Doczi T, Horvath Z, Bogner P (2016) Increased diffusion in the normal appearing white matter of brain tumor patients: is this just tumor infiltration? *Journal of Neuro-Oncology* 127(1):83-90. **IF: 2.754** (in 2015)

Horvath A, Perlaki G, Toth A, Orsi G, Nagy S, Doczi T, Horvath Z, Bogner P (2016) Biexponential diffusion alterations in the normal-appearing white matter of glioma patients might indicate the presence of global vasogenic edema. *Journal of Magnetic Resonance Imaging* 44(3):633-41. **IF: 3.250** (in 2015)

6.2 Articles unrelated to this thesis

Horváth A, Nagy SA, Perlaki G, Orsi G, Bogner P, Dóczy T (2015) Multimodal Quantitative Characterization of Intracranial Epidermoid Cysts: Preliminary Results. *Ideggyogyaszati szemle* 68:347-355. **IF: 0.376** (in 2015)

Toth A, Kovacs N, Tamas V, Kornyei B, Nagy M, **Horvath A**, Rostas T, Bogner P, Janszky J, Doczi T, Buki A, Schwarcz A (2016) Microbleeds may expand acutely after traumatic brain injury. *Neuroscience Letters* 617:207-12. **IF: 2.107** (in 2015)

Nagy SA HR, Perlaki G, Orsi G, Barsi P, John F, **Horvath A**, Kovacs N, Bogner P, Janszky J (2016) Age at onset and seizure frequency affect white matter diffusion coefficient in patients with mesial temporal lobe epilepsy. *Epilepsy & Behavior* 61:14-20. **IF: 2.332** (in 2015).

Aschermann Z, Perlaki G, Orsi G, Nagy SA, **Horvath A**, Bone B, Bihari K, Acs P, Janszky J, Komoly S, Bogner P (2015) Quantitative assessment of brain iron by R2* relaxometry in patients with cervical dystonia. *Movement disorders: official journal of the Movement Disorder Society* 30:1422-1426. **IF: 6.010**

Kellermayer MS, Murvai U, **Horvath A**, Laszloffi E, Soos K, Penke B (2013) Epitaxial assembly dynamics of mutant amyloid beta25-35_N27C fibrils explored with time-resolved scanning force microscopy. *Biophysical chemistry* 184:54-61. **IF: 2.319**

Horváth A, Aradi M, Perlaki G, Orsi G, Szalay Cs, Schwarcz A, Büki A, Kövér F, Dóczy T, Bogner P (2013) A kórnás agy strukturális és funkcionális vizsgálata multiparametrikus MR technikával. *Magyar Radiológia* 87(2):32-39

6.3 Presentations related to this thesis

Horváth A, Perlaki G, Toth A, Orsi G, Nagy S, Doczi T, Horvath Z, Bogner P.: *Comparison of diffusion alterations in the normal appearing white matter of glioma and meningioma patients*: 47th Annual Meeting HMAA – Current Developments in Biomedical and Clinical Sciences, Sarasota, FL, United States of America, 2015.

Horváth A, Perlaki G, Toth A, Orsi G, Nagy S, Doczi T, Horvath Z, Bogner P.: *Comparison of diffusion alterations in the normal appearing white matter of glioma and meningioma patients*: 53rd American Society of Neuroradiology Annual Meeting, Chicago, IL, United States of America, 2015

Horváth A, Perlaki G, Toth A, Orsi G, Nagy S, Doczi T, Horvath Z, Bogner P. *Tumor infiltration cannot be the only reason for diffusion alterations in the normal appearing white matter in brain tumors*. HMAA Conference in Balatonfüred 2015.

Horváth A, Perlaki G, Tóth A, Orsi G, Nagy S, Dóczi T, Horváth Z, Bogner P. *Diffusion alterations in the normal appearing white matter of glioma and meningioma patients*. Neuroimaging Workshop, Szeged, 2015.

Horváth A., Nagy SA, Perlaki G, Orsi G, Tóth A, Dóczi T, Horváth Zs, Bogner P. *Megváltozott szöveti diffúzió gliómás betegek épek tűnő fehérállományában*. Neuroscience Centre /Szentágotthai Research Centre PhD and Medical Student Congress, 2014.

Horváth A., Nagy SA, Perlaki G, Orsi G, Tóth A, Dóczi T, Horváth Zs, Bogner P. *Megváltozott szöveti diffúzió gliómás betegek épek tűnő fehérállományában*. 22nd Annual Meeting of the Hungarian Society of Neuroradiology. Hajdúszoboszló, 2014.

6.4. Presentations unrelated to this thesis

Horváth A, Várallyay C, Várallyay P, Schwartz D, Ambady P, Bogner P, Neuwelt E. *Comparison of ferumoxytol and gadolinium enhancement changes in response to Avastin in high grade glioma patients*. International Society for Magnetic Resonance in Medicine 24th Annual Meeting, Singapore, 2016

Várallyay C, Schwartz D, Prola NJ, Ambady P, **Horvath A**, Neuwelt E. *Introducing steady state blood volume mapping using ferumoxytol, a new MRI tool to assess the intravascular space in brain tumors and other intracranial pathologies*. International Society for Magnetic Resonance in Medicine 24th Annual Meeting, Singapore, 2016

Horváth A, Várallyay C, Szidonya L, Várallyay P, Schwartz D, Ambady P, Bogner P, Neuwelt E. *Comparison of gadolinium and ferumoxytol enhancement in treated glioma patients: preliminary results*. Radiology Research Retreat, Portland, OR, United States of America, 2016

Horváth A, Várallyay C, Várallyay P, Schwartz D, Ambady P, Bogner P, Neuwelt E. *Comparison of ferumoxytol and gadolinium enhancement changes in response to Avastin in high grade glioma patients*. European Congress of Radiology, Vienna, Austria, 2016

Horváth A, Várallyay C, Várallyay P, Schwartz D, Ambady P, Bogner P, Neuwelt E. *Comparison of gadolinium and ferumoxytol enhancement in treated glioma patients: preliminary results*. 23rd Annual Meeting of the Hungarian Society of Neuroradiology, 2015.

Péter Horváth, **Horváth A**, Péter Bogner, Zsolt Horváth. *The evaluation of cerebral atrophy after whole brain radiation therapy with MRI volumetry*. Grastyán Congress, 2015

Várallyay, C, **Horváth A**, Neuwelt, E. Ferumoxytol as an MRI Contrast agent in th CNS; Collaborations and multicenter trials.. 47th Annual Meeting HMAA – Current Developments in Biomedical and Clinical Sciences, Sarasota, FL, United States of America, 2015.

Orsi G, Perlaki G, Horváth R, Nagy SA, **Horváth A**, Bogner P, Janszky J. *Comparison of accuracy between FSL's FIRST and Freesurfer for caudate nucleus and putamen segmentation*. Magnetic resonance Materials in Physics and Biology and Medicine. ESMRMB Congress, Edinburgh, United Kingdom 2015.

Horváth P, **Horváth A**, Bogner P, Horváth Z. *The evaluation of cerebral atrophy after whole brain radiation therapy with MRI volumetry*. HMAA Conference in Balatonfüred 2015.

Környei B., **Horváth A**, Tóth A. *Follow-up susceptibility weighted (SWI) MRI study on traumatic brain injuries (TBI): revealing the lesions' dynamics*. HMAA Conference in Balatonfüred 2015.

Herczeg B, **Horváth A**, Horváth Z, Bogner P, Vető F. *Kinél segít a shunt? Liquortér volumetria hydrocephalusos betegekben*. HMAA Conference in Balatonfüred 2015.

Toth A, Kovacs N, Tamas V, Kornyei B, Nagy M, **Horvath A**, Bogner P, Janszky J, Doczi T, Buki A, Schwarcz A. *Microbleeds may progress acutely after traumatic brain injury*. Neuroimaging Workshop, Szeged, 2015

Orsi G, Perlaki G, Horvath R, Nagy SA, **Horváth A**, Bogner P, Janszky J. *Comparison of accuracy between FSL's FIRST and Freesurfer for caudate nucleus and putamen segmentation*. Neuroimaging Workshop, Szeged, 2015

Nagy SA, Horváth R, John F, Janszky J, Perlaki G, **Horváth A**, Bogner P. *Legújabb MR módszerek és alkalmazási területeik különböző intracraniális betegségekben*. X. Jubileumi Képzőképző Diagnosztikai Továbbképzés és Konferencia, Budapest, 2015.

Horváth A, Nagy SA, Perlaki G, Orsi G, Tóth A, Dóczi T, Bogner P. *Multimodal quantitative characterization of intracranial epidermoid cysts: preliminary results*. HMAA Conference in Balatonfüred 2014.

Horváth A., Nagy SA, Perlaki G, Orsi G, Tóth A, Horváth Zs, Dóczi T, Bogner P. *New Trends in Perfusion MR Imaging*. Neuroimaging Workshop, Debrecen, 2014.

Horváth A, Nagy SA, Perlaki G, Orsi G, Aradi M, Horváth Z, Dóczi T, Bogner P. *Perfúziós MR vizsgálati technikák összehasonlítása cerebrális neoplazmákban*. 21st Annual Meeting of the Hungarian Society of Neuroradiology, Visegrád, 2013.

Horváth A, Aradi M, Perlaki G, Orsi G, Tóth A, Schwarcz A, Büki A, Kövér F, Dóczi T, Bogner P. *Kómás betegek kognitív funkcióinak vizsgálata funkcionális MR, diffúzió tenzor képalkotással és ¹H- spektroszkópiával*. National Student Research Conference, Szeged, 2013.

Horváth A, Aradi M, Perlaki G, Orsi G, Tóth A, Schwarcz A, Büki A, Kövér F, Dóczi T, Bogner. *Kómás betegek kognitív funkcióinak vizsgálata funkcionális MR, diffúzió tenzor képalkotással és ¹H- spektroszkópiával*. Student Research Conference, Pécs, 2013.

Horváth A, Aradi M, Perlaki G, Orsi G, Tóth A, Schwarcz A, Büki A, Kövér F, Dóczi T, Bogner P. *The evaluation of comatose brain with fMRI, DTI and ¹H –spectroscopy*. 44. Annual Meeting HMAA – Current Developments in Biomedical and Clinical Sciences, Sarasota, FL, United States of America, 2012.

Horváth A, Nagy S, Aradi M, Orsi G, Perlaki G, Komáromy H, Schwarcz A, Janszky J, Bogner P. *Quantitative MR imaging of cholesteatoma with T1 and T2 mapping*. HMAA Conference in Balatonfüred 2012.

Horváth A, Nagy SA, Dóczi T, Bogner P. *A cholesteatoma kvantitatív MR vizsgálata, avagy a T2 térképezés módszere*. Student Research Conference, Pécs. 2012.

Horváth A, Aradi M, Perlaki G, Orsi G, Schwarcz A, Büki A, Kövér F, Dóczi T, Bogner P. *The evaluation of comatose brain with fMRI, DTI and 1H – spectroscopy*. HMAA Conference in Balatonfüred 2011.

Kellermeyer MSZ, **Horváth A**, Murvai Ü, Soós K, Penke B. *Epitaxial assembly kinetics of mutant amyloid beta 25-35 fibrils*. From Solid State to Biophysics V. International Conference and Biophysics Summer School. Dubrovnik, Croatia, 2010.

Horváth A, Aradi M, Schwarcz A, Kövér F, Dóczi T. *A funkcionális MR (fMRI) szerepe a kómas betegek alapvető kognitív funkciójának vizsgálatában*. Student Research Conference, Pécs, 2010.

Horváth A, Aradi M, Perlaki G, Orsi G, Schwarcz A, Büki A, Kövér F, Dóczi T, Bogner P. *The evaluation of comatose brain with fMRI, DTI and spectroscopy*. V. Young European Scientist Meeting, Porto, Portugal 2010.

Horváth A, Murvai Ü, Karsai Á, Kellermayer M. *A β 25-35_{N27C} amiloid fibrillumok epitaxiális növekedési kinetikája*. Student Research Conference, Pécs, 2009.

Szili K, **Horváth A**, Kálmándy-Pap P. *Betegség? Nem butaság! Dyslexia vizsgálata különböző korosztályokban*. 15th Students' Scientific Conference, Targu Mures, Románia 2008.

Horváth A, Sétáló Gy., Szeberényi J. *A proteaszóma-gátlás hatásainak vizsgálata PC12 sejtek túlélésére*. South-Hungarian Regional Student Research Conference, Paks, 2006.

7. Acknowledgements

All the work presented in this thesis could not have been carried out without the help of many people, to whom I owe a great debt of gratitude.

First, I wish to thank my supervisor, Prof. Péter Bogner for teaching me the basics of neuroscience research, his continuous support, efforts, guidance and irreplaceable help in summarizing my thesis. I am most grateful to Dr. Mihály Aradi for introducing me as a student research fellow into the world of neuroimaging. I would like to thank Prof. Tamás Dóczi and Dr. Ferenc Kövér for the technical and professional support of my work. I would like to also thank the members of the research group, Dr. Arnold Tóth, Dr. Gábor Perlaki, Dr. Gergely Orsi and Szilvia Anett Nagy for constantly advising and helping me through all these years regarding both the theoretical and technical parts of the research and for sharing their expertise with me. They answered a series of my questions every day tirelessly and patiently, providing their knowledge and insight in the field of MRI.

I would like to thank all my colleagues at the Diagnostic Center of Pécs and at the Department of Neurosurgery at the University of Pécs, in particular, Viktória Tamás, Kristóf Biczó, Péter Bódi, Szilvia Waller and Zsuzsanna Baranyai.

Special thanks must be paid to my friends, Dr. Anna Cseh, Dr. Bálint Scheich, Judit Sámson and Dr. Anna Budai. Most special thanks to Dr. Csanád Várallyay for his continuous support. I express my gratitude to my parents, my brother, my grandmother and other members of my family for their love and for supporting and encouraging me through all these years.