

SOME NEW CLINICAL AND EXPERIMENTAL ASPECTS
OF THE ETIOLOGY AND TREATMENT
OF ESOPHAGEAL DISEASES

Ph.D. thesis

by

Laura BOGNÁR M.D.



Supervisors:

Prof. emer. Örs Péter HORVÁTH M.D., Ph.D., D.Sc.

András PAPP M.D., Ph.D.

University of Pécs

Department of Surgical Research and Techniques

Department of Surgery

2020

INTRODUCTION

The esophagus is one of the most inscrutable organs of the gastrointestinal tract, hereby it challenges all physicians who specialize on it, including gastroenterologists, surgeons and also primary care physicians.

The complexity of the esophagus manifests itself on the colorful spectrum of complications that develop on the ground of gastroesophageal reflux disease (GERD). It is already unexplainable why chronic acid regurgitation provokes reflux esophagitis in some patients, while in others no endoscopic or histologic sign of inflammation can be detected, yet patients have severe complains. Development of diverse functional and structural esophageal disorders have been described in association with gastroesophageal reflux disease, but to date, it is unclear whether these secondary pathologies are simple consequences of GERD or is it possible that some of them are defensive reactions? Is there an expediency in their development or is it mere coincidence? Do the presumed adaptive esophageal changes influence the therapeutic strategy? Gastroesophageal reflux disease has become an endemic malady worldwide in the past decades. Understanding the long-term impacts of acid regurgitation on the esophagus would be imperative in order to better comprehend the behavior of this organ and to improve our knowledge about the possible complications of GERD.

Laparoscopic fundoplication is the standard surgery for gastroesophageal reflux disease. In the short term, fundoplication is considered to be an effective procedure, more than 90% of the patients are satisfied with their symptom control over a period of 1–2 years. However, efficacy wanes with time and post-fundoplication complications may occur, such as migration or herniation of the fundic wrap. These failures inspired us to search for an alternative, possibly more efficient antireflux procedure. With this purpose we set up an innovative surgical antireflux technique, which we carried out on a series of animal models.

Similarly to gastroesophageal reflux disease, lots of questions encircle the development, prognosis and adequate treatment of esophageal cancer. Esophageal cancer is one of the deadliest cancers worldwide due to its extremely aggressive nature and poor prognosis. Despite the rapid progress in cancer research, there are still debates concerning the

etiology of ESCC. It is also so far unanswered why patients with locally advanced esophageal cancer respond differently to neoadjuvant therapy. Why do upper third esophageal cancers have superior sensitivity to multimodal treatment than lower third cancers? The proximity of the oropharynx and changed sexual habits raise thoughts that human papillomavirus (HPV) infection may play a role in the development of esophageal cancers, similarly as it does in cervical and oropharyngeal cancers. International reports on HPV as a possible etiological factor for esophageal carcinoma are limited and inconsistent, and so is the possible impact of viral infection on the response to the oncological treatment. In order to improve prognosis it would be imperative to find prognostic markers that could distinguish between patients who respond to the oncological treatment and those who don't, consequently saving the non-responder group from unnecessary overtreatment with cytostatics. We searched for answers for these pending problems through retrospective analysis of pre-treatment tumor biopsies of esophageal cancer patients.

During the past quarter century, in the Department of Surgery, University of Pécs, we consulted and operated on nearly two thousand patients with various esophageal disorders. The hypotheses, observations and conclusions of this thesis are based on the experiences gained from the management of these patients.

AIMS

ESOPHAGEAL COMPLICATIONS OF GASTROESOPHAGEAL REFLUX DISEASE: CONSEQUENCES OR DEFENSIVE REACTIONS?

- 1 We aimed to elucidate our hypothesis whether gastroesophageal reflux disease might induce certain – supposedly adaptive – changes in the esophagus.
- 2 We aimed to deduce whether the presumed adaptive esophageal changes influence therapeutic strategy.

FUNCTIONAL EXAMINATION OF THE TRANSPOSED PYLORIC SPHINCTER IN ANTIREFLUX PORCINE MODELS: COULD IT BE SUITABLE TO CREATE A CONTINENT ILEOSTOMY?

- 3 We aimed to ascertain if transposition of a pedicled pyloric sphincter around an impaired gastroesophageal junction is technically feasible and if it is a safe and acceptable antireflux procedure.
- 4 We aimed to assess if the transposed pyloric sphincter preserves its pharmacological responsiveness in the new, ectopic position.
- 5 We also aimed to assess a different use of the pedicled pyloric sphincter, namely if it is applicable to complete a 3-limb S-pouch and create a continent ileostomy.

PROGNOSTIC ROLE OF HPV INFECTION IN ESOPHAGEAL SQUAMOUS CELL CARCINOMA

- 6 We aimed to determine the rate of HPV infection in Hungarian patients with locally advanced esophageal squamous cell carcinoma.
- 7 We aimed to determine the distribution of HPV positivity in the upper, middle and lower thirds of esophageal squamous cell cancer tumor samples.
- 8 We aimed to compare the response to oncological therapy and also the mean survival of the HPV positive and the HPV negative ESCC patients.

- 9 We aimed to investigate the correlation between the HPV status and expression pattern of heat shock proteins 90, 27, 16. 2, GHRH-R; and also between expression pattern of heat shock proteins 90, 27, 16. 2, GHRH-R and response to oncological therapy in pre-treatment tumor biopsies of ESCC patients.

CHAPTER 1

ESOPHAGEAL COMPLICATIONS OF GASTROESOPHAGEAL REFLUX DISEASE: CONSEQUENCES OR DEFENSIVE REACTIONS?

1.1 INTRODUCTION

Cause-and-effect associations between GERD and certain esophageal disorders have already been published in the literature, but to our knowlwdge this is the first study discussing GERD as a potential causative factor in the development of nine esophageal disorders that result in reduced acid regurgitations or decreased reflux symptoms. Based on our own experiences and review of the literature we propose a hypothesis that certain esophageal changes could be considered as protective reactions of the organism aimed at guarding the refluxate entering the esophagus or beyond, by narrowing the lumen of the esophagus.

1.2 OBSERVATIONS AND THEORIES

1.2.1 Hypertensive lower esophageal sphincter

To date, probably the most proven protective mechanism of the esophagus against reflux and its complications is the development of a hypertensive lower esophageal sphincter (HLES). About three-quarters of patients with a hypertensive lower esophageal sphincter have symptoms of regurgitation and heartburn and one quarter of patients display an abnormal esophageal acid exposure on 24-hour pH-monitoring. HLES is observed in 1.6–2.7% of the patients evaluated for GERD with manometry. The main evidence for HLES being secondary to acid reflux is that following a Nissen fundoplication, sphincter pressure and pH-metry values return to the normal range again and reflux symptoms disappear. Tamhankar *et al.* reported that Nissen fundoplication for hypertensive LES with GERD or type III hiatal hernia relieves dysphagia and chest pain, suggesting reflux as an etiology in the development of HLES. Katzka *et al.* reported 9 patients with HLES and

GERD, in whom LES pressure was restored to normal with antireflux medication and an additional three with fundoplication.

In our department, between 1999 and 2006, we operated on 6 patients, who had abnormal esophageal acid exposure and manometrically proven HLES at the same time. All 6 patients underwent a laparoscopic floppy Nissen fundoplication. After the operation, the mean DeMeester score of the patients returned to the normal range. Parallely, a marked decrease in the gastroesophageal junction pressure was detected.

Thus, some HLES is caused by acid reflux, and this elevated pressure can be interpreted as a protective action of LES to hinder gastroesophageal reflux. By eliminating excessive esophageal acid exposure with a simple fundoplication, the protective reaction of LES is no longer needed, and the pressure of LES returns to normal.

1.2.2 Achalasia

Numerous facts and observations support the theory that there is a cause-and-effect relationship between long-standing reflux disease and the development of achalasia. The theory was first proposed by Smart *et al.* in 1986, who described five patients presenting with reflux and subsequently developing achalasia over the years. Since then several reports were published where gastroesophageal reflux was documented to occur in patients prior to the development of achalasia. Reflux-induced severe esophagitis may damage the ganglion cells, and later an autoimmune reaction may possibly develop, maintaining chronic inflammation in the myenteric plexus of the esophagus leading to the degeneration of the inhibitory nerve endings and thereby to achalasia. This theory is supported by Altorjay *et al.* who examined morphological and metabolic changes in the muscle samples taken from the LES of reflux patients and compared them to muscle samples taken from non-reflux patients.

Other reports showed that 10–20% of untreated achalasia patients had abnormal acid exposure on pH monitoring. In the literature the development of Barrett's esophagus and even esophageal adenocarcinoma among untreated achalasia patients has been reported, suggesting that long-standing reflux disease preceded, and possibly played an etiological role in the development of achalasia. Similarly, several cases have been described where

achalasia occurred with concomitant hiatal hernia. It is well-known that hiatal hernia facilitates development of GERD.

In summary, the potential relationship between gastroesophageal reflux and achalasia is not clearly defined yet, but we have reason to believe that it can very well be.

Our surgical team has operated on over 40 patients with achalasia in the past 15 years, and in 10% of the cases achalasia developed on the ground of gastroesophageal reflux disease. In our opinion, in these cases dilation therapy should be avoided and the surgical management of achalasia should include a laparoscopic Heller's cardiomyotomy completed with a 360° Nissen fundoplication in order to minimize the risk of post-operative reflux.

1.2.3 Diffuse esophageal spasm

Diffuse or distal esophageal spasm (DES) is an uncommon esophageal motility disorder that presents clinically with chest pain and/or dysphagia and is defined manometrically as simultaneous contractions of the distal esophagus in $\geq 20\%$ of wet swallows alternating with normal peristalsis. Despite the recognition of the condition for over a century, the cause of the disease remains unknown. The role of gastroesophageal reflux disease in DES, has been suggested by several observations. Esophageal motility abnormalities induced by acid perfusion have been described since the late '60s. Coexisting gastroesophageal reflux disease has been reported to occur in 38–60% of patients with DES. Treatment of DES is imperfect and difficult due to the incomplete understanding of the pathophysiology and cause of this condition. Although there is no consensus on the role of acid reflux in DES, patients with coexisting GERD are suggested to use acid suppression instead of muscle relaxants, which may worsen their GERD. We believe that in case of patients where the above characterized simultaneous esophageal contractions develop on the ground of gastroesophageal reflux disease, DES can be considered as an adaptive reaction of the esophagus, as the contractions will after all impede the gastric refluxate to get into the esophagus or above.

1.2.4 Hypertensive upper esophageal sphincter

Several studies have reported a swift rise in upper esophageal sphincter (UES) pressure following the infusion of acid into the lower esophagus of healthy subjects. Tokashiki *et al.* termed this reflex-based rise in UES pressure “respiratory defense mechanism”. We presume that chronic acid exposure in the esophageal body likely leads to the hypertonicity of the UES, which can be considered as an adaptive mechanism.

In case of reflux induced HUES treatment strategy should in all cases comprise long-term acid suppression therapy after the esophageal dilation.

1.2.5 Zenker’s diverticulum

A large body of evidence supports the association between GERD and the development of a Zenker’s diverticulum. The formation of this diverticulum of the hypopharynx is the consequence of cricopharyngeal muscle hypertension, which is most likely induced by chronic acid exposure and can be regarded as a defensive mechanism of the esophagus precluding aspiration. The development of a Zenker’s diverticulum is an unwanted, indirect consequence of this protective hypertension of the cricopharyngeal muscle. Morales-Divo *et al.* found extraesophageal reflux in more than 72% of the patients with Zenker’s diverticulum. The same author reported that hiatal hernia was found in 39% of the patients with Zenker’s diverticulum, while it occurred only in 16% in the control group. Approximately 10% of patients undergoing antireflux surgery have short esophagus. Sasaki *et al.* presumed that acid reflux may induce longitudinal esophageal shortening, which in turn increases the risk for the development of herniation between two spatially related structures, the pharyngeal constrictors and cricopharyngeus muscles, leading to the development of Zenker diverticulum.

We recommend that when establishing the diagnosis of a Zenker’s diverticulum, the presence of GERD should be always excluded. If reflux is present, therapy should comprise either endoscopic or surgical treatment of the diverticulum, completed with cricopharyngeal myotomy and long-term acid suppression therapy.

1.2.6 Schatzki's ring

Schatzki's rings are lower esophageal rings that form at the esophagogastric junction. It is well established that 31–66% of SR patients are found to have pathologic gastroesophageal reflux on 24-h esophageal pH monitoring and nearly all of them have hiatal hernia. Several studies and anecdotal evidence suggested that dilation or incision in patients with symptomatic lower esophageal rings resulted in longer symptom-free survival and fewer recurrences if those were followed by treatment of GERD. This finding was confirmed by Sgouros *et al.* in a prospective study. These findings support an inflammatory etiology of the ring, promoted by acid reflux in the esophagus. We do not consider that the development of Schatzki's ring in reflux patients is an adaptive reaction, however, it clearly reduces acid exposure into the upper parts of the esophagus.

Mitre *et al.* found that Barrett's esophagus is less prevalent in patients with Schatzki's ring compared to patients without Schatzki's ring (0.73% vs. 1.80%). This observation supports the theory that Schatzki's ring protects the esophagus proximal to the ring from excessive acid exposure.

1.2.7 Esophageal web

An esophageal web is a thin, eccentric, smooth extension of normal esophageal tissue consisting of mucosa and submucosa that can be found anywhere along the esophagus. Similarly to Schatzki's ring, esophageal webs could be considered as secondary consequences of GERD, which ease the patient's symptoms of heartburn, however, their formation can not be regarded as a real adaptive mechanism.

1.2.8 Barrett's esophagus

The development of Barrett's esophagus can be regarded as a special form of accommodation of the esophagus against reflux. The metaplastic specialized columnar epithelium (SCE) of Barrett's esophagus arises in the setting of long-lasting GERD likely as replacement for acid-damaged squamous epithelium (SqE). As such, SCE is more acid-resistant than SqE and represents a form of "adaptive protection" against a hostile luminal environment. Consequently the long-lasting heartburn and other reflux symptoms may

ease as soon as patients develop Barrett's esophagus. This observation is also supported by routine histological findings, namely that biopsies taken from the intestinalized cardiac mucosa show little or no inflammation.

1.2.9 Esophageal stricture

Esophageal strictures are well-known severe complications of GERD that occur in approximately 10% of patients with untreated erosive esophagitis. Strictures have been associated with a hypotensive lower esophageal sphincter, hiatal hernia, motility dysfunction and bile reflux exposure. They usually occur in the lower esophagus, but may include the entire length of the thoracic esophagus. Most strictures cease to worsen when the esophagus is narrowed to a diameter of 1.5–2 cm. This near-complete lumen obliteration limits the gastric refluxate to go up to the proximal esophagus and beyond.

We observed in several of our own patients that as soon as the peptic stricture develops, esophagitis being proximal to the narrowing ceases. We believe that in case of reflux induced esophageal strictures, the luminal constriction is not an adaptive reaction against reflux, but a structural consequence of acid induced inflammation that will, as a matter of fact, finally lead to a reduced risk of pulmonary aspiration.

1.2.10 Subglottic tracheal stenosis

Several studies reported a strong association between extraesophageal reflux (EER) and development of subglottic tracheal stenosis (STS). Subglottic tracheal stenosis is not an esophageal pathology, therefore it can be considered as an odd one out in this thesis, however, narrowing of the upper airway in response to acid reflux can also be considered as a form of protective reaction against aspiration. Extraesophageal reflux has been implicated as a contributing or causative factor in the development of inflammatory lesions of the upper aerodigestive tract over the last several decades. Koufman *et al.* reported a study involving 32 patients with laryngotracheal stenosis (LTS) and found that 78% of the patients demonstrated laryngopharyngeal reflux with dual-probe 24-hour pH-metry. In a prospective study, Toohill *et al.* concluded that reflux to the pharynx, larynx and trachea would add insult to an intubated or injured airway, thus enhancing the development of a

stenosis. The authors found that identification and treatment of GER simplifies and improves the treatment of LTS and they suggested that all patients with LTS should be concomitantly managed for GERD. Jindal *et al.* studied seven patients with idiopathic subglottic stenosis (iSGS) by barium esophagogram, pH monitoring, and response to antireflux therapy and concluded that GER was the likely cause of iSGS. Strong evidence of the presence of EER in iSGS was published by Blumin *et al.*. In a prospective study involving 22 patients with iSGS, biopsies of the subglottic scar and postcricoid area were evaluated for the presence of pepsin. They found that one-half of the patients had pepsin embedded in the tissue of their larynx or subglottic scar. This finding was substantial and gave support that this condition is indeed a result of refluxed and microaspirated gastric contents.

Luminal stenosis of the subglottic trachea in response to EER decreases the risk of aspiration in the lower airways. In our interpretation, subglottic tracheal stenosis can be classified as a reflux induced structural consequence, which by the way, reduces the risk of aspiration.

1.3 CONCLUSION

In summary, the esophagus – and the airway – can react in various ways to chronic acid exposure. Patients with progressive GERD, refractory to medical treatment, may develop diverse structural and functional esophageal changes. The functional changes (HLES, HUES, achalasia, diffuse esophageal spasm) seem to be adaptive reactions aimed at easing the unpleasant symptoms and reducing acid regurgitation. The development of Barrett's esophagus can also be regarded as an adaptive change, as it is associated with a decrease in reflux symptoms. The structural changes (Schatzki's ring, esophageal web, esophageal stricture, subglottic tracheal stenosis) also result in decreased acid regurgitation, but we consider that these are rather secondary consequences of GERD and not adaptive mechanisms. We recommend that when establishing the diagnosis of a functional esophageal disorder, the etiology of GERD should be at all times ruled out, as it may alter therapeutic strategy. If reflux proves to be present, treatment should primarily focus on eliminating acid regurgitation.

CHAPTER 2

FUNCTIONAL EXAMINATION OF THE TRANSPOSED PYLORIC SPHINCTER IN ANTIREFLUX PORCINE MODELS: COULD IT BE SUITABLE TO CREATE A CONTINENT ILEOSTOMY?

2.1 INTRODUCTION

In our study, we planned a two-stage animal experiment aimed at examining different uses of the pyloric sphincter in ectopic positions. The primary purpose of our experiment was to evaluate whether the pyloric sphincter based on the left gastroepiploic arterial pedicle could be technically transposed around the esophagogastric junction that had been previously weakened by circular myectomy, hereby artificial gastroesophageal reflux was created. We investigated whether creation of a pyloric wrap could be an alternative of fundoplication. Beyond the technical feasibility, we examined if the valve preserved its pharmacological responsiveness in the new, ectopic position. In the second series of our experiment we aimed to examine the use of the pyloric ring in the construction of a continent ileostomy, by wrapping a pedicled pyloric sphincter around the efferent loop of a small intestine reservoir.

2.2 METHODS

2.2.1 Antireflux model

In the first series of our experiment 6 pigs underwent surgical transposition of a pedicled pyloric sphincter around the gastroesophageal junction, where circular myectomy, hereby artificial gastroesophageal reflux had been previously created. After a midline laparotomy, the gastrocolic omentum was dissected off the transverse colon. The branches of the gastroepiploic vascular arcade to the greater curvature of the stomach were divided. Mobilization of the gastroepiploic arcade started at the upper margin of the pylorus, detachment then proceeded to include one-half to two-thirds of the greater curvature.

The right gastroepiploic artery was ligated and divided at the lower margin of the pylorus. The antral and duodenal ends of the pyloric valve were cut. The pyloric ring was, from here on, based on the left gastroepiploic artery. Gastroduodenostomy was performed to restore the gastrointestinal continuity. (*Figure 1*)

After this, we excised the muscular layer of the lower esophageal sphincter. The pyloric ring was cut on the lesser curvature side, and sutured around the impaired distal esophagus. In all animals, changes in the microcirculation of the pyloric ring were measured by laser Doppler flowmetry (LDF) before and after the transposition. Similarly, changes in the intraesophageal pressures were measured before and after the cardiomyectomy and after the transposition of the ring around the cardia. After this, half of the animals received parasympathomimetics (*neostigmine* 0.2 mg), the other half nitrovasodilators (*glyceryl trinitrate* 4 mg) systematically, then the intraesophageal pressure and microcirculation of the transposed pylorus were measured again.

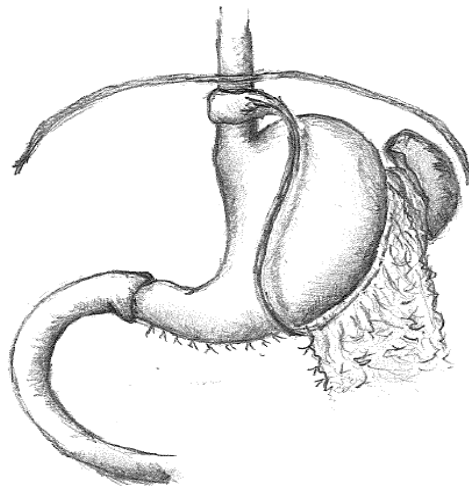


Figure 1. Pyloric sphincter based on the left gastroepiploic artery and transposed around the weakened gastroesophageal junction

2.2.2 Continent ileostomy model

In the second series of our experiment, we aimed to create continent ileostomy in porcine models with the use of a pedicled pyloric sphincter, wrapped around the efferent loop of a 3-limb S-pouch. (*Figure 2*) We involved 2 pigs in the study. After a midline laparotomy, an end ileostomy with an S-pouch was created in both subjects. The pyloric ring

based on the left gastroepiploic arterial pedicle was dissected the same way as described before, the pylorus was then cut on the anti-mesenteric side and placed next to the ileostomy, where it was wrapped around the small intestine between the abdominal wall and the S-pouch. Pharmacological responsiveness of the transposed pyloric ring to drugs was not examined in these cases.

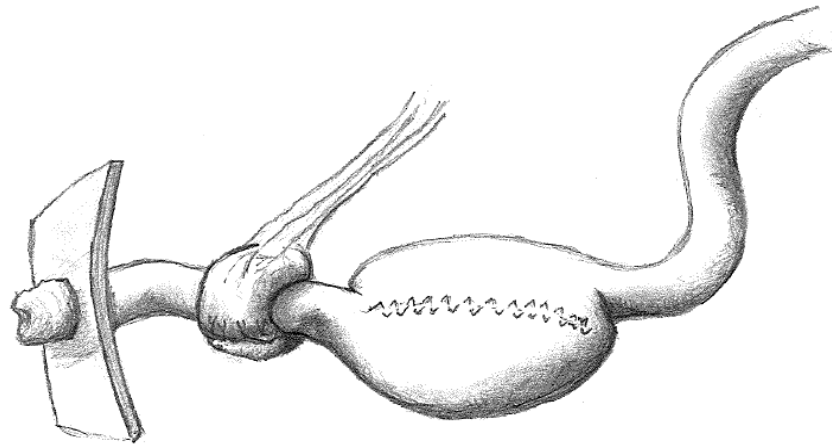


Figure 2. Pyloric sphincter based on the left gastroepiploic artery and transposed around the efferent loop of a S-pouch

2.3 RESULTS

Transposition of the pedicled pyloric ring around the impaired cardia is technically feasible, the pyloric flap preserved its viability throughout the operation. However, the lumen of the ring was too narrow to surround appropriately the esophagus, and most likely would have caused dysphagia on the long term. The pharmacological responsiveness of the ring in the ectopic position, however, could be examined very well.

Microcirculation of the sphincter with the gastroepiploic artery (GEA) pedicle barely changed after it was removed from the gastroduodenal continuity (33 BFU vs. 32 BFU), which proves the completeness of the gastroepiploic arcade. After the creation of the pyloric cuff around the weakened cardia, 3 animals were given *glyceryl trinitrate* 4 mg (Group A), while the other 3 received *neostigmine* 0.2 mg intravenously (Group B). 3 minutes later, laser Doppler flowmetry showed that microcirculation of the ring increased in Group A (40 BFU) and decreased in Group B (28 BFU). Parallely, we measured the intraesophageal pressure at different stages of the operation. The average basic pressure of

the intact cardia was 42 mmHg, which dropped to an average of 26 mmHg after the partial cardiomyectomy. Then, as the cut pyloric ring was sutured around the weakened cardia with its original diameter, the intraesophageal pressure rose to an average of 72 mmHg. This value suggests that the ring is too narrow to use as a cuff around the esophagus, and would probably cause dysphagia in the animal. In Group A, 3 minutes after the injection of *glyceryl trinitrate*, the intraesophageal pressure dropped to an average of 65 mmHg. In Group B, the injection of *neostigmin* led to further increase in the intraesophageal pressure after 3 minutes (84 mmHg).

The continent ileostomy model was technically feasible, the left gastroepiploic arterial pedicle was sufficiently long to reach the ileostomy. The pyloric ring preserved its viability in the ectopic position until the end of the study.

2.4 DISCUSSION

For solitary defective lower esophageal sphincters fundoplication is the gold standard surgical treatment, though its popularity has somewhat declined due to concerns regarding wrap durability and adverse events. These complications inspired us to search for an alternative, new antireflux procedure that may possibly eliminate these undesirable complications and side-effects. Gaining confidence from the publications on the successful transfer of the pyloric sphincter into the anal region, we got the idea to use a pedicled pyloric sphincter to restore the high pressure zone of a weakened lower esophageal sphincter. The cut pyloric ring was sutured around the impaired gastroesophageal junction at its original diameter. Manometry then showed that the distal intraesophageal pressure increased from 26 mmHg to 72 mmHg, meaning that the pyloric ring is a too tight structure to restore an antireflux barrier and the animal would very likely experience difficulty swallowing in the future. So we concluded that, however, the operation itself was technically feasible, the pyloric sphincter would not be suitable to replace a damaged lower esophageal sphincter due to its narrow lumen and high resting tone. Regardless of this finding, we continued the experiment to explore the response of the ring to different drugs. Injection of *neostigmine* caused contraction in both the smooth muscle of the ring and in its vessels. In contrast to this, a bolus of intravenous *glyceryl trinitrate* resulted in rise in the microcirculation, and in the relaxation of the ring. These findings provided evi-

dence that the cut and re-sutured pedicled pyloric sphincter responded to drugs in the new, ectopic position with muscle contraction and relaxation and with changes in the microcirculation. This effect met our expectations, since in our second series of experiment, as a preliminary study, we aimed to create a completely continent ileostomy by suturing a pedicled pyloric sphincter as a constricting force around the efferent loop of the ileal reservoir and thus providing constant continence, which could then be intentionally opened by controlled pharmacological relaxation of the pedicled pyloric ring. The diameter of the pyloric ring was calibrated to the diameter of the bowel, with care taken to avoid ischaemization of the intestine. The operation was technically feasible, and at reoperation on the second postoperative day, we found that the pyloric ring was viable and caused no ischaemia on the bowel. An ileostomy of this kind could offer patients constant continence without facing the valve related complications of the S-pouch. It is indisputable that this technique will not allow the pouch either to drain itself deliberately and patients will have to intubate their reservoirs for evacuation in the future too, but avoiding complications related to valve dysfunction could be considered as an advantage.

CHAPTER 3

PROGNOSTIC ROLE OF HPV INFECTION IN ESOPHAGEAL SQUAMOUS CELL CARCINOMA

3.1 INTRODUCTION

Esophageal cancer is the eighth most common malignant tumor and the sixth leading cause of cancer mortality worldwide. Esophageal cancer has a poor prognosis with a 5-year survival rate around 15–20%, mainly due to the absence of early symptoms and therefore late stage diagnosis. The incidence of squamous cell carcinoma of the esophagus varies considerably from place to place, suggesting an important role of environmental factors in its etiology. The hypothesis that HPV could potentially be involved in the pathogenesis of esophageal malignancies was first proposed by Syrjänen *et al.* in 1982. Since then, several systematic reviews and meta-analyses have been published that ob-

served a close association between HPV infection and the incidence of ESCC. However, the presumed underlying oncogenic mechanisms of HPV-induced esophageal squamous cell carcinoma are poorly understood, and until now, the International Agency on Research on Cancer has not made a definite statement on the potential etiologic relationship between HPV and ESCC.

The impact of HPV infection on response to the oncological treatment and survival is not fully elucidated yet. It is well known, that patients with locally advanced esophageal cancer respond differently to neoadjuvant therapy, due to unexplained factors. So far no clinically relevant markers have been found that could predict the response to preoperative therapy.

Our study aimed to evaluate the effect of tumor HPV status on the prognosis and response to CRT in patients with ESCC. It was also our goal to investigate the correlation between the expressions of Hsp-s (90, 27, 16.2), GHRH-R and response to therapy and overall survival.

3.2 PATIENTS AND METHODS

3.2.1 Patients

A retrospective histological examination of pre-treatment tumor tissue samples from patients with locally advanced esophageal squamous cell carcinoma was carried out. All patients received chemoradiotherapy at the Department of Oncotherapy, Clinical Center, University of Pécs, Hungary, between 2006 and 2016. Following oncological treatment, patients either underwent surgery or continued chemoradiotherapy. 74 patients were enrolled in the study. All patients had squamous cell cancer, with stages cT3-4, cN0-2, cM0-1. Six weeks after the oncological treatment, patients were restaged according to the Response Evaluation Criteria in Solid Tumors (RECIST). In order to simplify the evaluation of the results, patients were divided into two groups: *responders* including patients who showed complete or partial response and *non-responders* including patients where either stable disease or disease progression were observed.

3.2.2 HPV detection

Sections from the pre-treatment tumor tissue samples were fixed in formalin and embedded in paraffin. The presence of HPV was detected by chromogenic in situ hybridization (CISH) using ZytoFast PLUS Implementation Kits. This system detects HPV types 6, 11, 16, 18, 31, 33, 35, 45, 51 and 82.

3.2.3 Immunohistochemical staining for Hsp 90, 27 and 16.2 and GHRH-R

Immunohistochemical reactions were carried out by LEICA BOND automated staining machines, using polyclonal rabbit antibodies directed against the human Hsp 90, 27, 16.2 and GHRH-R.

The immunostaining was interpreted by our pathologist blindly, without knowledge of the treatment response rate of the patients. The presence of cytoplasmic staining with or without nuclear staining was required to assign the positivity for heat shock proteins and GHRH-R. Staining intensity was finally sorted into two classes: *high-intensity* and *low-intensity* samples.

3.3 RESULTS

3.3.1 Clinical and patient data

Of the 74 patients participating in the study, 22 patients (30%) received neoadjuvant CRT and 52 patients (70%) received definitive CRT due to their general condition and/or advanced stage of the disease. 38 patients (51%) responded well to therapy. Ultimately, 14 out of the 22 patients, who had neoadjuvant CRT, underwent surgical resection. Reasons for not having surgery included: not responding well to CRT (5 patients), refusing to consent to surgery (2 patient) and death (1 patient). 14 (19%) of the 74 ESCC patients were found to be HPV positive with CISH.

Regarding the distribution of the sexes and locations of the tumors, in the HPV positive group we found a male:female ratio of 8:6, where 4 patients had upper third, 6 patients had middle third and 4 patients had lower third esophageal tumor, while in the

HPV negative group the male:female ratio was 5:1, and among them 8 patients had upper third, 35 had middle third and 17 had lower esophageal tumor.

3.3.2 Effects of HPV status on response to therapy and prognosis

Comparing the HPV status and the clinical response to CRT, we found that HPV positivity was associated with a higher rate of non-responder patients (71.4% non-responders vs. 28.6% responders), however, this difference was not significant (Chi-Square $p=0.058$). Similarly, the overall survival of HPV-positive patients was shorter compared to HPV-negative patients (mean survival of 8 months vs. 11 months and median survival of 6 months vs. 7 months), but this difference was also not significant (log-rank $p=0.898$)

3.3.3 Relationship between HPV status and expressions of Hsp 16.2, 27, 90 and GHRH-R

Significantly more HPV positive tumors expressed Hsp 90 and 16.2 at high intensities than at low intensities (Chi-Square $p=0.019$ and $p=0.031$). On the other hand, there was a near-equal distribution of low and high intensity Hsp staining in HPV negative tumors. No significant correlation could be observed between the Hsp 27 and GHRH-R expression patterns and HPV positivity.

3.3.4 The effects of Hsp expression on response to therapy

Among non-responders, there were significantly more tumors, which expressed Hsp 90 and 16.2 at high levels (Chi-Square $p<0.001$ and $p<0.01$). This tendency was also apparent in the expression levels of Hsp 27, but the difference was not significant. We also found that patients with tumors that expressed Hsp-s at high levels had a significantly shorter overall survival, than patients with tumors that stained low for Hsp-s.

3.4 DISCUSSION

In recent years, a large number of studies have investigated human papillomavirus infection in esophageal squamous cell carcinoma, with largely inconclusive results. The detection rates of HPV-ESCC show high variability worldwide. In our study, the rate of HPV positivity in ESCC patients was 19%. HPV infection in esophageal cancer as a possible predictive factor before neoadjuvant therapy has also been a subject of ongoing debate. In our study, we found that HPV positive patients responded worse to CRT and had worse overall survival than the HPV negative group. Therefore, HPV positivity was a negative prognostic factor in relation to multimodal therapy and to overall survival, though the differences were not significant. We also examined the anti-apoptotic Hsp 90, 27 and 16.2 expression patterns in the pre-treatment tumor biopsies. We investigated whether HPV infection, as an environmental insult, influences the Hsp expression pattern of ESCC patients. We found elevated Hsp 90 and 16.2 expression levels in the HPV-positive tumor samples compared to the HPV negative ones. As expected, increased levels of Hsp 90 and 16.2 expression, were associated with significantly poorer response to CRT and worse overall survival. It is unclear why HPV positivity in ESCC patients proves to be a negative prognostic marker in certain regions of the world, while in others it is a positive prognostic marker. We have set up a hypothesis for this. In regions where the HPV detection rate in esophageal tumors is high, a positive correlation can be observed between HPV positivity and response to treatment. We presume that in these cases the viral infection plays a role in the cancerogenesis itself, while in the low-risk regions, the development of cancer is attributed to other factors, such as poor socioeconomic environment, excessive alcohol and tobacco consumption, and HPV only superinfects the esophagus. The evaluation of p16 expression, a surrogate biomarker for HPV infection, is also of importance regarding prognosis of ESCC. Expression of p16 in ESCC means an active HPV infection in tumor cells and has been shown to correlate with higher rate of pathologic complete remission in patients undergoing neoadjuvant chemotherapy, compared with p16 negative individuals, who carry HPV DNA. We presume that this may be attributed to the fact that in p16 positive individuals the virus itself induced the cancerogenesis, while in p16 negative cases that were HPV DNA positive, HPV means only a superinfection of the tumorous cells. This superinfection, as an environmental insult,

could lead to an increased expression of heat shock proteins, and as a consequence these tumors respond worse to anticancer treatments. This hypothesis brings up an unanswered issue of the current understanding of the epidemiology and biology of HPV-associated esophageal squamous cell carcinoma.

Today, the Advisory Committee on Immunization Practices (ACIP) recommends routine HPV vaccination for females and males at age 11 or 12 years, to prevent infection with HPV types that are associated with certain cancers, including cervical, vaginal, vulvar, anal, throat and penile cancers. The recommendation doesn't comprise the prevention of HPV-associated esophageal cancers, however, growing literature demonstrates that the virus is involved in the development of esophageal squamous cell carcinoma or may worsen the prognosis. In our opinion, extension of the indications of prophylactic immunization is imperative.

In our study, we found association neither between GHRH-R expression and the HPV status, nor between GHRH-R expression and response to treatment.

In conclusion, the present study found that one-fifth of the patients with ESCC proved to have HPV positive tumors in Hungary's Southwestern region. HPV positivity was accompanied by significantly increased expressions of Hsp 90 and 16.2. HPV positive cases and cases expressing high intensity Hsp 90 and 16.2 levels showed a significantly poorer response to oncological treatment and worse overall survival. Given the limited sample size, the results of this report should be interpreted with caution.

NOVEL FINDINGS

ESOPHAGEAL COMPLICATIONS OF GASTROESOPHAGEAL REFLUX DISEASE: CONSEQUENCES OR DEFENSIVE REACTIONS?

- 1 This study was the first to discuss gastroesophageal reflux disease as a potential causative factor in the development of nine different esophageal and one airway disorders that result in decreased reflux symptoms, reduced acid regurgitation, and through this they reduce the risk of aspiration as well. We concluded that the functional esophageal changes (HLES, HUES, achalasia, diffuse esophageal spasm) that develop following long-standing GERD are adaptive reactions, aimed at easing the unpleasant reflux symptoms and reducing acid regurgitation. The development of Barrett's esophagus can also be regarded as an adaptive change, as it is associated with a downturn in reflux symptoms. The structural changes (Schatzki's ring, esophageal web, esophageal stricture, subglottic tracheal stenosis) also result in reduced acid regurgitation, but we consider that these are rather secondary consequences of GERD and not real adaptive mechanisms.
- 2 Based on our experiences and review of the literature we assume that in those functional esophageal disorders, where the etiological role of GERD arises, therapeutic strategy should be different from that of the same, but primary esophageal motility disorder. In all of these cases, therapy should focus on the treatment of GERD. Our recommendation is as what follows in case of GERD induced
 - HLES: laparoscopic total (Nissen 360°) fundoplication
(not recommended: myotomy of the LES + fundoplication)
 - HUES: dilation therapy and long-term treatment with acid suppression medication
(not recommended: myotomy of the UES)
 - Zenker's diverticulum: surgical or endoscopic treatment of the diverticulum + cricopharyngeal myotomy + long-term treatment with acid suppression medication
 - achalasia: laparoscopic Heller's myotomy and total (Nissen 360°) fundoplication
(not recommended: ballon dilation)

- DES: long-term treatment with acid suppression medication
(*not recommended: use of smooth muscle relaxants*)

FUNCTIONAL EXAMINATION OF THE TRANSPOSED PYLORIC SPHINCTER IN ANTIREFLUX PORCINE MODELS: COULD IT BE SUITABLE TO CREATE A CONTINENT ILEOSTOMY?

- 3 Transposition of a pedicled pyloric sphincter around the impaired gastroesophageal junction is technically feasible, however, it cannot be recommended for antireflux procedure due to the narrow lumen and high resting tone of the pyloric ring, which would lead to dysphagia in this location.
- 4 Our animal study proved evidence that the pedicled pyloric ring preserved its pharmacological responsiveness in the ectopic position. Injection of *neostigmine* resulted in contraction in both the smooth muscles of the ring and in its vessels. Injection of *glyceryl trinitrate* resulted in relaxation of the ring and in an increase in the microcirculation of the ring.
- 5 In our second animal study, our novel approach to create a continent ileostomy with the use of a pyloric sphincter based on the left gastroepiploic artery proved to be technically feasible. Planned reoperation revealed that the ring did not cause ischaemia on the small intestine.

PROGNOSTIC ROLE OF HPV INFECTION IN ESOPHAGEAL SQUAMOUS CELL CARCINOMA

- 6 In our study, the rate of HPV positivity in Hungarian esophageal squamous cell cancer patients corresponded to that of the low risk countries, namely, 19% of the patients were confirmed to be HPV positive by CISH.
- 7 In our study, the distribution of HPV positivity in the upper, middle and lower thirds of the esophagus were 28,6%, 42,8% and 28,6%, respectively. Thus, upper third cancers did not harbour higher rates of HPV, as it could have been expected due to the proximity of the oral cavity.

- 8 In our study, we found that HPV infection was associated with worse response to oncological treatment and decreased overall survival, and therefore proved to be a negative prognostic factor in patients with esophageal squamous cell carcinoma.
- 9 In our study, we found that HPV positivity was associated with high expression levels of Hsp 90 and 16.2. High expression levels of Hsp 90 and 16.2 were associated with worse prognosis. We found association neither between Hsp 27 or GHRH-R expression and the HPV status, nor between Hsp 27 or GHRH-R expression and response to treatment.

LIST OF PUBLICATIONS AND PRESENTATIONS

PUBLICATIONS RELATED TO THE THESIS

CUMULATIVE IMPACT FACTOR 10.697

Bognar L, Vereczkei A, Papp A, Jancso G, Horvath OP. Gastroesophageal reflux disease might induce certain – supposedly adaptive – changes in the esophagus: a hypothesis. *Dig Dis Sci*. 2018 Oct;63(10):2529-2535. doi: 10.1007/s10620-018-5184-3.

IF 2.819 (Q1)

Bognar L, Hegedus I, Bellyei Sz, Pozsgai E, Zoltan L, Gombos K, Horvath OP, Vereczkei A, Papp A. Prognostic role of HPV infection in esophageal squamous cell carcinoma. *Infect Agent Cancer*. 2018; 13: 38. doi : 10.1186/s13027-018-0210-9.

IF 2.123 (Q2)

Bognar L, Vereczkei A, Horvath OP. Gastroesophageal reflux disease could progress to achalasia. *J Neurogastroenterol Motil*. 2017 Oct; 23(4): 618. (Letter to the Editor)

IF 3.438 (Q2)

Bognar L, Horvath OP, Jancso G, Vereczkei A (2016). GERD: A debated background of achalasia. *J Gastrointest Dig Syst* 6:432. doi:10.4172/2161-069X.1000432.

Bognar L, Horváth OP, Solt J, Jancso G, Vereczkei A. Laparoskopópos hiatus hernia rekonstrukciót követő intraoesophagealis hálómigráció. *Magy Seb*. 2015 Aug; 68(4): 176–80.

Vereczkei A, **Bognar L**, Papp A, Horváth OP. Achalasia following reflux disease: coincidence, consequence, or accommodation? An experience-based literature review. *Ther Clin Risk Manag*. 29 Dec 2017; 14: 39–45. IF 1.995 (Q1)

Horváth OP, **Bognar L**, Papp A, Vereczkei A. Esophageal complications of gastroesophageal reflux disease: consequences or defensive reactions? *Orv Hetil*. 2017 May; 158(20): 763–769. IF 0.322 (Q4)

Horváth OP, Varga G, Biro Z, Papp A, **Bognar L**, Vereczkei A. Complications and reoperations following laparoscopic antireflux surgery. *Magy Seb.* 2016 Sep; 69(3): 91–9.

ABSTRACTS THAT CAN BE CITED RELATED TO THE THESIS

Bognár L, Horváth ÖP, Vereczkei A. GERD indukálta achalasia. Magyar Sebész Társaság Dunántúli Szekciójának Tudományos ülése. Veszprém, 2015. május 29–30.

Bognár L, Horváth ÖP, Papp A, Vereczkei A. GERD indukálta achalasia? FIGAMU XI. Kongresszusa, Balatonalmádi, 2016. április 15–17.

Bognár L, Horváth ÖP, Papp A, Vereczkei A. GERD: a debated background of achalasia. European Congress of Clinical Case Reports. 8-9 March, 2017 - Vienna, Austria

Bognár L, Bellyei Sz, Pozsgai É, Hegedüs I, László Z, Vereczkei A, Horváth ÖP, Papp A. A HPV státusz prediktív szerepe onkológiai kezelésben részesülő nyelőcső laphámrákos betegeknél. A Magyar Sebész Társaság Sebészeti Onkológiai Szekciójának 1. Kongresszusa. Szeged, 2017. március 23–25.

Bognár L, Bellyei Sz, Pozsgai É, Hegedüs I, László Z, Vereczkei A, Horváth ÖP, Papp A. A HPV státusz prediktív szerepe onkológiai kezelésben részesülő nyelőcső laphámrákos betegeknél. A Magyar Sebész Társaság 2018. évi kongresszusa. Debrecen, 2018. május 24–26.

Bognar L, Horvath OP, Tanczos B, Szabo B, Deak A, Nemeth N, Jancso G. Functional examination of the pyloric sphincter transposed around an impaired cardia: an experimental animal study. 53rd Congress of the European Society for Surgical Research. Madrid, Spain. 30 May–2 June 2018.

Bognar L, Bellyei Sz, Pozsgai E, Hegedus I, Laszlo Z, Vereczkei A, Horváth OP, Papp A. Prognostic role of HPV infection in esophageal squamous cell carcinoma. 16th World Congress of the International Society for Diseases of the Esophagus, Vienna, Austria. 16–19 September 2018.

Bognár L, Bellyei Sz, Pozsgai É, Hegedűs I, László Z, Vereczkei A, Horváth ÖP, Papp A. Prognostic role of HPV infection in esophageal squamous cell carcinoma. 38th Congress of the European Society of Surgical Oncology, Budapest. 10–12 October 2018.

OTHER PUBLICATIONS

Petrovics L, Nagy T, Hardi P, **Bognár L**, Pavlovics G, Tizedes G, Takacs I, Jancso G. The effect of trimetazidine in reducing the ischemia-reperfusion injury in rat epigastric skin flaps. *Clin Hemorheol Microcirc.* 13 April 2018. **IF 1.914 (Q2)**

Zoltan L, Farkas R, Schally AV, Pozsgai E, Papp A, **Bognár L**, Tornoczki T, Mangel L, Bellyei S. Possible predictive markers of response to therapy in esophageal squamous cell cancer. *Pathol Oncol Res.* 4 November 2017. doi: 10.1007/s12253-017-0342-z. **IF 1.935 (Q2)**

OTHER ABSTRACTS AND PRESENTATIONS

Bognár L, Papp A, Kalmár NK, Vereczkei A. Sikeres májmetastasectomia biológiai terápiával kombinált neoadjuváns kemoterápiát követően. *Fiatal Sebészek Szekciójának II. Kongresszusa.* Balatonalmádi, 2014. április 4–6.

Bognár L, Jakab L, Benkő I, Szántó Z, Vereczkei A. Nyitott thoracotomia ritka szövődménye. *Fiatal Sebészek Szekciójának III. Kongresszusa.* Balatonalmádi, 2015. április 15–17.

Bognár L, Pavlovics G, Horváth OP. Szövődményes nyelőcső pótlás utáni antethoracalis rekonstrukció bőrcsővel és szabad jejunum átültetéssel. *Magyar Sebész Társaság Fiatal Sebészek Szekciójának V. Kongresszusa.* Balatonalmádi, 2017. április 7–9.

Bognár L, Pavlovics G, Horváth OP. Szövődményes nyelőcső pótlás utáni antethoracalis rekonstrukció bőrcsővel és szabad jejunum átültetéssel. *Magyar Plasztikai Helyreállító és Esztétikai Sebész Társaság.* Kecskemét, 2017. november 2–4.

CUMULATIVE IMPACT FACTOR OF ALL PUBLICATIONS: 14.546

ACKNOWLEDGEMENT

I owe a great debt of gratitude to Prof. emer. Örs Péter Horváth for his excellent guidance, continuous support and irreplaceable help throughout my PhD studies.

I express my sincere appreciation to András Papp for his constant encouragement and valuable suggestions.

I would like to emphasize my deepest gratitude towards Gábor Jancsó for his generosity and sincere support.

I cordially acknowledge the support of Prof. András Vereczkei who provided me opportunity to peacefully work on my thesis and always helped to improve my manuscripts.

I am grateful for the help of all the members of the Department of Operative Techniques and Surgical Research, University of Debrecen, who contributed to my work.

I am also thankful to all my colleagues at the Department of Surgical Research and Techniques and at the Department of Surgery for always providing a joyful atmosphere.

Finally, I wish to express my gratitude to my parents and my grandmother, for their unlimited love and unconditional support throughout my entire life.