

**New technical and clinical aspects in the
management of radiofrequency catheter ablation
of frequent premature ventricular contractions**

Ph.D. Thesis

Author: Csaba Herczku, M.D.

Project leader: Prof. Kálmán Tóth, M.D., D.Sc.

1st Department of Medicine

University of Pécs, Medical School

Tutors: Antonio Berruezo, M.D., Ph.D.

Cardiology Department, Thorax Institute, Hospital Clinic, Barcelona

and

Zoltán Csanádi, M.D., Ph.D.

Institute of Cardiology, University of Debrecen

2014.

Table of contents

I. New mapping data predictors of a left ventricular outflow tract origin of idiopathic ventricular arrhythmias	6.
I. 1. Introduction	6.
I.1.1. Background	6.
I.1.2. Anatomical considerations	10.
I.1.3. The 12 lead ECG	12.
I.1.4. Mapping and ablation of OT VAs	14.
I.2. Aims and the corresponding electrophysiological considerations	17.
I.3. Methods	18.
I.3.1. Patient characteristics	18.
I.3.2. Electrophysiologic study	19.
I.3.3. Mapping and ablation	19.
I.3.4. Data collection	20.
I.3.5. Statistical analysis	22.
I.4. Results	22.
I.4.1. Patient population	22.

I.4.2. Surface ECG and RVOT mapping data	23.
I.4.3. Coronary sinus mapping	29.
I.5. Discussion	31.
I.5.1. Surface ECG	31.
I.5.2. Mapping data	32.
I.5.3. Study limitations	34.
I.6. Conclusions	35.
II. The impact of RFCA of frequent PVC on left ventricular systolic function in patients with cardiac resynchronization therapy	36
II.1. Introduction	36.
II.2. RFCA of PVC improved the left ventricular function in a nonresponder to cardiac resynchronization therapy, the first clinical description	37.
II.2.1. Case report	37.
II.2.2. Limitations and clinical considerations	41.
II.3. Further investigations	42.
II.4. Discussion	44.
II.5. Conclusion	46.

III. References	47.
IV. Acknowledgements	58.
V. List of the author's publications	59.

List of abbreviations

OT: outflow tract

VA: ventricular arrhythmia

LBBB: left bundle branch block

LV: left ventricular

RBBB: right bundle branch block

PVC: premature ventricular contraction

VT: ventricular tachycardia

RFCA: radiofrequency catheter ablation

RV: right ventricular

SOO: site of origin

RVOT: right ventricular outflow tract

LVOT: left ventricular outflow tract

EG: intracardiac electrogram

RF: radiofrequency

CS: coronary sinus

CRT: cardiac resynchronization therapy

TDI: tissue Doppler imaging

I. New mapping data predictors of a left ventricular outflow tract origin of idiopathic ventricular arrhythmias

I.1. Introduction

I.1.1. Background

Idiopathic outflow tract (OT) ventricular arrhythmias (VA) occur in the absence of structural heart disease and are generally considered a benign disorder (1). However, they are frequently clinically symptomatic and may cause invalidating symptoms like palpitation, fatigue, dizziness and rarely syncope and may lead to tachycardia induced cardiomyopathy (2,3). These patients represent 10% of all ventricular tachycardia cases and this is the most frequent idiopathic VA. The OT VAs have a characteristic ECG pattern with inferior frontal QRS axis and show left bundle branch block (LBBB) or in some cases of a left ventricular (LV) origin right bundle branch block (RBBB) morphology (Figure 1).

These arrhythmias have a focal origin and the underlying cellular electrophysiological mechanism is thought to be calcium-channel dependent delayed after depolarization caused triggered activity mediated by cyclic adenosine monophosphat (4). The clinical appearance of the arrhythmia may be premature ventricular contraction (PVC), non sustained or sustained ventricular tachycardia (VT) (Figure 2).

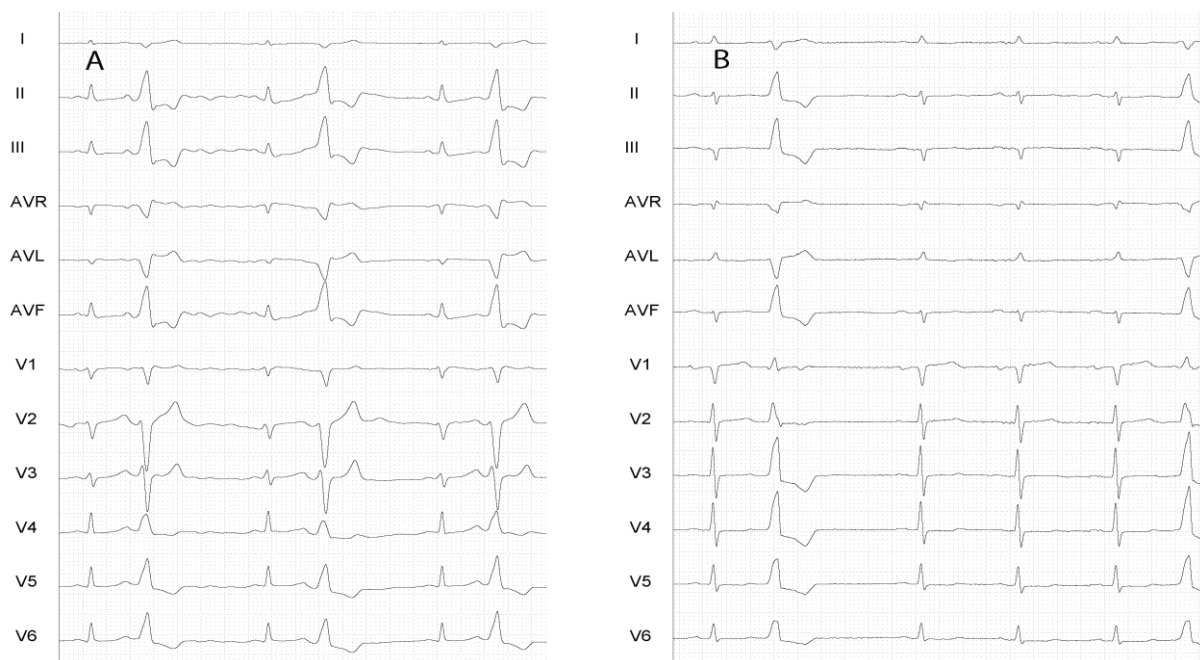


Figure 1. Typical ECG patterns of ventricular extrasystoles originating from the OTs. Panel A demonstrates an extrasystole from the right while panel B from the left ventricular OT. Although the axis in the frontal plane is similar, the ECGs in the precordial leads are different.

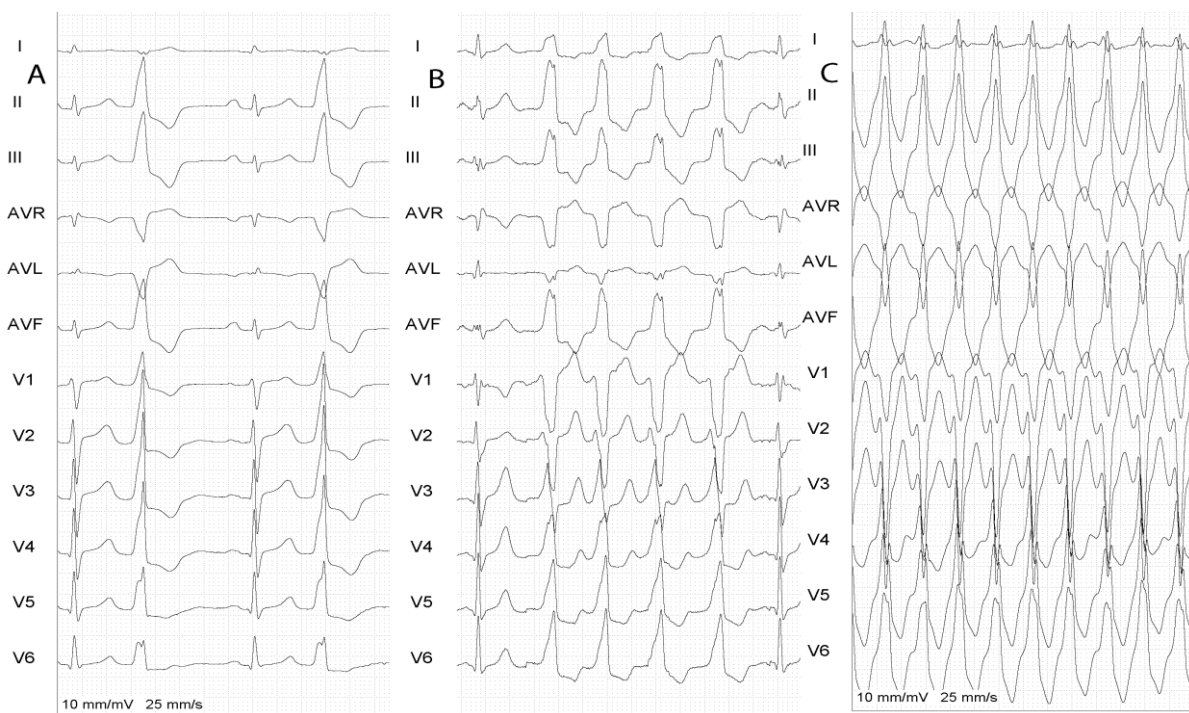


Figure 2. Typical clinical appearance of OT VAs. Isolated monomorphic ventricular extrasystole (A), non sustained ventricular tachycardia (B) and sustained ventricular tachycardia (C).

In addition to pharmacological therapy, radiofrequency catheter ablation (RFCA) was introduced in the early 1990's (5,6) for the definitive treatment of idiopathic right ventricular (RV) and LV OT VAs with high success and low complication rate. Later on electroanatomical mapping systems with MR or CT image integration were introduced providing more detailed information about the OT anatomy and arrhythmia origin thus further increasing the success rate and safety of RFCA (Figure 3).

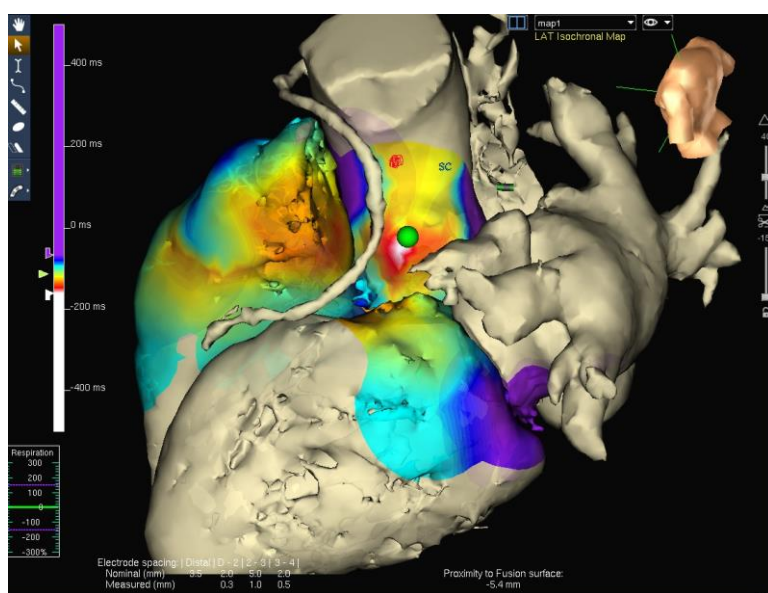


Figure 3. The use of electroanatomical mapping system (in this case NavX) and 3D CT image integration. The arrhythmia was originated in the aortic root marked with green dot (with courtesy of Barcelona Hospital Clinic, David Andreu, PhD).

OT VAs most frequently arise in patients without structural heart disease in relatively early age but differences in age, gender and comorbidities (e.g. hypertension) were demonstrated depending on the site of origin (SOO) (7,8,9). Since an underlying cardiomyopathy was an exclusion criterion in most of the previous studies, we know very little about the presence and distribution of structural heart disease in this patient population. However, in clinical practice these arrhythmias frequently emerge in

patients with coexisting cardiomyopathy. The left ventricular dilation and decrease in ejection fraction may be a consequence of the arrhythmia and is reversible after the RFCA (2,3,10,11,12) both in right ventricular outflow tract (RVOT) and left ventricular outflow tract (LVOT) VAs. Nevertheless, there is a lack of information about the presence of non tachycardia induced cardiomyopathy and comorbidities like hypertension, diabetes, hyperlipidaemia and their relation to the arrhythmia origin in this patient population. If such a difference could have been demonstrated in RV versus LVOT VAs, it may have a predictive value in the differentiation of these arrhythmias before RFCA.

Although the common electrophysiological mechanism of RV versus LVOT VA was proved (13), the technical aspects, difficulties and risk of RFCA significantly differ depending on the SOO and several algorithms have been developed to determine the SOO based on surface electrocardiogram analysis (14,15,16). However, the close proximity of the OTs (17), the presence of ECG abnormalities during sinus rhythm, and sometimes the presence of cardiomyopathy frequently result in an overlap in surface ECG features. In addition, intracardiac electrogram (EG) precocity, which is basically used for mapping the arrhythmia focus, varies greatly in patients with OT VAs, showing an overlap between successful and unsuccessful RFCA sites (18,19,20,21). Based on the surface ECG analysis, when the transition in the precordial leads occurs in V3 and during intracardiac mapping the maximum electrogram precocity is located in the septal RVOT, there are no reliable criteria to predict RV versus LV origin. This circumstance may result in extensive, unsuccessful, and unnecessary radiofrequency (RF) applications. A stepwise method previously described by Tanner et al. (22) proposed the mapping of six different anatomic structures in patients with OT tachycardia and an R/S transition in lead V3. In this approach a systematic mapping was recommended in the

RVOT, pulmonary artery, coronary sinus (CS), aortic sinuses, left ventricle and finally in the epicardium via percutaneous pericardial access. This time consuming and potentially high risk approach would be unnecessary if we had a right ventricular mapping parameter, which predicts the SOO accurately.

The aim of the recent work was to find new mapping data predictors of a LV origin in OT VAs, what may help us to design the ablation strategy.

I.1.2 Anatomical considerations

The outflow tracts are defined as those anatomic regions in the right or left ventricle where these chambers continue into the great vessels, the pulmonary trunk and the aortic root. The close relationship between the OTs is a consequence of their embryological development. The distal portion of the initial primitive heart tube after looping separates into two distinct regions by septation and forms the RVOT and LVOT (23). It is important to note that the OT region is one of the heart's transitional zones that have slow conduction properties which can explain their arrhythmogenic feature. The embryological development also explains the close anatomical relation between the OTs (17,24). The RVOT lies anterior to the LVOT and courses from rightward to leftward direction. The two structures are separated by the interventricular septum in their proximal portion, while their distal part is separated by pericardial space, thus, the terminology frequently used as septal RVOT is misleading (Figure 4).

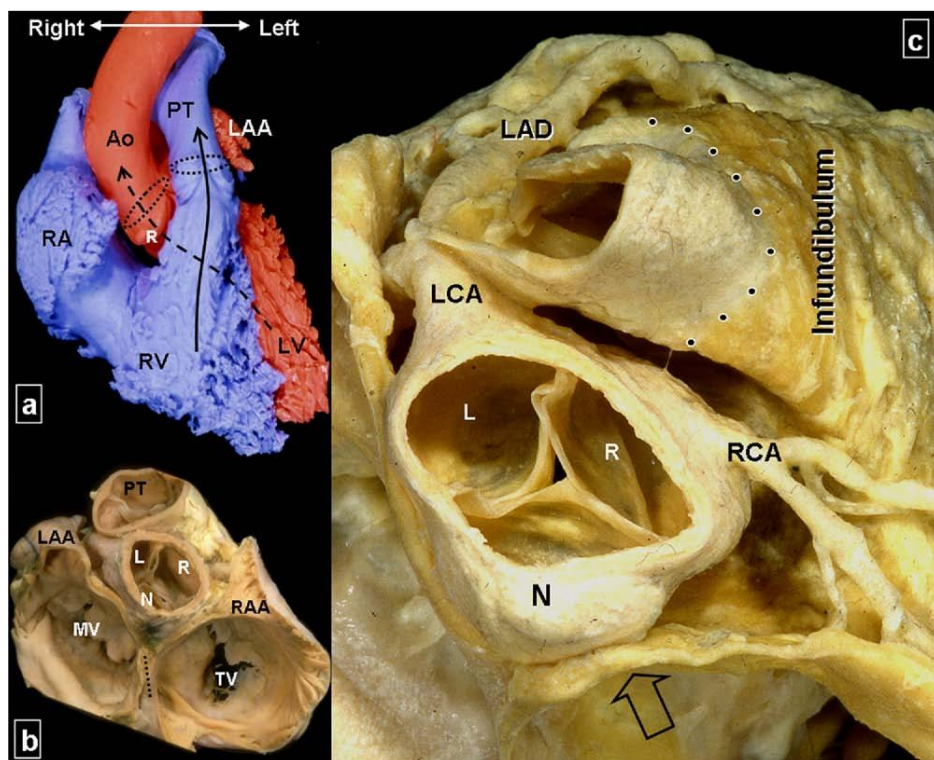


Figure 4 a: Endocast of a normal heart viewed from the front showing the crossover relationship between right and left ventricular outflow tracts (arrows). Dotted ovals represent the orifices of the pulmonary and aortic valves. b: Atrial chamber transected and pulmonary and aortic valves cut at the level of the sinutubular junctions. The heart viewed from the right and posterior shows the central location of the aortic valve. Note the near alignment between a closure line of the aortic valve with that of the tricuspid valve. Dotted line represents plane of the atrial septum. c: Epicardial fat removed to show the ventriculoarterial junction (dotted line) between the pulmonary sinuses and the infundibulum and the relationship between the infundibulum and the aortic sinuses. Open arrow indicates the aortic mound in the right atrium. Ao = aorta; L = left coronary aortic sinus; LAA = left atrial appendage; LCA = left coronary artery; LAD = left anterior descending artery; LV = left ventricle; MV = mitral valve; N = noncoronary aortic sinus; PT = pulmonary trunk; R = right coronary aortic sinus; RA = right atrium; RAA= right atrial appendage; RCA = right coronary artery; RV = right ventricle; TV= tricuspid valve. Reprinted from *Heart Rhythm* 2009;6:S77–S80, Siew Yen Ho *Anatomic insights for catheter ablation of ventricular tachycardia* Page 78., Copyright 2009, with permission from Elsevier.

Since the level of the pulmonic valves is cephalad to the plane of the aortic valves, the anterior portion of the aortic sinuses (that is the anterior part of the left and right

coronary aortic sinus) lie behind the subpulmonary infundibulum. VAs from the left and right coronary aortic sinuses are well recognized (16,25) and due to their anatomical location may mimic a RVOT origin on the surface ECG. The non-coronary aortic sinus lies posteriorly towards the atrial septum and therefore atrial tachycardias may arise from this location, even though there are reports about VAs from the non coronary cusp (26). There is rarely ventricular myocardium in the fibrous tissue of the aortomitral continuity between the aortic and mitral valves and may give a rise for VAs (27). Many reports presented VAs from the pulmonary artery (28,29) and the underlying anatomical substrate, as it is in VAs from the aortic root, could be the presence of myocardial extension above the level of the pulmonic and aortic valves (30).

I.1.3 The 12 lead ECG

Since the OT locates superiorly, VAs originating from this region have a characteristic ECG pattern with inferior frontal QRS axis. The typical appearance in RVOT VA shows a LBBB morphology with a transition not earlier than V3 while in case of a LV origin an LBBB pattern with transition in V2 or V3 or a RBBB pattern can be observed (31) (Figure 1). Several algorithms were developed for the differentiation of RV versus LVOT VAs and the surface ECG analysis may provide additional distinction between the septal and freewall or anterior, mid and posterior sites in the RVOT or may locate the SOO in the different aortic cusps and subvalvular left ventricular sites like the aortomitral continuity or anterior mitral annulus (15,16,32,33). The algorithm presented by Ouyang et al. (16) found that an R-wave duration index $\geq 50\%$ and an R/S ratio $\geq 30\%$ in lead V1 or V2 predicts the left sided origin with high accuracy (Figure 5) although the patient population consisted of those with a transition in lead V1 or V2 when a left sided origin is not a question of debate.

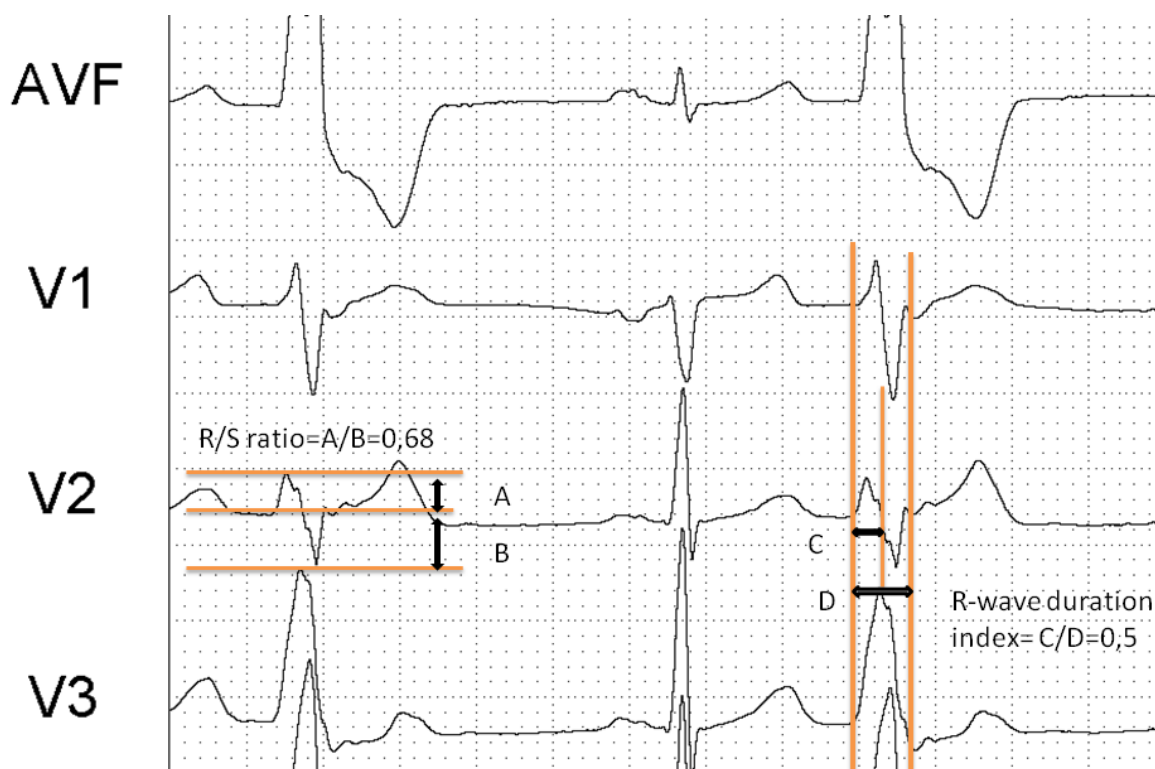


Figure 5. Illustration of the measurement of the R/S ratio and R-wave duration index in this case in V2 in a patient with LVOT extrasystoles. According to the algorithm if the R/S ratio ≥ 30 % or the R-wave duration index ≥ 50 % in V1 or in V2 then the focus is on the left side. In this case the algorithm predicted appropriately the SOO.

If the zone of transition is in V3, as it is in more than 50% of all patients in some studies (22), the focus of the arrhythmia can be found in the RVOT or LVOT in a ratio of approximately 1:1, therefore additional methods were developed to discriminate the SOO in these patients (14,34). The V2 transition ratio (Figure 6) deals with the calculation of the percentage of R wave related to the whole R+S amplitude in VA divided by the percentage of R-wave in sinus rhythm and a value $\geq 0,6$ predicts a left sided origin with 91 % accuracy in a prospective analysis in patients with V3 transition (14). In this study a transition zone during PVC later than in sinus could exclude an LVOT origin. Despite the several algorithms, the determination of the site of origin in case of a V3 transition is still a matter of debate.

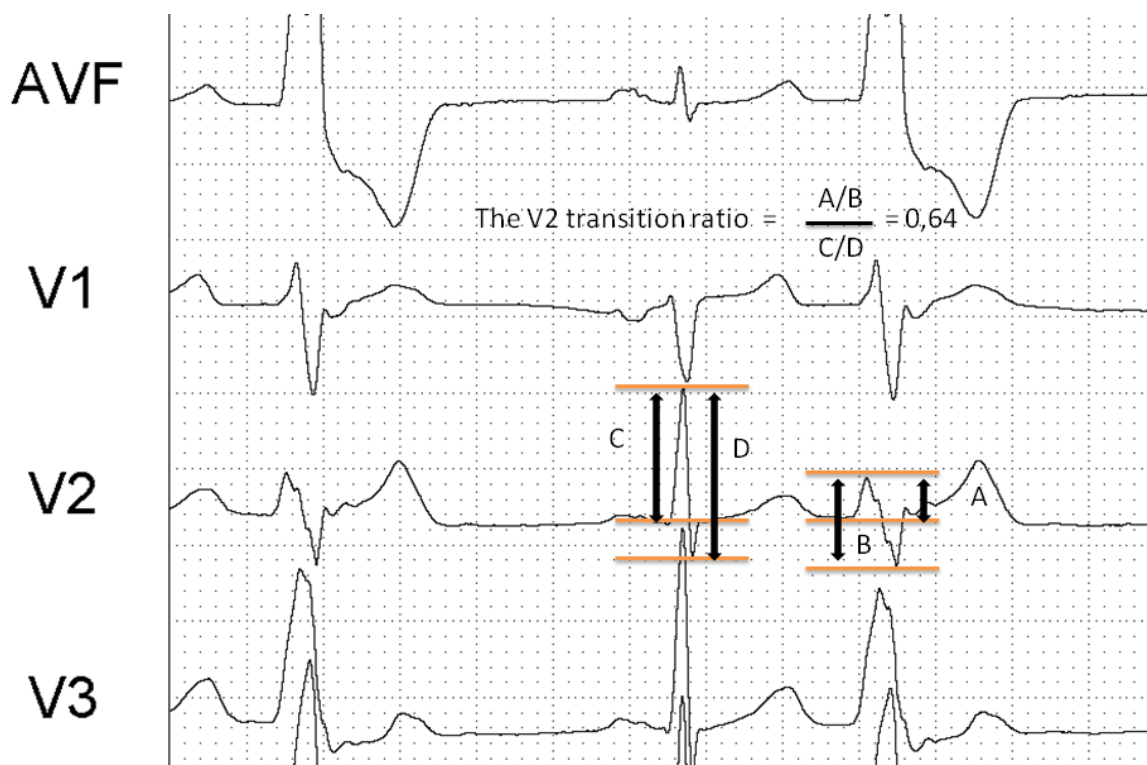


Figure 6. The V2 transition ratio for the prediction of the SOO. If the calculated ratio $\geq 0,6$ then the predicted SOO is in the LVOT as in this case.

I.1.4. Mapping and ablation of OT VAs

Owing to the arrhythmia mechanism, OT VAs have a focal origin. The earliest activation can be determined by conventional activation mapping or by pace mapping if the arrhythmia is not present at baseline or after isoproterenol administration. The site of earliest activation indicates the arrhythmia origin and RFCA at this point eliminates the arrhythmia. Although the local activation time precedes the QRS onset at the successful site of ablation, the prematurity of the local EG itself may not be enough to predict successful ablation since an overlap exists between the successful and unsuccessful RFCA sites (18,19,20,21). A very accurate point-by point mapping is mandatory to find

the earliest activated site which refers to the SOO. The local bipolar EG at the SOO has a sharp deflection whereas the local unipolar EG shows a QS morphology without any initial positive wave. While the absolute value of the local activation time is not predictive for a successful ablation site itself, the EG morphology may indicate it as it was demonstrated by van Huls van Taxis et al. (20). The reversed polarity of the local EG in the distal and more proximal poles of the ablation catheter had a higher specificity but a lower sensitivity for predicting a successful ablation site than the local activation time with a cut off value of 23 msec.

The introduction of electroanatomical mapping systems in the RFCA of OTVAs further increased the success rate, provided better anatomical insight into the geometry of the outflow tracts and depicted the SOO and impulse propagation more precisely. The administration of electroanatomical mapping made it possible to compare pace mapping versus activation mapping favoring the latter in locating the SOO (18,35).

When the arrhythmia is not present at baseline or after isoproterenol administration, pacemapping can be used. A good match during pacemapping represents an identically induced morphology in at least 10 of 12 leads in comparison with the spontaneous arrhythmia beats (35). Sometimes it is impossible to have a good pacemap at the SOO but an almost identical pacemap can be achieved from a location far from the focus, what can be explained by the presence of preferential conduction between the different anatomical structures (36,37,38). Sometimes a farfield EG can be achieved from the contralateral side very similarly to the successful location (Figure 7).

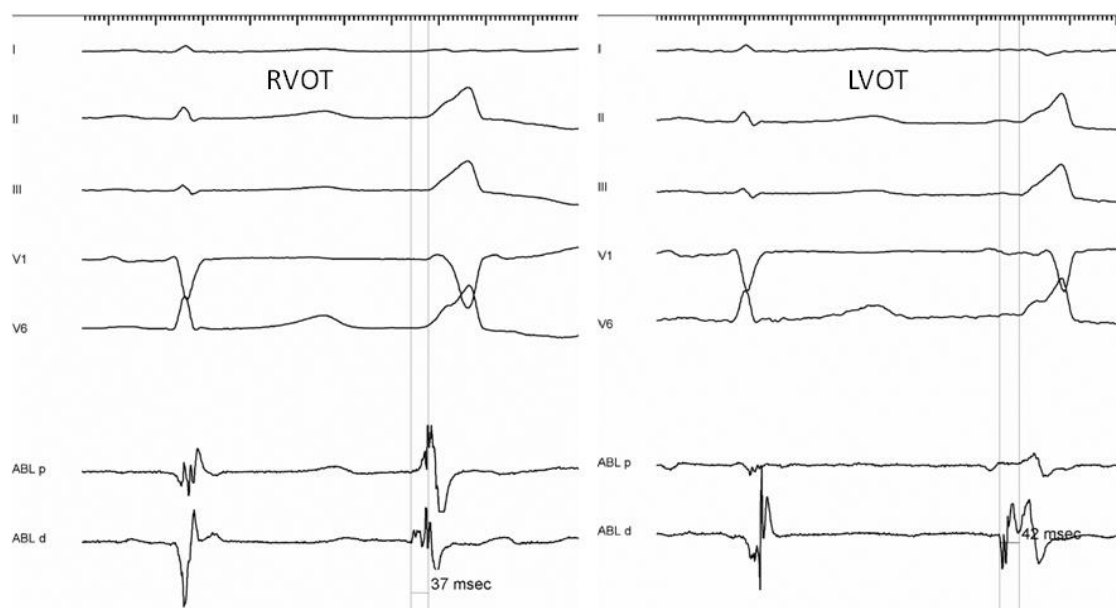


Figure 7. The local EG in the unsuccessful RVOT septal site (left panel) shows a similar but farfield like morphology in comparison with the successful site EG (right panel) in the LVOT in patients with frequent PVC. The prematurity of the local EG differs only slightly between the two sides (37 vs 42 msec respectively).

Regarding the difficulties of mapping and RFCA of frequent PVC during electroanatomical mapping, it is important to know that a significant spatial displacement of the point positions can be observed during PVC in comparison with sinus. The displacement is based on the difference in the acquisition time, which is in late diastole in sinus rhythm, while it is during systole or early diastole with PVC. The displacement is greater with RVOT SOO and shorter coupling interval of the PVC and is less pronounced in the proximity of the great arteries and annular regions (39). After careful mapping, the arrhythmia ablation can be performed with either conventional or irrigated tip catheter. The latter is providing greater efficacy and may be safer in embolia prophylaxis in case of a left sided ablation. If the ablation is performed in the aortic sinuses of valsalva or in the CS then a coronary arteriography or the 3D integration of CT, contrast enhanced cardiovascular MR or intracardiac

echocardiography images to the electroanatomical mapping system is necessary to avoid coronary injury (40) (Figure 8).

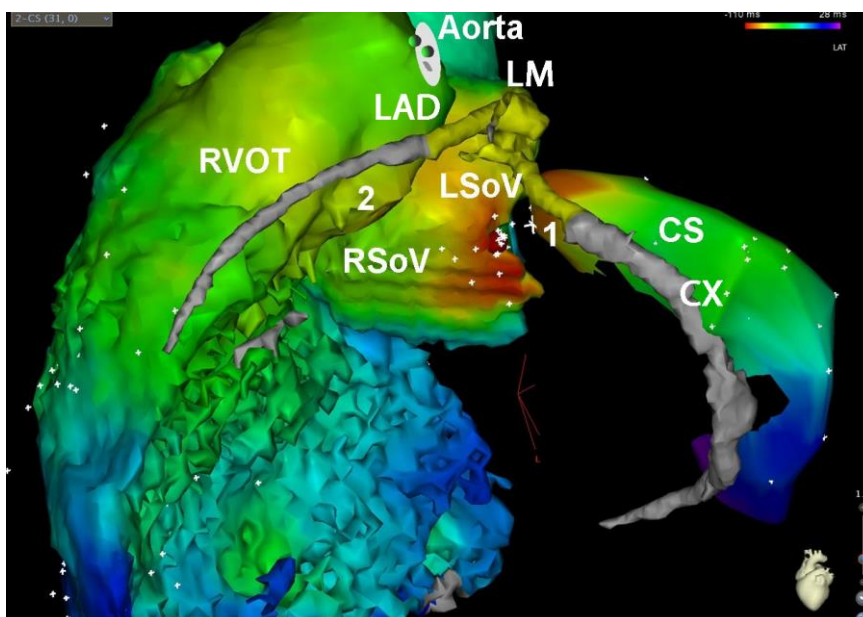


Figure 8. 3D CT image integration into the electroanatomical mapping system. The arrhythmia was eliminated by RFCA from the left sinus of Valsalva (red dot) in safe distance from the left main coronary artery(LM). The 3D CT image integration and the visualisation of the coronary arteries provided reliable and accurate anatomic information and thus coronary angiography was unnecessary. RVOT, right ventricular outflow tract; LSoV, left sinus of Valsalva; RSoV, right sinus of Valsalva; CS, coronary sinus; LM, left main coronary artery; LAD, left anterior descending coronary artery; CX, circumflex coronary artery.

I.2. Aims and the corresponding electrophysiological considerations

As it was written in the introduction, when the zone of transition is in lead V3 and the earliest site in the RVOT is located in the septum, there are no reliable criteria to predict RV versus LV origin in OT VAs, what may result in extensive, unsuccessful, and unnecessary RF applications. No previous study investigated the characteristics of electroanatomical mapping data analysis of the RVOT for the prediction of the SOO.

The use of activation maps with the electroanatomic mapping systems does not only permit finding the earliest activation point in the mapped chamber but also the depiction of the time course and shape of impulse propagation, which greatly depend on myocardial fiber orientation (41). Isochronal map areas have been previously analyzed in patients with RVOT VAs (18,35,42), although no previous study investigated their ability to predict RVOT versus LVOT origin. The RVOT fiber orientation is circumferential and parallel to the atrioventricular groove in the subepicardial region, while longitudinally aligned in the endocardial surface (24). Therefore it can be expected that the area/shape of isochronal maps in the RVOT would differ depending on the SOO, as the propagation velocity depends on the fiber orientation (43). Finally, it has been suggested that mapping the distal CS could help in identifying the actual SOO (22).

We hypothesized that data derived from the isochronal map area measurement and analysis could provide new predictors accurate enough to reduce mapping requirements and unnecessary RF applications in OT ventricular tachycardias with V3 transition and septal earliest activation. Data provided by the distal CS mapping was also analyzed.

I.3. Methods

I.3.1. Patient characteristics

From a series of 38 consecutive patients submitted for OT VA ablation, the subgroup of patients meeting the following two criteria (n=15) was selected for more precise intracardiac EG analysis: 1) a transition from negative to positive QRS complex during premature ventricular complex in the precordial lead V3 and 2) the earliest EG during

activation mapping being located septally in the RVOT in the electroanatomic map. The V3 transition was considered on the basis of the agreement between two observers, blinded to the electrophysiological data and ablation results.

Patients with arrhythmogenic RV cardiomyopathy and those with a V3 transition and nonseptal activation were excluded from the analysis. Patients with baseline ECG abnormalities or structural heart disease were not excluded from the study.

I.3.2. Electrophysiologic study

The electrophysiologic study was performed in a 12-hour fasting state after written informed consent had been obtained. Beta-blockers and antiarrhythmic medications were discontinued for 5 half-lives before the procedure. A 6 Fr electrode catheter was introduced into the RV apex for stimulation. If the arrhythmia was not present at baseline, programmed RV stimulation was performed with up to 3 extrastimuli or burst pacing. Isoproterenol was used only in one patient with baseline PVCs to induce the clinical VT with the same morphology but was not maintained during mapping. The CARTO (Biosense Webster, Diamond Bar, CA, USA) electroanatomic mapping system was used to guide ablation in all cases. The ablation catheter used for mapping and ablation was a 7 Fr 3.5-mm-tip irrigated catheter (Navistar, Biosense Webster) in all cases. The 12 surface ECG leads and intracardiac EGs were displayed and recorded by an electrophysiologic data acquisition system (EP tracer, CardioTek, Maastricht, The Netherlands or Bard Labssystem, CR Bard Inc., Lowell, MA, USA).

I.3.3. Mapping and ablation

A detailed bipolar endocardial activation map was sequentially taken during either PVC or VT in the RVOT, the distal portion of the CS until the junction with the anterior interventricular vein, and the LVOT (supravalvular and subvalvular). The epicardium

was mapped in only one case. As the total number of mapped points does not properly reflect the mapping accuracy, the minimum density of points required to consider whether the electroanatomic map of a given chamber was acceptable was defined as a fill threshold of 15 mm. Radiofrequency was delivered at the earliest activated site after careful mapping of all the structures. The temperature limit was set at 45° C. A power limit of 40 W was used in the RVOT and the subvalvular LVOT, 20 W in the CS and 30 W in the aortic root. At successful RF ablation sites energy delivery was continued for a full 60 seconds. When the PVC or VT was not eliminated after 30 seconds, energy delivery was discontinued and another site was selected for further applications.

I.3.4. Data collection

Relevant ECG data known to differentiate between RVOT and LVOT SOO, such as the R-wave duration index and R/S wave ratio in leads V1 and V2 (16), the V2 transition ratio, and the PVC transition occurring earlier/later than during sinus rhythm (14), were collected for analysis. The earliest activation time relative to the earliest onset of the QRS complex was measured online and used to decide the RF application location, after comparing data from the different structures. The data derived from the isochronal map area measurement and analyses were obtained offline, therefore the procedure results were not dependent on these data. The isochronal map areas were measured using the area measurement tool of the CARTO system. To obtain reproducible results, the minimum fill threshold value required to fully fill the RV 10 ms isochronal map was also measured (Figure 9).

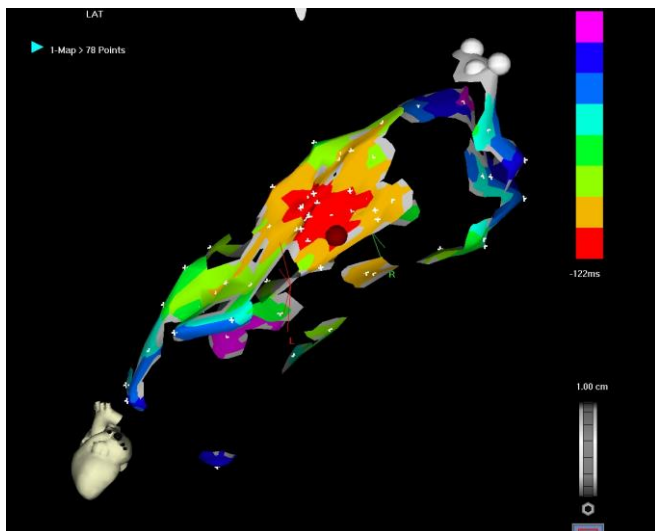


Figure 9. Measurement of the fill threshold value in a given patient in the area of interest. This parameter is modified (progressively reduced) until the isochronal map area becomes incompletely filled.

The spread of activation was characterized by defining the longitudinal and perpendicular diameters of the isochronal areas relative to the RVOT axis (Figure 10).

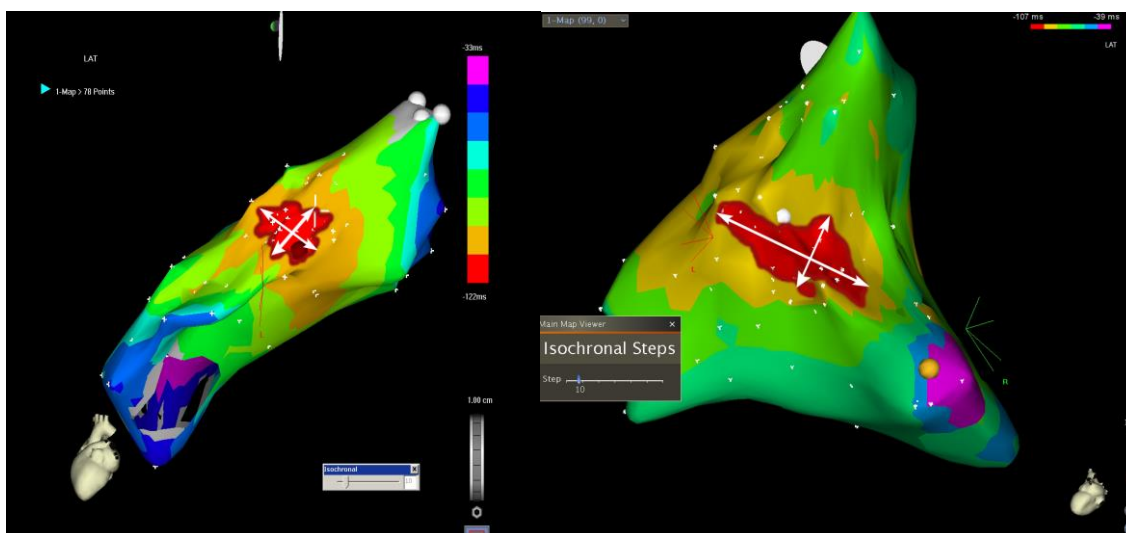


Figure 10. The typical 10-ms isochronal area (dark red line) in the right ventricular outflow tract in patients with a ventricular arrhythmia originated in the RVOT (left) and the left ventricular outflow tract (right). Note the elliptic form with a shorter longitudinal and longer perpendicular diameter in the case of LVOT site of origin. The arrows define the longitudinal and perpendicular axis diameters of the ellipse.

The longitudinal diameter of the isochronal map area was that defined by a line parallel to the septal projection of the RVOT longitudinal axis (perpendicular to the plane of the pulmonary valve). The defined longitudinal axis specified the perpendicular axis of the early activated area. A new variable, the ratio between the longitudinal and perpendicular RV 10 and 20 ms isochronal map area diameters, was created to characterize the shape area.

I.3.5. Statistical analysis

Data are reported as median and interquartile range (IQR). The comparison between populations was performed with Mann-Whitney U test. Proportions were compared with Fisher exact test. We used the likelihood ratio (LR +), defined as Sensitivity/(1-Specificity), to evaluate the optimal cut-off value for predicting a left-sided arrhythmia in our sample. A *P*-value of ≤ 0.05 was considered statistically significant. Statistical analysis was performed using SPSS for Windows Version 18.0.

I.4. Results

I.4.1 Patient Population

Baseline characteristics of the 15 patients with a V3 transition and septal earliest activation in the RVOT are summarized in Table 1.

These patients represent 39.5% of a series of 38 consecutive patients submitted for ablation. Ablation was successful in all these 15 patients, 7 of them in the LVOT (5 in the right sinus of Valsalva, 1 in the left sinus of Valsalva and 1 just below the aortic valve, between the right and left coronary cusp) and 8 in the RVOT.

Table 1. Baseline characteristics of patients with outflow tract ventricular arrhythmia with a V3 transition and septal earliest activation. RVOT, right ventricular outflow tract; LVOT, left ventricular outflow tract; PVC, premature ventricular complex; VT, ventricular tachycardia;. Results expressed as median and interquartile range (analyzed with U Mann-Whitney test) or absolute frequencies with percentages (analyzed with Fisher exact test).

	All patients (n=15)	RVOT origin (n=8)	LVOT origin (n=7)	P value
Age, yrs	49 [41-59]	45 [42-54]	59 [24-62]	0.25
Male sex, n (%)	11 (73)	4 (50)	7 (100)	0.08
Hypertension, n (%)	4 (27)	1 (12)	3 (42)	0.28
Diabetes, n (%)	2 (13)	0 (0)	2 (28)	0.20
Dyslipidemia, n (%)	6 (40)	2 (25)	4 (57)	0.32
Cardiomyopathy, n (%)	9 (60)	4 (50)	5 (71)	0.61
Redo procedure, n (%)	2 (13)	1 (12)	1 (14)	1
Ejection fraction (%)	50 [30-54]	51 [31-59]	42 [30-50]	0.19
Atrial fibrillation, n (%)	1 (7)	0 (0)	1 (14)	0.47
Clinical presentation				
PVC	9 (60)	6 (75)	3 (43)	0.32
nsVT	2 (13)	0 (0)	2 (29)	0.20
VT	4 (27)	2 (25)	2 (29)	0.28

I.4.2. Surface ECG and RVOT Mapping Data

Differences between the surface ECG variables depending on the SOO are shown in Table 2.

Table 2. Electrocardiographic data of patients with outflow tract ventricular arrhythmia with V3 transition and earliest septal activation, grouped by the site of origin. RVOT, right ventricular outflow tract; LVOT, left ventricular outflow tract; LBBB, left bundle branch block; PVC, premature ventricular complex. Results expressed as median and interquartile range (analyzed with U Mann-Whitney test) or absolute frequencies with percentages (analyzed with Fisher exact test).

	RVOT (n=8)	LVOT (n=7)	P value
Electrocardiographic parameters depending on the site of origin			
QRS width in sinus rhythm (ms)	89 [75-108]	108 [87-142]	0.13
QRS width during PVC (ms)	151 [135-155]	148 [141-159]	0.73
Presence of baseline LBBB, n (%)	0 (0)	3 (43)	0.077
R wave duration ratio V1 PVC	0.36 [0.19-0.43]	0.4 [0.31-0.44]	0.8
R wave duration ratio V2 PVC	0.31 [0.22-0.41]	0.47 [0.39-0.5]	0.037
R/S ratio V1 PVC	0.17 [0.12-0.23]	0.35 [0.19-0.43]	0.16
R/S ratio V2 PVC	0.22 [0.10-0.29]	0.37 [0.27-0.47]	0.16
PVC R/S transition later than in SR, n (%)	3 (37)	1(14)	0.56
V2 transition ratio	0.51 [0.37-2.99]	0.87 [0.28-5.8]	0.49

Significant differences were only found for the R wave duration ratio in V2 during PVC, being higher in the case of LVOT SOO (0.31 (0.22-0.41) vs. 0.47 (0.39-0.5); P=0.037).

Differences in the variables obtained from the electroanatomic map depending on the SOO are shown in Table 3.

Table 3. Mapping data of the patients with outflow tract ventricular arrhythmia with V3 transition and earliest septal activation grouped by the site of origin. RVOT, right ventricular outflow tract; LVOT, left ventricular outflow tract. Results expressed as median and interquartile range (analyzed with U Mann-Whitney test).

	RVOT (n=8)	LVOT (n=7)	P value
Electroanatomic mapping data			
Number of mapped points	99 [62-142]	99 [31-183]	0.7
Precocity in the RVOT (ms)	39 [30-46]	30 [19-40]	0.15
Measured values at the 10 ms isochronal map area			
Longitudinal diameter (mm)	12 [8-16]	14 [12-16]	0.9
Perpendicular diameter (mm)	13 [7-17]	28 [20-29]	0.001
Ratio of longitudinal/perpendicular diameter	1.04 [0.95-1.11]	0.49 [0.44-0.57]	0.001
Area (cm ²)	1.2 [0.4-2.1]	3.4 [2.4-3.9]	0.004
Circumference (cm)	4.3 [2.9-5.9]	8 [7-9.6]	0.007
Fill threshold	6 [4-7]	8 [3-13]	0.45
Measured values at the 20 ms isochronal area			
Longitudinal diameter (mm)	35 [23-38]	33 [32-40]	0.7
Perpendicular diameter (mm)	35 [21-41]	45 [41-50]	0.024
Ratio of longitudinal/perpendicular diameter	0.96 [0.92-1.05]	0,75 [0.7-0.85]	0.005
Area (cm ²)	8.3 [4.3-12.1]	14 [7.5-23]	0.045
Circumference (cm)	12.5 [7.5-15.2]	15 [10.4-19.5]	0.15
Fill threshold	12 [9-15]	13 [11-21]	0.17

The 10 ms isochronal map area in the RVOT was significantly smaller in the RVOT than in the LVOT SOO group (1.2 [0.4-2.1] vs. 3.4 [2.4-3.9] cm² respectively; P=0.004). A cut-off value of >2.3 cm² was able to predict a LVOT SOO with 85.7 % sensitivity and 87.5 % specificity (Figure 11).

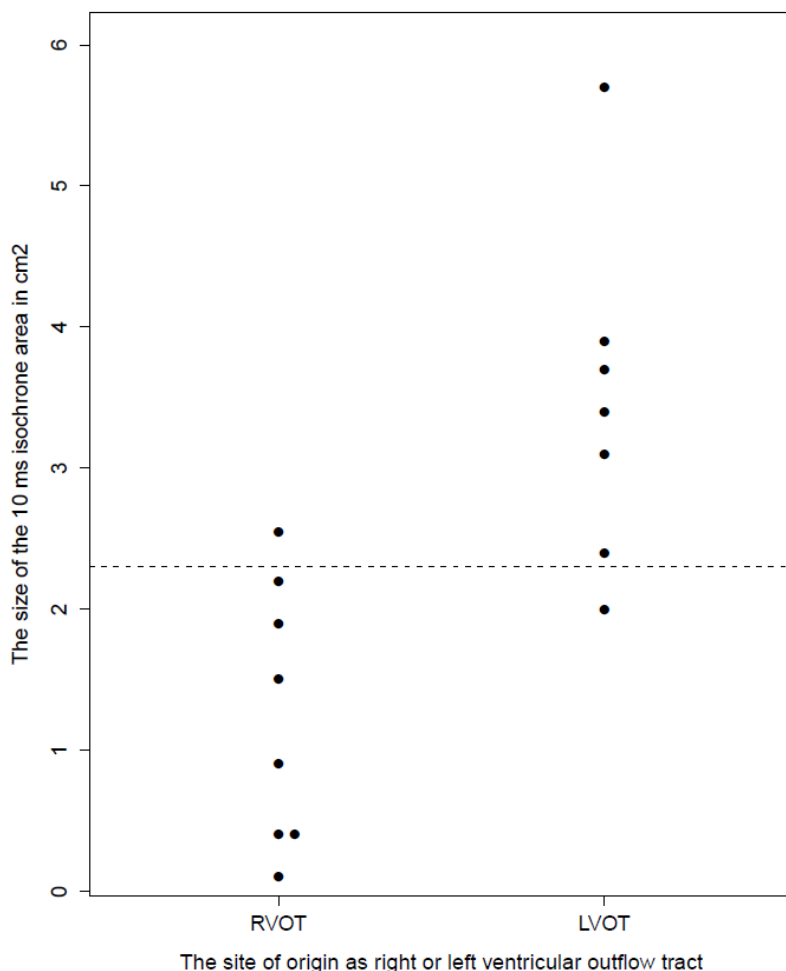


Figure 11. The 10 ms isochronal map area differed significantly between the different sites of origin although there is an overlap, which results in low sensitivity and specificity when defining a cut-off value (horizontal line at 2.3 cm²). RVOT, right ventricular outflow tract; LVOT, left ventricular outflow tract

The shape of the 10 ms isochrone area also differed depending on the SOO. While the longitudinal diameter did not differ significantly depending on the RVOT vs LVOT SOO (12 mm [8-16] vs. 14 mm [12-16]; P=0.9), the perpendicular diameter was significantly greater in the LVOT group (13 mm [7-17] vs. 28 mm [20-29]; P=0.001),

explaining the differences in the 10 ms isochronal map areas. The longitudinal to perpendicular diameter ratio was significantly smaller in the LVOT SOO (1.04 [0.95-1.11] vs 0.49 [0.44-0.57]; P=0.001). The differences between groups were smaller when the 20 ms isochronal map area was analyzed, but still statistically significant for the isochronal map area (8.3 (4.3-12.1) vs. 14 (7.5-23) cm²; P=0.045), the perpendicular diameter (35 (21-41] vs. 45 (41-50) mm; P=0.024) and the longitudinal to perpendicular diameter ratio (0.96 (0.92-1.05) vs. 0.75 (0.7-0.85); P=0.005).

The fill threshold value is a CARTO parameter expressed in millimeters, which indicates the distance around an acquired point that is filled by the system and colored according to the point precocity. Therefore the minimal fill threshold value, which fully colors the 10 and 20 ms isochronal map areas, indicates the mapping density of the area of interest. This fill threshold value did not differ significantly between the patient groups (Table 3) and the median value of this parameter in the 10 ms early activated area for the two patient groups was 6 (4-9) mm.

The sensitivity and specificity of the ECG variables and mapping data for the VAs with a V3 transition and septal earliest activation is shown in Table 4.

Table 4. The sensitivity and specificity of different criteria to predict a left sided origin of outflow tract ventricular arrhythmias with a V3 transition.

	Sensitivity (%)	Specificity (%)
R wave duration index > 50 % or R/S ratio > 30 % in V1 or V2	71.5 (29.0-96.3)	62.5 (24.5-91.5)
The V2 transition ratio	57 (18.4-90.1)	62 (24.5-91.5)
The 10 ms isochronal map area >2.3 cm ²	87.5 (42.1-99.6)	85.7 (47.3-99.7)
Longitudinal/perpendicular axis ratio <0.8 <i>of the 10 ms isochronal map area</i>	100 (47.3-100)	100 (51.8-100)

A cut-off value of the longitudinal to perpendicular diameter ration <0.8 predicted a LVOT SOO with 100% specificity and 100% sensitivity (Figure 12).

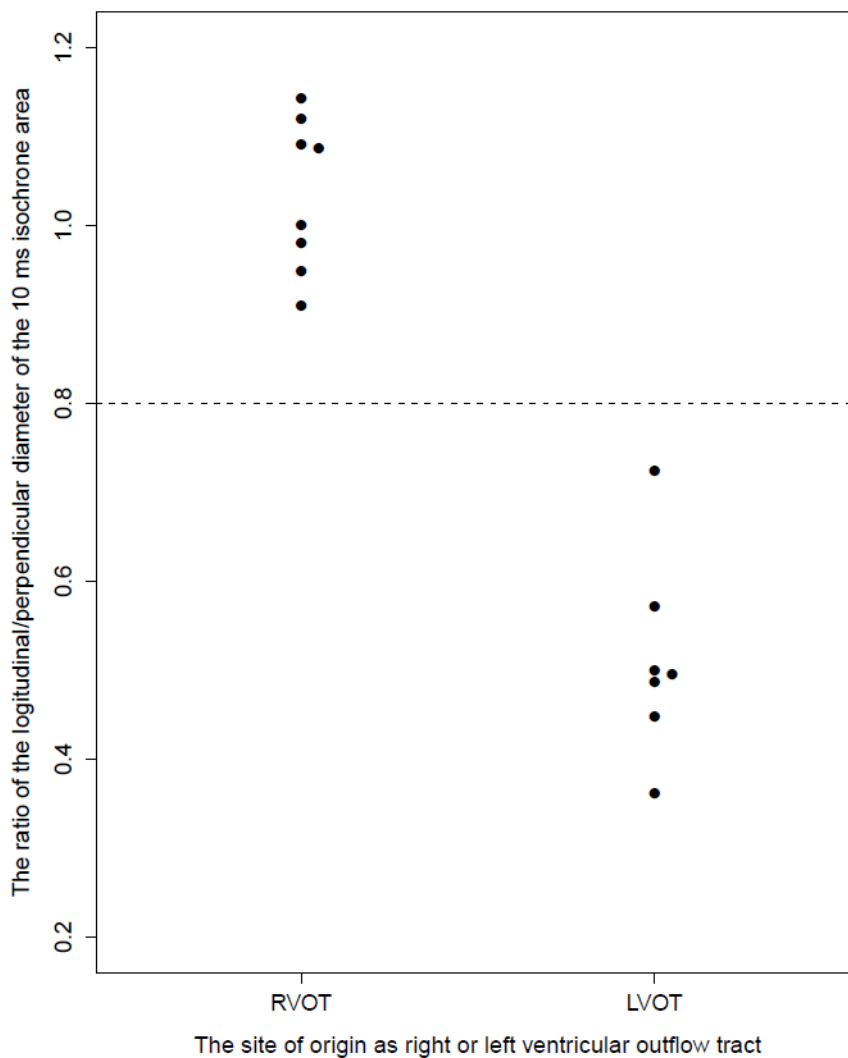


Figure 12. The ratio of the longitudinal / perpendicular diameter of the 10 ms isochrone area differed significantly between the two groups, without overlapping. A cut-off value of 0.8 (horizontal line) separated all values from the two groups.

I.4.3. Coronary Sinus Mapping

The usefulness of CS mapping to distinguish between the RVOT and LVOT SOO was evaluated by comparing the measured precocity between the distal CS (at the level of its junction with the anterior interventricular vein) and the RVOT in both groups of patients. In the RVOT group all patients had a higher precocity in the septal RVOT than in the distal CS. In the LVOT group an earlier distal CS activation was found in 28% (n=2), while 72% (n=5) of them had a higher precocity in the septal RVOT. In one of the cases with a higher precocity in the CS, the SOO was located just below the aortic valve, between the right and left coronary cusps, whereas in the other case, the SOO was in the left sinus of Valsalva. In all cases in the LVOT group, in which the higher precocity was found in the septal RVOT, the SOO was located in the right sinus of Valsalva. Two representative activation patterns from the mapped RVOT, aortic root and distal CS in two different SOO are shown in Figure 13.

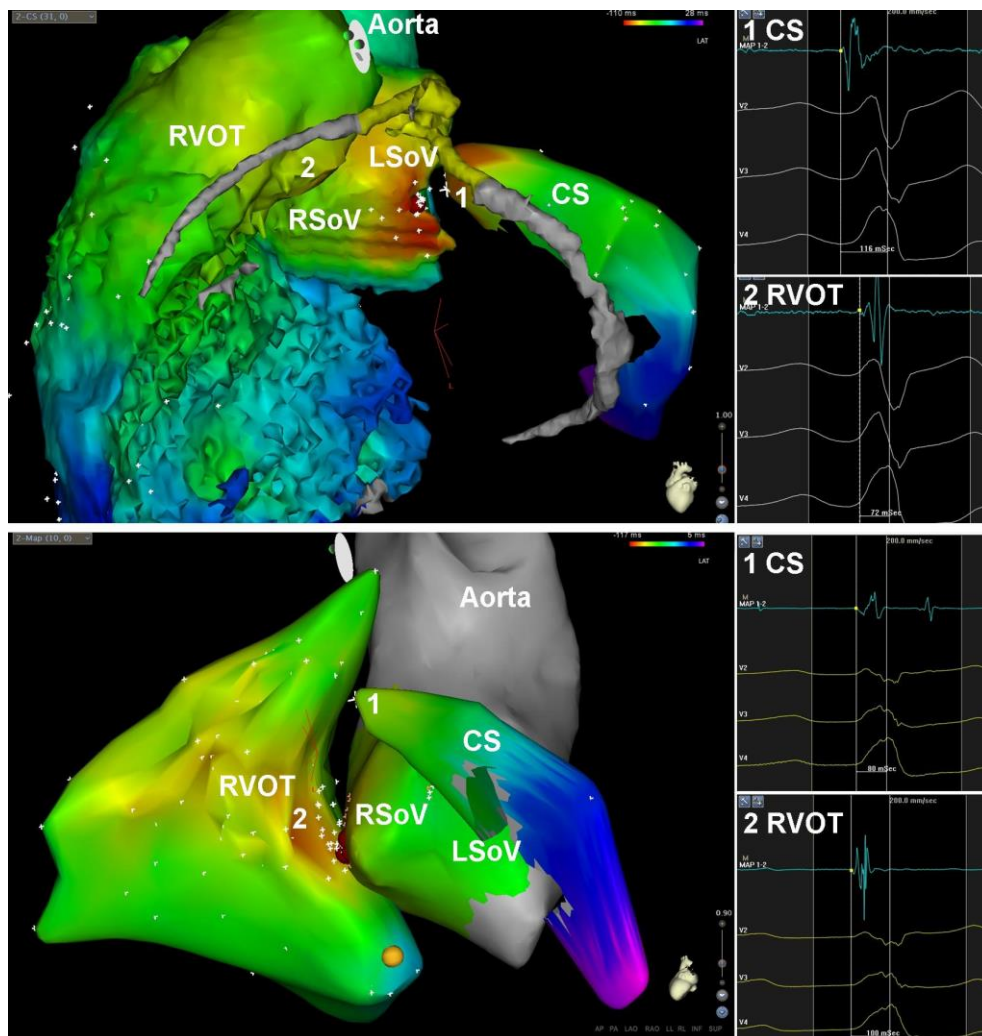


Figure 13. Characteristic activation patterns in the right ventricular outflow tract, aortic root and coronary sinus of premature ventricular complex (PVC) with a V3 transition and an earliest septal activation in the right ventricular outflow tract. In the upper panel the PVC originated from the left sinus of Valsalva. The precocity of the local intracardiac electrogram in the distal coronary sinus is earlier than in the septal RVOT. In the lower panel the PVC originated from the right sinus of Valsalva. The precocity of the local intracardiac electrogram in the distal coronary sinus is later than in the septal RVOT despite the LVOT site of origin. RVOT, right ventricular outflow tract; LVOT, left ventricular outflow tract; LSoV, left sinus of Valsalva; RSoV, right sinus of Valsalva; CS, coronary sinus.

I.5. Discussion

The main finding of the study is that intracardiac mapping data can predict the LVOT versus RVOT SOO with a very high sensitivity and specificity in the population of patients with a V3 transition and septal earliest activation.

I.5.1. Surface ECG

The ECG features of RVOT VAs are accepted to be left bundle branch block morphology and a precordial transition that begins no earlier than V3 (31). However, an important proportion of patients with LVOT VA have a transition zone in V3 and the SOO is not straightforward. In previous studies and in the present one, the ratio of RVOT to LVOT SOO in patients with V3 transition was approximately 1:1 (14). Therefore, additional ECG features or intracardiac mapping data are necessary to increase the accuracy in identifying the actual SOO in this population. A recent study focusing on patients with a V3 transition showed that the “V2 transition ratio” could be used to predict the RVOT versus LVOT SOO (14). This parameter has been tested in the present study; however, sensitivity and specificity were lower than previously published in this specific subgroup of patients (14). There are three main differences between the two studies that could account for the discrepancy in the accuracy of the ECG criterion to predict the SOO: 1) in the present study, patients having structural heart disease or ECG abnormalities during sinus rhythm were not excluded, so that the results would be applicable to the whole population of patients having a V3 transition; 2) as not all patients with a V3 transition have a septal earliest activation (11 % of patients in the present series), this criterion was also required in the present study; 3) strikingly, a higher than expected proportion of patients in the previous series had a left sinus of Valsalva origin, as the precordial transition usually occurs in V1 or V2 in those patients.

I.5.2. Mapping Data

The intracardiac EG precocity at the successful ablation site in the RVOT differs greatly in previously published studies (18,19) in patients with a RVOT SOO. As expected, because of the close anatomical SOO of the two groups in the present series (72% of the LVOT VAs originated from the right sinus of Valsalva), intracardiac EG precocity in the RVOT showed a big overlap between the two groups. Therefore, absolute precocity in the RVOT is not helpful in deciding the right place for RF application in a case of a V3 transition.

As also was expected because of the inclusion criteria, a small proportion of patients (n=1, 14%) had a left sinus of Valsalva SOO. Accordingly, previous reports have shown that PVCs originating from the left sinus of Valsalva usually have an earlier ECG transition than those originating from the right sinus of Valsalva (44). In contrast, 35% of patients with a V3 transition had a left sinus of Valsalva SOO in a single previous report (14). The low percentage of a left sinus of Valsalva SOO in the present study probably accounts for the fact that the distal CS mapping was not found to be useful to predict the SOO of OT VTs with a V3 transition and a septal earliest activation.

To our knowledge no previous study has described the characteristic RVOT activation pattern that predicts a left-sided origin of OT VAs, even in the general group of patients with a transition in V3 or beyond. The size and shape of the early-activated area in the RVOT probably depends on multiple factors including the arrhythmia SOO, the myocardial fiber orientation in the region of interest, the velocity of impulse propagation, and the chamber geometry. When the VA originates in the LVOT, the spread of activation causes the activation wave front to reach the RVOT in a larger isochronal map area. In the case of a RVOT SOO, the 10 ms isochronal map area in the

RVOT was $1.2 [0.4-2.1]$ cm², similar to a previous study where this area was 1.2 ± 0.7 cm² (10). This area is significantly greater in cases with LVOT origin ($3.4 [2.4-3.9]$ cm²), although with a small overlap between groups. These reported results could have been influenced by the administration of isoproterenol, which was not used in the present study. Isoproterenol would increase the impulse propagation velocity and thus the size of the early activated area. In fact, the difference in size of the early (10ms) activated area in two previous studies (18,35) was attributed to differences in isoproterenol administration. Therefore the results on the size of the early-activated area in the septal RVOT are limited for procedures performed without isoproterenol administration.

On the other hand, the shape of the 10 ms isochrone area is dependent on the chamber geometry and the myocardial fiber orientation, as the velocity of impulse propagation is higher in the longitudinal direction (43). The myocardial fiber orientation in the right ventricle is circumferential and parallel to the atrioventricular groove in the subepicardial region, while there are longitudinally aligned myocardial fibers in the endocardial surface (24). In the present study we have found a characteristic activation pattern in the subendocardial RVOT that significantly differs depending on the chamber of origin (RVOT vs LVOT). If the SOO is located in the LVOT, the 10 ms isochronal map area in the subendocardial RVOT is significantly greater and the shape of activation shows an elliptic pattern with the long axis perpendicular to the OT axis orientation and parallel to the subepicardial fiber orientation. In the case of a septal RVOT SOO, the 10 ms isochronal map has a rounded shape. Although the present series had no cases with an epicardial origin (LV summit or distal CS), due to their low prevalence, such cases should be expected to produce a bigger 10 ms isochronal map area on the septal RVOT, as compared with the true septal RVOT PVCs.

Finally, in order to make these results reproducible and clinically applicable, the minimum fill threshold to fully fill the area of interest (10 ms isochronal area in the septal RVOT) on the electroanatomical map should be set up as ≤ 10 mm, according to the measured values in the present study (median 6 (4 to 9)).

I.5.3. Study limitations

The retrospective nature of the study and the small sample population are the main limitations and thus the value of the described criteria should be evaluated in a prospective study. The presence of underlying cardiomyopathy (60% of patients) and conduction disturbances (20% of patients) during sinus rhythm were not exclusion criteria. Therefore, the isochronal map area and shape could have been influenced by the structural/functional changes in the myocardial tissue that could lead to a different pattern of impulse propagation. However, it has been recently shown that a LVOT SOO can be more prevalent than a RVOT SOO in patients with structural heart disease or LV dysfunction (45) and a substantial proportion of these patients have PVCs with a V3 transition and baseline abnormal ECG. Therefore, the exclusion of patients with structural heart disease or baseline ECG abnormalities from the study would decrease the clinical value of the identified criteria.

Although the results on the size of the early activated area in the septal RVOT are limited for procedures performed without isoproterenol administration, it probably would not alter the activation pattern and therefore the longitudinal to perpendicular axis ratio would remain useful in those cases.

I.6. Conclusions

A different activation pattern in the RVOT 10 ms isochronal maps exists in OT VTs with a V3 transition and a septal earliest activation, depending on the RVOT versus LVOT SOO. This information can be used to predict the SOO of OT VTs with a high accuracy, thereby avoiding extensive RVOT ablation or unnecessary CS or LVOT mapping.

II. The impact of RFCA of frequent PVC on left ventricular systolic function in patients with cardiac resynchronization therapy

II.1. Introduction

Cardiac resynchronization pacemaker therapy (CRT) has evolved as a highly successful treatment modality in congestive heart failure associated with an intra- and/or interventricular conduction delay. Large scale clinical trials have revealed resultant improvements in the quality of life and the functional capacity (46-49), and more recently a mortality benefit (50). However, a certain subgroup of patients exhibits only a minimal or no response after a technically successful implantation procedure. This phenomenon has been recognized since the very beginning of the CRT era; a number of explanations have been proposed, including suboptimal patient selection or positioning of the left and right ventricular electrodes, and difficulties in postimplantation device programming to maximize the hemodynamic benefit.

The deteriorating effect of frequent PVC for the LV systolic function was also known before our study, although it was mainly investigated in patients without organic heart disease where the arrhythmia was responsible for the diminished LV systolic function (1-3,51-53). It was also known that PVCs frequently occur in patients with organic heart disease, and especially in those with poor left ventricular function. All patients who are candidates for CRT belong in this cohort. Somewhat surprisingly, we have found no publication before our case in which the underlying mechanism of a nonresponse to resynchronization therapy was attributed to frequent PVCs. We reported the first case in

which we ascribed the lack of a response to CRT to frequent PVCs, where a marked improvement was achieved by transcatheter elimination of the arrhythmia.

II.2. RFCA of PVC improved the left ventricular function in a nonresponder to cardiac resynchronization therapy, the first clinical description

II.2.1 Case report

A 57-year-old male with nonischemic dilated cardiomyopathy was referred for CRT. He was in a status of NYHA III heart failure and was on optimal medical therapy, including carvedilol, an ACE inhibitor, digitalis, diuretics and acenocoumarol. The 12-lead ECG showed a left bundle branch block with a QRS width of 140 msec. Transthoracic echocardiography demonstrated a dilated left ventricle with an impaired systolic function and moderate mitral regurgitation (Table 5)

Table 5: Transthoracic echo parameters during follow-up.

	Before implantation	6 weeks postimplantation	6 months postimplantation	6 months postablation
Ejection fraction (%)	20	18	16	28
End diastolic diameter of the left ventricle (mm)	85	82	80	79
End systolic diameter of the left ventricle (mm)	66	74	73	66
Mitral regurgitation (grade)	II°	III°	III°	I°

Tissue Doppler imaging (TDI) revealed an intraventricular wall motion delay, with the latest activation recorded at the posterior wall. Frequent ventricular ectopy (15% of all beats) and runs of nonsustained ventricular tachycardia were documented on 24-hour ambulatory monitoring.

Resynchronization therapy was offered for the patient and an Insync III pacemaker (Medtronic Inc., Minneapolis, Minnesota) was implanted, with the left ventricular lead (Attain OTW, Medtronic Inc.) positioned in a posterior branch of the CS. The QRS width was reduced to 120 msec (Figure 14) after the implantation, and no significant intraventricular delay was observed on TDI echocardiography.

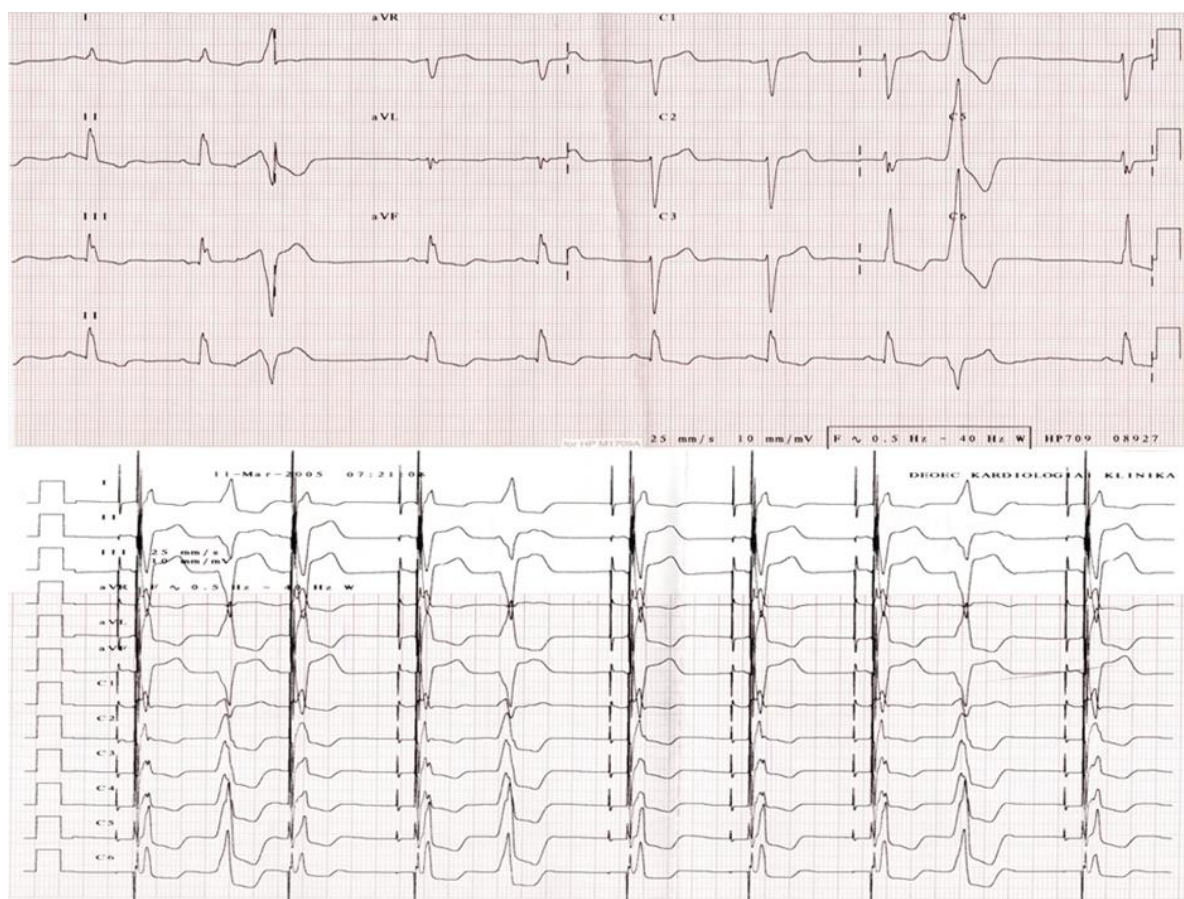


Figure 14. 12-lead ECG before (upper panel) and after (lower panel) CRT implantation. Frequent ventricular ectopies can be observed in both recordings.

Device was programmed to DDD at lower rate of 50 beats/min, however, device optimization (V-V and AV delay) could not be performed properly before his discharge or at 6 weeks postimplantation, due to frequent PVCs. The AV delay (sensed) was programmed to 110 msec and the V-V delay to 0 (equal). During the following 6 months, the clinical status of the patient did not improve; in fact, he was hospitalized for acute heart failure requiring intravenous diuretics on 5 occasions. Frequent monomorphic PVCs were still present in the 12-lead ECG recordings and also evidenced by the 20 % rate of ventricular sensed beats in the device log. The echocardiographic parameters indicated no significant change except for a worsening of the mitral regurgitation (Table 5). In order to avoid contamination of the echo measurements by the arrhythmia, they were obtained during a period of stable biventricular capture in at least 6 consecutive cycles. The pacemaker was otherwise functioning well, mostly in tracking mode at a sinus rate of 50-60 beats / min with excellent sensing and pacing parameters in all 3 leads. A decision was made to attempt the RFCA of the monomorphic PVCs, guided by CARTO electroanatomical mapping (CARTO™, Biosense Webster, Diamond Bar, CA). Both ventricles were mapped during monomorphic premature beats, using a 4-mm tip deflectable catheter (NAVISTAR™, Biosense Webster). The focus of the PVCs was localized to the postero-inferior left ventricle (Figure 15),

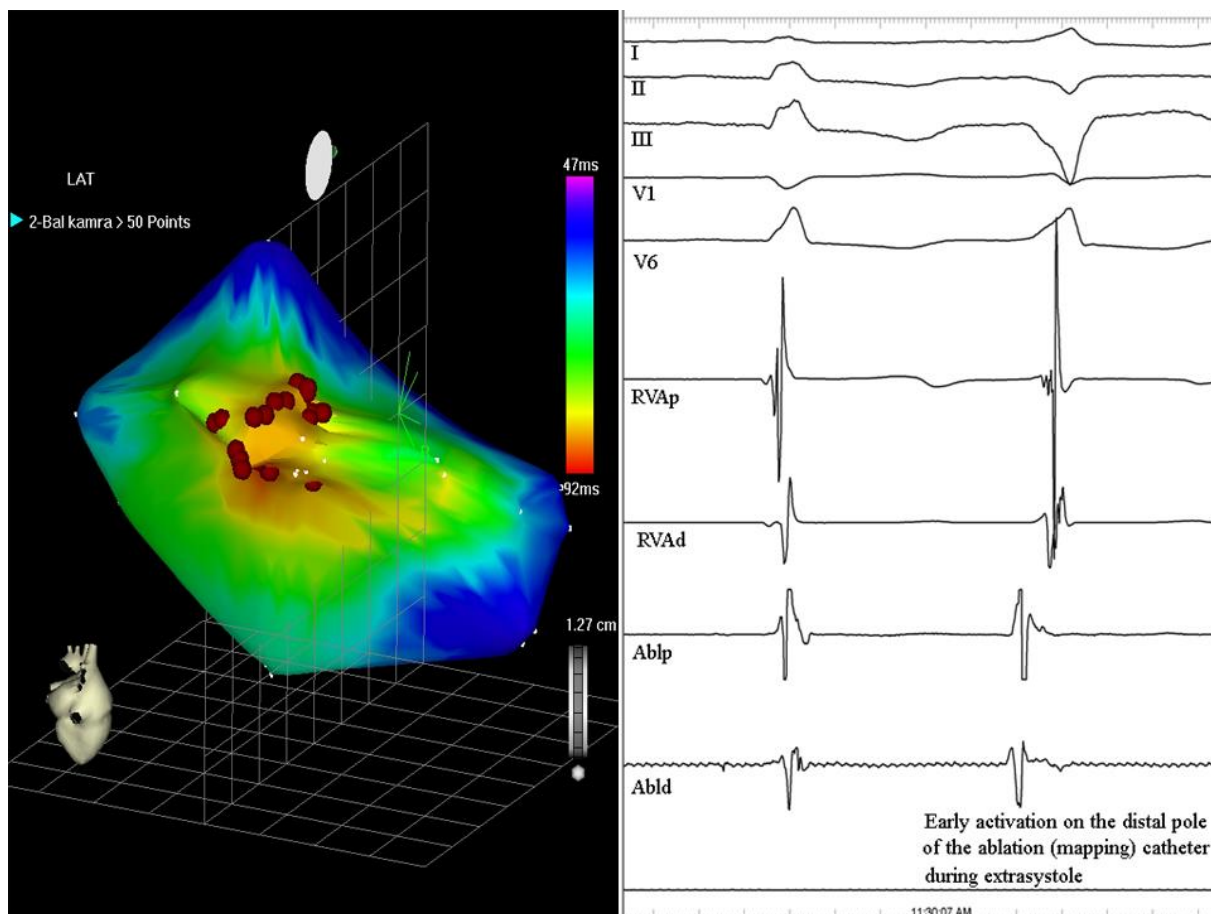


Figure 15. (Left) Electroanatomical activation map of the left and right ventricles from a posterior view, obtained during monomorphic ventricular premature beats. The site of the earliest activation in the left ventricle (red area) was covered by several RF applications (red dots) to ensure a long-term result. (Right) Intracardiac recordings show early local activation on the distal ablation pole (Abl) at the site of successful RF application preceding the QRS onset by 44 msec. (I-II-III-V1-V6: surface ECG leads; RVAp, RVAd: proximal and distal poles of the catheter in the right ventricular apex; Ablp: proximal ablation electrodes)

where RF energy delivery resulted in the prompt disappearance of all premature beats. Proper device optimization became possible after successful RFCA; the AV delay was programmed to 120 msec and the V-V delay to 20 msec with the left ventricular lead paced earlier. A marked clinical improvement was observed within a few weeks post-RFCA: the functional class decreased to NYHA I, with no need for hospitalization during the following 6 months, and the dose of oral diuretics was reduced. Interrogation

of the device log revealed that the sensed ventricular event rate had fallen to less than 4%. Improvements were also evident on echocardiography (Figure 16).

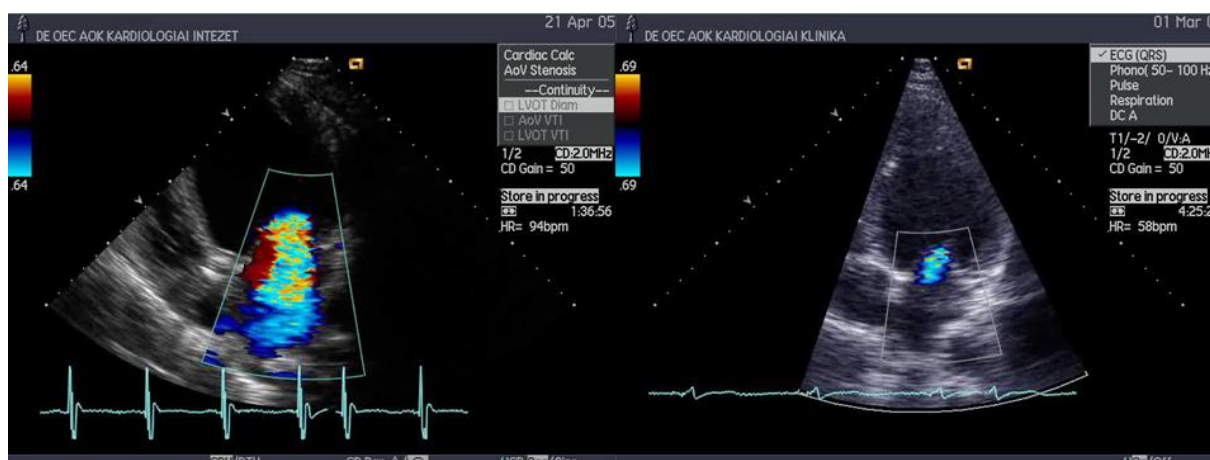


Figure 16. Severe mitral regurgitation 6 months after CRT implantation (left), and minimal mitral regurgitation 6 months after ablation (right)

It was noteworthy that a similar intraventricular delay could still be measured 6 months post-RFCA with the ventricular pacing temporarily switched off as the one which was measured before device implantation.

II.2.2. Limitations and clinical considerations

In most of the reports of PVC-induced tachycardiomyopathy, the extrasystoles originated from the right ventricular outflow tract, supporting the concept that the LV dysfunction in these patients is caused by asynchronous ventricular activation, similar to that often due to a left bundle branch block. In our patient, however, the PVCs originated from the left ventricle. One explanation for this phenomenon could be the truncation of the diastole by the premature beats, leading to insufficient ventricular filling. Another possibility is that the frequent PVCs eliminated the beneficial effect of the CRT. The inaccuracy of echo measurements before RFCA, because of the frequent

PVCs, cannot be excluded entirely, despite the significant efforts made to ensure reliability. However, the marked improvement in clinical status in this patient makes it unlikely that the improvement in the echo-derived systolic function was simply a measurement artifact. On the other hand, proper echo-guided fine tuning of the AV and V-V delays was feasible only after the arrhythmia was controlled. Accordingly, the resolution of the tachycardia-mediated cardiomyopathy, the more effective resynchronization therapy and the increase in the proportion of paced beats might all contribute to the positive changes observed after effective arrhythmia control had been achieved.

II.3. Further investigations

On the basis of the previous finding, we have made a screening in our center among patients with CRT. 125 consecutive patients were screened after technically successful CRT device implantation (ejection fraction (EF) 26 ± 5 %, 91 male (73%), 34 female (27 %), 50 CRT-D (40%), 75 CRT-P (60%), 38 ischemic (30 %), 87 non ischemic (70%) dilated cardiomyopathy) (54). These patients were followed up for at least 12 months. LV function, functional class and frequency of PVC based on the ratio of ventricular sensed beats in holter memory of the device were evaluated after the implantation and every 3 months. PVCs were considered frequent if their rate exceeded 10 % of all ventricular beats. Elimination of frequent PVC was attempted if the patient was a "non-responder" to CRT after at least 6 months. Frequent PVC were found after the implantation at pre-discharge in 10 out of 125 patients (8%). Gradual decrease of PVC frequency along with improving LV function and functional status was observed in 4 patients after CRT. A responder with no symptoms had no specific treatment of the

arrhythmia. In 5 non-responders, the arrhythmia was successfully eliminated (or significantly reduced) by radiofrequency ablation (in 2 patients), amiodarone (in 2 patients) or ablation and programming of the device to a higher basic rate (in 1 patient). The elimination or significant reduction of frequent PVC resulted in significant improvement of LV function (EF before treatment: $21\pm 5\%$ after treatment: $34\pm 7\%$ $p: 0,003$) and functional class in all (NYHA before treatment: $3,2\pm 0,4$ after treatment: $1,6\pm 0,5$ $p:0,002$) (Table 6).

Table 6. Echocardiographic and clinical data before and after RFCA of PVC in patient with frequent PVC and non response to CRT (n:patients number; LV:left ventricle; EF:ejection fraction; PVC: premature ventricular contraction; CRT:cardiac resynchronization therapy; NYHA:New York Heart Association class)

n	Treatment (Tx)	LV EF after CRT (%)	LV EF before PVC Tx (%)	LV EF after PVC Tx (%)	PVC ratio before Tx	PVC ratio after Tx	NYHA before Tx	NYHA after Tx
1	Ablation	20	16	38	20	3	IV	II
2	Ablation	22	30	48	25	1	III	II
3	Ablation + programming	20	20	30	50	15	IV	II
4	Amiodarone	23	20	33	13	<1	III	I
5	Amiodarone	23	20	33	20	<1	III	II

This study confirmed our finding in our case report and a proper control of frequent PVC became a routine management for our CRT patients.

II.4. Discussion

The effect of the elimination of frequent PVC in cardiomyopathy was already investigated even before the era of routine RFCA of the arrhythmia. Duffee et al. reported an improvement of left ventricular systolic function in patients with organic heart disease after successful pharmacological suppression of frequent PVC (55). Later on frequent isolated ectopic beats, mostly originating from the right ventricular outflow tract were investigated in case reports and retrospective analyses and reported as a cause of tachycardiomyopathy, a reversible form of congestive heart disease that resolved after the elimination of the culprit arrhythmia (1-3, 51-53). Most of the patients featuring in these reports were individuals with no organic heart disease and the ventricular dysfunction was attributed exclusively to the provoking arrhythmia. Further investigations revealed this improvement in the left ventricular systolic function with PVCs from different SOO (56) and a comparable beneficial effect of RFCA was demonstrated recently in patients with or without structural heart disease (57). Although the presence of frequent PVC in structural heart disease and heart failure is well known in clinical practice (58,59) and the patient population amenable for CRT belongs to this cohort, the beneficial effect of RFCA of frequent PVC for the response for CRT was not investigated before our reports. In our follow up study the prevalence of frequent PVC in the whole CRT population using a cut off value of 10% for significant PVC burden was 8% even though 50% of these patients became responder for CRT and thus did not require further therapy according to our protocol. The treatment of the remaining patients (4% of the whole study group) was successfully treated either conservatively or with RFCA and became responder after the elimination or significant reduction of frequent PVC. Further investigations from Lakkireddy et al. verified the beneficial effect of RFCA of frequent PVC in a large group (2034) of CRT patients in a

prospective multicentric study (60) using a cut off value of > 10,000 PVC in a 24-hour period for the definition of frequent PVC. The prevalence of non-responders was 25 % in their study, while the prevalence of frequent PVC was 13% among the non-responders to CRT. In the whole CRT group the prevalence of non-responders with frequent PVC was 3,2%, which is comparable with our results (4%). Lakireddy et al. found a cut-off value of 14,3 % initial PVC ratio to have a beneficial effect of RFCA in LV EF, LV dimensions and NYHA functional class but clinically significant improvement was achieved only in those with more than 22% PVC burden. Somewhat surprisingly it was also demonstrated in this study that the beneficial effect of frequent PVC ablation was based on the more effective CRT function with higher percentage of biventricular pacing after RFCA rather than the deteriorating effect of the PVC itself. This is hard to explain since the deteriorating effect of frequent PVC for the LV systolic function is well known from other studies. In the study of Baman et al. (61) a more than 24% PVC predicted a PVC induced cardiomyopathy with 79% sensitivity and 78% specificity, which is in line with the results of Lakireddy et al. However, these patients were individuals with structurally normal hearts without CRT and their LV parameters normalized once the arrhythmia was eliminated. In another study, Penela et al. proved significant and similar improvement in patients with or without structural heart disease (57) although those with structural heart disease had a significantly higher PVC burden before RFCA. These results show that the abolishment of frequent PVC alone has enough beneficial effect to improve the LV systolic function in patients without CRT. It is also remarkable that a significant number of patients, who met the criteria for primary preventive ICD implantation before the RFCA in the Penela study, could not fulfill that after ablation. On the ground of these findings it is hard to explain that the benefit from the RFCA ablation of frequent PVC in the Lakireddy study was based only on the

higher biventricular pacing rate and may raise the question of RFCA of frequent PVC even before the CRT. A proper screening for frequent especially monomorphic PVC amenable for ablation seems to be mandatory in this patient population either before or after CRT implantation.

II.5. Conclusion

The presence of frequent PVC in the CRT population is one of the possible reasons for the non response for this therapy. A thorough investigation for the presence of frequent PVC is mandatory in case of a low biventricular stimulation rate in those of non-responders since RFCA of the arrhythmia may render these patients to responder.

III. References

1. Belhassen B. Radiofrequency ablation of "benign" right ventricular outflow tract extrasystoles: a therapy that has found its disease? *J Am Coll Cardiol.* 2005 Apr 19;45(8):1266-8. Comment on *J Am Coll Cardiol.* 2005 Apr 19;45(8):1259-65.
2. Takemoto M, Yoshimura H, Ohba Y, Matsumoto Y, Yamamoto U, Mohri M, Yamamoto H, Origuchi H. Radiofrequency catheter ablation of premature ventricular complexes from right ventricular outflow tract improves left ventricular dilation and clinical status in patients without structural heart disease. *J Am Coll Cardiol.* 2005 Apr 19;45(8):1259-65.
3. Yarlagadda RK, Iwai S, Stein KM, Markowitz SM, Shah BK, Cheung JW, Tan V, Lerman BB, Mittal S. Reversal of cardiomyopathy in patients with repetitive monomorphic ventricular ectopy originating from the right ventricular outflow tract. *Circulation.* 2005 Aug 23;112(8):1092-7. Epub 2005 Aug 15.
4. Lerman BB, Stein K, Engelstein ED, Battleman DS, Lippman N, Bei D, Catanzaro D. Mechanism of repetitive monomorphic ventricular tachycardia. *Circulation.* 1995 Aug 1;92(3):421-9.
5. Morady F, Kadish AH, DiCarlo L, Kou WH, Winston S, deBuitleur M, Calkins H, Rosenheck S, Sousa J: Long-term results of catheter ablation of idiopathic right ventricular tachycardia. *Circulation* 1990;82:2093-2099
6. Klein LS, Shih HT, Hackett FK, Zipes DP, Miles WM. Radiofrequency catheter ablation of ventricular tachycardia in patients without structural heart disease. *Circulation.* 1992 May;85(5):1666-74.

7. Nakagawa M, Takahashi N, Nobe S, Ichinose M, Ooie T, Yufu F, Shigematsu S, Hara M, Yonemochi H, Saikawa T. Gender differences in various types of idiopathic ventricular tachycardia. *J Cardiovasc Electrophysiol*. 2002 Jul;13(7):633-8. Review.
8. Tanaka Y, Tada H, Ito S, Naito S, Higuchi K, Kumagai K, Hachiya H, Hirao K, Oshima S, Taniguchi K, Aonuma K, Isobe M. Gender and age differences in candidates for radiofrequency catheter ablation of idiopathic ventricular arrhythmias. *Circ J*. 2011;75(7):1585-91. Epub 2011 May 12.
9. Kim YH, Park SM, Lim HE, Pak HN, Kim YH, Shim WJ. Chronic frequent premature ventricular complexes originating from right and non-right ventricular outflow tracts. *Int Heart J*. 2010;51(6):388-93.
10. Vijgen J, Hill P, Biblo LA, Carlson MD. Tachycardia-induced cardiomyopathy secondary to right ventricular outflow tract ventricular tachycardia: improvement of left ventricular systolic function after radiofrequency catheter ablation of the arrhythmia. *J Cardiovasc Electrophysiol*. 1997 Apr;8(4):445-50.
11. Kim YH, Goldberger J, Kadish A. Treatment of ventricular tachycardia-induced cardiomyopathy by transcatheter radiofrequency ablation. *Heart*. 1996 Dec;76(6):550-2.
12. Taieb JM, Maury P, Shah D, Duparc A, Galinier M, Delay M, Morice R, Alfares A, Barnay C. Reversal of dilated cardiomyopathy by the elimination of frequent left or right premature ventricular contractions. *J Interv Card Electrophysiol*. 2007 Nov;20(1-2):9-13. Epub 2007 Oct 17.
13. Iwai S, Cantillon DJ, Kim RJ, Markowitz SM, Mittal S, Stein KM, Shah BK, Yarlagadda RK, Cheung JW, Tan VR, Lerman BB. Right and left ventricular outflow

tract tachycardias: evidence for a common electrophysiologic mechanism. *J Cardiovasc Electrophysiol*. 2006 Oct;17(10):1052-8. Epub 2006 Jun 27.

14. Betensky BP, Park RE, Marchlinski FE., Hutchinson MD, Garcia FC, Dixit S, Callans DJ, Cooper JM, Bala R, Lin D, Riley MP, Gerstenfeld EP. The V2 Transition Ratio A New Electrocardiographic Criterion for Distinguishing Left From Right Ventricular Outflow Tract Tachycardia Origin. *J Am Coll Cardiol*. 2011; 57:2255-2262.

15. Ito S, Tada H, Naito S, Kurosaki K, Ueda M, Hoshizaki H, Miyamori I, Oshima S, Taniguchi K, Nogami A. Development and validation of an ECG algorithm for identifying the optimal ablation site for idiopathic ventricular outflow tract tachycardia *J Cardiovasc Electrophysiol* 2003; 14:1280-1286.

16. Ouyang F, Fotuhi P, Ho SY, Hebe J, Volkmer M, Goya M, Burns M, Antz M, Ernst S, Cappato R, Kuck KH. Repetitive monomorphic ventricular tachycardia originating from the aortic sinus cusp: Electrocardiographic characterization for guiding catheter ablation. *J Am Coll Cardiol* 2002; 39:500-508.

17. Ho SY. Anatomic insights for catheter ablation of ventricular tachycardia. *Heart Rhythm* 2009; 6(Suppl 8):S77-80.

18. Azegami K, Wilver DJ, Arruda M, Lin AC, Denman RA. Spatial resolution of pacemapping and activation mapping in patients with idiopathic right ventricular outflow tract tachycardia. *J Cardiovasc Electrophysiol* 2005;16:823– 829.

19. Rodriguez LM, Smeets JL, Timmermans C, Wellens HJ. Predictors for successful ablation of right- and left-sided idiopathic ventricular tachycardia. *Am J Cardiol* 1997; 79:309 –314.

20. van Huls van Taxis CF; Wijnmaalen AP; den Uijl DW; Gawrysiak M, Putter H; SchaliJ MJ, Zeppenfeld K. Reversed polarity of bipolar electrograms for predicting a successful ablation site in focal idiopathic right ventricular outflow tract arrhythmias. *Heart Rhythm*. 2011; 8:665-671.
21. Okumura Y, Watanabe I, Nakai T, Ohkubo K, Kofune T, Ashino S, Kofune M, Nagashima K, Hiro T, Hirata A, Nikaido M, Hirayama A. A quantitative and qualitative analysis of the virtual unipolar electrograms from non-contact mapping of right or left-sided outflow tract premature ventricular contractions/ventricular tachycardia origins. *J Interv Card Electrophysiol*. 2011; 30:17-25.
22. Tanner H, Hindricks G, Schirdewahn P, Kobza R, Dorszewski A, Piorowski C, Gerds-Li JH, Kottkamp H. Outflow tract tachycardia with R/S transition in lead V3: six different anatomic approaches for successful ablation. *J Am Coll Cardiol*. 2005 Feb 1;45(3):418-23.
23. Gittenberger-de Groot AC, Bartelings MM, Deruiter MC, Poelmann RE. Basics of cardiac development for the understanding of congenital heart malformations. *Pediatr Res*. 2005 Feb;57(2):169-76. Epub 2004 Dec 20. Review.
24. Ho SY, Nihoyannopoulos P. Anatomy, echocardiography, and normal right ventricular dimensions. *Heart*. 2006 Apr;92 Suppl 1:i2-13. Review.
25. Kanagaratnam L, Tomassoni G, Schweikert R, Pavia S, Bash D, Beheiry S, Neibauer M, Saliba W, Chung M, Tchou P, Natale A. Ventricular tachycardias arising from the aortic sinus of valsalva: an under-recognized variant of left outflow tract ventricular tachycardia. *J Am Coll Cardiol*. 2001 Apr;37(5):1408-14.

26. Alasady M, Singleton CB, McGavigan AD. Left ventricular outflow tract ventricular tachycardia originating from the noncoronary cusp: electrocardiographic and electrophysiological characterization and radiofrequency ablation. *J Cardiovasc Electrophysiol.* 2009 Nov;20(11):1287-90.
27. Chen J, Hoff PI, Rossvoll O, De Bortoli A, Solheim E, Sun L, Schuster P, Larsen T, Ohm OJ. Ventricular arrhythmias originating from the aortomitral continuity: an uncommon variant of left ventricular outflow tract tachycardia. *Europace.* 2012 Mar;14(3):388-95.
28. Timmermans C, Rodriguez LM, Crijns HJ, Moorman AF, Wellens HJ. Idiopathic left bundle-branch block-shaped ventricular tachycardia may originate above the pulmonary valve. *Circulation.* 2003 Oct 21;108(16):1960-7. Epub 2003 Oct 6.
29. Yamashina Y, Yagi T, Namekawa A, Ishida A, Sato H, Nakagawa T, Sakuramoto M, Sato E, Yambe T. Clinical and electrophysiological difference between idiopathic right ventricular outflow tract arrhythmias and pulmonary artery arrhythmias. *J Cardiovasc Electrophysiol.* 2010 Feb;21(2):163-9.
30. Hasdemir C, Aktas S, Govsa F, Aktas EO, Kocak A, Bozkaya YT, Demirbas MI, Ulucan C, Ozdogan O, Kayikcioglu M, Can LH, Payzin S. Demonstration of ventricular myocardial extensions into the pulmonary artery and aorta beyond the ventriculo-arterial junction. *Pacing Clin Electrophysiol.* 2007 Apr;30(4):534-9.
31. Natale A, Raviele A, Al-Ahmad A, Alfieri O, Aliot E, Almendral J, Breithardt G, Brugada J, Calkins H, Callans D, Cappato R, Camm JA, Della Bella P, Guiraudon GM, Haïssaguerre M, Hindricks G, Ho SY, Kuck KH, Marchlinski F, Packer DL, Prystowsky EN, Reddy VY, Ruskin JN, Scanavacca M, Shivkumar K, Soejima K, Stevenson WJ, Themistoclakis S, Verma A, Wilber D; Venice Chart members. Venice Chart

International Consensus document on ventricular tachycardia/ventricular fibrillation ablation. *J Cardiovasc Electrophysiol*. 2010; 21:339-379.

32. Dixit S, Gerstenfeld EP, Callans DJ, Marchlinski FE. Electrocardiographic patterns of superior right ventricular outflow tract tachycardias: distinguishing septal and free-wall sites of origin. *J Cardiovasc Electrophysiol*. 2003 Jan;14(1):1-7.

33. Bala R, Garcia FC, Hutchinson MD, Gerstenfeld EP, Dhruvakumar S, Dixit S, Cooper JM, Lin D, Harding J, Riley MP, Zado E, Callans DJ, Marchlinski FE. Electrocardiographic and electrophysiologic features of ventricular arrhythmias originating from the right/left coronary cusp commissure. *Heart Rhythm*. 2010 Mar;7(3):312-22.

34. Cheng Z, Cheng K, Deng H, Chen T, Gao P, Zhu K, Fang Q. The R-wave deflection interval in lead V3 combining with R-wave amplitude index in lead V1: A new surface ECG algorithm for distinguishing left from right ventricular outflow tract tachycardia origin in patients with transitional lead at V3. *Int J Cardiol*. 2012 Dec 26.

35. Bogun F, Taj M, Ting M, Kim HM, Reich S, Good E, Jongnarangsin K, Chugh A, Pelosi F, Oral H, Morady F. Spatial resolution of pace mapping of idiopathic ventricular tachycardia/ectopy originating in the right ventricular outflow tract. *Heart Rhythm*. 2008 Mar;5(3):339-44.

36. Yamada T, Murakami Y, Yoshida N, Okada T, Shimizu T, Toyama J, Yoshida Y, Tsuboi N, Muto M, Inden Y, Hirai M, Murohara T, McElderry HT, Epstein AE, Plumb VJ, Kay GN. Preferential conduction across the ventricular outflow septum in ventricular arrhythmias originating from the aortic sinus cusp. *J Am Coll Cardiol*. 2007 Aug 28;50(9):884-91.

37. Yamada T, Platonov M, McElderry HT, Kay GN. Left ventricular outflow tract tachycardia with preferential conduction and multiple exits. *Circ ArrhythmElectrophysiol*. 2008 Jun 1;1(2):140-2.
38. Yamada T, McElderry HT, Doppalapudi H, Kay GN. A couplet of PVCs with different QRS morphologies arising from a single origin in the left ventricular outflow tract. *Pacing Clin Electrophysiol*. 2010 Sep;33(9):e88-92.
39. Andreu D, Berruezo A, Fernández-Armenta J, Herczku C, Borràs R, Ortiz-Pérez JT, Mont L, Brugada J. Displacement of the target ablation site and ventricles during premature ventricular contractions: relevance for radiofrequency catheter ablation. *Heart Rhythm*. 2012 Jul;9(7):1050-7
40. Herczku Csaba, Tóth Kálmán: Kifolyótraktus eredetű kamrai ritmuszavarok diagnosztikája és kezelése mai szemmel (Current concepts in the diagnosis and treatment of outflow tract ventricular arrhythmias) *Cardiologia Hungarica* 2014; 44. évfolyam 1. szám
41. Valderrábano M. Influence of anisotropic conduction properties in the propagation of the cardiac action potential. *Prog Biophys Mol Biol*. 2007; 94:144–168.
42. Kühne M, Sarrazin JF, Crawford T, Ebinger M, Good E, Chugh A, Jongnarangsin K, Pelosi F Jr, Oral H, Morady F, Bogun FM. Radiofrequency ablation guided by mechanical termination of idiopathic ventricular arrhythmias originating in the right ventricular outflow tract. *J Cardiovasc Electrophysiol*. 2010 Jan;21(1):42-6.
43. Spach MS, Boineau JP. Microfibrosis produces electrical load variations due to loss of side-to-side cell connections: a major mechanism of structural heart disease arrhythmias. *Pacing Clin Electrophysiol*. 1997 Feb;20(2 Pt 2):397-413. Review

44. Lin D, Ilkhanoff L, Gerstenfeld E, Dixit S, Beldner S, Bala R, Garcia F, Callans D, Marchlinski FE. Twelve-lead electrocardiographic characteristics of the aortic cusp region guided by intracardiac echocardiography and electroanatomic mapping. *Heart Rhythm*. 2008 May;5(5):663-9.
45. Mountantonakis SE, Frankel DS, Gerstenfeld EP, Dixit S, Lin D, Hutchinson MD, Riley M, Bala R, Cooper J, Callans D, Garcia F, Zado ES, Marchlinski FE. Reversal of outflow tract ventricular premature depolarization-induced cardiomyopathy with ablation: effect of residual arrhythmia burden and preexisting cardiomyopathy on outcome. *Heart Rhythm*. 2011 Oct;8(10):1608-14.
46. Cazeau S, Leclercq C, Lavergne T, Walker S, Varma C, Linde C, Garrigue S, Kappenberger L, Haywood GA, Santini M, Bailleul C, Daubert JC; Multisite Stimulation in Cardiomyopathies (MUSTIC) Study Investigators. Effects of multisite biventricular pacing in patients with heart failure and intraventricular conduction delay. *N Engl J Med*. 2001 Mar 22;344(12):873-80.
47. Abraham WT, Fisher WG, Smith AL, Delurgio DB, Leon AR, Loh E, Kocovic DZ, Packer M, Clavell AL, Hayes DL, Ellestad M, Trupp RJ, Underwood J, Pickering F, Truex C, McAtee P, Messenger J; MIRACLE Study Group. Multicenter InSync Randomized Clinical Evaluation. Cardiac resynchronization in chronic heart failure. *N Engl J Med*. 2002 Jun 13;346(24):1845-53.
48. Higgins SL, Hummel JD, Niazi IK, Giudici MC, Worley SJ, Saxon LA, Boehmer JP, Higginbotham MB, De Marco T, Foster E, Yong PG. Cardiac resynchronization therapy for the treatment of heart failure in patients with intraventricular conduction delay and malignant ventricular tachyarrhythmias. *J Am Coll Cardiol*. 2003 Oct 15;42(8):1454-9.

49. Abraham WT, Young JB, León AR, Adler S, Bank AJ, Hall SA, Lieberman R, Liem LB, O'Connell JB, Schroeder JS, Wheelan KR; Multicenter InSync ICD II Study Group. Effects of cardiac resynchronization on disease progression in patients with left ventricular systolic dysfunction, an indication for an implantable cardioverter-defibrillator, and mildly symptomatic chronic heart failure. *Circulation*. 2004 Nov 2;110(18):2864-8. Epub 2004 Oct 25.
50. Cleland JG, Daubert JC, Erdmann E, Freemantle N, Gras D, Kappenberger L, Tavazzi L. Longer-term effects of cardiac resynchronization therapy on mortality in heart failure [the CARDiac RESynchronization-Heart Failure (CARE-HF) trial extension phase]. *Eur Heart J*. 2006 Aug;27(16):1928-32. Epub 2006 Jun 16.
51. Chugh SS, Shen WK, Luria DM, Smith HC: First evidence of premature ventricular complex-induced cardiomyopathy: A potentially reversible cause of heart failure. *J Cardiovasc Electrophysiol* 2000; 66:1065-1067.
52. Redfearn DP, Hill JD, Keal R, Toff WD, Stafford PJ: Left ventricular dysfunction resulting from frequent unifocal ventricular ectopics with resolution following radiofrequency ablation. *Europace* 2003; 5:247-250.
53. Sekiguchi Y, Aonuma K, Yamauchi Y, Obayashi T, Niwa A, Hachiya H, Takahashi A, Nitta J, Iesaka Y and Isobe M: Chronic hemodynamic effects after radiofrequency catheter ablation of frequent monomorphic ventricular premature beats. *J Cardiovasc Electrophysiol* 2005; 16:1057-1063.
54. C. Herczku, C. Kun, M. Clemens, I. Edes, Z. Csanadi Clinical significance of frequent ventricular premature beats after cardiac resynchronization therapy *Eur J Heart Fail*. 2 Volume 7, Issue S1, June 2008, Page: 184

55. Duffee DF, Shen WK, Smith HC. Suppression of frequent premature ventricular contractions and improvement of left ventricular function in patients with presumed idiopathic dilated cardiomyopathy. *Mayo Clin Proc* 1998; 73:430-3.
56. Bogun F, Crawford T, Reich S, Koelling TM, Armstrong W, Good E, Jongnarangsin K, Marine JE, Chugh A, Pelosi F, Oral H, Morady F. Radiofrequency ablation of frequent, idiopathic premature ventricular complexes: comparison with a control group without intervention. *Heart Rhythm*. 2007 Jul;4(7):863-7
57. Penela D, Van Huls Van Taxis C, Aguinaga L, Fernández-Armenta J, Mont L, Castel MA, Heras M, Tolosana JM, Sitges M, Ordóñez A, Brugada J, Zeppenfeld K, Berruezo A. Neurohormonal, structural, and functional recovery pattern after premature ventricular complex ablation is independent of structural heart disease status in patients with depressed left ventricular ejection fraction: a prospective multicenter study. *J Am Coll Cardiol*. 2013 Sep 24;62(13):1195-202.
58. Anastasiou-Nana MI, Menlove RL, Mason JW, Western Enoximone Study Group: Quantification of prevalence of asymptomatic ventricular arrhythmias in patients with heart failure. *Ann Noninvasive Electrocardiol* 1997;2:346-53.
59. Burkart F, Pfisterer M, Kiowski W, Follath F, Burckhardt D. Effect of antiarrhythmic therapy on mortality in survivors of myocardial infarction with asymptomatic complex ventricular arrhythmias: Basel Antiarrhythmic Study of Infarct Survival (BASIS). *J Am Coll Cardiol*. 1990 Dec;16(7):1711-8.
60. Lakkireddy D, Di Biase L, Ryschon K, Biria M, Swarup V, Reddy YM, Verma A, Bommana S, Burkhardt D, Dendi R, Dello Russo A, Casella M, Carbucicchio C, Tondo C, Dawn B, Natale A. Radiofrequency ablation of premature ventricular ectopy improves the efficacy of cardiac resynchronization therapy in nonresponders. *J Am Coll*

Cardiol. 2012 Oct 16;60(16):1531-9.

61. Baman TS, Lange DC, Ilg KJ, Gupta SK, Liu TY, Alguire C, Armstrong W, Good E, Chugh A, Jongnarangsin K, Pelosi F Jr, Crawford T, Ebinger M, Oral H, Morady F, Bogun F. Relationship between burden of premature ventricular complexes and left ventricular function. *Heart Rhythm*. 2010 Jul;7(7):865-9.

IV. Acknowledgements

I would like to express my thanks to my project leader, Professor Kálmán Tóth for the encouragement, practical advice and help that he provided me to make a synthesis of my works. The recent study was partly performed in the Arrhythmia Section of the Cardiology Department in the Thorax Institute, Hospital Clinic, Barcelona and partly in the Institute of Cardiology at the University of Debrecen. I would like to express my gratitude to my tutors, Antonio Berruezo and Zoltán Csanádi for their fantastic ideas, support and guidance.

V. List of the author's publications

The thesis is based on the following papers and abstract

Publications

Herczku C, Berruezo A, Andreu D, Fernández-Armenta J, Mont L, Borràs R, Arbelo E, Tolosana JM, Trucco E, Ríos J, Brugada J. Mapping data predictors of a left ventricular outflow tract origin of idiopathic ventricular tachycardia with V3 transition and septal earliest activation. *Circ Arrhythm Electrophysiol.* 2012 Jun1;5(3):484-91.

IF: 6.462

Herczku C, Kun C, Edes I, Csanadi Z. Radiofrequency catheter ablation of premature ventricular complexes improved left ventricular function in a non-responder to cardiac resynchronization therapy. *Europace.* 2007 May;9(5):285-8.

IF: 1.376

Herczku Csaba, Tóth Kálmán: Kifolyótraktus eredetű kamrai ritmuszavarok diagnosztikája és kezelése mai szemmel (Current concepts in the diagnosis and treatment of outflow tract ventricular arrhythmias) *Cardiologia Hungarica* 2014; 44. évfolyam 1. szám

Citable abstract (congress poster)

C. Herczku, C. Kun, M. Clemens, I. Edes, Z. Csanadi Clinical significance of frequent ventricular premature beats after cardiac resynchronization therapy Eur J Heart Fail. Volume 7, Issue S1, June 2008, Page: 184

Other thesis related publication with co-authorship

Andreu D, Berruezo A, Fernández-Armenta J, Herczku C, Borràs R, Ortiz-Pérez JT, Mont L, Brugada J. Displacement of the target ablation site and ventricles during premature ventricular contractions: relevance for radiofrequency catheter ablation. Heart Rhythm. 2012 Jul;9(7):1050-7.

IF: 4.102

Other publications

1. Clemens M, Herczku C, Kun C, Edes I, Csanádi Z. Reduction in ventricular pacing after AV node modification in a patient with dual-chamber pacemaker: what is the mechanism? J Cardiovasc Electrophysiol. 2008 Oct;19(10):1116-7.

IF: 3.798

2. Szomják E, Dér H, Kerekes G, Veres K, Tóth J, Olvasztó S, Herczku C, Soltész P. Multiplex obliteratív érbetegség: Kihívás a diagnosztikában és a kezelésben [Multiple

obliterative vascular disease. Challenge in diagnosis and in treatment]. *Orv Hetil.* 2008 Nov 9;149(45):2135-40.

3. Clemens M, Nagy-Baló E, Herczku Cs, Karányi Zs, Édes I, Csanádi Z Correlation of body mass index and responder status in heart failure patients after cardiac resynchronization therapy : does the obesity paradox exist? *Intervent Med Appl Sci* 2010 Mar 25;2(1):17-2.

4. Herczku C, Clemens M, Edes I, Csanadi Z. Pacemaker-mediated tachycardia over the upper rate limit in a biventricular pacemaker system: what is the mechanism? *Pacing Clin Electrophysiol.* 2010 Nov;33(11):1421-4.

IF:1.353

5. Tóth Z, Nagy-Baló E, Kertész A, Clemens M, Herczku C, Tint D, Kun C, Edes I, Csanádi Z. Pitvarfibrilláció kezelése a pulmonalis vénák krioballon izolációjával: Középtávú eredmények az első 55 beteg alapján [Cryoballoon isolation of the pulmonary veins in atrial fibrillation: mid-term results after the first 55 patients]. *Orv Hetil.* 2010 Jan 31;151(5):163-71.

6. Clemens M, Nagy-Baló E, Herczku C, Kun C, Edes I, Csanádi Z. Long-term arrhythmia variability after monomorphic ventricular tachycardia in patients with an implantable cardioverter defibrillator. *Pacing Clin Electrophysiol.* 2011 Oct;34(10):1185-91.

IF: 1.351

7. Berruezo A, Fernández-Armenta J, Mont L, Zeljko H, Andreu D, Herczku C, Boussy T, Tolosana JM, Arbelo E, Brugada J. Combined endocardial and epicardial catheter ablation in arrhythmogenic right ventricular dysplasia incorporating scar dechanneling technique. *Circ Arrhythm Electrophysiol.* 2012 Feb;5(1):111-21.

IF: 6.462

8. Fernández-Armenta J, Berruezo A, Ortiz-Pérez JT, Mont L, Andreu D, Herczku C, Boussy T, Brugada J. Improving safety of epicardial ventricular tachycardia ablation using the scar dechanneling technique and the integration of anatomy, scar components, and coronary arteries into the navigation system. *Circulation.* 2012 Mar 20;125(11):e466-8.

IF:14.739

Citable abstracts (congress posters)

1.Cs Kun, Cs Herczku, A Peter, I Hegedus, I Lorincz, I Édes, Z Csanádi Effects of biventricular pacing on ECG markers of ventricular repolarization *Europace* 2006; 8(Suppl. 1): 20PW/6

2.C Herczku, C. Kun, M. Clemens, A. Peter, I. Hegedus, I. Edes, Z. Csanadi Examination for empiric interventricular delay optimization in cardiac resynchronization therapy *Eur J Echocardiogr.* 2007; 8(Suppl.1):(S70)504

3.C Herczku, C. Kun, M. Clemens, A. Peter, I. Hegedus, I. Edes, Z. Csanadi Patient selection for interventricular delay optimization in cardiac resynchronization therapy

Eur J Echocardiogr. 2007; 8(Suppl.1):(S68)498

4.Clemens M, Nagy-Balo E, Herczku C, Kun C, Edes I, Csanadi Z Predictive Value of the Index Arrhythmia In Long Term Programming of Implantable Cardioverter Defibrillators. Circulation 2008; 118:(18) S673

5.Csaba Kun, Csaba Herczku, Marcell Clemens, Istvan Lorincz, Istvan Edes, Zoltan Csanadi Effect of biventricular pacing on dispersion of ventricular repolarization Europace 2008; 10 (Suppl. 1):75L-1

6.M Clemens, E Nagy-Balo, C Herczku, C Kun, Z Toth, I Edes, Z Csanadi Correlation of body mass index and responder status in heart failure patients after cardiac resynchronization therapy: Does obesity paradox exists? Europace 2009; 11(Suppl. 2), Abstract 1004

7.Marcell Clemens, Orsolya Bene, Zsuzsa Toth, Csaba Herczku, Attila Kertesz, Istvan Edes, Zoltan Csanadi Diastolic Dysfunction may Cause Heart Failure Symptoms in Patients Hyperresponder to Cardiac Resynchronization Therapy Circulation.2010; 122: A20284

8.D. Andreu, A. Berruezo, J. Fernandez-Armenta, C. Herczku, R. Borrás, J.T. Ortiz, L. Mont, J. Brugada: Displacement of the target ablation site and ventricles during premature ventricular contractions: Relevance for ventricular tachycardia ablation. Europace 2012; 14(Suppl. 1.):63_L5